


Provided for non-commercial research and education use.
Not for reproduction, distribution or commercial use.



This article was published in an Elsevier journal. The attached copy is furnished to the author for non-commercial research and education use, including for instruction at the author's institution, sharing with colleagues and providing to institution administration.

Other uses, including reproduction and distribution, or selling or licensing copies, or posting to personal, institutional or third party websites are prohibited.

In most cases authors are permitted to post their version of the article (e.g. in Word or Tex form) to their personal website or institutional repository. Authors requiring further information regarding Elsevier's archiving and manuscript policies are encouraged to visit:

<http://www.elsevier.com/copyright>



Expression of survivin and XIAP for DMBA-induced hamster buccal pouch squamous cell carcinogenesis is associated with p53 accumulation

Shue-Sang Hsue, Yuk-Kwan Chen *, Li-Min Lin *

Oral Pathology Department, School of Dentistry, College of Dental Medicine, Kaohsiung Medical University, Kaohsiung Medical University Hospital, Kaohsiung, Taiwan

Received 5 November 2006; accepted 5 December 2006
Available online 15 February 2007

KEYWORDS

Survivin;
XIAP;
p53;
IAP

Summary Apoptosis (programmed cell death) is regulated by a number of inhibitory or stimulatory factors. One such family of antiapoptotic proteins is the inhibitors of apoptosis proteins (IAPs), of which survivin and X chromosome-linked IAP (XIAP) are members. The expression of survivin and XIAP, as well as their association with p53, in chemically-induced experimental oral carcinogenesis is not completely understood. The objective of the present study was, therefore, to investigate the protein expression of these two IAP family members and their relationship with p53 status, in 7,12-dimethylbenz[a]anthracene (DMBA)-induced hamster buccal pouch squamous cell carcinogenesis. Immunohistochemical analysis of survivin, XIAP and p53 protein expression was performed in DMBA-induced pouch squamous cell carcinogenesis. Fifty outbred, young (6 weeks), male Syrian golden hamsters (*Mesocricetus auratus*) were randomly divided into three experimental groups (each group consisting of 10 animals treated with DMBA for 3-, 7- or 14-weeks), and two control groups (with 10 animals in each). The pouches of the three experimental groups were painted bilaterally with a 0.5% DMBA solution three times a week. The treatment protocol for animals in one of the control groups was identical with only mineral oil applied, while the other control group remained untreated throughout the experiment. Survivin staining could not be detected by immunohistochemistry in any of the untreated or mineral oil treated hamster pouch-tissue specimens. Cytoplasmic staining of survivin proteins was apparent in the entire epithelial layer (excluding the keratinized layer) in all 3-week DMBA treated pouch-tissue analyzed. In addition, cytoplasmic survivin staining was observed in all specimens of 7- and 14-week DMBA treated pouch-tissue. XIAP positivity was confined to the outermost keratinized layer of the pouch-tissue from control animals and those treated with DMBA for 3-weeks. However, XIAP staining was detected in the whole epithelial layer (except

* Corresponding authors. Tel.: +886 7 3121107x7007; fax: +886 7 3210637.
E-mail addresses: k0285@ms22.hinet.net (Y.-K. Chen), k0285@ms22.hinet.net (L.-M. Lin).

the basal layer) in 7- and 14-week DMBA treated pouch-tissue. p53 was not detected in any untreated and mineral oil treated pouch-tissue, whereas nuclear p53 staining was observed for all 3-, 7- and 14-week DMBA treated pouch-tissue. The results of this study demonstrate the association between survivin/XIAP and p53 expression in this experimental model system for oral carcinogenesis, although their exact interactions remain to be clarified. Moreover, our findings suggest that the DMBA-induced hamster buccal pouch mucosa may serve as an appropriate experimental model for investigation of potential novel therapeutic tools for oral squamous-cell carcinomas.

© 2006 Elsevier Ltd. All rights reserved.

Introduction

Apoptosis, also termed programmed cell death, plays diverse roles in embryogenesis and normal homeostasis, as well as in tumorigenesis.^{1–3} Apoptotic processes are executed by a number of factors, which have inhibitory or stimulatory effects.^{2–4} Besides the pro- and anti-apoptotic Bcl-2 family proteins,^{5,6} there is another family of inhibitors of apoptosis proteins (IAPs). IAPs, first described in baculovirus are characterized by a novel domain of approximately 70 amino acids, known as the baculoviral IAP repeat (BIR). This domain is able to inhibit caspases and, thus, suppress apoptosis.^{7–9} Proteins containing BIR domains have been found in a wide variety of eukaryotic species, and eight IAP members have been identified in humans.⁹

Survivin protein (MW: 16.5 kDa) is the smallest of the known IAP family proteins. The gene is situated on chromosome 17q25, approximately 3% of the distance from the telomere, and comprises three introns and four exons.¹⁰ It is a unique bifunctional protein that inhibits apoptosis by suppressing caspase-3 and caspase-7 and modulates the G2/M phase of the cell cycle through association with mitotic spindle microtubules.¹¹ Interestingly, survivin contains a single BIR domain and can bind caspases, preventing caspase-induced apoptosis.¹² It is the least-expressed IAP family candidate in adult tissues (it is almost absent in normal tissue), but can be recognized in developing fetal tissues, with the exceptions of placenta and thymus.^{13–16}

X chromosome-linked IAP (XIAP; MW: 57 kDa), whose gene is located at chromosome Xq25, is another IAP family member and inhibits apoptosis by binding distinct caspases (caspases-3, -7 and -9).^{17–19} Expression of XIAP mRNA has been observed in most fetal and adult tissues with the exception of peripheral blood lymphocytes.¹⁹ Mice deficient in XIAP have shown upregulation of other IAP members.²⁰ Furthermore, XIAP expression has also been investigated in the ovary, where apoptosis is regarded to be importance in ovulation. In granulosa cells from pre-antral and early antral follicles, extensive apoptosis was associated with decreased XIAP protein level.²¹

The p53 tumor-suppressor gene is involved in cell cycle checkpoint mechanisms, preventing cell cycle progression and inducing apoptosis in response to DNA damage.²² Given that p53 expression has been previously reported in hamster buccal pouch cancerous tissue,^{23–25} the relationship between IAP and p53 remains an interesting area for study.

The hamster buccal pouch mucosa constitutes one of the most widely accepted experimental models for oral carcinogenesis.²⁶ Despite anatomic and histologic variations be-

tween hamster pouch mucosa and human buccal tissue, experimental carcinogenesis protocols for the former induce premalignant changes and carcinomas that resemble those that take place during analogous development in human oral mucosa.²⁷ As the expression of survivin and XIAP, as well as their association with p53, in experimental oral carcinogenesis is not completely understood, this study was designed to investigate the protein expression of these two IAP members in 7,12-dimethylbenz[a]anthracene (DMBA)-induced hamster buccal pouch squamous cell carcinogenesis. In addition, the relationship between the survivin and XIAP expression and p53 status in DMBA-induced hamster buccal pouch squamous cell carcinogenesis was also examined.

Materials and methods

Animals

Outbred, young (6 weeks), male, Syrian golden hamsters (*Mesocricetus auratus*; 50 animals, purchased from the National Science Council Animal Breeding Center, Taipei, ROC), weighing approximately 100 g at the beginning of the experiment, were randomly divided into three experimental and two control groups (10 animals per group). The animals were housed under constant conditions (22 °C, and a 12 h light/dark cycle) and supplied with tap water and standard Purina laboratory chow ad libitum. Appropriate animal care and an approved experimental protocol ensured humane treatment, and all procedures were conducted in accordance with the NIH Guide for the Care and Use of Animals. After allowing the animals one week of acclimatization to their new surroundings, both pouches from all animals in the experimental groups were painted with a 0.5% DMBA solution at 9 AM on Monday, Wednesday and Friday of each week, using a No. 4 sable-hair brush. Bilateral pouches from each animal of one control group were similarly treated with mineral oil. Approximately 0.2 ml of the appropriate solution was applied topically to the medial walls of both pouches at each painting. The second control group of animals remained untreated throughout the experiment. At the end of 3 weeks (3 days after the last treatment), all animals from one of the experimental groups were simultaneously killed by administration of a lethal dose of diethyl ether at 9 AM, to avoid any influence of diurnal variation.²⁸ Their pouches were exposed by dissection and examined grossly. Both pouches were then excised and placed on cardboard to prevent distortion of the pouch tissues. After 7 weeks of treatment, the animals from one of the two remaining experimental groups were killed in

a similar manner. Then, at 14 weeks, the animals from the last experimental group and those from the two control groups were killed, using the same procedure. The pouch-mucosa specimens were routinely processed for light microscopy by fixation in 10% neutral-buffered formalin solution, with dehydration in increasing concentrations of alcohol solution, clearing in xylene, and paraffin embedding. Serial sections of each specimen were prepared, at a thickness of 4 μm , for immunohistochemical analysis as well as for hematoxylin–eosin staining.

Immunohistochemistry

Staining was performed using a standard avidin–biotin peroxidase complex (ABC) method.²⁹ Rabbit polyclonal antibodies against human, rat and mouse survivin and XIAP (Cat. Nos. ab469 and ab21278, Abchem Corporation, Cambridge, UK) were used and their specificity has been established in previous studies.^{30,31} Monoclonal antibody NCL-p53-D07 (mAb DO7; Novocastra, Newcastle, UK) was used for the identification of p53 protein. The mAb DO7 antibody detects both wild-type and mutant forms of p53.³²

Tissue sections were mounted on gelatin-chrome alum-coated slides. Following deparaffinization in xylene (twice) and rehydration in a decreasing-concentration ethanol series (absolute, 95%, 70% and 30% ethanol, and then water), tissue sections were microwave treated three times (5 min each) in citrate buffer (10 mM; pH 6.0) in order to retrieve antigenicity. Endogenous peroxidase activity was blocked with 3% H_2O_2 in methanol for 60 min. Prior to staining for survivin and XIAP, a 10% solution of normal rabbit serum was applied for 60 min to tissue sections in order to inhibit non-specific staining. These sections were subsequently incubated with antibodies against survivin and XIAP (1:100, each for survivin and XIAP) overnight at 4 °C. A blocking solution of 2% low-fat milk powder in TBS (with 0.02% sodium azide) was applied to those sections to be stained for p53 protein. These sections were then treated with mAb DO7 at a dilution of 1:200 for 2 h at room temperature. Following subsequent rinsing with Tris-buffered saline (TBS, 3 times, 10 min each), tissue sections stained for survivin and XIAP were then incubated for 60 min at room temperature with biotin-conjugated goat anti-rabbit IgG (Vector, Burlingame, CA, USA; 1:100). By contrast, the sections stained for p53 were treated with biotinylated anti-mouse IgG antibody (Vector; 1:100) for 30 min. Following this, all the sections (those stained for survivin, XIAP and p53) were again washed with TBS (3 times, 10 min each) and then incubated with avidin-biotin complex conjugated to horseradish peroxidase (Dako, Santa Barbara, CA, USA) for a further 60 min. After washing with PBS (3 times, 10 min each), peroxidase binding was visualized as brown reaction products via a benzidine reaction. The sections were then counterstained with Mayer's hematoxylin. Each set of experiments included a human buccal squamous-cell carcinoma specimen known to express survivin, XIAP and p53, which served as a positive control and ensured the reproducibility of the staining process. Immunohistochemical staining was classified as negative if staining was apparent in 10% of cells or less, and positive where over 10% were stained. A negative control, in which

the primary antibody step was omitted, was also included in each set of experiments.

Results

Gross observation and histopathology

Upon gross examination, there were no apparent changes for any of the mineral oil-treated or untreated pouches. Thickened mucosa, with a rough surface and of whitish granular appearance, were noted in the 3- and 7-week DMBA-treated pouches, with 100% tumor incidence apparent in all samples after 14 weeks DMBA treatment.

No significant histologic changes were observed for any of the mineral oil-treated or untreated pouches. However, hyperkeratosis was noted in the 3-week DMBA-treated pouches and areas of epithelial hyperplasia were observed in the 7-week DMBA-treated pouches. Furthermore, infiltrative squamous cell carcinomas were detected in the 14-week DMBA-treated mucosa.

Immunochemistry

No survivin staining could be found in any of the untreated and mineral oil treated hamster pouch-tissue specimens (Fig. 1A). Cytoplasmic staining of survivin proteins was detected in the entire epithelial layer (except the keratinized layer) in all hamster pouch tissues treated with DMBA for 3 weeks (Fig. 1B). In addition, cytoplasmic staining of survivin protein was observed in all specimens of hamster buccal pouch tissue treated with DMBA for 7 weeks (Fig. 1C) and 14 weeks (Fig. 1D).

In contrast, XIAP staining was located in the outermost keratinized layer of the untreated, mineral oil treated and all 3 weeks DMBA treated pouch tissues (Fig. 2A and B). Interestingly, cytoplasmic staining of XIAP proteins was found to extend downwards and was detected in the whole epithelial layer (with the exception of the basal layer) in all specimens of hamster buccal-pouch tissue treated with DMBA for 7 weeks (Fig. 2C). Similar cytoplasmic staining of XIAP proteins was also observed for all specimens of pouch tissue treated with DMBA for 14 weeks (Fig. 2D).

No p53 staining could be detected in any of the untreated and mineral oil treated pouch-tissue specimens (Fig. 3A), whereas, nuclear staining of p53 was noted for all pouch tissues treated with DMBA for 3 weeks (Fig. 3B). In addition, nuclear staining of p53 proteins was present in all specimens of pouch tissue treated with DMBA for 7 weeks (Fig. 3C), and for 14 weeks (Fig. 3D).

Discussion

Overexpression of some IAP family members has been noted in cancers, implying that IAP-mediated inhibition of apoptosis may participate to tumorigenesis.³³ The association of some IAP family members, especially survivin, with human oral squamous cell carcinomas has extensively been reported;^{34–43} however, the relationship of the IAP family with chemically-induced oral experimental carcinogenesis has rarely been studied. Recently, our laboratory has reported on the survivin expression in DMBA-induced hamster buccal pouch tissue carcinoma.⁴⁴ In the current study, we

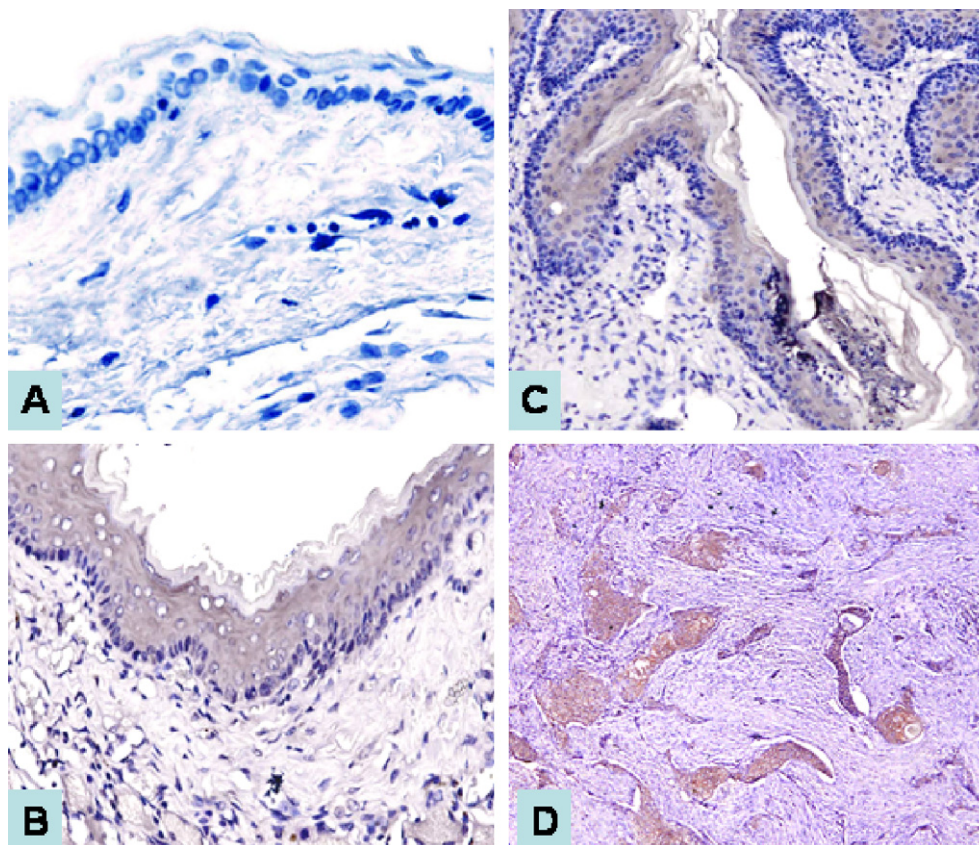


Figure 1 Survivin staining was not detected in untreated hamster pouch-tissue specimen (A, ABC stain $\times 200$). Cytoplasmic staining of survivin proteins was detected in the entire epithelial layer (except the keratinized layer) of a representative 3-week DMBA treated pouch tissue sample (B, ABC stain $\times 100$). Representative cytoplasmic survivin staining for specimens of hamster pouch-tissue treated with DMBA for 7-weeks (C, ABC stain $\times 100$) and 14-weeks (D, ABC stain $\times 40$).

further demonstrate the expression of survivin protein during DMBA-induced hamster buccal pouch carcinogenesis. This is, to the best of our knowledge, the first study to document the sequence of survivin expression in chemically-induced oral experimentally carcinogenesis. Our results indicate that survivin protein expression is an early event in DMBA-induced pouch carcinogenesis, compatible with the findings of human oral carcinogenesis.^{35,36} Therefore, the present study further supports the hypothesis that IAPs may be associated with oral carcinogenesis.

XIAP protein expression has rarely reported in human oral carcinoma in English-language medical literature.⁴⁵ Furthermore, its expression in chemically-induced oral experimental carcinogenesis has not been studied previously. In the present study, we demonstrate the sequential pattern of expression of XIAP protein during DMBA-induced hamster buccal pouch tissue carcinogenesis. Furthermore, we found that during DMBA treatment, XIAP expression progresses downwards from location within the outermost keratinized layer in untreated, mineral oil treated and 3 weeks DMBA treated pouch-tissue to expression throughout the whole epithelial layer (except the basal layer) after 7 weeks treatment, as well as detection in the tumor islands of the 14 weeks analog. This suggests that XIAP expression increases during DMBA-induced pouch carcinogenesis and is greater in less-differentiated cells than mature pouch keratinocytes.

As both survivin and XIAP proteins have been found to be overexpressed in this study, a synergistic effect between these two IAP members and consequently a possible common regulatory mechanism might be presumed. To date, the interaction amongst IAP family members remains unclear. A possible interaction between IAP family members has been reported; survivin was demonstrated to bind second mitochondria-derived activator of caspase (Smac), relieving its suppression of XIAP, and subsequently permitting XIAP to function.⁴⁶ Further investigation into the synergistic effect amongst IAP members during DMBA-induced hamster buccal-pouch carcinogenesis is required to elucidate the relationship between coexpression of IAPs and oral experimental carcinogenesis.

Mechanisms of IAP overexpression in cancer are largely unknown. Amplification of the survivin locus on chromosome 17 and DNA demethylation of its promoter region have been reported as possible mechanisms of survivin upregulation in some cancers,⁴⁷ including human oral cancer and chemically-induced hamster pouch carcinoma.^{35,44} Furthermore, loss of p53 or mutant p53 might result in the upregulation of survivin expression^{48,49} but the relevance of p53 regulation to other IAP family members such as XIAP remains to be elucidated. In the present study, we demonstrate that the expression of both survivin and XIAP is associated with p53 accumulation during DMBA-induced pouch carcinogenesis.

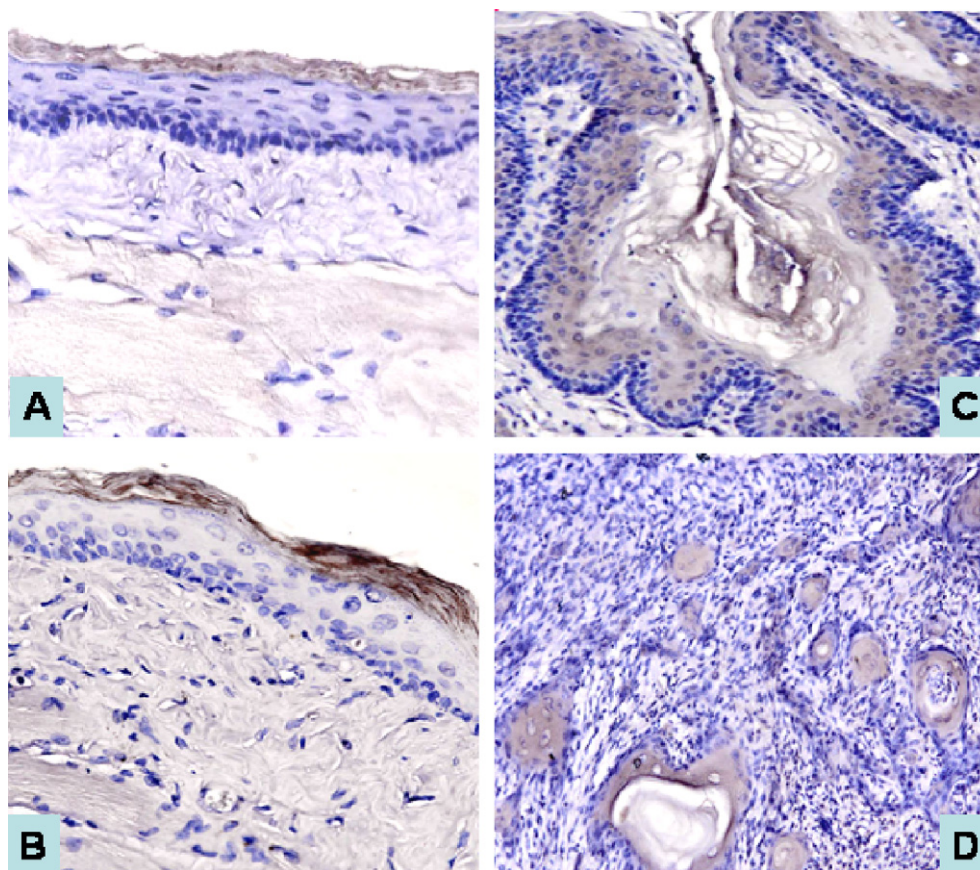


Figure 2 XIAP staining was located in the keratinized layer of an untreated pouch-tissue specimen (A, ABC stain $\times 100$), as well as a representative 3-week DMBA treated pouch tissue (B, ABC stain $\times 100$). Cytoplasmic staining was detected in the whole layer (except for the basal layer) of a representative specimen of 7-week DMBA treated pouch-tissue (C, ABC stain $\times 100$). Representative specimen of pouch-tissue treated with DMBA for 14 weeks demonstrated cytoplasmic XIAP staining (D) (ABC stain $\times 100$).

Mirza et al.⁴⁸ and Hoffman et al.⁴⁹ demonstrated that the cellular accumulation of wild-type p53 suppresses p53 responsive promoter activity, resulting in the down-regulation of survivin expression, thus suggesting a negative feedback loop between survivin expression and wild-type p53. Based on these findings, along with the appreciation of a rather high p53 mutation frequency for hamster buccal pouch carcinomas^{24–26} and the results of this present study, the following mechanism may be associated with the correlation between IAP and p53 expression for DMBA-induced hamster pouch carcinogenesis: following DMBA treatment, p53-mutation (induced by a high concentration DMBA) in pouch keratinocytes, could be responsible for the failure of the negative feedback loop that exists between IAP and wild-type p53. As a result of this failure, IAP expression would therefore remain unchecked and subsequently become up-regulated, with the potential to progress to a cancerous state. Although the p53 primary antibody used in this study was not able to differentiate between wild-type and mutant p53, a previous study⁵⁰ has suggested that p53 mutation could result in an accumulation of p53. Furthermore, based on the finding that all samples in the present study revealed the overexpression of IAP (survivin and XIAP) and p53 protein, we hypothesize that the aforementioned mechanism is likely to predominate, although it is the subject of some conjecture. In future, further study on p53

gene expression should be performed in order to assess really the presence of p53 gene mutation.

Understanding the mechanism of IAP function could potentially enable the development of therapeutic strategies for cancer. The almost cancer-specific expression of survivin, coupled with its importance in suppressing cell death and in regulating cell division, makes it a useful diagnostic marker of cancer and a potential target for the treatment of oral cancer.

Emerging data implicate a pivotal role for IAP family members in maintaining cancer cell survival and inhibiting apoptosis induced by anticancer drugs.^{51–53} Our results demonstrate that overexpression of both survivin and XIAP occurs frequently in chemically-induced oral experimentally carcinogenesis. These data provide further validation of IAP family members as potential drug discovery targets for the improved treatment of oral cancer. Furthermore, the observation that frequently more than one IAP family member is expressed simultaneously in our study raises the possibility that effective strategies will require IAP antagonists capable of inhibiting multiple members of this family of apoptosis-suppressing proteins.

In conclusion, we report what is, to the best of our knowledge, the first identification of the association between survivin/XIAP and p53 expression in this experimental model system for oral carcinogenesis, although their exact

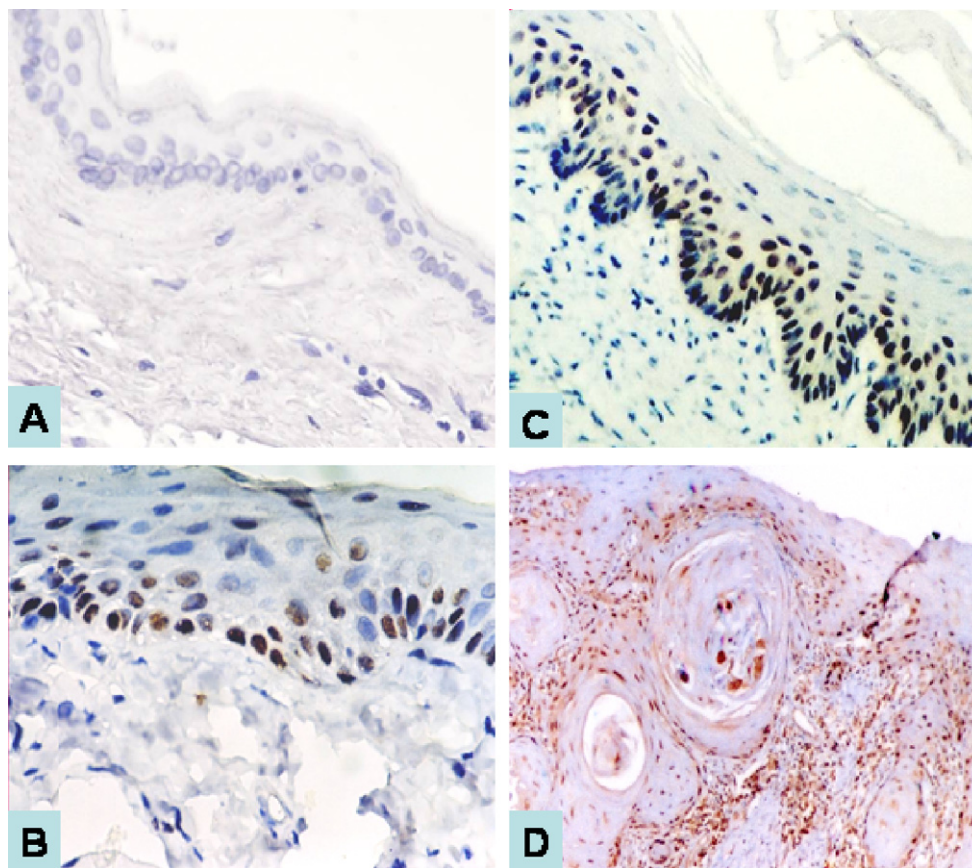


Figure 3 Negative p53 staining was observed for an untreated pouch-tissue specimen (A, ABC stain $\times 100$). Nuclear staining of p53 was noted in representative samples from 3-week (B, ABC stain $\times 200$), 7-week (C, ABC stain $\times 100$) and 14-week (D, ABC stain $\times 40$) DMBA treated pouch tissue.

interactions remain to be clarified. Taken together, our findings indicate that the DMBA-induced hamster buccal pouch mucosa may serve as a suitable experimental model for investigation of the potential of targeting strategies as novel therapeutic tools for oral squamous-cell carcinomas.

Acknowledgements

We wish to acknowledge the technical assistance of Ms S.M. Ji and Ms L.M. Chen. This research was partly supported by a grant from the National Science Council, ROC (N.S.C. 94-2314-B-037-054).

References

- Kerr JF, Wyllie AH, Currie AR. Apoptosis: a basic biological phenomenon with wide-ranging implications in tissue kinetics. *Br J Cancer* 1972;**26**:239–57.
- Soini Y, Paakko P, Lehto VP. Histopathological evaluation of apoptosis in cancer. *Am J Pathol* 1998;**153**:1041–53.
- Thompson CB. Apoptosis in the pathogenesis and treatment of disease. *Science* 1995;**267**:1456–62.
- Reed JC. Mechanisms of apoptosis. *Am J Pathol* 2000;**157**:1415–1430.
- Reed JC. Bcl-2 family proteins: regulators of apoptosis and chemoresistance in hematologic malignancies. *Semin Hematol* 1997;**34**:9–19.
- Reed JC. Bcl-2 family proteins. *Oncogene* 1998;**17**:3225–36.
- Clem RJ, Fechheimer M, Miller LK. Prevention of apoptosis by a baculovirus gene during infection of insect cells. *Science* 1991;**254**:1388–90.
- Deveraux QL, Reed JC. IAP family proteins: suppressors of apoptosis. *Genes Dev* 1999;**13**:239–52.
- Takahashi R, Deveraux Q, Tamm I, Welsh K, Assa-Munt N, Salvesen GS, et al. A single BIR domain of XIAP sufficient for inhibiting caspases. *J Biol Chem* 1998;**273**:7787–90.
- Altieri DC, Marchisio C. Survivin apoptosis: an interloper between cell death and cell proliferation in cancer. *Lab Invest* 1999;**79**:1327–33.
- Yamamoto T, Tanigawa N. The role of survivin as a new target of diagnosis and treatment in human cancer. *Med Electron Microsc* 2001;**34**:207–12.
- Tamm I, Want Y, Sausville E, Scudiero DA, Vigna N, Oltsersdorf T, et al. IAP-family protein survivin inhibits caspase activity and apoptosis induced by Fas (CD95), Bax, caspases, and anticancer drugs. *Cancer Res* 1998;**59**:5315–20.
- Altieri DC. Survivin, versatile modulation of cell division and apoptosis in cancer. *Oncogene* 2003;**22**:8581–9.
- Kajiwara Y, Yamasaki F, Hama S, Yahara K, Yoshioka H, Sugiyama K, et al. Expression of survivin in astrocytic tumors: correlation with malignant grade and prognosis. *Cancer* 2003;**97**:1077–83.
- Islam A, Kageyama H, Takada N, Kawamoto T, Takayasu H, Isogai E, et al. High expression of survivin, mapped to 17q25, is significantly associated with poor prognostic factors and promotes cell survival in human neuroblastoma. *Oncogene* 2000;**19**:617–23.

16. Ambrosini G, Adida C, Altieri D. A novel anti-apoptosis gene, *survivin*, expressed in cancer and lymphoma. *Nat Med* 1997;3:917–21.
17. Deveraux QL, Takahashi R, Salvesen GS, Reed JC. X-linked IAP is a direct inhibitor of cell-death proteases. *Nature* 1997;388:300–4.
18. Deveraux QL, Roy N, Stennicke HR, Van Arsedale T, Zhou Q, Srinivasula SM, et al. IAPs block apoptotic events induced by caspase-8 and cytochrome *c* by direct inhibition of distinct caspases. *EMBO J* 1998;17:2215–23.
19. Liston P, Roy N, Tamai K, Lefebvre C, Baird S, Cherton-Horvat G, et al. Suppression of apoptosis in mammalian cells by NAIP and a related family of IAP genes. *Nature* 1996;379:349–53.
20. Harlin H, Reffey SB, Duckett CS, Lindsten T, Thompson CB. Characterization of XIAP-deficient mice. *Mol Cell Biol* 2001;21:3604–8.
21. Li J, Kim JM, Liston P, Li M, Miyazaki T, Mackenzie AE, et al. Expression of inhibitor of apoptosis proteins (IAPs) in rat granulosa cells during ovarian follicular development and atresia. *Endocrinology* 1998;139:1321–8.
22. Gottlieb TM, Oren M. p53 and apoptosis. *Sem Cancer Biol* 1998;8:359–68.
23. Gimenez-Conti IB, LaBate M, Liu F, Osterndorff E. p53 alterations in chemically induced hamster cheek-pouch lesions. *Mol Carcinogenesis* 1996;16:197–202.
24. Chang KW, Sarraj S, Lin SC, Tsai PI, Solt D. p53 expression, p53 and Ha-ras mutation and telomerase activation during nitrosamine-mediated hamster pouch carcinogenesis. *Carcinogenesis* 2000;21:1441–51.
25. Chen YK, Hsue SS, Lin LM. Correlation between inducible nitric oxide synthase and p53 expression for DMBA-induced hamster buccal-pouch carcinomas. *Oral Dis* 2003;9:227–34.
26. Gimenez-Conti IB, Slaga TJ. The hamster cheek pouch carcinogenesis model. *J Cell Biochem* 1993;17F(Suppl.):83–90.
27. Morris AL. Factors influencing experimental carcinogenesis in the hamster cheek pouch. *J Dent Res* 1961;40:3–15.
28. Lin LM, Chen YK. Diurnal variation of γ -glutamyl transpeptidase activity during DMBA-induced hamster buccal pouch carcinogenesis. *Oral Dis* 1997;3:153–6.
29. Hsu SM, Raine L, Fanger H. Use of avidin–biotin–peroxidase complex (ABC) in immunoperoxidase techniques: a comparison between ABC and unlabelled antibody (PAP) procedures. *J Histochem Cytochem* 1981;29:577–80.
30. Barnes N, Haywood P, Flint P, Knox WF, Bundred NJ. Survivin expression in situ and invasive breast cancer relates to COX-2 expression and DCIS recurrence. *Br J Cancer* 2006;94:253–8.
31. Liston P, Fong WG, Kelly NL, Toji S, Miyazaki T, Conte D, et al. Identification of XAF1 as an antagonist of XIAP anti-Caspase activity. *Nat Cell Biol* 2001;3:128–33.
32. Vojtesek B, Bartek J, Midgley CA, Lane DP. An immunohistochemical analysis of the human nuclear phosphoprotein p53. New monoclonal antibodies and epitope mapping using recombinant p53. *J Immunol Meth* 1992;151:237–44.
33. LaCasse EC, Baird S, Korneluk RG, MacKenzie AE. The inhibitors of apoptosis (IAPs) and their emerging role in cancer. *Oncogene* 1998;17:3247–59.
34. Lo Muzio L, Staibano S, Pannone G, Mignogna MD, Mariggio A, Salvatore G, et al. Expression of the apoptosis inhibitor survivin in aggressive squamous cell carcinoma. *Exp Mol Pathol* 2001;70:249–54.
35. Tanaka C, Uzawa K, Shibahara T, Yokoe H, Noma H, Tanzawa H. Expression of an inhibitor of apoptosis, survivin, in oral carcinogenesis. *J Dent Res* 2003;82:607–11.
36. Lo Muzio L, Pannone G, Leonardi R, Staibano S, Mignogna MD, De Rosa G, et al. Survivin, a potential early predictor of tumor progression in the oral mucosa. *J Dent Res* 2003;82:923–8.
37. Lo Muzio L, Pannone G, Staibano S, Mignogna MD, Rubini C, Mariggio MA, et al. Survivin expression in oral squamous cell carcinoma. *Br J Cancer* 2003;89:2244–8.
38. Kim MJ, Lim KY, Kim JW, Nam IW, Lee JH, Myoung H. Stage and mRNA expression of survivin in lymph node as prognostic indicators in patients with oral squamous cell carcinoma. *Cancer Lett* 2005;224(28):253–61.
39. Lo Muzio L, Farina A, Rubini C, Pezzetti F, Stabellini G, Laino G, et al. Survivin as prognostic factor in squamous cell carcinoma of the oral cavity. *Cancer Lett* 2005;225:27–33.
40. Lin CY, Hung HC, Kuo RC, Chiang CP, Kuo MY. Survivin expression predicts poorer prognosis in patients with areca quid chewing-related oral squamous cell carcinoma in Taiwan. *Oral Oncol* 2005;41:645–54.
41. Marioni G, Bedogni A, Giacomelli L, Ferraro SM, Bertolin A, Facco E, et al. Survivin expression is significantly higher in pN+ oral and oropharyngeal primary squamous cell carcinomas than in pN0 carcinomas. *Acta Otolaryngol* 2005;125:1218–23.
42. Tanimoto T, Tsudaa H, Imazekia N, Ohnob Y, Imoto I, Inazawa J, et al. Nuclear expression of cIAP-1, an apoptosis protein, inhibiting in head and neck squamous cell carcinomas predicts lymph node metastasis and poor patient prognosis. *Cancer Lett* 2005;224:141–51.
43. Jane C, Nerurkar AV, Shirsat NV, Deshpande RB, Amrapurkar FR, Karjodkar FR. Increased survivin expression in high-grade oral squamous cell carcinoma: a study in Indian tobacco chewers. *J Oral Pathol Med* 2006;35:595–601.
44. Chen YK, Hsue SS, Lin LM. Survivin expression is regulated by an epigenetic mechanism for DMBA-induced hamster buccal-pouch squamous-cell carcinomas. *Arch Oral Biol* 2005;50:593–598.
45. Matsumiya T, Imaizumi T, Yoshida H, Kimura H, Satoh K. Cisplatin inhibits the expression of X-chromosome-linked inhibitor of apoptosis protein in an oral carcinoma cell line. *Oral Oncol* 2001;37:296–300.
46. Song Z, Yao X, Wu M. Direct interaction between survivin and Smac/DIABLO is essential for the anti-apoptotic activity of survivin during taxol-induced apoptosis. *J Biol Chem* 2003;278:23130–40.
47. Altieri DC. The molecular basis and potential role of survivin in cancer diagnosis and therapy. *Trends Mol Med* 2001;7:542–7.
48. Mirza A, McGuirk M, Hockenberry TN, Wu Q, Ashar H, Black S, et al. Human survivin is negatively regulated by wild-type p53 and participates in p53-dependent apoptotic pathway. *Oncogene* 2002;21:2613–22.
49. Hoffman WH, Biade S, Zilfou JT, Chen J, Murphy M. Transcriptional repression of the anti-apoptotic survivin gene by wild type p53. *J Biol Chem* 2002;277:3247–57.
50. Wang LD, Shi ST, Zhou Q, Goldstein S, Hong JY, Shao P, et al. Changes in p53 and cyclin D1 protein levels and cell proliferation in different stages of human esophageal and gastric-cardia carcinogenesis. *Int J Cancer* 1994;59:514–9.
51. Li F, Ackermann E, Bennett C, Rothermel A, Plescia J, Tognin S, et al. Pleiotropic cell division defects and apoptosis induced by interference with survivin function. *Nat Cell Biol* 1999;1:461–6.
52. Sasaki H, Sheng Y, Kotsuji F, Tsang BK. Down-regulation of X-linked inhibitor of apoptosis protein induces apoptosis in chemoresistant human ovarian cancer cells. *Cancer Res* 2000;60:5659–66.
53. Li J, Feng Q, Kim JM, Schneiderman D, Liston P, Li M, et al. Human ovarian cancer and cisplatin resistance: possible role of inhibitor of apoptosis proteins. *Endocrinology* 2001;142:370–80.