


Case Report

Laser Doppler for Accurate Diagnosis of Oehler's Type III Dens Invaginatus: A Case Report

Hui-Na Lee ^{1,†}, Dah-You Yan ^{2,†}, Chun-Yin Huang ³, Shih-Chieh Chen ⁴, Chin-Yun Pan ⁴, Jjiang-Huei Jeng ^{5,6,7}, Yuk-Kwan Chen ^{5,8,9}  and Fu-Hsiung Chuang ^{1,5,*}

¹ Division of Endodontics and Operative Dentistry, Department of Dentistry, Kaohsiung Medical University Hospital, Kaohsiung 807378, Taiwan; 1030623@ms.kmu.edu.tw

² Division of Periodontics, Department of Dentistry, Kaohsiung Medical University Hospital, Kaohsiung 807378, Taiwan; 1010395@ms.kmu.edu.tw

³ Department of Nuclear Medicine, E-DA Hospital, Kaohsiung 824005, Taiwan; jyhuang@ntu.edu.tw

⁴ Division of Orthodontics, Department of Dentistry, Kaohsiung Medical University Hospital, Kaohsiung 807378, Taiwan; 1030414@ms.kmu.edu.tw (S.-C.C.); 910119@ms.kmu.edu.tw (C.-Y.P.)

⁵ School of Dentistry, College of Dental Medicine, Kaohsiung Medical University, Kaohsiung 807378, Taiwan; jhjeng@kmu.edu.tw (J.-H.J.); yukkwa@kmu.edu.tw (Y.-K.C.)

⁶ School of Dentistry, National Taiwan University Medical College, Taipei 100225, Taiwan

⁷ Department of Dentistry, National Taiwan University Hospital, Taipei 100225, Taiwan

⁸ Division of Oral Pathology & Maxillofacial Radiology, Kaohsiung Medical University Hospital, Kaohsiung 807378, Taiwan

⁹ Oral & Maxillofacial Imaging Center, College of Dental Medicine, Kaohsiung Medical University, Kaohsiung 807378, Taiwan

* Correspondence: d860203@kmu.edu.tw; Tel.: +886-7-312-1101 (ext. 7002)

† These authors contributed equally to the 1st author.



Citation: Lee, H.-N.; Yan, D.-Y.; Huang, C.-Y.; Chen, S.-C.; Pan, C.-Y.; Jeng, J.-H.; Chen, Y.-K.; Chuang, F.-H. Laser Doppler for Accurate Diagnosis of Oehler's Type III Dens Invaginatus: A Case Report. *Appl. Sci.* **2021**, *11*, 3848. <https://doi.org/10.3390/app11093848>

Academic Editor: Luca Testarelli

Received: 5 April 2021

Accepted: 22 April 2021

Published: 24 April 2021

Publisher's Note: MDPI stays neutral with regard to jurisdictional claims in published maps and institutional affiliations.



Copyright: © 2021 by the authors. Licensee MDPI, Basel, Switzerland. This article is an open access article distributed under the terms and conditions of the Creative Commons Attribution (CC BY) license (<https://creativecommons.org/licenses/by/4.0/>).

Abstract: In vital pulp therapy, pulp testing aids in the differential diagnosis and influences the treatment plan. Different from previous doppler flowmetry studies that only recorded waves and data, we report the first time, the use of a laser doppler blood flow monitor and imager with a colored image to present pulp vitality information in the dental field. We report here a case of Oehlers type IIIa dens invaginatus of the right upper lateral incisor in a 31-year-old girl, with the opening of the invagination near CDJ and a peri-invagination lesion sized $8 \times 9 \text{ mm}^2$. Cone beam computed tomography was used to verify specific spatial and stereoscopic data. After removing the source of infection, mineral trioxide aggregate was selected to fill the invagination. Laser doppler was scheduled for further assessment. After three years of regular follow-up, the patient's clinical condition improved, the peri-invagination lesion healed, and the laser doppler and electric pulp test both showed a positive reaction. Laser doppler has successfully improved the diagnostic accuracy. Thus, unnecessary interventions can be avoided while reducing the treatment time by preserving the vitality. However, further work is needed to resolve the limitations of laser doppler.

Keywords: dens invaginatus; conservative; vital pulp; laser doppler

1. Introduction

Dens invaginatus (DI) is a rare dental malformation resulting from an invagination of the tooth crown [1]. In most cases, it occurs when the enamel organ invaginates into the surrounding dental papilla prior to its calcification [2].

The type of endodontic treatment and disease prognosis depends on the type of abnormality [3], and cone beam computed tomography (CBCT) has been used to verify specific spatial and stereoscopic data [4]. Therefore, there is a need for early diagnosis and accurate evaluation of treatment options [5,6].

There are various concepts, techniques, and materials involved in vital pulp therapy [7]. Dentists should carefully evaluate the pulp condition and eliminate all infections

during the vital pulp treatment procedure, which should be guided by minimally invasive procedures using the optimal material and technique to provide the maximum advantages [8].

In vital pulp therapy, dental pulp testing aids the differential diagnosis and influences the treatment plan such as electric pulp testing, propane-butane spray and CO₂ [9]. Electric pulp testing, which is commonly used in current clinical practices, functions by stimulating the A δ fibers in the dentin-pulp complex of the test tooth through stimulation of a quick, sharp, and transitory tingling sensation [10,11]. Since it relies on the patient's subjective experience to respond to the test, the objective assessment of the pulp condition is difficult [9,12]. Laser doppler flowmetry (LDF) is a non-invasive, objective, painless test that acquires the frequency-shift signal using optical methods, and subsequently switches to a semi-quantitative mode after measurement of the blood flow [13]. Laser doppler has proven to be reliable in previous studies for pulp vitality evaluation and even to assess the healing process of bone lesion of the jaws [14,15]. This *in vivo* study demonstrated some of the several advantages laser speckle imaging has over conventional vitality test, making the new instrument more versatile in a clinical environment. However, previous Doppler flowmetry studies only recorded waves and data. Here, we report the first time, the use of laser doppler blood flow monitor and imager with a colored image to present pulp vitality information in the dental field.

Endodontic treatment of the invagination alone is advisable for maintaining the vitality of the main root canal pulp [16]. We report here a case of type IIIa DI in the right maxillary lateral incisor with a vital pulp, necrotic invagination, and a large peri-invagination lesion was managed successfully using a conservative approach. Electric pulp testing and laser doppler blood flow monitor and imager were used in combination to confirm the pulp vitality and provide relevant clinical evidence for the subsequent treatment plan [17].

2. Case Report

A 31-year-old Taiwanese woman underwent orthodontic treatment in the hospital and the routine examination revealed a large peri-invagination lesion with a unique root canal shape in the upper right lateral incisor; therefore, she was referred to Endodontics and Operative Dentistry department of Kaohsiung Medical University Chung-Ho Memorial Hospital.

The patient had fair oral hygiene, with no systemic diseases, food or drug allergies, or history of dental trauma. Intraoral examination revealed normal soft tissues with no swelling or sinus tracts. Clinical imaging revealed a peg-shaped clinical crown with no caries or fillings. However, brackets and wires were present in the maxillary teeth with no tenderness or pain on percussion (Figure 1).

The tooth responded normally to thermal and electric pulp testing (Parkell pulp vitality tester, Farmingdale, NY, USA). Moreover, teeth 11 and 13 also showed normal responses to both thermal and electrical pulp testing. Tooth mobility was grade I. A 4-mm periodontal pocket was detected in the buccal area.

We can observe the radiolucent invagination from the periapical film (Figure 2a), which looks like a tooth is inside another. A radiopaque invagination of the dentin lined by the enamel could be observed in the crown. A "pseudo-canal" was located near the mesial side and extended from the enamel invagination to approximately the cemento-enamel junction, spreading and forming the opening of the pseudo canal, with a lesion at the mesial and lateral part of the root. Considering the irregular shape, root resorption in the "pseudo-canal" was suspected.

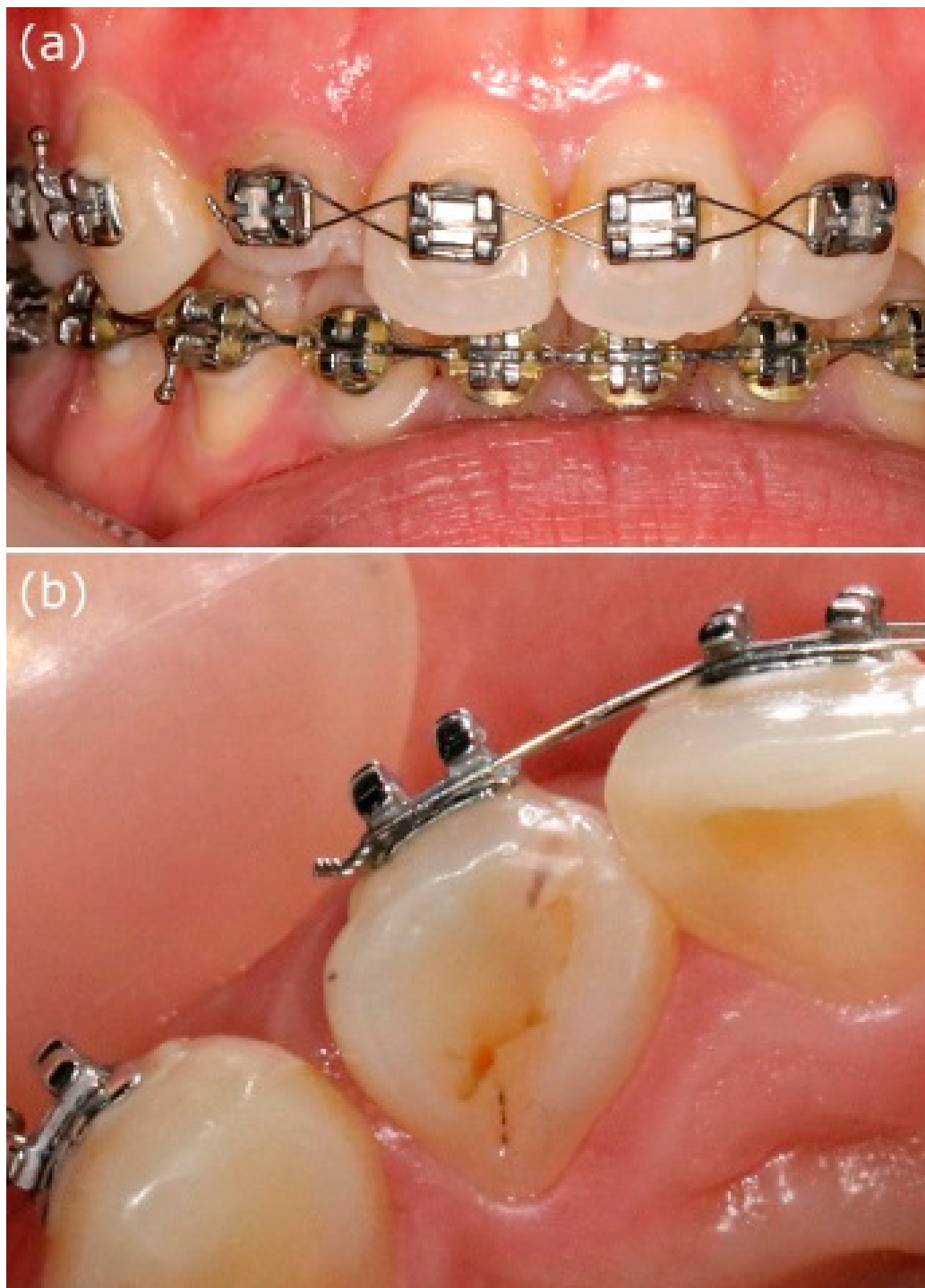


Figure 1. Clinical examination. (a) Intraoral examination of a 31-year-old woman showing normal soft tissue. (b) Incisal view of tooth 12 showing a Peg-shaped clinical crown.

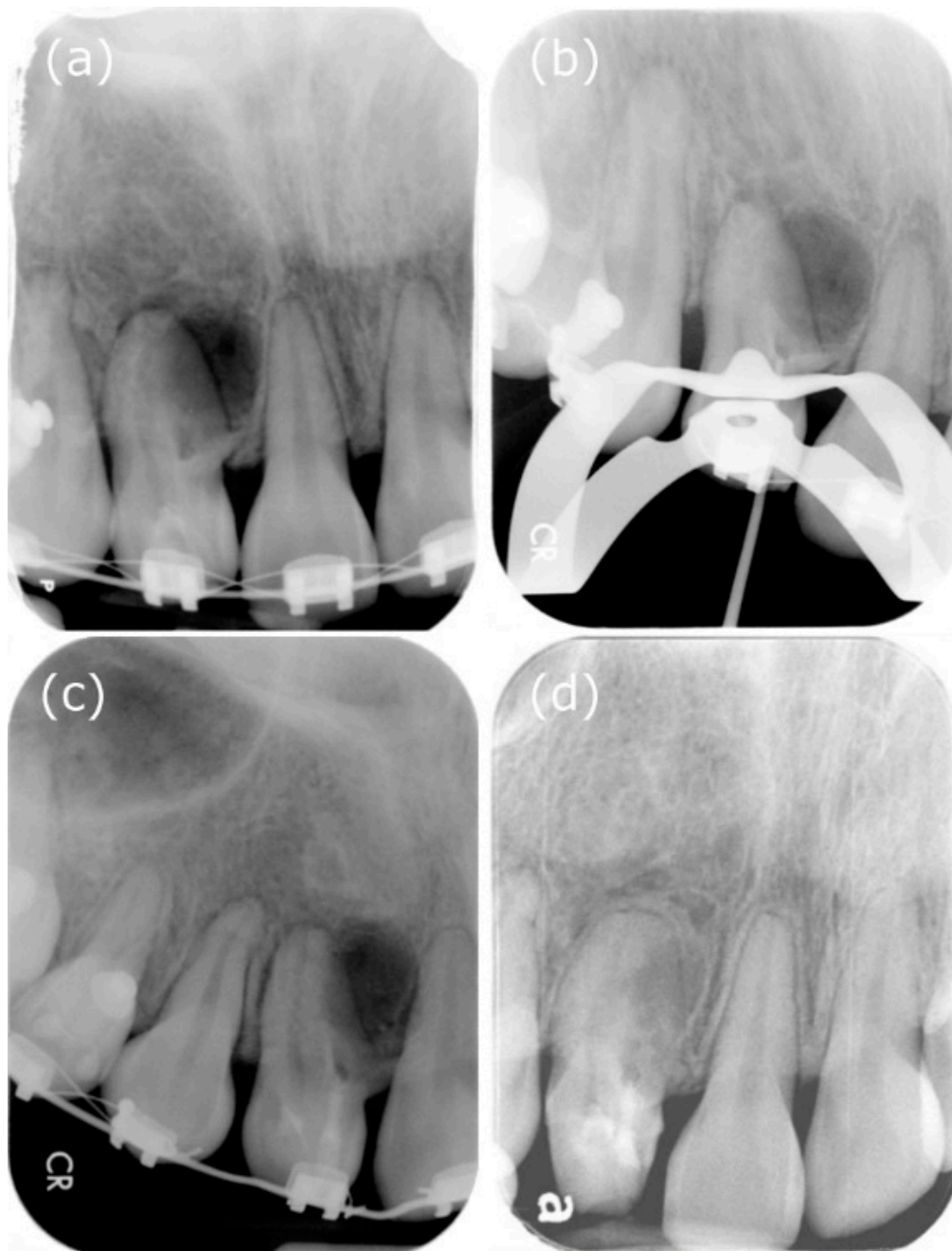


Figure 2. Periapical films during the treatment procedure. (a) X-ray showed that the radiolucent invagination looks like a tooth inside another. Additionally, there was dentin invagination lined by enamel into the main canal space, spreading into the mesial part of the middle root. Tooth 12 appeared to be associated with a large peri-invagination radiolucent lesion around the opening of the invagination near CDJ. (b) Measurement of the working length. (c) Mineral trioxide aggregate was used to seal the invagination. (d) Follow-up at two postoperative years. The patient complained of no clinical symptoms, and the peri-invagination lesion had healed significantly.

We decided to investigate further with CBCT because of the complex anatomy of tooth 12. As expected, the CBCT scan (EPX-Impla; E-Woo Technology, Yongin, Korea) revealed a type III invagination. We can observe from the CBCT coronal view that the pseudo canal was located near the buccal part, while the CBCT sagittal view showed that the buccal side of the pseudo canal with the opening of the invagination near the cemento-enamel junction, and it was adjacent with a well-defined unilocular peri-invagination radiolucent lesion measuring 8 mm (mesiodistal) × 9 mm (labiopallatal) × 12 mm (craniocaudal) (Figure 3).

Three-dimensional CBCT aided the diagnosis and provided additional information on the root canal during the treatment procedure. A diagnosis of Oehler's type III DI with necrotic invagination and asymptomatic peri-invagination periodontitis was made. We decided to proceed with the vital pulp therapy of the main canal, followed by nonsurgical endodontic treatment for the pseudo root canal, after discussing the treatment plans with the patient.

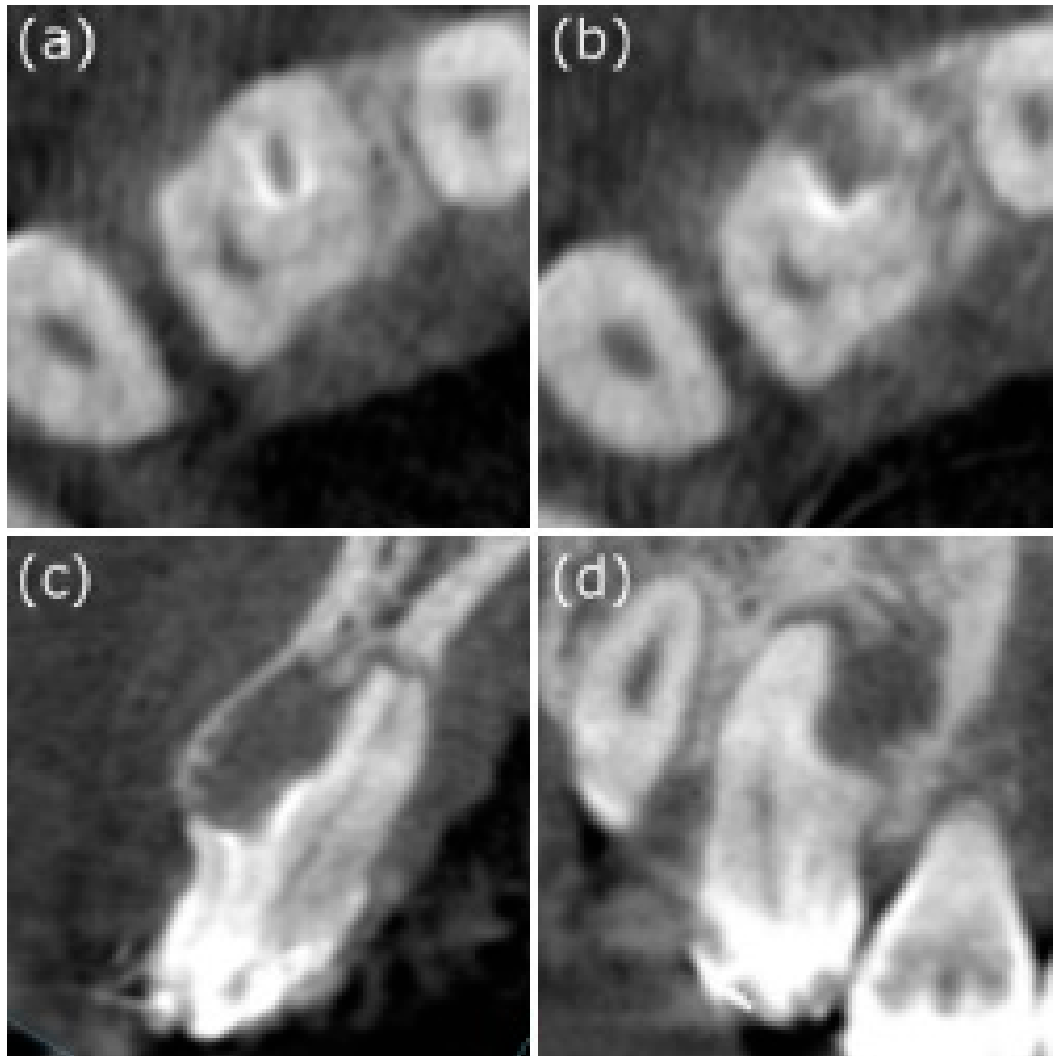


Figure 3. Different sections in cone-beam computed tomography. (a) From the axial view, “pseudo-canal” can be observed on the mesial side, surrounded by the enamel. (b) The opening of the invagination near CEJ can be seen in the “pseudo-canal”, in the middle-third of the root. (c) From the CBCT coronal view, we can observe that the pseudo canal was located near the core part. (d) The CBCT sagittal view showing that the buccal side of the pseudo canal with the opening of the invagination near the cemento-enamel junction, and it was adjacent with a well-defined unilocular peri-invagination radiolucent lesion with a size of 8 mm × 9 mm × 12 mm.

According to previous literature [10], the invagination is the usual site of origin of infection. The main canal is still vital with no other symptoms; therefore, follow-up was recommended. Regarding the pseudo canal, it was infected, and root canal therapy was advised. Due to the necrotic invagination, either apexification or revascularization can be selected. The dentin thickness was sufficient, and it had an open apex on the middle part; therefore, an operation will not be time-consuming. However, the material should be thick enough for sealing. MTA, which is more biocompatible, was applied as the filling to the pseudo canal.

In the first appointment, the access cavity of the invagination was carefully prepared after rubber dam isolation. A surgical operating microscope (OPMI® pico, Carl Zeiss, Oberkochen, Germany) was used to prevent damage to the main canal and for precision. Based on the information from CBCT images regarding the extent, position, and pulpal involvement of the invagination, the pseudo root canal of tooth 12 was located precisely (Figure 4a).

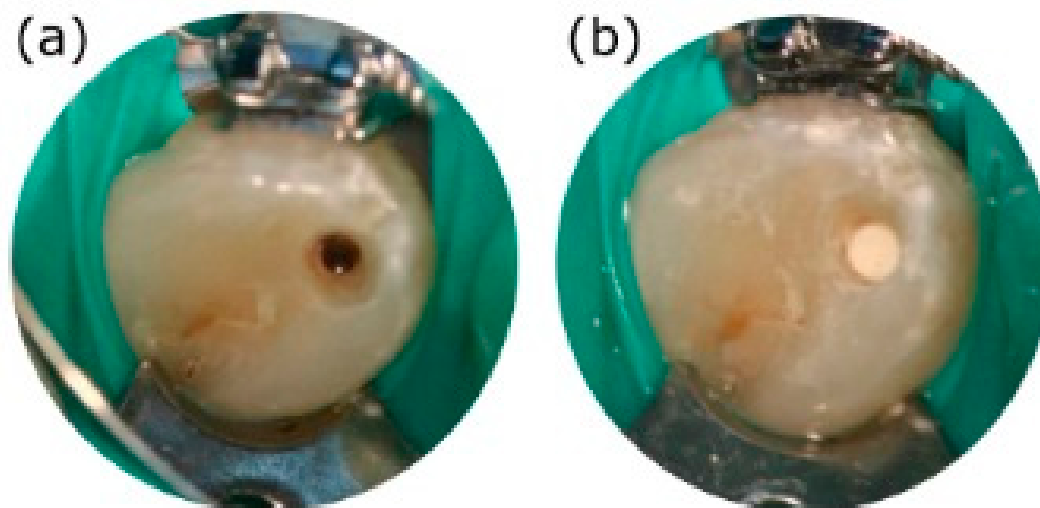


Figure 4. Microscopic photos during the treatment procedure. (a) The “pseudo-canal” was accurately located under the microscope at a magnification of X9.6 to avoid excessive dental tissue loss. (b) Dense mineral trioxide aggregate was filled-in after thorough debridement.

With the help of X-ray imaging and Root ZX mini apex locator (J. Morita Corp., Tokyo, Japan), a 13-mm working length was confirmed (Figure 2b). The pseudo-canal that appeared to be invaginated was instrumented with K-files up to a size 80 apical master file. During instrumentation, the “pseudo-canal” was immersed in 3% sodium hypochlorite solution and thoroughly rinsed between file changes. After removing the biofilm present on the root canal wall, calcium hydroxide was applied as the intracanal medication for chemical disinfection. Then, the entrance of the operated cavity was covered with 3-mm-thick Cavit (3M ESPE US, Norristown, PA, USA.) for 12 days.

At the second appointment, the patient returned for a follow-up completely asymptomatic. The temporary restorative materials were removed under rubber dam isolation. Sodium hypochlorite irrigation with a three percent concentration solution, ISO size 40 stainless steel hand files, and passive ultrasonic irrigation (Obtura Spartan, Algonquin, IL, USA) were used for removing the calcium hydroxide paste. After thorough rinsing, a microscopic examination was performed. The amount of residual calcium hydroxide was minimized to promote the subsequent mineral trioxide aggregate (MTA) sealing.

At this time, it was recommended that root canal filling be performed on the pseudo root canal because the infection had been controlled. In addition, follow-up was recommended because the main canal was still vital, without any symptoms. Furthermore, the pseudo canal was infected. Due to the necrotic invagination with an open apex, either apexification or revascularization can be selected, considering the opening on the cemento-enamel junction part of the root canal with a short working length. However, the material should be at least 3-mm, which is thick enough for sealing. Therefore, we chose MTA (Dentsply Tulsa Dental, Tulsa, OK, USA), which is more biocompatible as the filling for the invaginated canal (Figure 4b).

A final rinse was performed with normal saline. A sterilized paper needle was used to confirm that the “pseudo-canal” was dry, without exudation of liquid, followed by MTA preparation in accordance with the manufacturer’s instructions and recommendations.

MTA was applied in layers inside the “pseudo-canal” with proper squeezing and packing. A wet cotton ball was placed inside the root canal to accelerate material hardening. Subsequently, the root canal opening was sealed with Cavit. In the next visit, we restored the tooth with a composite resin (3M ESPE, St. Paul, MN, USA) (Figure 2c). The patient was asymptomatic when she came for followed up half month later.

During the 6-month postoperative follow-up period, the patient did not have any clinically significant pain or soft tissue swelling. According to the radiographic examination, the patient had improvements in the lesion and responded to EPT normally. In the deeper portion of the periodontal pocket, a flap surgery was performed by a periodontist to level the root.

However, the orthodontist was concerned that the significant size of the lesion around the root might affect root movement during the orthodontic treatment. In addition, according to the literature, a metal orthodontic gear attached to the tooth surface might cause false-positive results in traditional electric pulp testing, thereby leading to an inaccurate evaluation of the pulp vitality. Therefore, laser Doppler blood flow monitor and imager (MoorLDI-2λ) was scheduled for further assessment.

In the flux image, red color indicates the area with sufficient supply of blood. In other words, the red parts stand for vital pulp. Therefore, it is suggested that the three front teeth are vital. According to the perfusion unit's (PU) analysis of the laser Doppler, circle 1 refers to the red circle. Further, the statistics show that PU has no significant difference from the other two in the control group. It shows that the tooth is still vital and that regular follow-up could suffice (Figure 5). Since laser Doppler has successfully enhanced the diagnostic accuracy, unnecessary interventions can be avoided. At two years, the periapical area showed normal bone density (Figure 2d). Moreover, the tooth still responded normally to electric pulp testing. The PRICE 2020 flowchart showing the steps involved in the case report (Figure 6).

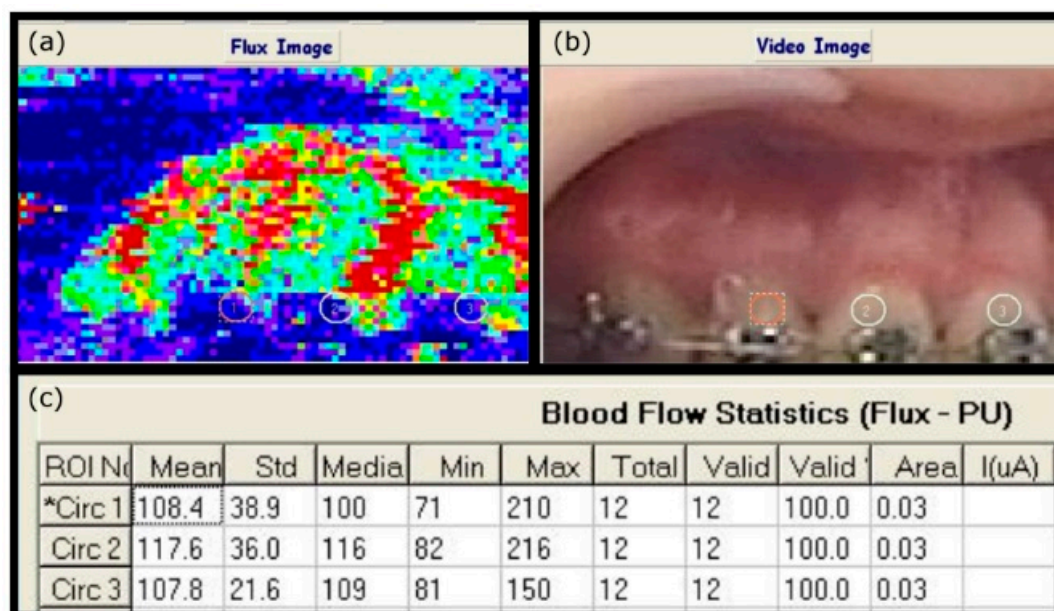


Figure 5. Laser Doppler to track the pulp vitality. (a) In the flux image, the red color represents areas of abundant blood flow, corresponding to the video image (b), in which the red circle shows the tooth to be measured. According to (c), PU analysis of laser Doppler revealed that circle 1 was the red circle (* means the circle 1 was selected as the reference). The calculated perfusion units in the diseased tooth were not significantly different from those in the two control teeth, indicating that the tooth remained viable. Continuous follow-up was recommended.

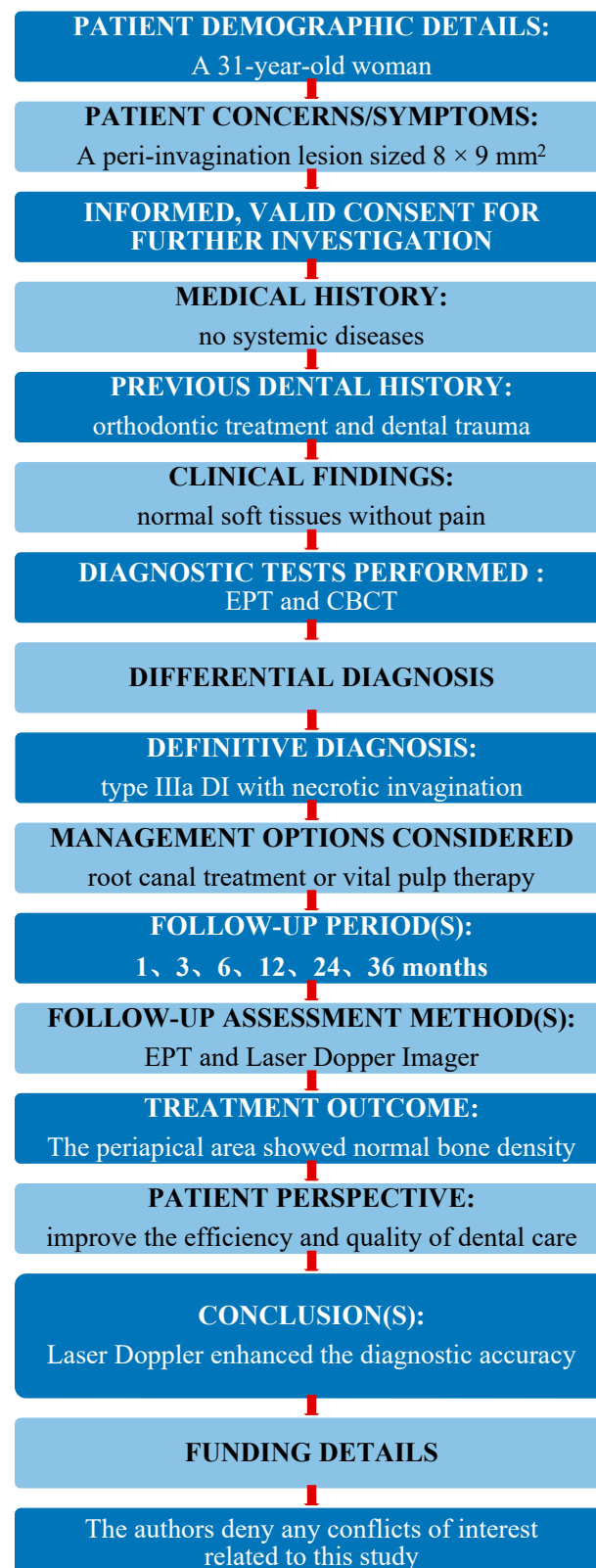


Figure 6. The PRICE 2020 flowchart showing the steps involved in the case report. From: Nagen-drababu V, Chong BS, McCabe P, Shah PK, Priya E, Jayaraman J, Pulikkotil SJ, Setzer FC, Sunde PT, Dummer PMH (2020) PRICE 2020 Guidelines for reporting case reports in Endodontics: A consensus-based development. International Endodontic Journal doi: 10.1111/iej.13285. For further details visit: <http://pride-endodonticguidelines.org/price/>.

3. Discussion

In a previous study, the pseudo canal was shown to be the usual site of origin of infection because the invagination acts as a region of stagnation for organic substances and provides a conducive environment for microbes [18]. The invagination of the enamel into the dental papilla results in a tunnel lined by dentin and enamel invaginating into the pulp [19].

In this case report, a necrotic invagination was debrided and filled, and the viable main root canal was followed-up [20]. However, as other major lesions were present, other dental specialists were consulted. A more accurate pulp diagnosis was required for the treatment plan [21,22].

In 1964, the red blood cell velocity evaluation method of collecting frequency-shift signals using optical measurements and switching to a semi-quantitative mode after the measurement of blood flow and volume was first adopted [14,23]. Doppler flowmetry has since been widely used to measure blood flow in soft tissues [24]. Since 1970, laser has been used in various clinical fields in Japan and Western countries. In the past decade, with advancements in medical laser devices, the use of lasers in the medical field has become more popular [25]. Laser Doppler mainly uses the Doppler effect to detect the pulp blood flow condition [26]. As a diagnostic technique for pulp disease, laser Doppler flowmetry (LDF) improves the accuracy of dental diagnosis, especially for traumatized and permanent teeth [27]. It reduces the diagnostic errors and improves the prognosis of the diseased teeth [9,28].

Laser Doppler is a non-invasive, objective, painless, semi-quantitative method, proven to be reliable and reproducible by numerous studies [29]. Laser is used to detect the pulp blood vessels in which the red blood cells scatter the light beams and cause Doppler shifts [13,30]. The objective data and imaging scans are presented. The calculated signals in the perfusion units represent the red blood cell density and velocity to evaluate the pulp vitality after trauma or pulp capping [29,31]. Different from previous Doppler flowmetry studies that only recorded waves and data, we report for the first time, the use of laser Doppler blood flow monitor and imager (MoorLDI-2λ) to evaluate the pulp vitality in the dental field.

As manufacturers have derived various high-end products from the standard models to satisfy applicability for medical research, this study adopted a new-generation laser Doppler blood flow monitor and imager (MoorLDI-2λ), which allows the observation of accurate images of low blood flow areas in the dental pulp under the slow scanning mode. It has higher sensitivity, wider dynamic range, and higher resolution compared with previous laser Doppler flowmetry (LDF). Through laser beam measurement, the mobile interference caused by traditional operators using the probe is reduced. It does not need to contact tissues, thus effectively avoiding infections and traumas to tissues. However, there are other limitations to the use of laser Doppler imager, such as the cost of the equipment and the interference by extraneous noise and movement near or in the apparatus itself.

Contrary to previous reports, we directly presented the pulp-colored image of the anterior teeth to observe the pulp condition in the main root canal. In combination with the objective data, the perfusion units in the diseased tooth did not differ from those in two control teeth, indicating that the main root canal remained viable. The pulp tissues, rich in blood and lymphatic vessels and nerves, connects to the circulation through the root apex [32]. They contain the necessary components of the peripheral immune system and the stem cells responsible for pulp tissue regeneration. They produce the dentin, maintain dental nutrition and esthetics, conduct pain sensation, and produce protective responses against external stimuli [33]. Maintaining the pulp vitality helps extend the life of the diseased tooth. Therefore, before the root canal therapy, pulp evaluation should be performed based on the patient's medical history, clinical symptoms, intraoral examination results, and imaging data. When necessary, both laser Doppler and laser Doppler blood flow monitor and imager can be used to monitor the pulp blood flow and evaluate the

pulp condition to improve the diagnostic accuracy [34], thereby providing relevant clinical evidence for the treatment plan.

4. Conclusions

Although the internal structural complexity of DI makes the root canal treatment difficult, with the development of minimally invasive procedures, laser Doppler have successfully enhanced the diagnostic accuracy, accompanied by modern devices and intracanal medication for debridement and a sealing material of good biocompatibility to preserve the healthy pulp tissues. Thus, unnecessary interventions can be avoided while reducing the treatment time and extending the life of the diseased teeth by preserving the vitality, thereby improving the efficiency and quality of dental care. The factor and motion artifact noise of the laser Doppler technique motivate ongoing research, and further work is needed to resolve the limitations.

Author Contributions: All authors made substantial contributions to present study. H.-N.L. and F.-H.C. designed the study. H.-N.L. and C.-Y.H. analyzed and interpreted the patient data regarding the disease. S.-C.C. and C.-Y.P. performed the examination of the teeth. J.-H.J. and Y.-K.C. reviewed and editing the original draft preparation. H.-N.L., D.-Y.Y., and F.-H.C. was a major contributor in writing the manuscript. All authors have read and agreed to the published version of the manuscript.

Funding: This research received no external funding.

Institutional Review Board Statement: The study was conducted according to the guidelines of the Declaration of Helsinki, and approved by the Institutional Review Board of Kaohsiung Medical University Hospital (KMUHIRB-E(II)-20180018).

Informed Consent Statement: Written informed consent has been obtained from the patient to publish this paper.

Data Availability Statement: The data presented in this study are available on request from the corresponding author within the framework of a scientific cooperation.

Acknowledgments: The authors would like to thank Ying-Chun Lin assistant research fellow of Department of Dentistry, Kaohsiung Medical University Hospital for editing assistance.

Conflicts of Interest: The authors declare no conflict of interest.

References

1. Alani, A.; Bishop, K. Dens invaginatus. Part 1: Classification, prevalence and aetiology. *Int. Endod. J.* **2008**, *41*, 1123–1136. [\[CrossRef\]](#)
2. Agrawal, P.K.; Wankhade, J.; Warhadpande, M. A Rare Case of Type III Dens Invaginatus in a Mandibular Second Premolar and Its Nonsurgical Endodontic Management by Using Cone-beam Computed Tomography: A Case Report. *J. Endod.* **2016**, *42*, 669–672. [\[CrossRef\]](#)
3. Capar, I.D.; Ertas, H.; Arslan, H.; Tarim Ertas, E. A retrospective comparative study of cone-beam computed tomography versus rendered panoramic images in identifying the presence, types, and characteristics of dens invaginatus in a Turkish population. *J. Endod.* **2015**, *41*, 473–478. [\[CrossRef\]](#)
4. Liu, J.; Que, K.H.; Xiao, Z.H.; Wen, W. Endodontic management of the maxillary first molars with two root canals: A case report and review of the literature. *World J. Clin. Cases.* **2019**, *7*, 79–88. [\[CrossRef\]](#)
5. Altuntas, A.; Cinar, C.; Akal, N. Endodontic treatment of immature maxillary lateral incisor with two canals: Type 3 dens invaginatus. *Oral Surg. Oral Med. Oral Pathol. Oral Radiol. Endod.* **2010**, *110*, e90–e93. [\[CrossRef\]](#)
6. Brooks, J.K.; Ribera, M.J. Successful nonsurgical endodontic outcome of a severely affected permanent maxillary canine with dens invaginatus Oehlers type 3. *J. Endod.* **2014**, *40*, 1702–1707. [\[CrossRef\]](#)
7. Keles, A.; Cakici, F. Endodontic treatment of a maxillary lateral incisor with vital pulp, periradicular lesion and type III dens invaginatus: A case report. *Int. Endod. J.* **2010**, *43*, 608–614. [\[CrossRef\]](#) [\[PubMed\]](#)
8. Kfir, A.; Telishevsky-Strauss, Y.; Leitner, A.; Metzger, Z. The diagnosis and conservative treatment of a complex type 3 dens invaginatus using cone beam computed tomography (CBCT) and 3D plastic models. *Int. Endod. J.* **2013**, *46*, 275–288. [\[CrossRef\]](#) [\[PubMed\]](#)
9. Ghouth, N.; Duggal, M.S.; BaniHani, A.; Nazzal, H. The diagnostic accuracy of laser Doppler flowmetry in assessing pulp blood flow in permanent teeth: A systematic review. *Dent. Traumatol.* **2018**, *34*, 311–319. [\[CrossRef\]](#)
10. Brignardello-Petersen, R. Laser Doppler flowmetry and pulse oximetry seem to have high accuracy in detecting vital and nonvital teeth and perform better than cold, heat, and electric pulp testing. *J. Am. Dent. Assoc.* **2018**, *149*, e152. [\[CrossRef\]](#) [\[PubMed\]](#)

11. Civjan, S.; Barone, J.J.; Vaccaro, G.J. Electric pulp vitality testers. *J. Dent. Res.* **1973**, *52*, 120–126. [[CrossRef](#)]
12. Karayilmaz, H.; Kirzioglu, Z. Comparison of the reliability of laser Doppler flowmetry, pulse oximetry and electric pulp tester in assessing the pulp vitality of human teeth. *J. Oral. Rehabil.* **2011**, *38*, 340–347. [[CrossRef](#)] [[PubMed](#)]
13. Olgart, L.; Gazelius, B.; Lindh-Stromberg, U. Laser Doppler flowmetry in assessing vitality in luxated permanent teeth. *Int. Endod. J.* **1988**, *21*, 300–306. [[CrossRef](#)]
14. Ahn, S.Y.; Kim, D.; Park, S.H. Long-term Prognosis of Pulpal Status of Traumatized Teeth Exhibiting Contradictory Results between Pulp Sensibility Test and Ultrasound Doppler Flowmetry: A Retrospective Study. *J. Endod.* **2018**, *44*, 395–404. [[CrossRef](#)]
15. Musu, D.; Shemesh, H.; Boccuzzi, M.; Dettori, C.; Cotti, E. Correction to: The effectiveness of ultrasound examination to assess the healing process of bone lesions of the jaws: A systematic review. *Clin. Oral Investig.* **2020**, *24*, 3739–3747. [[CrossRef](#)]
16. Lee, J.K.; Hwang, J.J.; Kim, H.C. Treatment of peri-invagination lesion and vitality preservation in an immature type III dens invaginatus: A case report. *BMC Oral Health* **2020**, *20*, 29. [[CrossRef](#)] [[PubMed](#)]
17. Gazelius, B.; Lindh-Stromberg, U.; Pettersson, H.; Oberg, P.A. Laser Doppler technique—A future diagnostic tool for tooth pulp vitality. *Int. Endod. J.* **1993**, *26*, 8–9. [[CrossRef](#)] [[PubMed](#)]
18. Nosrat, A.; Schneider, S.C. Endodontic Management of a Maxillary Lateral Incisor with 4 Root Canals and a Dens Invaginatus Tract. *J. Endod.* **2015**, *41*, 1167–1171. [[CrossRef](#)]
19. Teixido, M.; Abella, F.; Duran-Sindreu, F.; Moscoso, S.; Roig, M. The use of cone-beam computed tomography in the preservation of pulp vitality in a maxillary canine with type 3 dens invaginatus and an associated periradicular lesion. *J. Endod.* **2014**, *40*, 1501–1504. [[CrossRef](#)] [[PubMed](#)]
20. Vier-Pelisser, F.V.; Pelisser, A.; Recuero, L.C.; So, M.V.; Borba, M.G.; Figueiredo, J.A. Use of cone beam computed tomography in the diagnosis, planning and follow up of a type III dens invaginatus case. *Int. Endod. J.* **2012**, *45*, 198–208. [[CrossRef](#)]
21. Yang, J.; Zhao, Y.; Qin, M.; Ge, L. Pulp revascularization of immature dens invaginatus with periapical periodontitis. *J. Endod.* **2013**, *39*, 288–292. [[CrossRef](#)]
22. Zoya, A.; Ali, S.; Alam, S.; Tewari, R.K.; Mishra, S.K.; Kumar, A.; Andrabi, S.M.-U.-N. Double Dens Invaginatus with Multiple Canals in a Maxillary Central Incisor: Retreatment and Managing Complications. *J. Endod.* **2015**, *41*, 1927–1932. [[CrossRef](#)]
23. Ersahan, S.; Sabuncuoglu, F.A.; Oktay, E.A. The Efficacy of Laser Doppler Flowmetry, Electric Pulp Test and Cold Test in Diagnosing Revascularization of Extrusively Luxated Immature Maxillary Incisors. *Pak. J. Med. Sci.* **2018**, *34*, 787–793. [[CrossRef](#)]
24. Evans, D.; Reid, J.; Strang, R.; Stirrups, D. A comparison of laser Doppler flowmetry with other methods of assessing the vitality of traumatised anterior teeth. *Endod. Dent. Traumatol.* **1999**, *15*, 284–290. [[CrossRef](#)]
25. Firestone, A.R.; Wheatley, A.M.; Thuer, U.W. Measurement of blood perfusion in the dental pulp with laser Doppler flowmetry. *Int. J. Microcirc. Clin. Exp.* **1997**, *17*, 298–304. [[CrossRef](#)]
26. Gazelius, B.; Olgart, L.; Edwall, B. Restored vitality in luxated teeth assessed by laser Doppler flowmeter. *Endod. Dent. Traumatol.* **1988**, *4*, 265–268. [[CrossRef](#)] [[PubMed](#)]
27. Liao, Q.; Ye, W.; Yue, J.; Zhao, X.; Zhang, L.; Zhang, L.; Huang, D.; Zheng, Q. Self-repaired Process of a Traumatized Maxillary Central Incisor with Pulp Infarct after Horizontal Root Fracture Monitored by Laser Doppler Flowmetry Combined with Tissue Oxygen Monitor. *J. Endod.* **2017**, *43*, 1218–1222. [[CrossRef](#)]
28. Ingolfsson, A.R.; Tronstad, L.; Hersh, E.V.; Riva, C.E. Efficacy of laser Doppler flowmetry in determining pulp vitality of human teeth. *Endod. Dent. Traumatol.* **1994**, *10*, 83–87. [[CrossRef](#)] [[PubMed](#)]
29. Ingolfsson, A.E.; Tronstad, L.; Riva, C.E. Reliability of laser Doppler flowmetry in testing vitality of human teeth. *Endod. Dent. Traumatol.* **1994**, *10*, 185–187. [[CrossRef](#)]
30. Roy, E.; Alliot-Licht, B.; Dajeau-Trudaud, S.; Fraysse, C.; Jean, A.; Armengol, V. Evaluation of the ability of laser Doppler flowmetry for the assessment of pulp vitality in general dental practice. *Oral Surg. Oral Med. Oral Pathol. Oral Radiol. Endod.* **2008**, *106*, 615–620. [[CrossRef](#)] [[PubMed](#)]
31. Kim, D.; Park, S.H. Effects of age, sex, and blood pressure on the blood flow velocity in dental pulp measured by Doppler ultrasound technique. *Microcirculation* **2016**, *23*, 523–529. [[CrossRef](#)] [[PubMed](#)]
32. Raab, W.H.; Reithmayer, K.; Grund, P. Vitality tests of the tooth pulp using laser Doppler flowmetry. *Dtsch. Zahnarztl. Z.* **1990**, *45*, 725–727. [[PubMed](#)]
33. Musselwhite, J.M.; Klitzman, B.; Maixner, W.; Burkes, E.J.J. Laser Doppler flowmetry: A clinical test of pulpal vitality. *Oral Surg. Oral Med. Oral Pathol. Oral Radiol. Endod.* **1997**, *84*, 411–419. [[CrossRef](#)]
34. Winzap-Kalin, C.; Chappuis, V.; von Arx, T. Laser Doppler flowmetry for vitality testing of traumatized maxillary incisors. *Schweiz. Monatsschr. Zahnmed.* **2005**, *115*, 12–17. [[PubMed](#)]