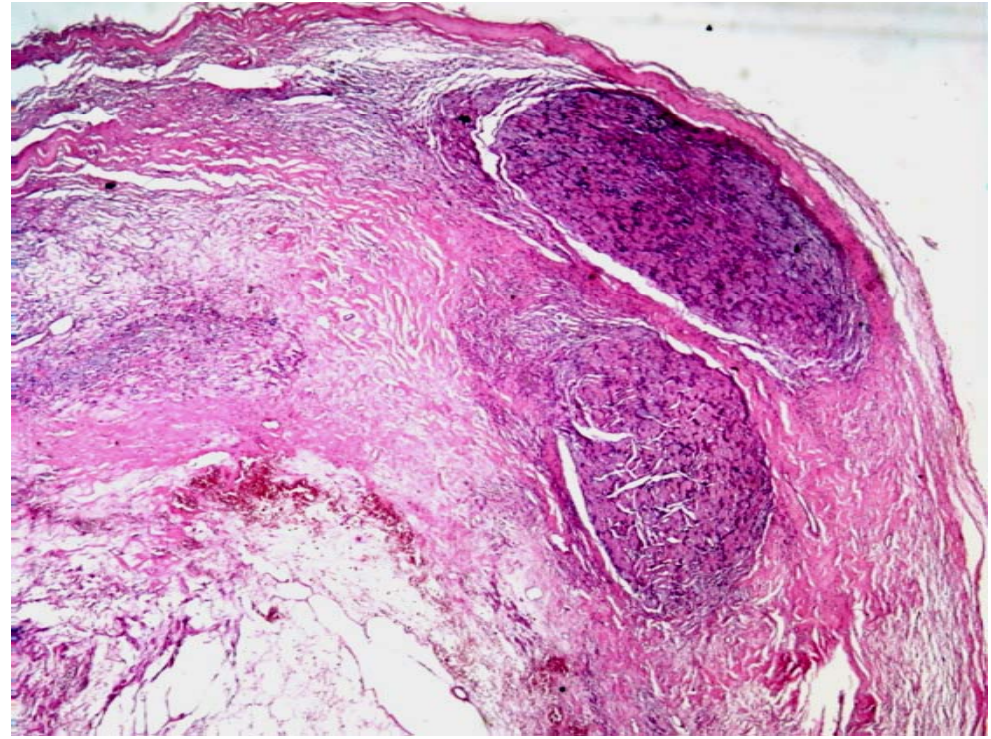
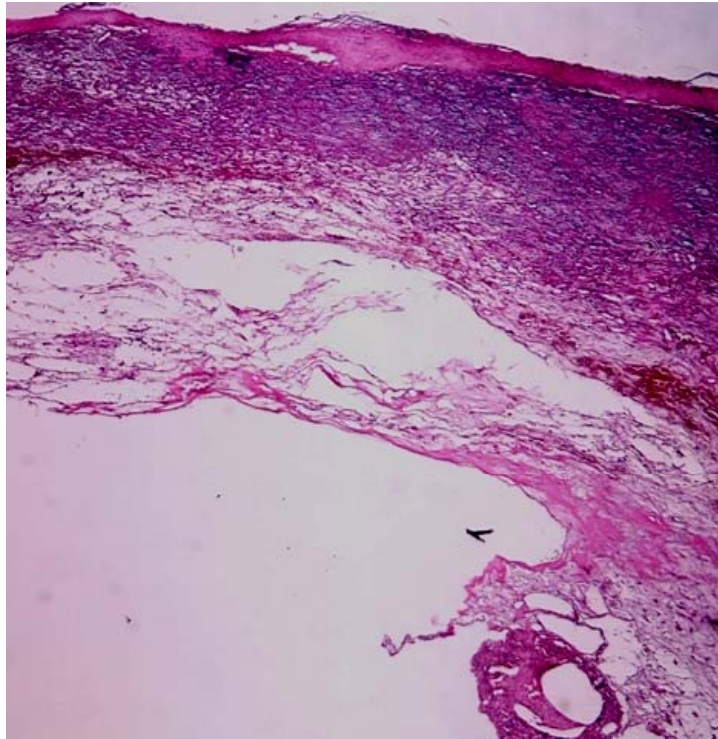


Case 3

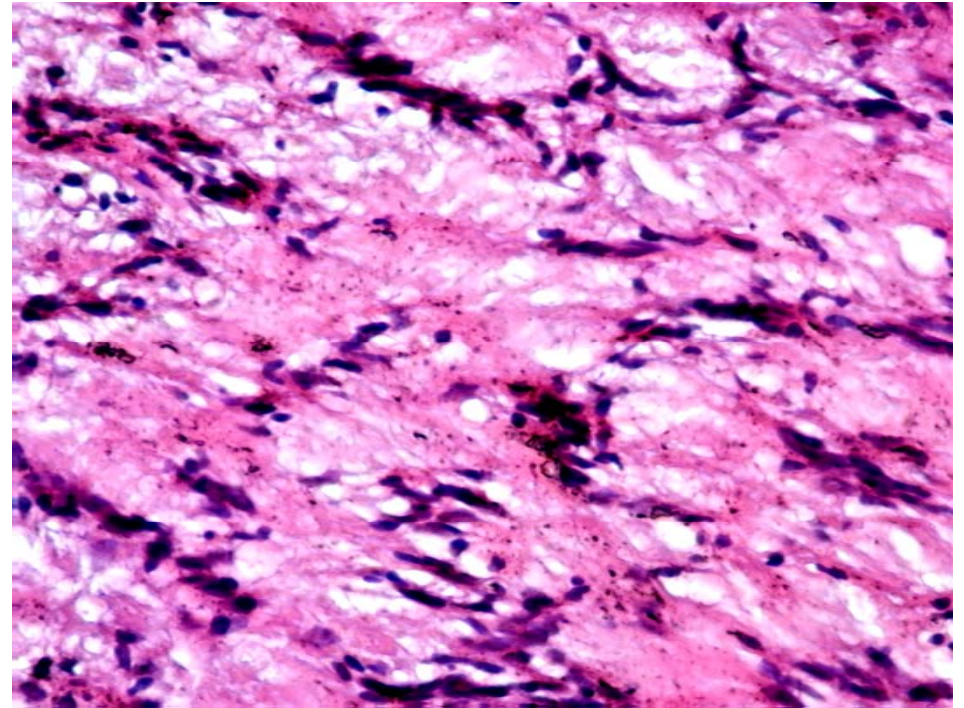
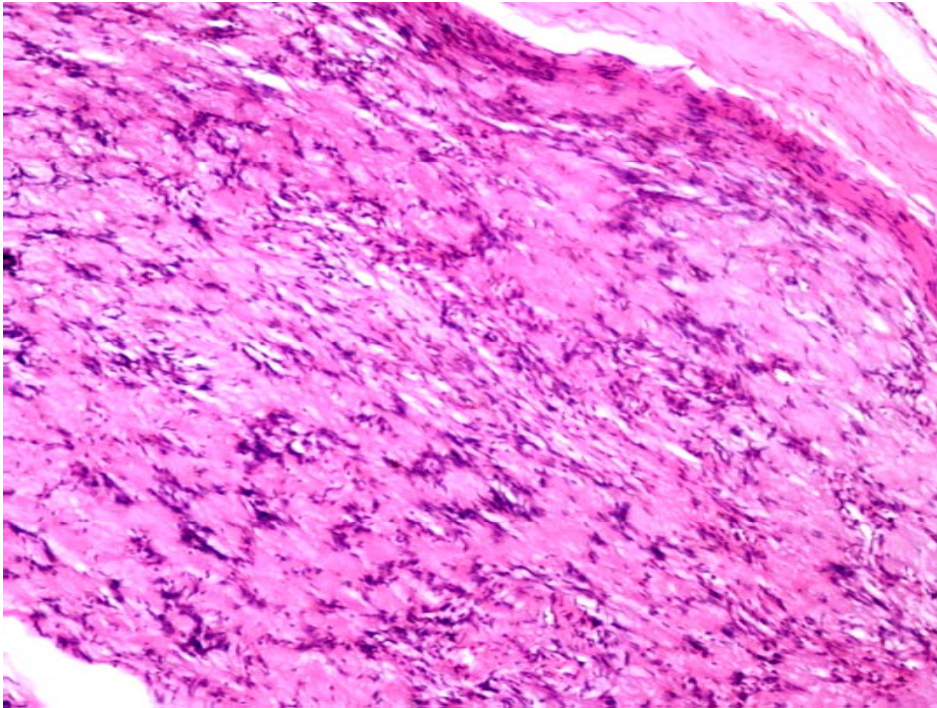
Microscopic Examination– 1

A well-encapsulated mass consisting of two tumor nests, myxoid tissue, fibrous tissue, hemorrhage, and cystic degeneration.

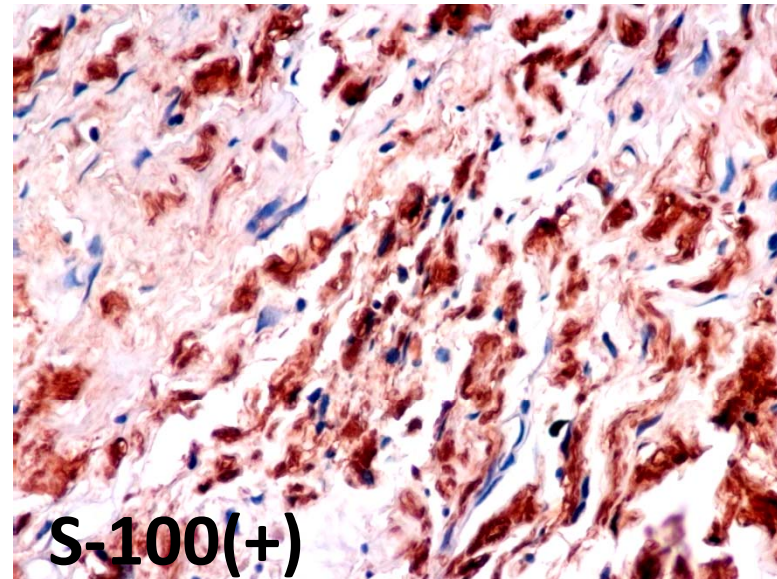
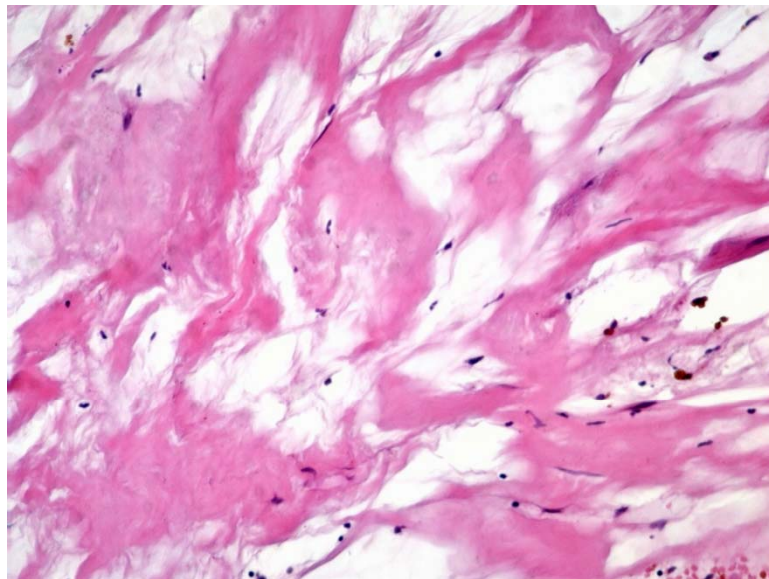
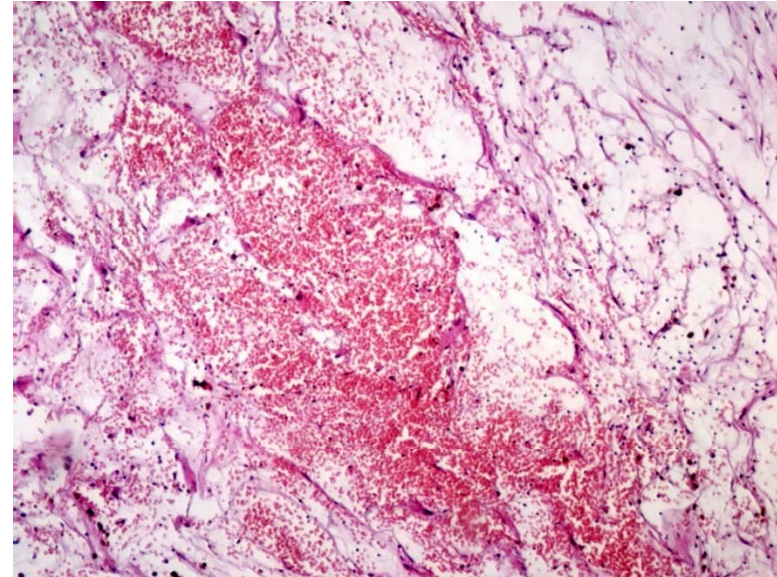
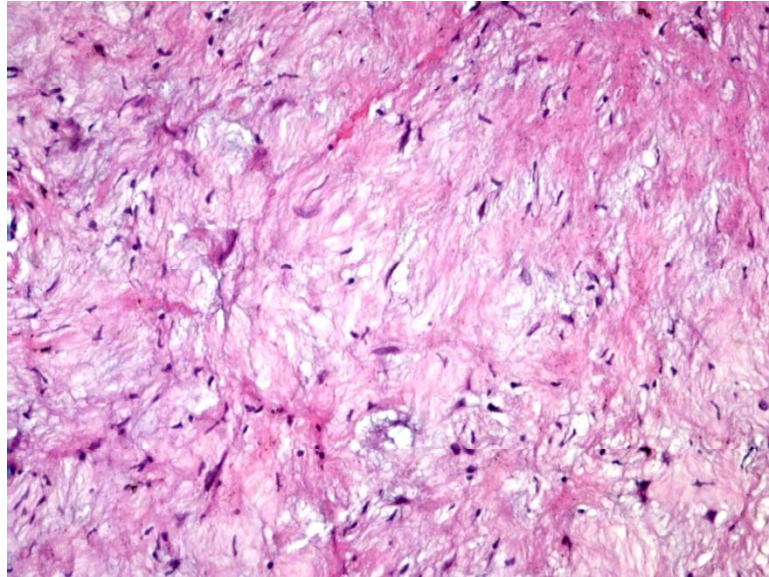


Microscopic Examination– 2

Antoni A – palisading nuclei and Verocay bodies



Microscopic Examination– 3



Final Diagnosis

- **Ancient schwannoma**

Oral cavity, Mouth floor, Right, Excision