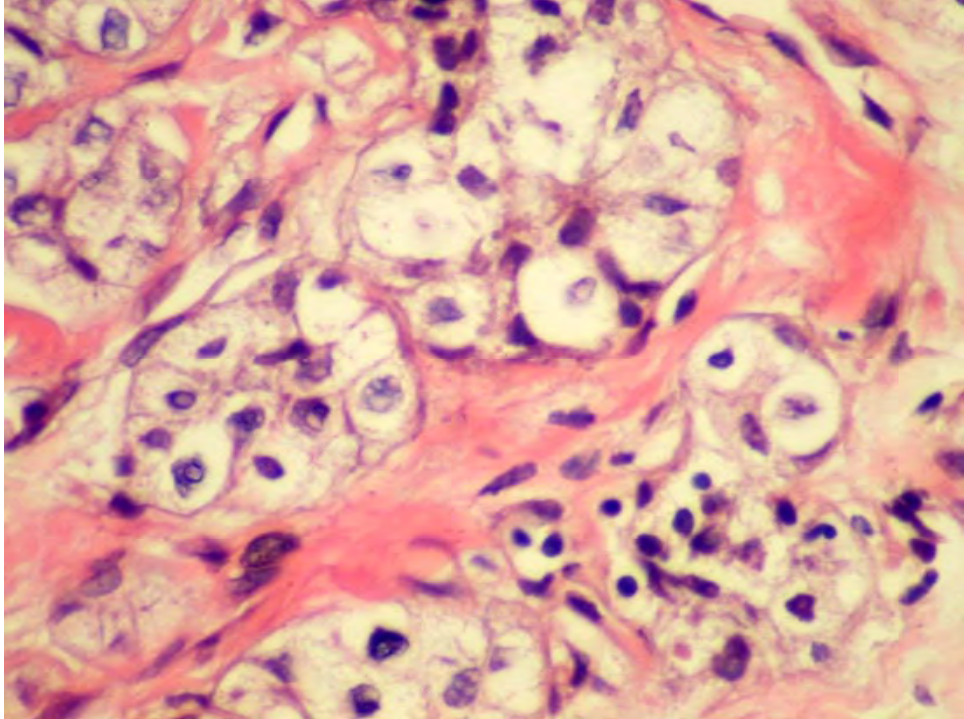
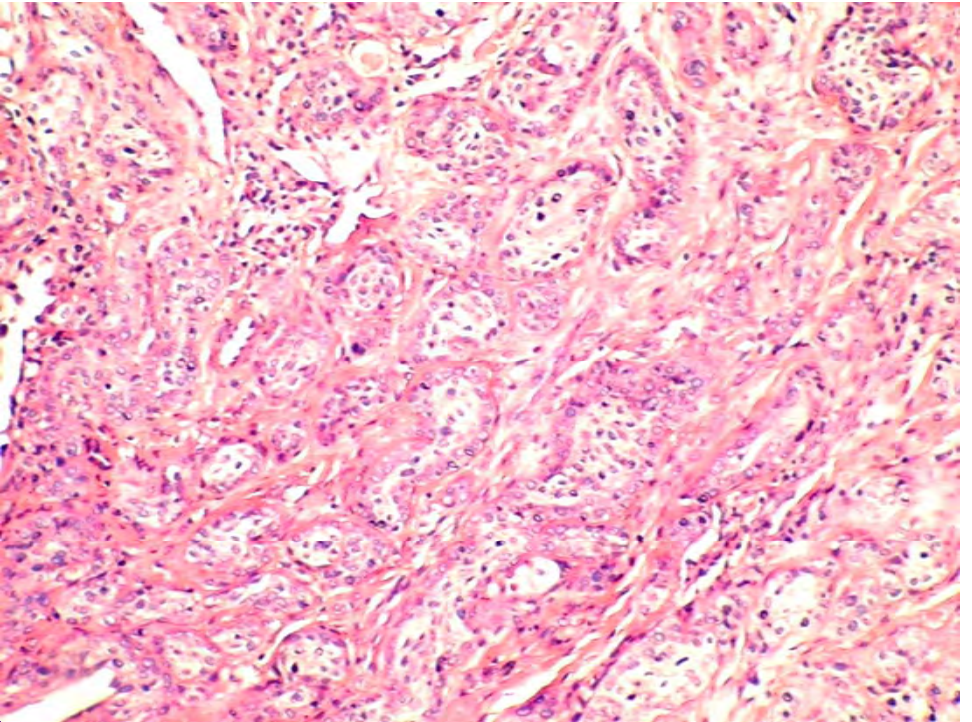
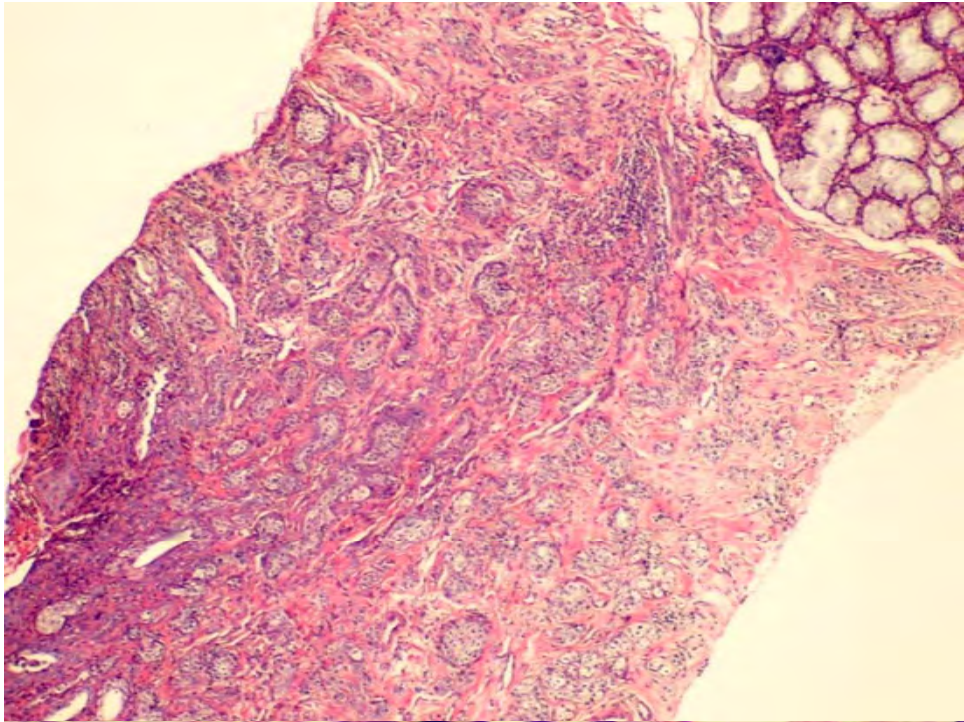
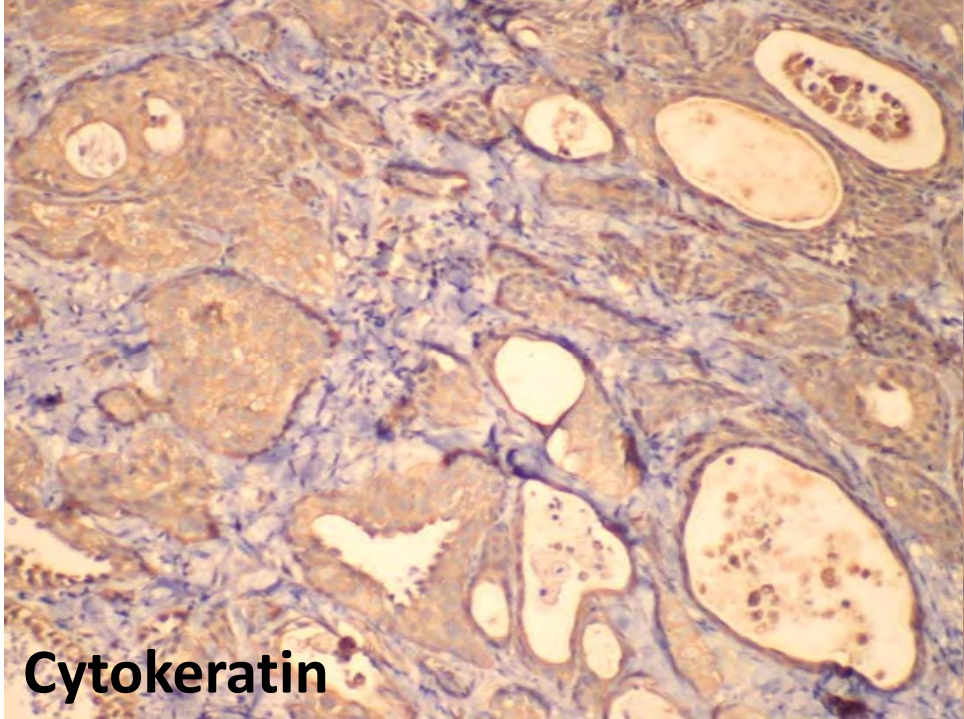
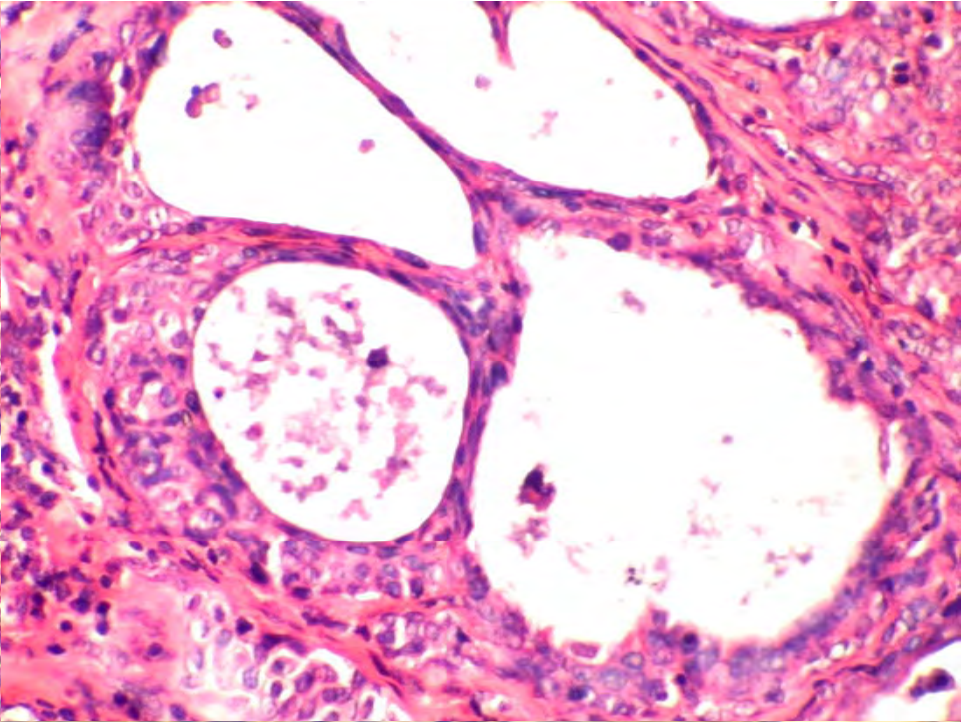
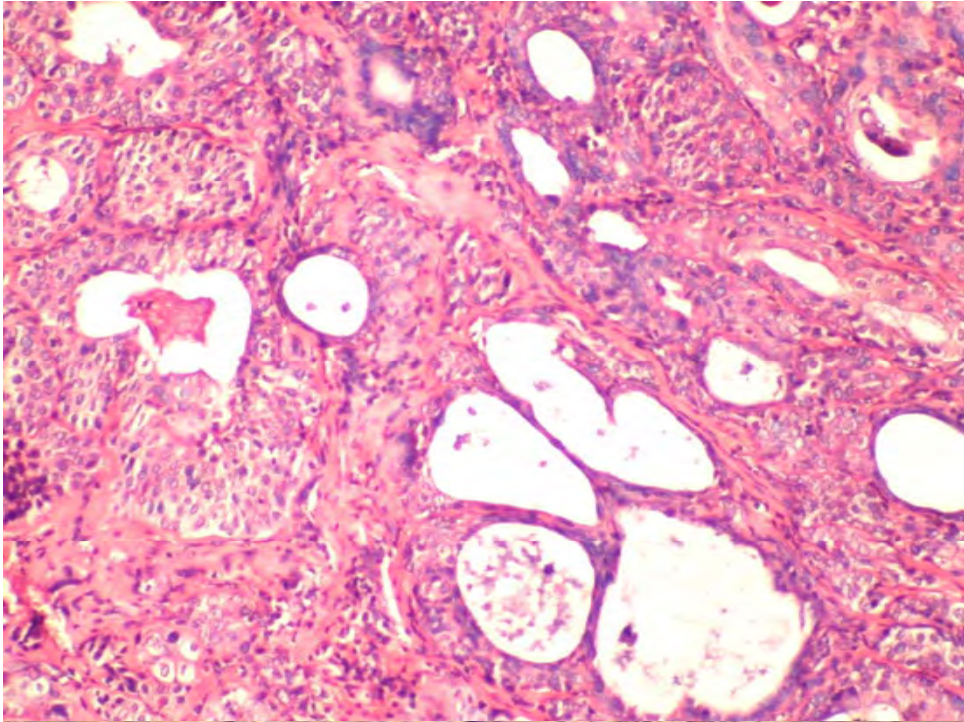
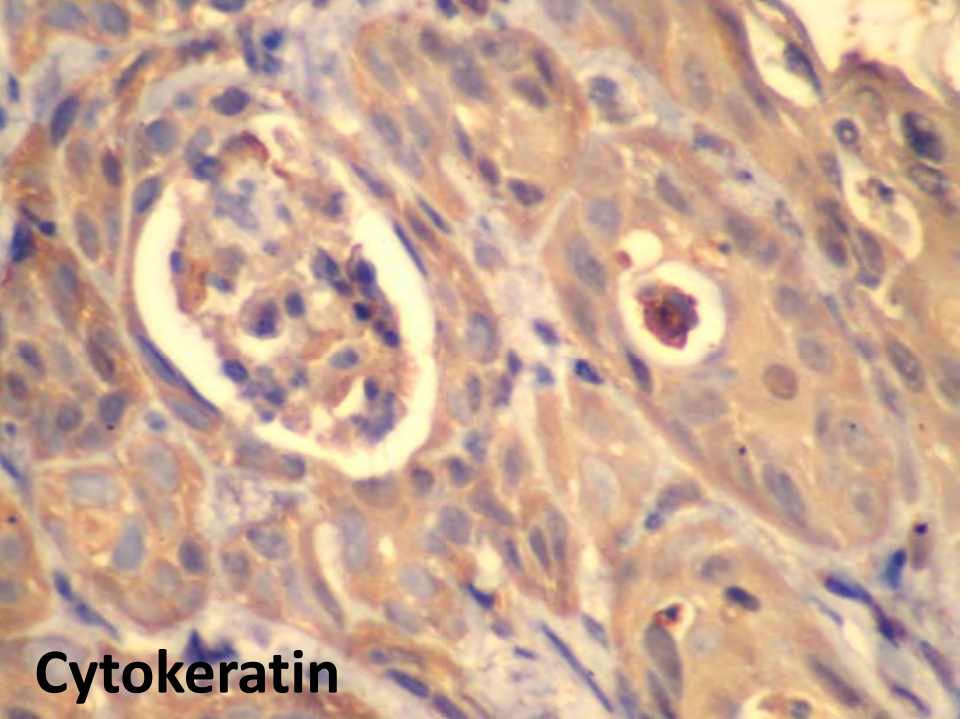


Case 1

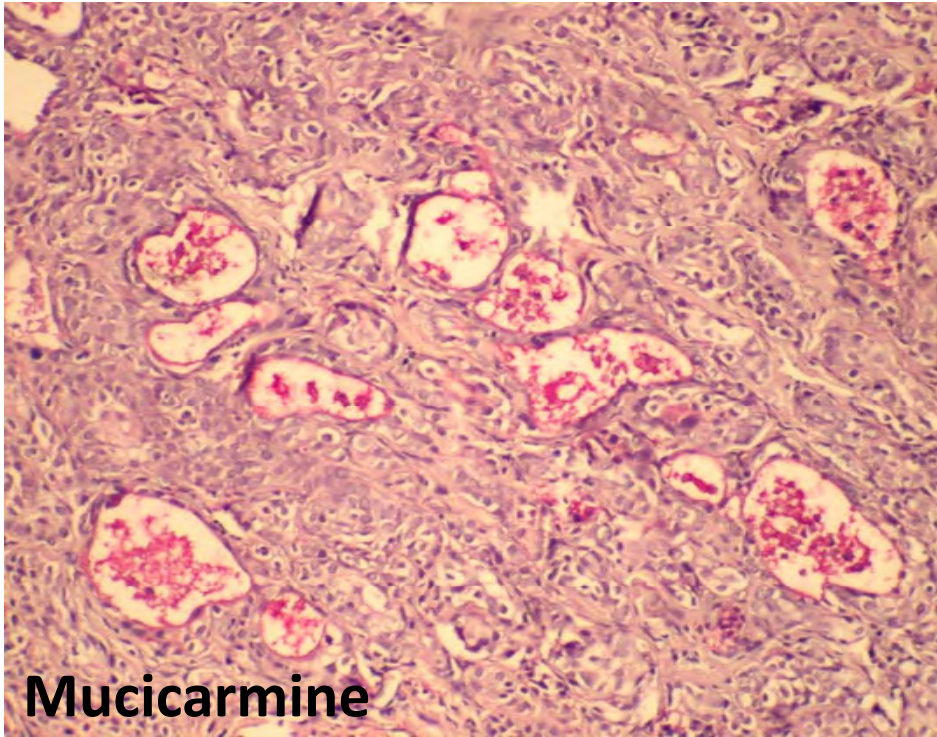




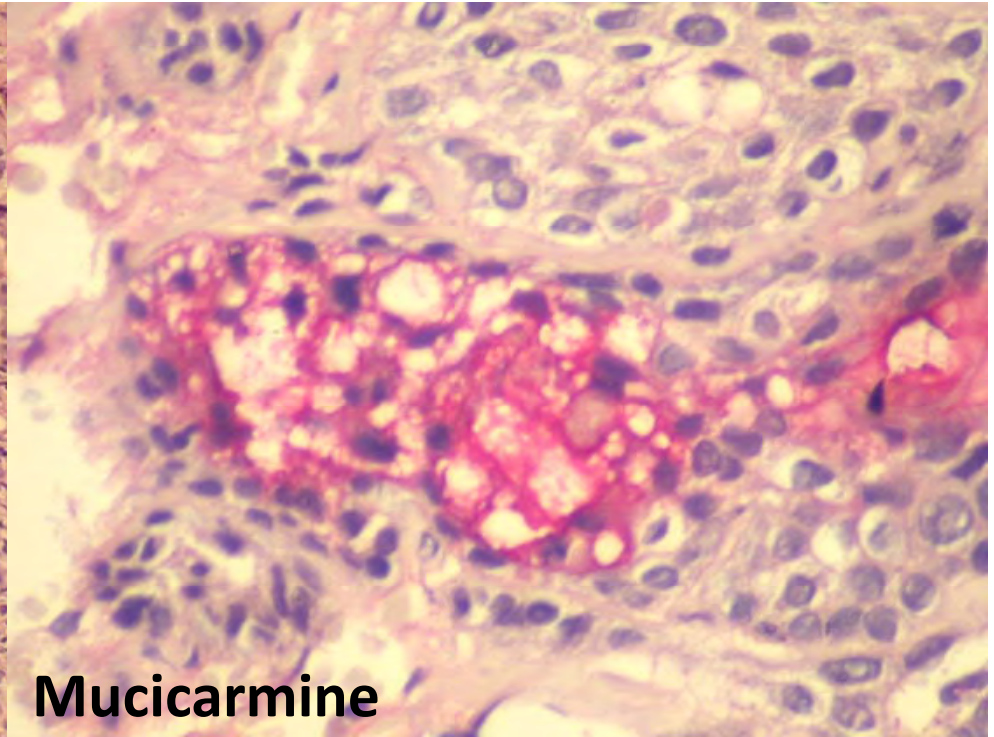
Cytokeratin



Cytokeratin



Mucicarmine



Mucicarmine

Histopathological Report

- **Mucoepidermoid carcinoma, high grade**
Oral cavity, mouth floor, right, incision