

口診SEMINAR第三組

指導老師：王文岑醫師 & 陳玉昆醫師

組員：9402015 張嘉倫
9402050 周煥琄
9402074 柳 琪
9402077 馬兆逸
9402092 陳歆如

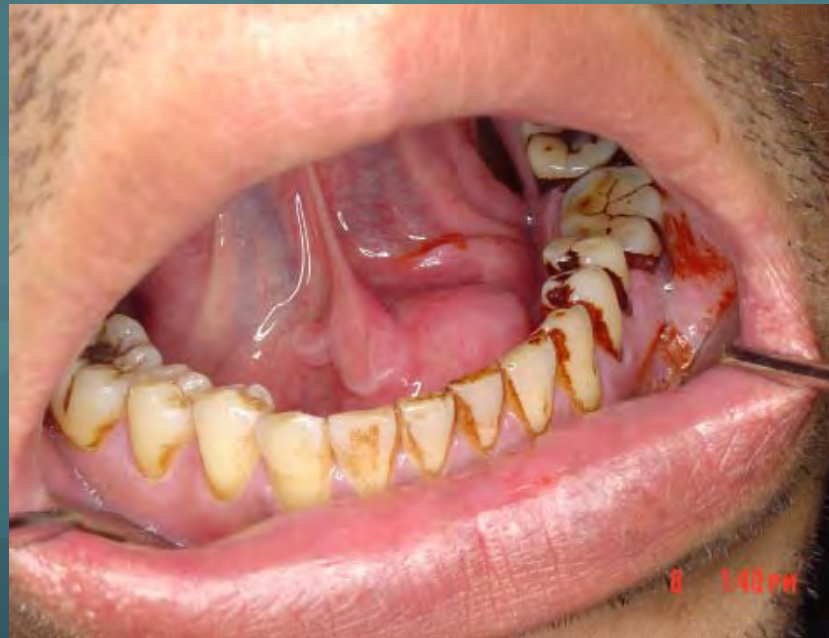9402016 謝佩妤
9402073 蕭立彥
9402076 曾智皇
9402091 黃郁舒
9323055 連勻嘉

Personal Data

- Name : XXX
- Gender : male
- Age : 34 y/o
- Occupation : 工
- Marital status : 已婚

Chief Complaint

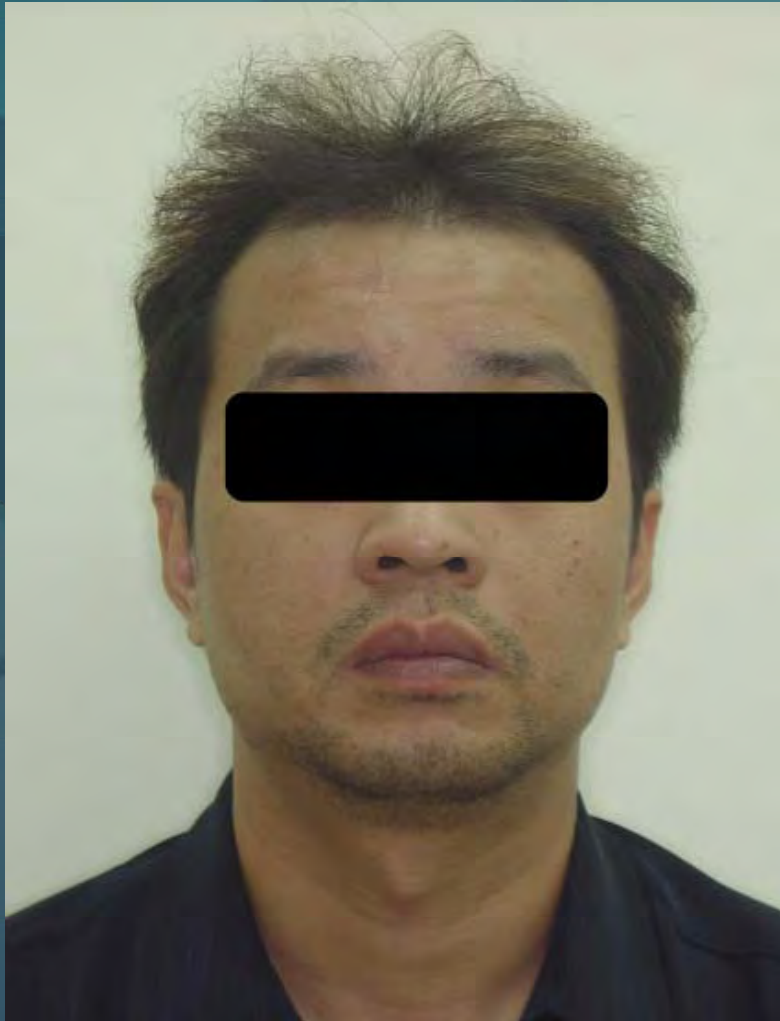- A swelling mass over anterior left mouth floor for more than one decade.



Present Illness

- This 34 years old male found a swelling mass over anterior left mouth floor when he was a senior high school student.
- No obvious change or disturbance is noted.
- He came to our OPD for treatment.

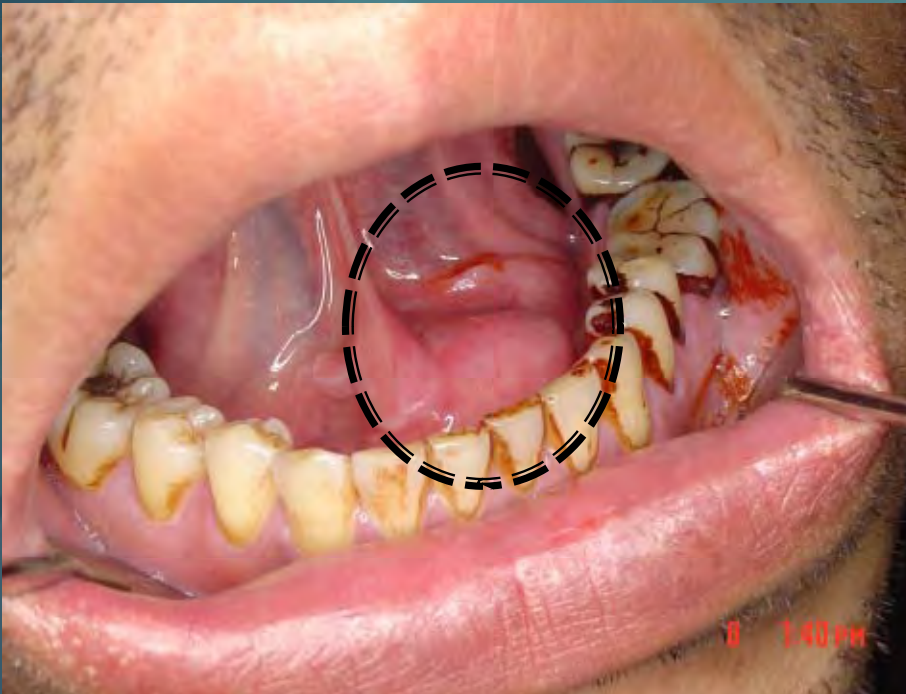
Extraoral examination



- nothing particular
- lymphadenopathy (-)

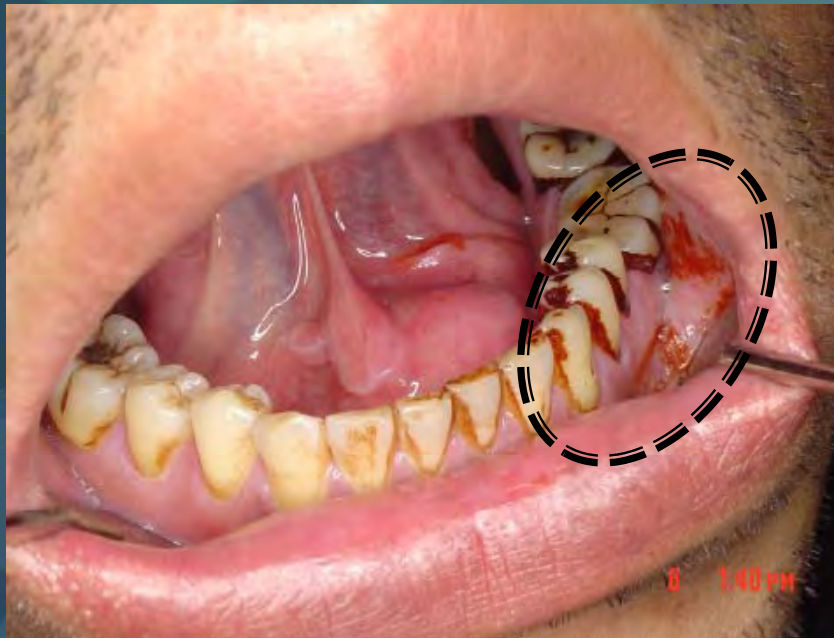
Intraoral examination(1)

- An exophytic mass over the anterior left mouth floor



- 2 x2 cm swelling
- smooth surface
- sessile base
- dome-shaped
- pink color
- soft texture
- no fluctuation
- fixed
- pain(-)
- tenderness (-)
- induration (-)

Intraoral examination(2)



- Plaque or calculous deposition
- Generalized teeth attrition
- Generalized gingival swelling
- Betel nut chewer's mucosa

Past history

- Past Medical History
 1. Denied any drug or food allergy
 2. Denied any systemic disease
 3. Hospitalization : appendicitis
- Past Dental History : unknown

Personal habits

- –Alcohol : (+), ≥ 10 years, persisted
- –Betel quid : (+), ≥ 10 years, persisted
- –Cigarette : (+), ≥ 10 years, persisted
- Other special habits : denied

Laboratory test

- No associated data
→ **Unknown**

Biopsy

- No associated data
→ **Unknown**

Cyst, inflammation or neoplasm?

Fever or local heat : (-)

Pain : (-)

→ rule out inflammation

→ *Neoplasm or cyst*

benign or malignant?

Pain(-)

Tenderness(-)

Ulceration(-)

Induration(-)

Smooth surface(+)

Slow growth(+)

Long duration(+)

Fixed to overlying skin or mucosa(+)

→ ***benign***

Peripheral or intrabony origin ?

(we don't have radiographic examination)

- location: floor of mouth
- consistency: soft

→ *peripheral*

benign peripheral neoplasm or cyst



```
graph TD; A[benign peripheral neoplasm or cyst] --> B[salivary gland]; A --> C[connective tissue]; A --> D[cyst]; B --> E[Pleomorphic Adenoma]; C --> F["1. Neurolemoma (Schwannoma)  
2. Lipoma  
3. Rhabdomyoma  
4. Neurofibrom"]; D --> G[Dermoid cyst]
```

The diagram is a flowchart with a dark blue background and light blue circular patterns. At the top is a pink rounded rectangle containing the text 'benign peripheral neoplasm or cyst'. A horizontal line extends from this box, with three vertical lines descending to three yellow rounded rectangles below it. These are labeled 'salivary gland', 'connective tissue', and 'cyst'. From each yellow box, a yellow arrow points down to a light blue rounded rectangle. The first points to 'Pleomorphic Adenoma'. The second points to a list of four items: '1. Neurolemoma (Schwannoma)', '2. Lipoma', '3. Rhabdomyoma', and '4. Neurofibrom'. The third points to 'Dermoid cyst'.

salivary
gland

Pleomorphic
Adenoma

connective
tissue

1. Neurolemoma
(Schwannoma)
2. Lipoma
3. Rhabdomyoma
4. Neurofibrom

cyst

Dermoid cyst

Working diagnosis

- Neurilemoma (Schwannoma)
- Dermoid cyst
- Lipoma
- Rhabdomyoma
- Neurofibroma
- Pleomorphic adenoma



Neurilemoma (Schwannoma)

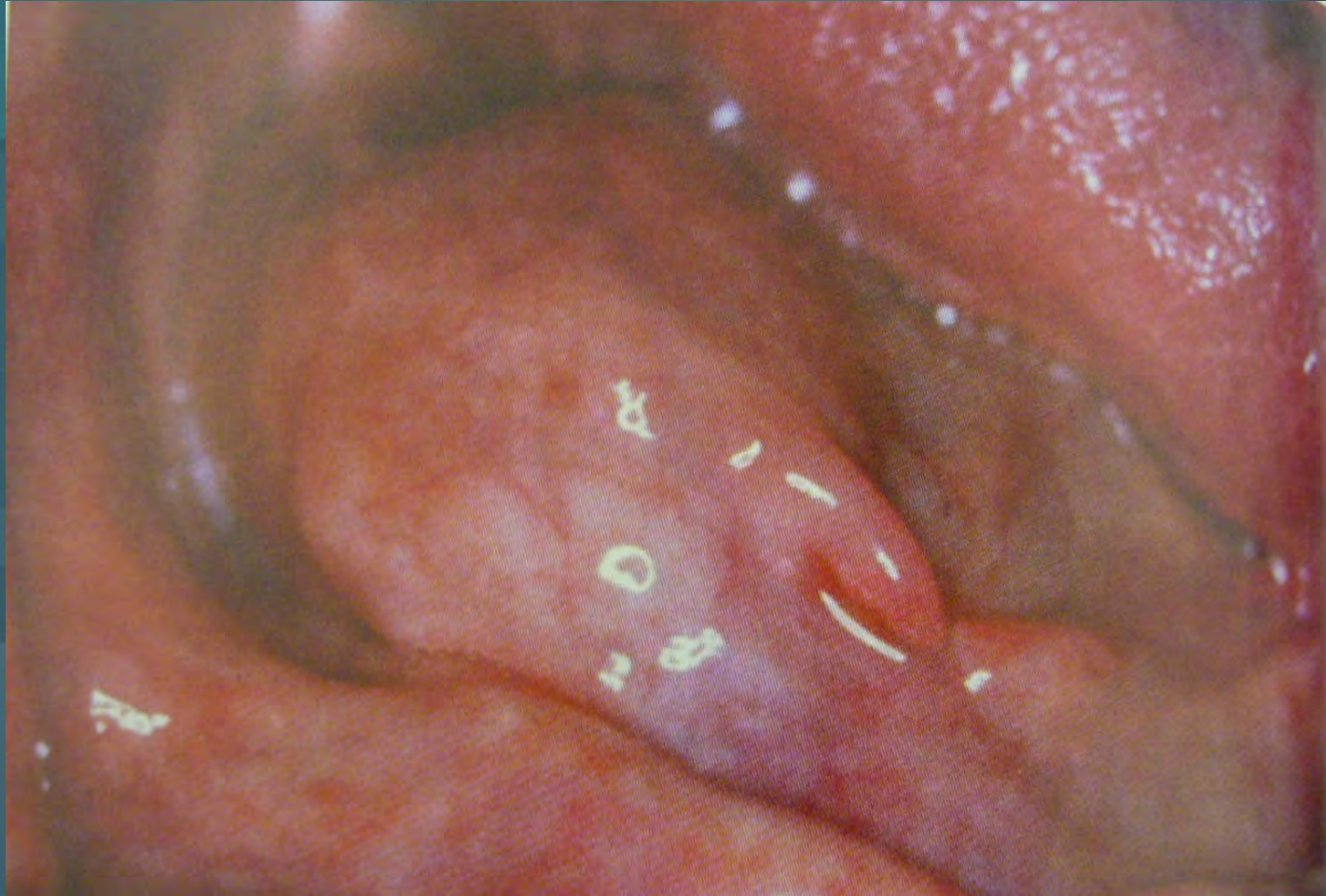Neurilemoma

	This case	Neurilemoma
Age	34y/o	young and middle-aged adults
Gender	male	both
Site	anterior left mouth floor	1. almost anywhere in the mouth (tongue) 2. intraosseous (posterior mandible)
Size	2.0*2.0cm	from a few millimeters to several centimeters
risk factor----- alcohol, betel nut, cigarette	alcohol(+) betel nut(+) cigarette(+)	rare relationship
Duration	more than one decade	long time (slow-growing)

Neurilemoma

	This case	Neurilemoma
Color	pink	red
Shape	dome	nodular / dome
Surface	smooth	smooth
Consistency	soft	firm
Pain	(-)	almost(-)
Tenderness	(-)	almost(-)
Mobility	fixed	movable to fixed
Induration	(-)	(-)
Ulcer	(-)	(-)

Neurilemoma





Dermoid Cyst

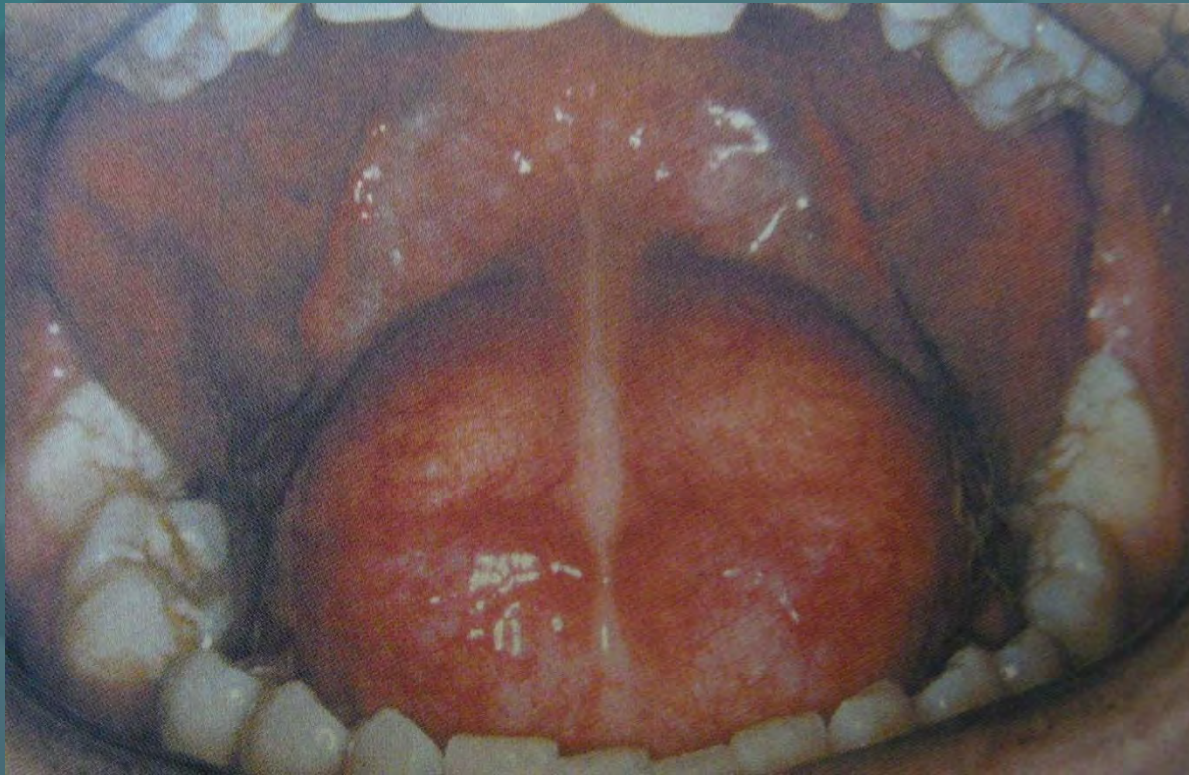
Dermoid Cyst

	This case	Dermoid cyst
Age	34	children & young adult
Gender	male	both
Site	left mouth floor	midline of the floor of mouth, although they are occasionally displaced laterally or develops in other locations.
Size	2x2(cm)	few millimeters~12cm
Risk factor----- Alcohol, Betel nut, Cigarette	alcohol(+) betel nut(+) cigarette(+)	rare relationship
Duration	more than one decade	long time(slow growing)

Dermoid Cyst

	This case	Dermoid cyst
Color	pink	red
Shape	dome	dome
Surface	smooth	smooth
Consistency	soft	doughy & rubbery
Pain	(-)	(-)
Tenderness	(-)	(-)
Mobility	fixed	movable
Induration	(-)	(-)
Ulcer	(-)	(-)

Dermoid Cyst





Lipoma

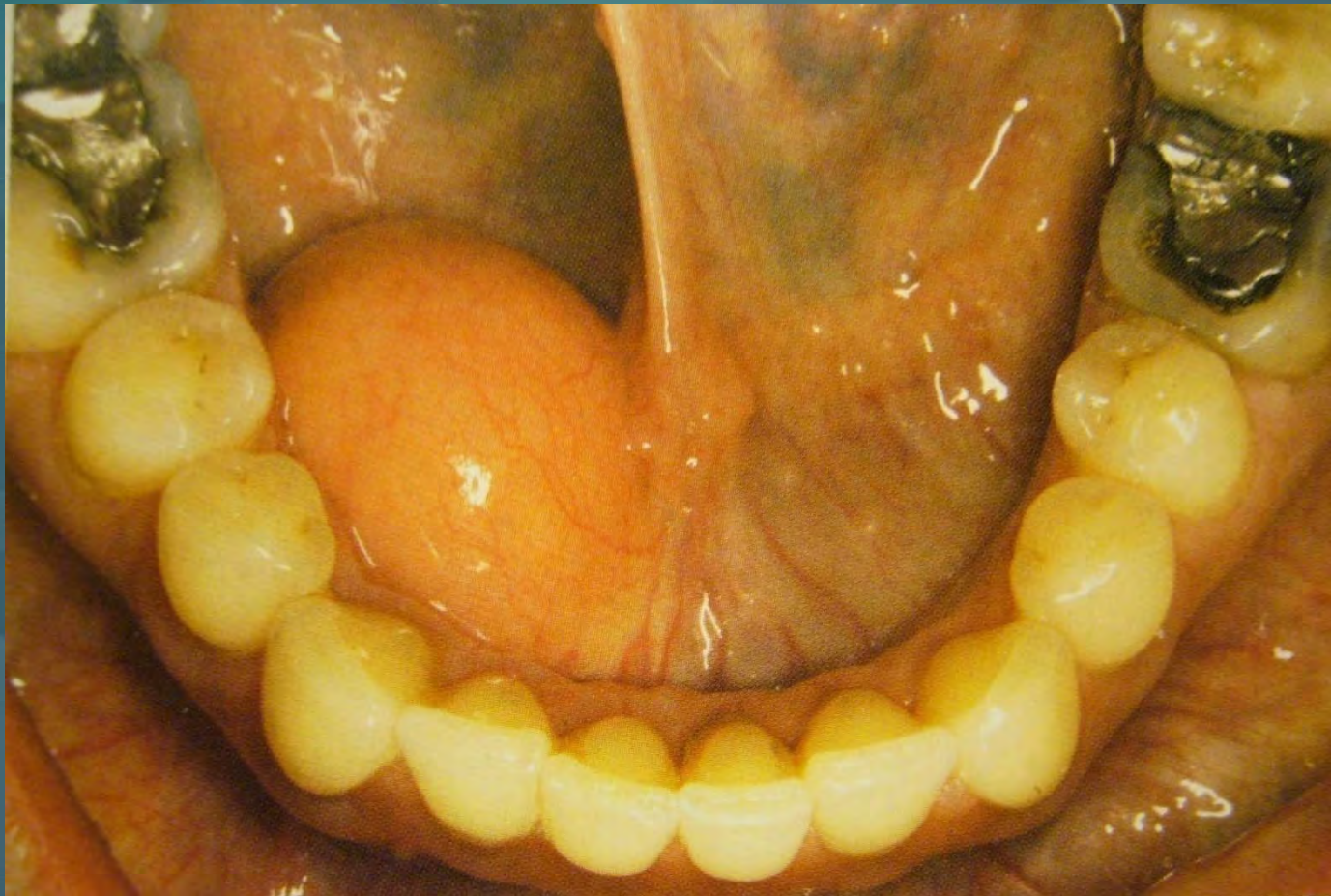
Lipoma

	This case	lipoma
Age	34	40 years of age or older
Gender	male	fairly balanced (male)
Site	left mouth floor	buccal mucosa, buccal vestibule, tongue, floor of the mouth, lips
Size	2.0x2.0 cm	less than 3 cm in size (larger)
Risk factor----- Alcohol, Betel nut, Cigarette	alcohol(+) betel nut(+) cigarette(+)	rare relationship
Duration	more than one decade	noted for many months or years before diagnosis

Lipoma

	This case	lipoma
Color	pink	yellow, pink(deep)
Shape	dome	nodule
Surface	smooth	smooth
Consistency	soft	soft
Pain	(-)	(-)
Tenderness	(-)	(-)
Mobility	fixed	movable
Induration	(-)	(-)
Ulcer	(-)	(-)

Lipoma





Rhabdomyoma

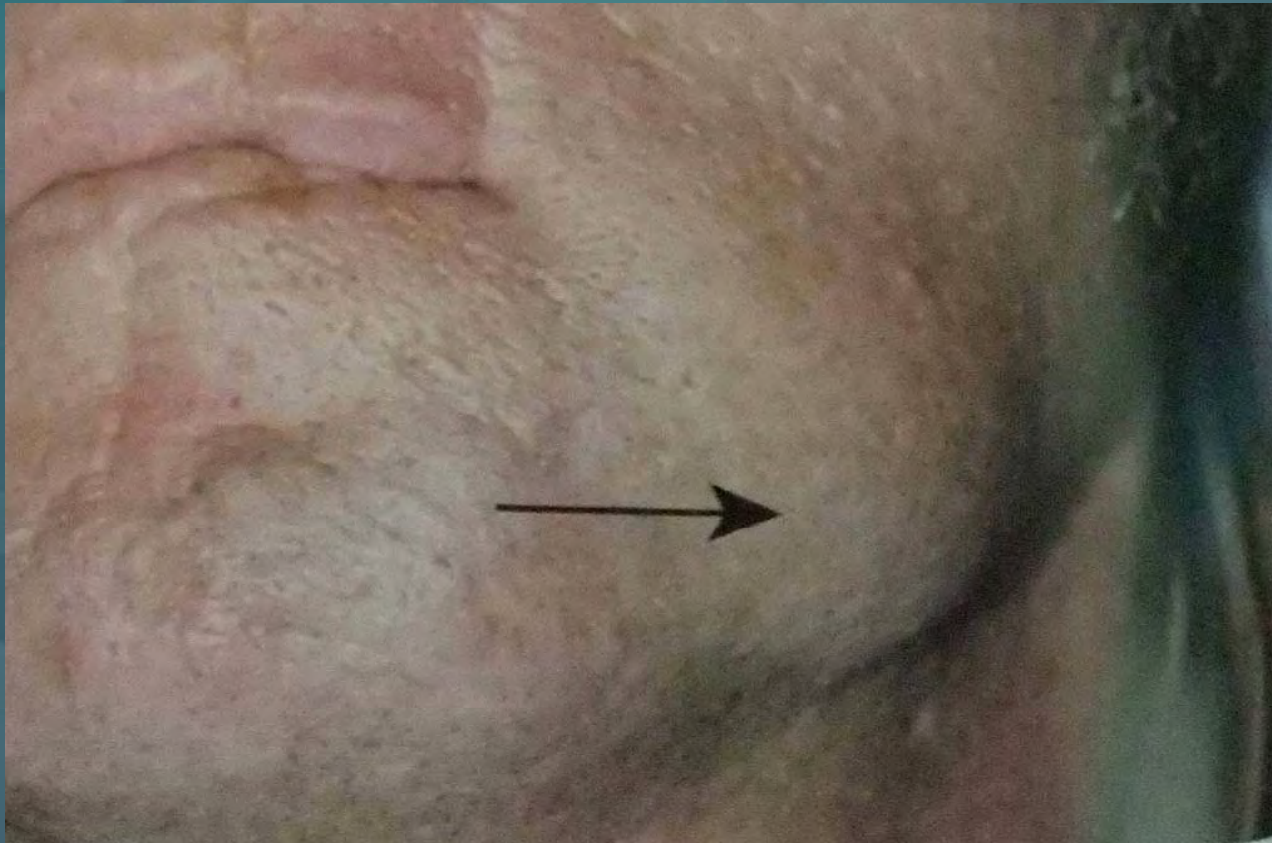Rhabdomyoma

	This case	Rhabdomyoma
Age	34	1. adult : middle-age & older 2. fetal : young children
Gender	male	70% male
Site	left mouth floor	1. adult : floor of mouth, soft palate, base of tongue 2. fetal : face &
		periauricular region
Size	2.0 x 2.0 cm	many centimeters
Risk factor----- Alcohol, Betel nut, Cigarette	alcohol(+) betel nut(+) cigarette(+)	rare relationship
Duration	more than one decade	several years

Rhabdomyoma

	This case	Rhabdomyoma
Color	pink	red
Shape	dome	nodule
Surface	smooth	smooth
Consistency	soft	soft
Pain	(-)	(-)
Tenderness	(-)	(-)
Mobility	fixed	movable
Induration	(-)	(-)
Ulcer	(-)	(-)

Rhabdomyoma





Neurofibroma

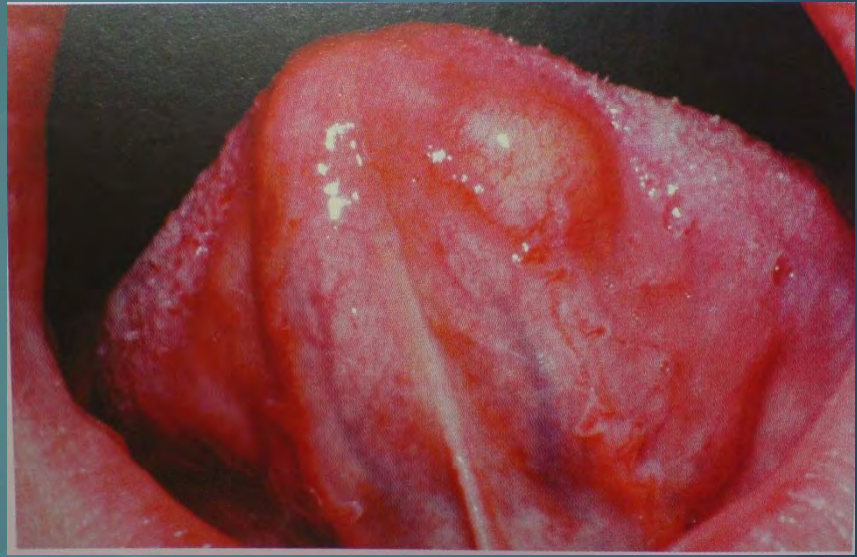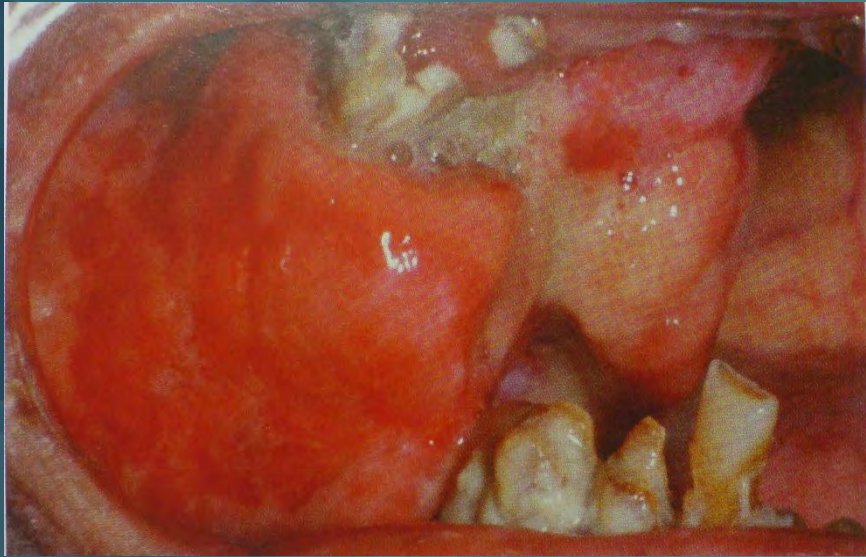Neurofibroma

	This case	Neurofibroma
Age	34	young adult
Gender	male	both
Site	left mouth floor	1.skin 2.oral cavity tongue/ buccal mucosa
Size	2.0x2.0	vary
Risk factor----- Alcohol, Betel nut, Cigarette	alcohol(+) betel nut(+) cigarette(+)	rare relationship
Duration	more than one decade	long time(slow growing)

Neurofibroma

	This case	Neurofibroma
Color	pink	red
Shape	dome	nodule/mass
Surface	smooth	smooth
Consistency	soft	firm/soft
Pain	(-)	(-)
Tenderness	(-)	(-)
Mobility	fixed	movable
Induration	(-)	(-)
Ulcer	(-)	(-)

Neurofibroma





Pleomorphic Adenoma

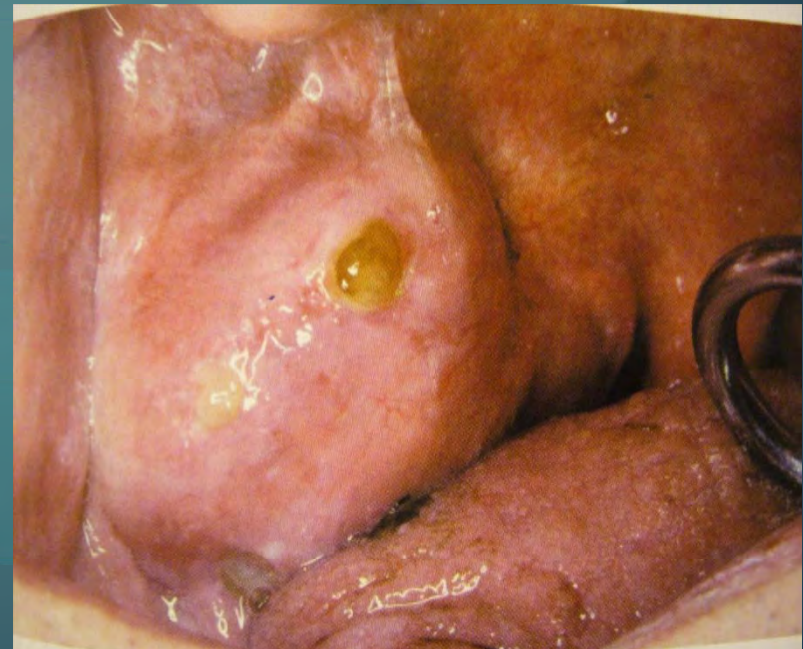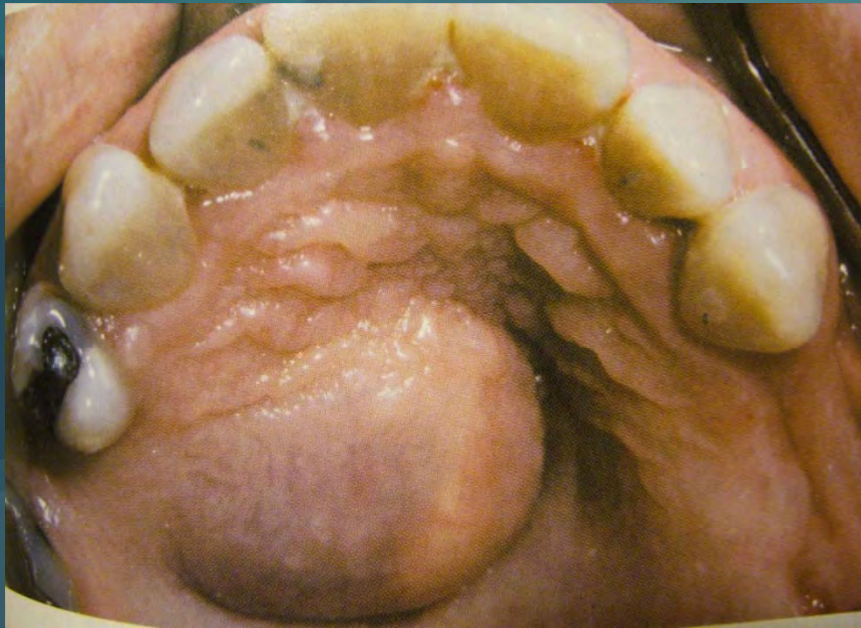Pleomorphic Adenoma

	This case	Pleomorphic Adenoma
Age	34 y/o	30~50 y/o
Gender	male	slightly female predilection
Site	left mouth floor	<ol style="list-style-type: none"> 1. mandibular ramus in front of ear (parotid gland) 2. lateral pharyngeal wall or palate
Size	2x2 cm	usually <3 cm
Risk factor----- Alcohol, Betel nut, Cigarette	alcohol (+) betel nuts (+) cigarette (+)	rare relationship
Duration	more than one decade	many months or years(slow growing)

Pleomorphic Adenoma

	This case	Pleomorphic Adenoma
Color	pink	red
Shape	dome	dome
Surface	smooth	smooth
Consistency	soft	firm
Pain	(-)	(-)
Tenderness	(-)	(-)
Mobility	fixed	movable/fixed (palate)
Induration	(-)	(-)
Ulcer	(-)	(-), secondary ulceration may occur

Pleomorphic Adenoma



Clinical Impression

- Neurilemoma, anterior left floor of mouth
- Dermoid cyst, anterior left floor of mouth

Reference

- Oral and Maxillofacial Pathology 2nd and 3rd edition
- Differential Diagnosis of Oral and Maxillofacial Lesions 5th edition



THANKS FOR YOUR
ATTENTION !