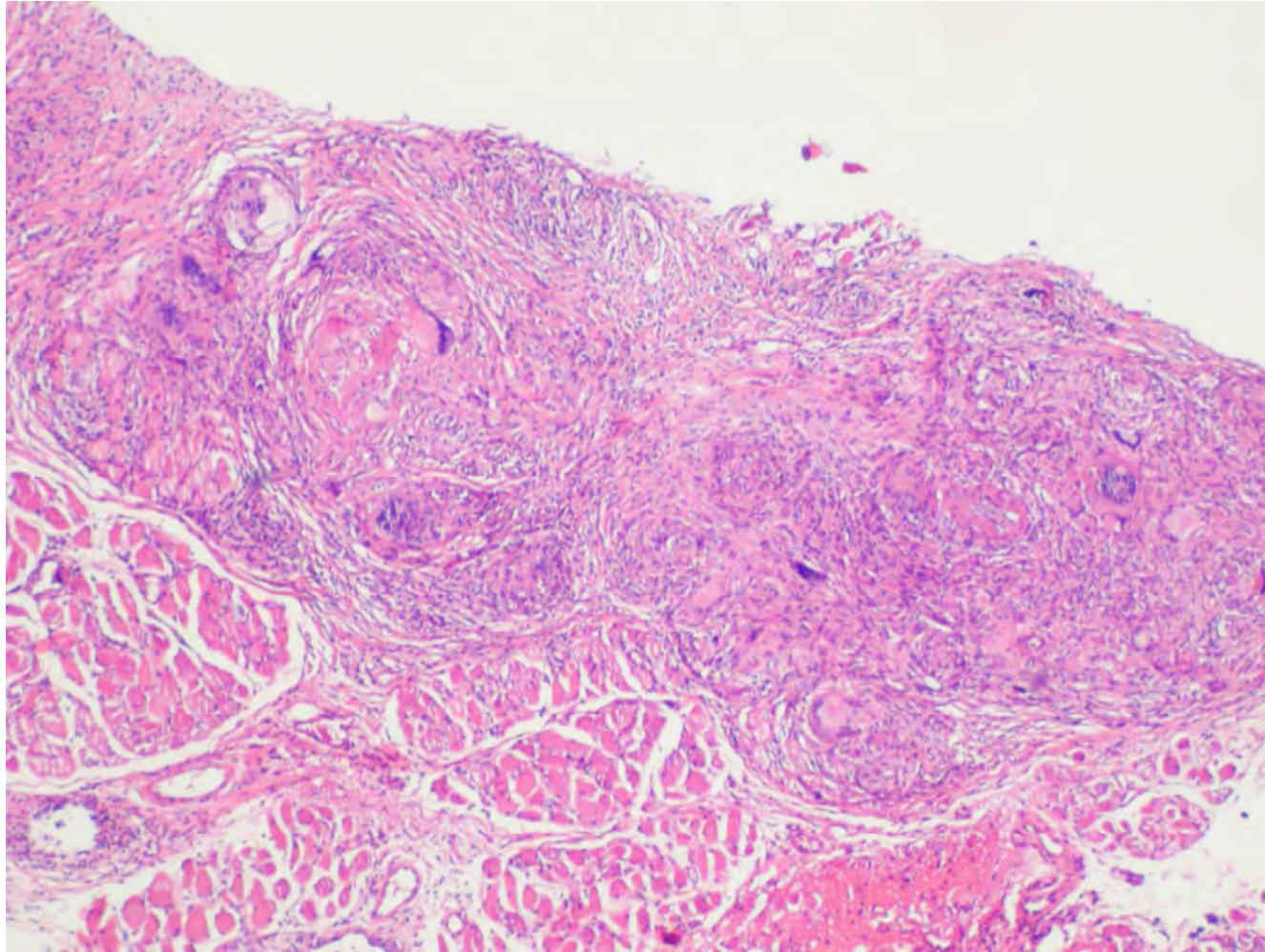
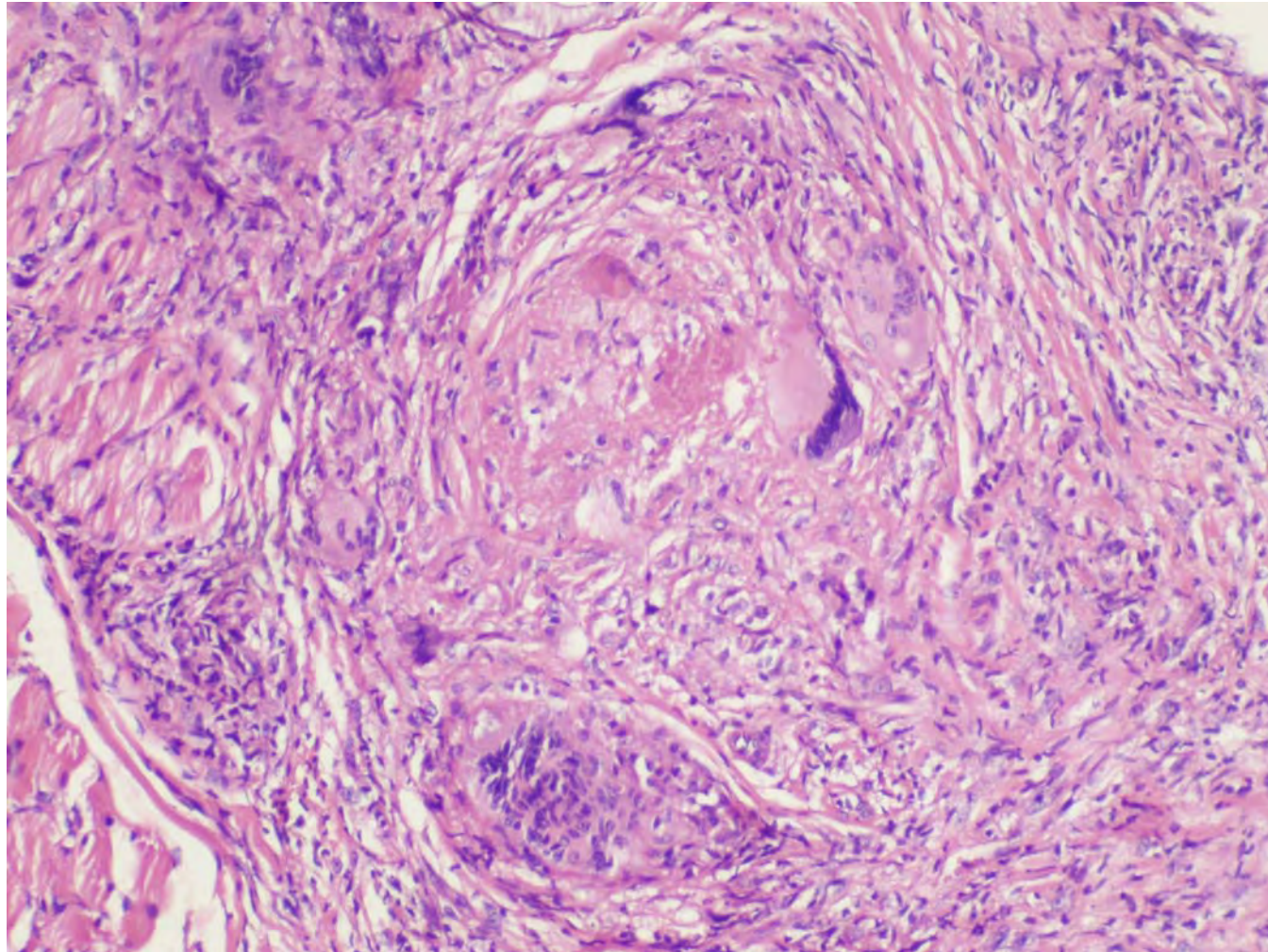


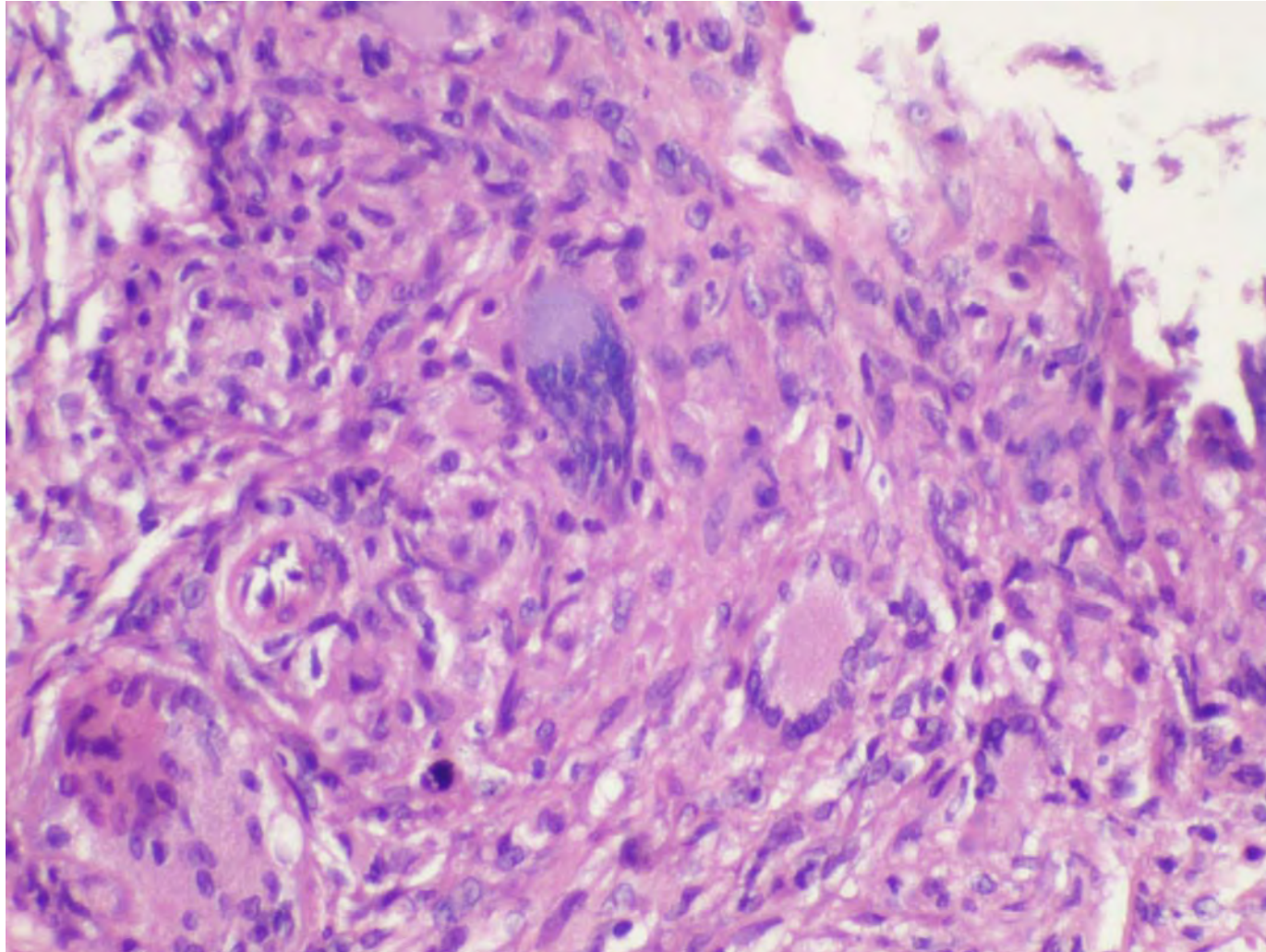
Case 4 - 1



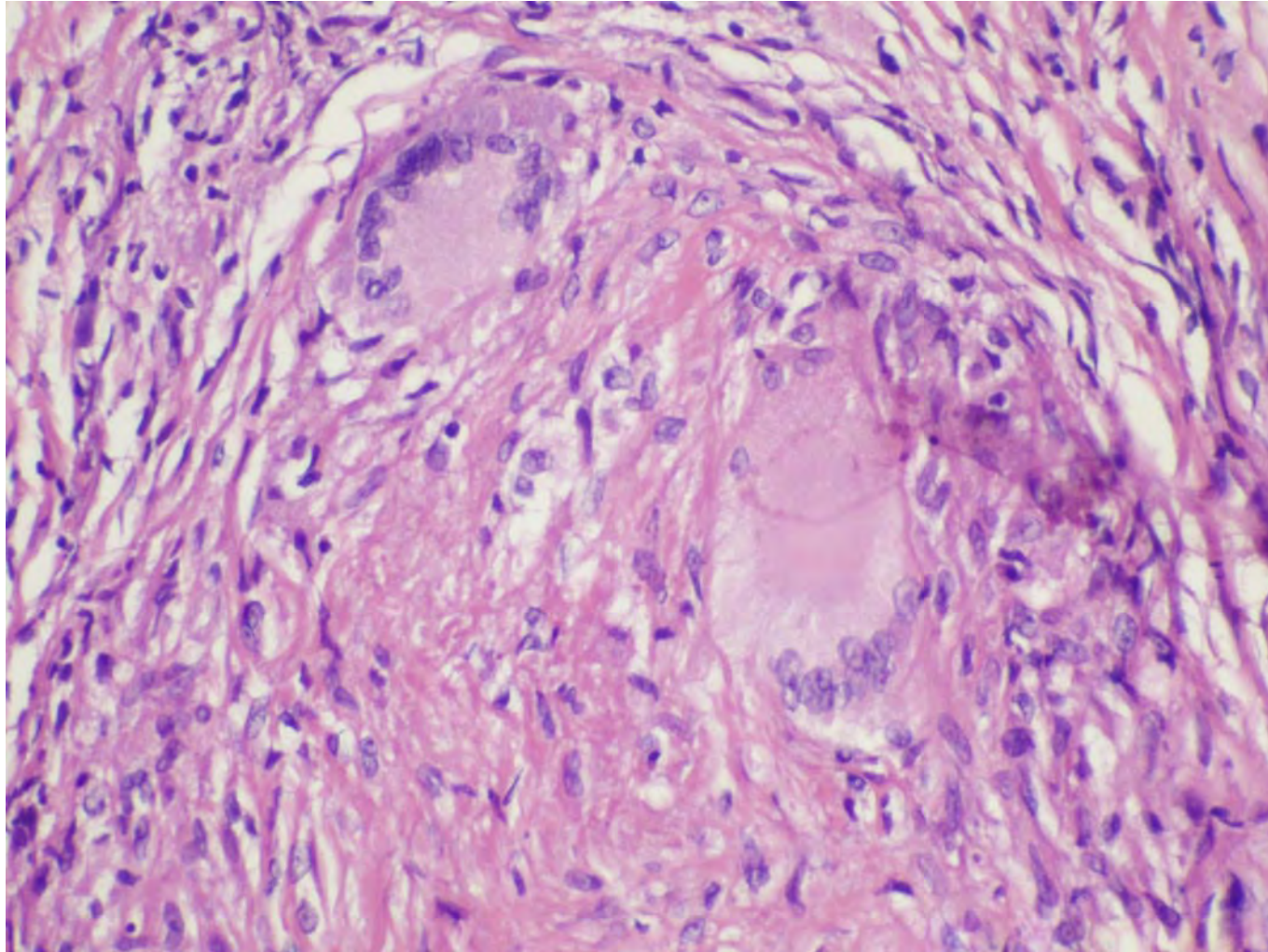
Case 4 - 2



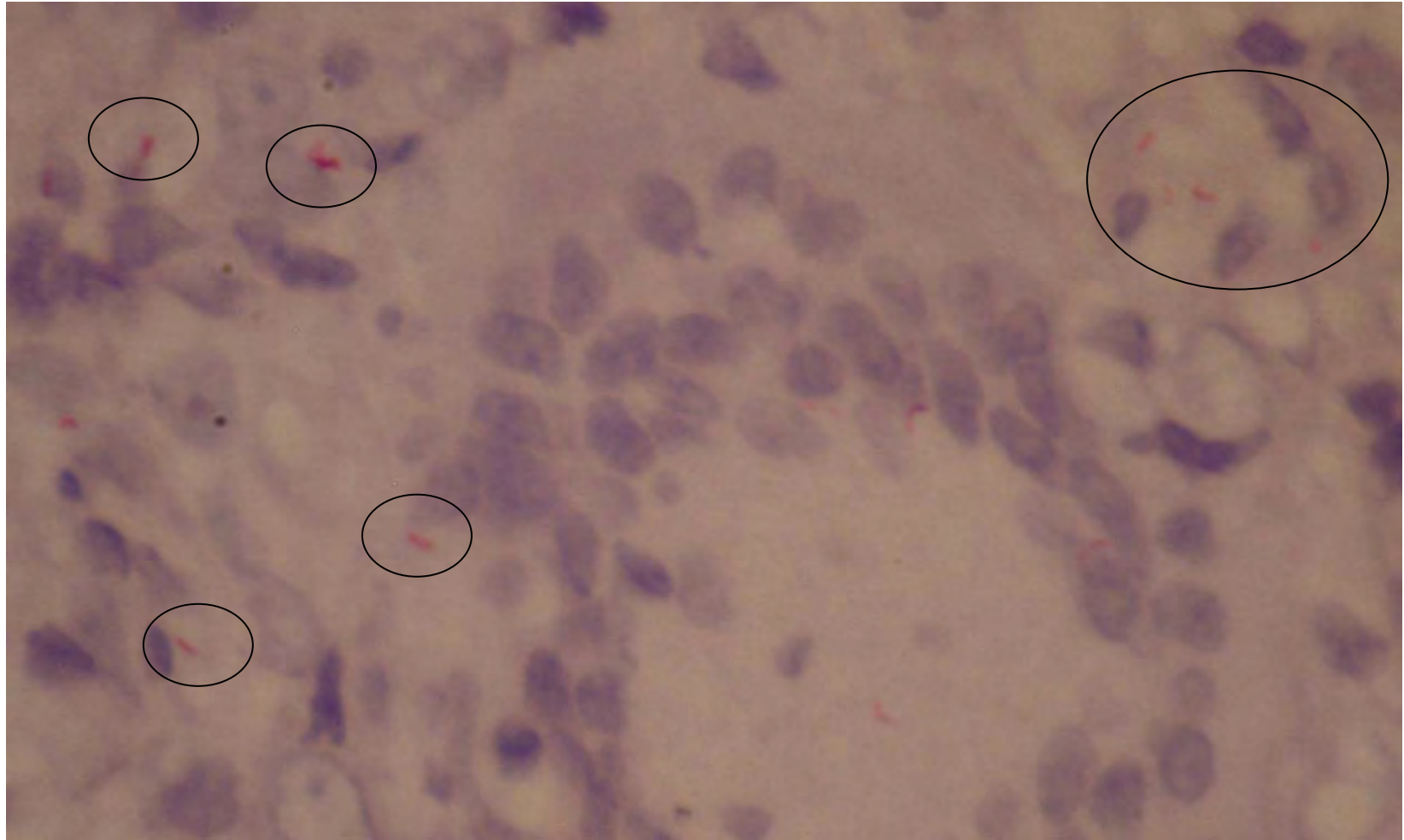
Case 4 - 3



Case 4 - 4



Case 4 Acid-fast stain



HP Report

- Tuberculosis

Oral cavity, Upper lip, Middle, Incision