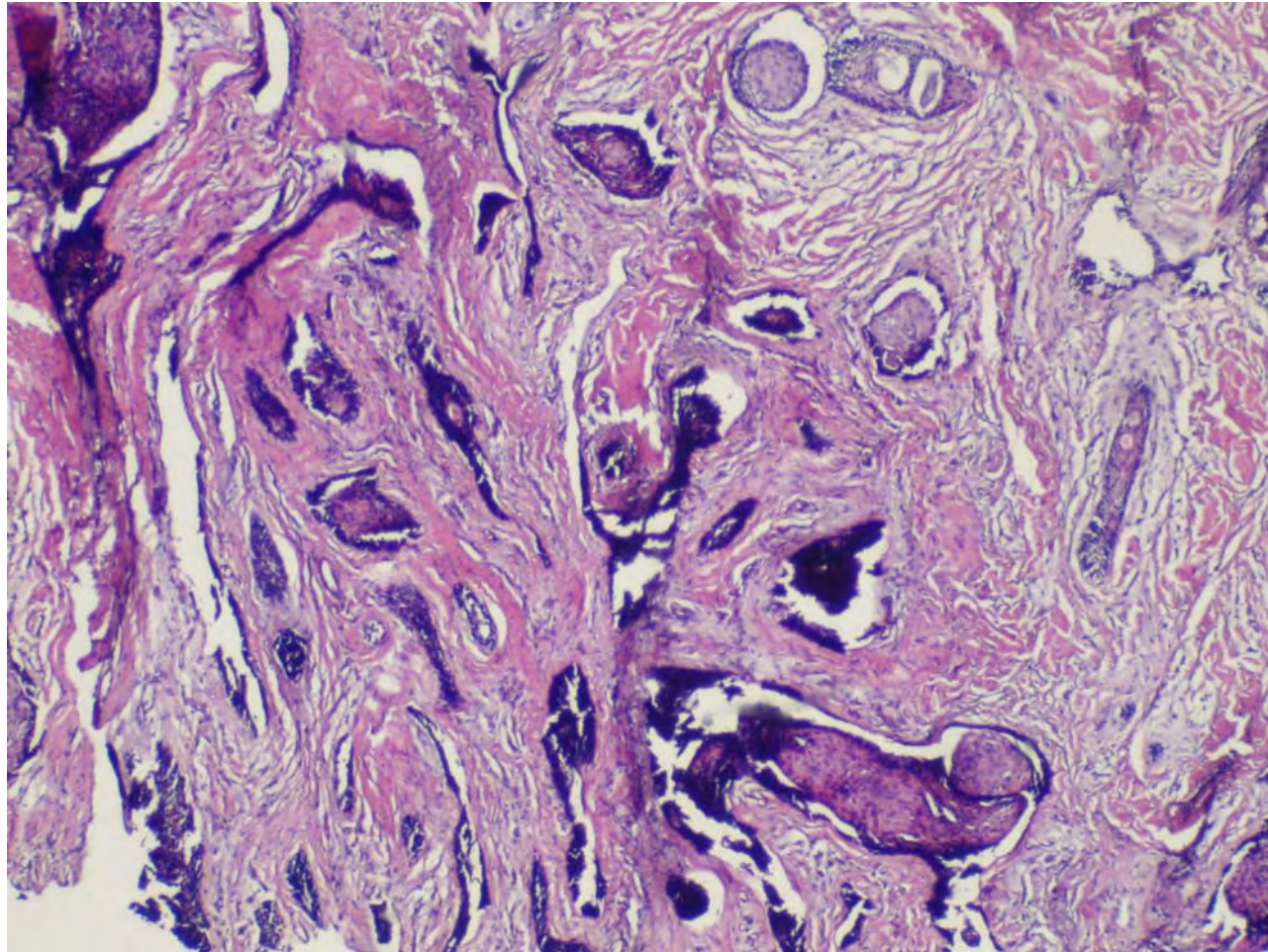
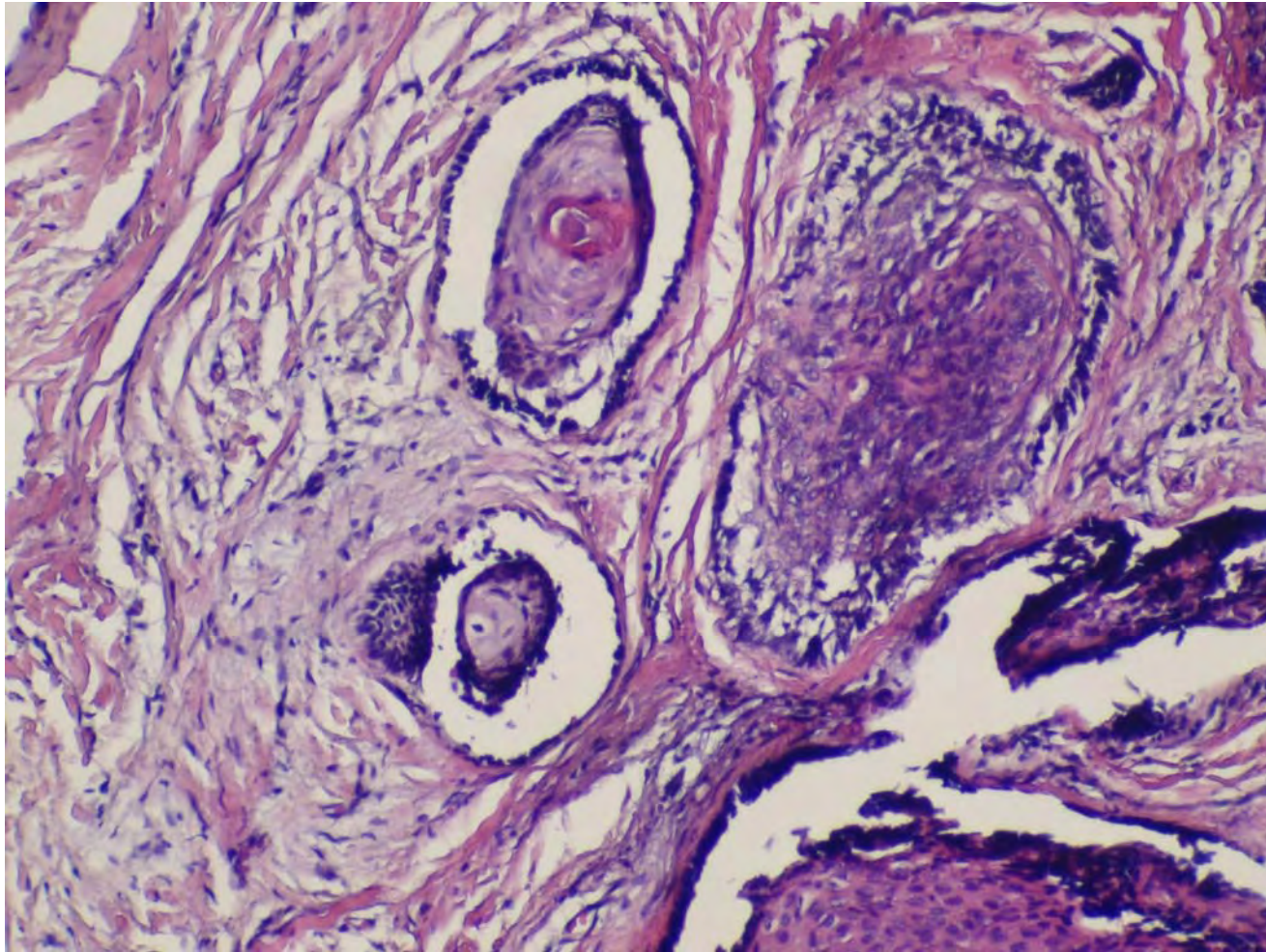


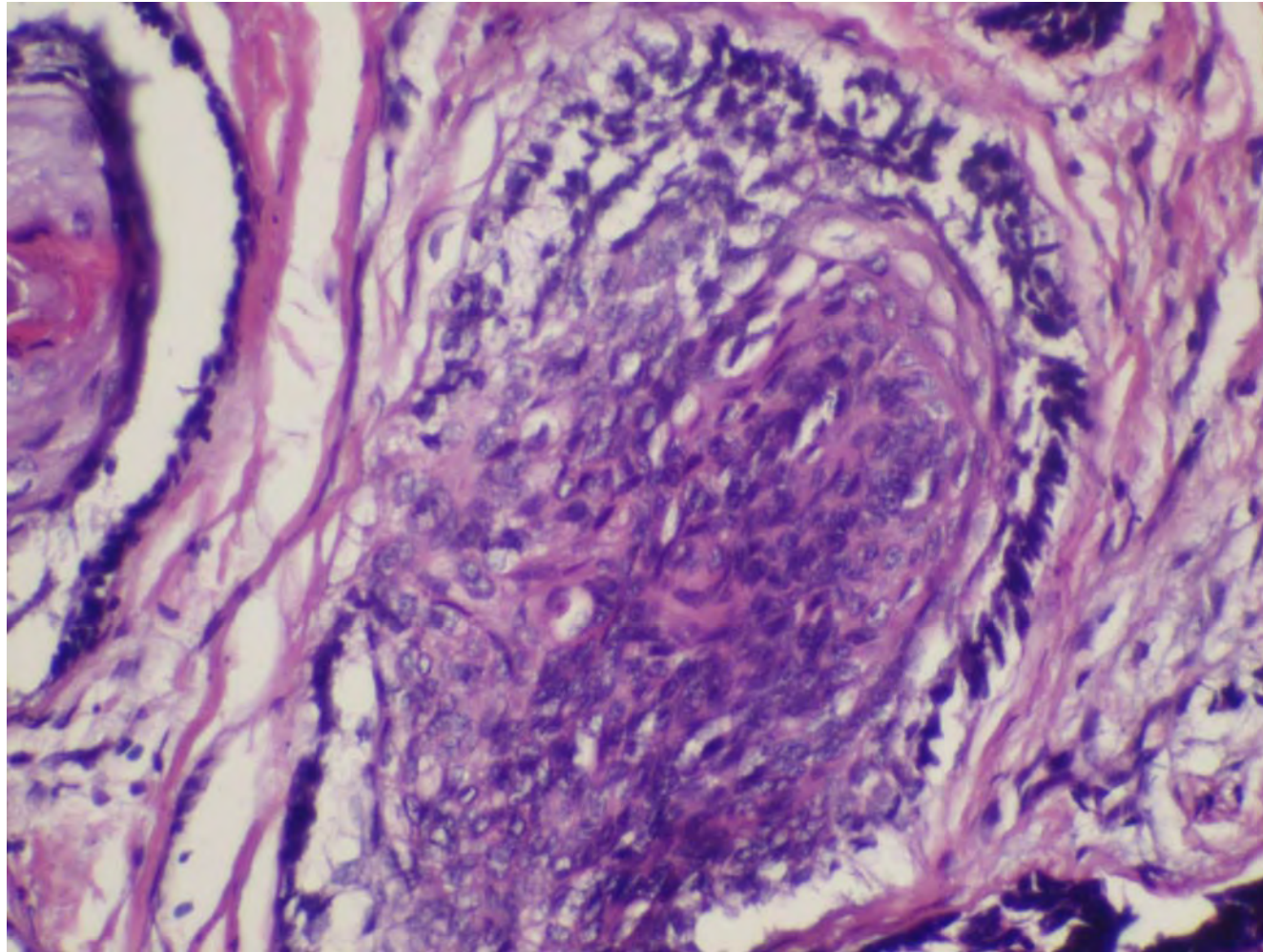
Case 3 - 1



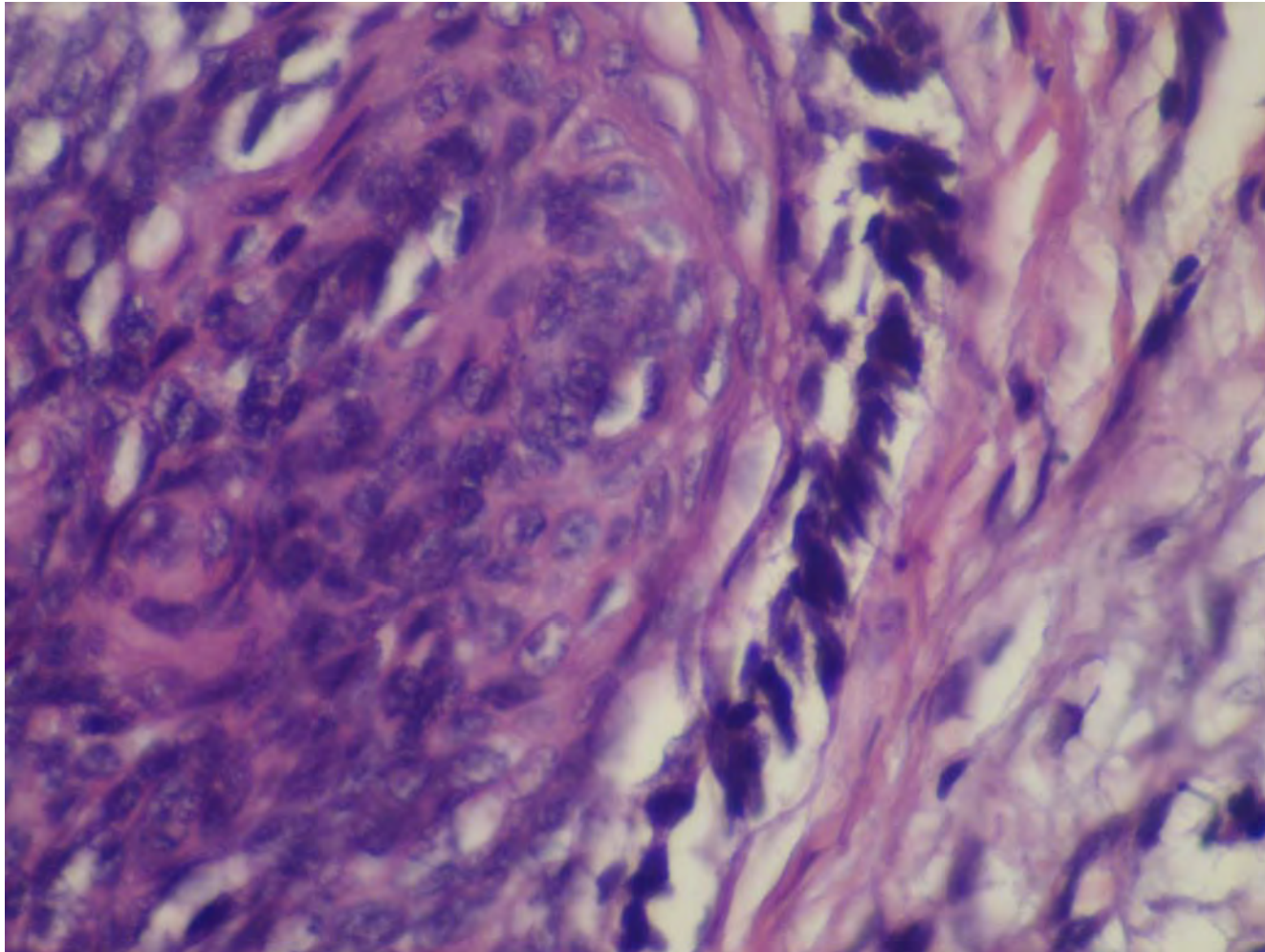
Case 3 - 2



Case 3 - 3



Case 3 - 4



HP Report

- Ameloblastoma
Bone, Mandible, Left, Incision