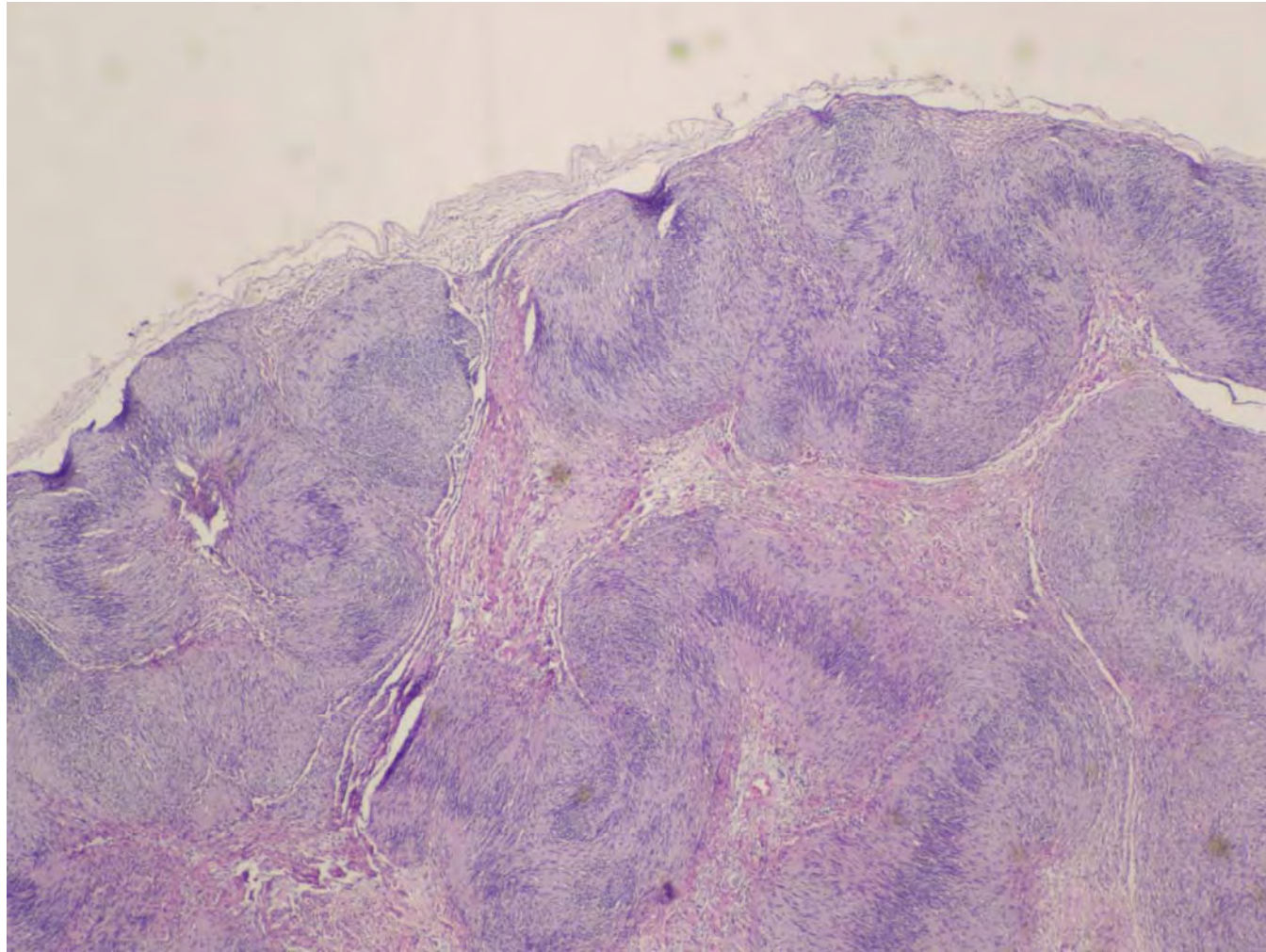
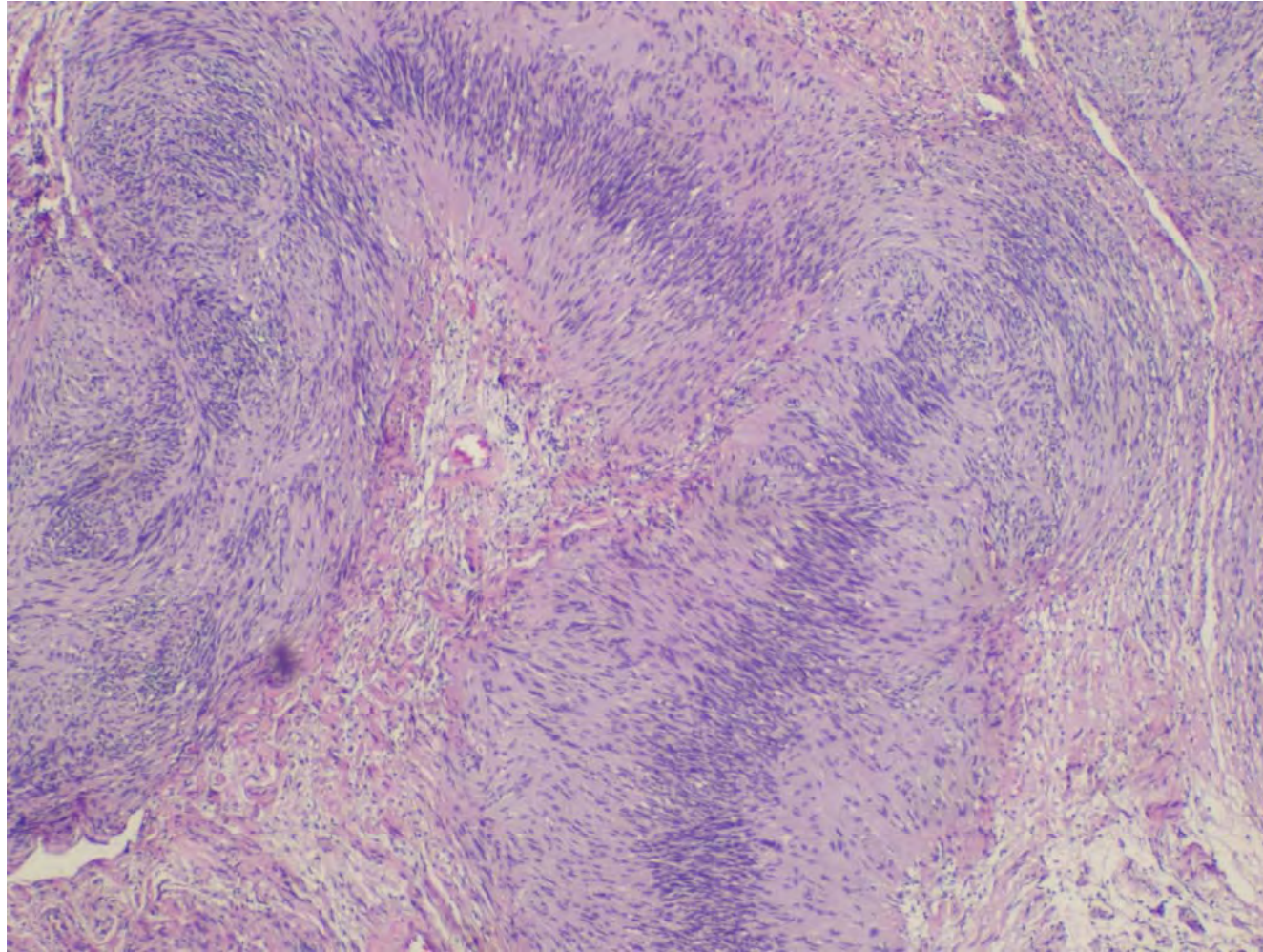


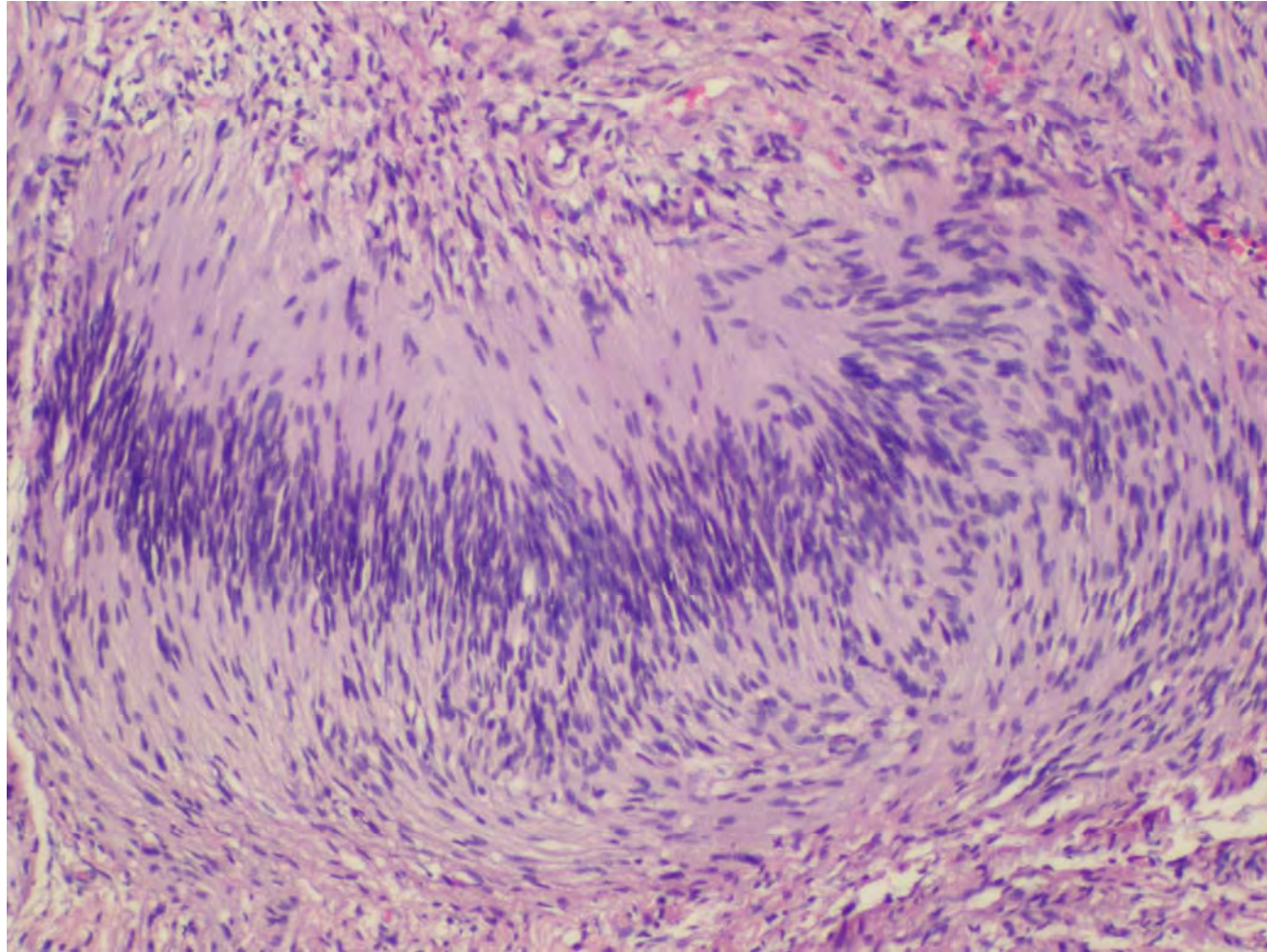
Case 2 - 1



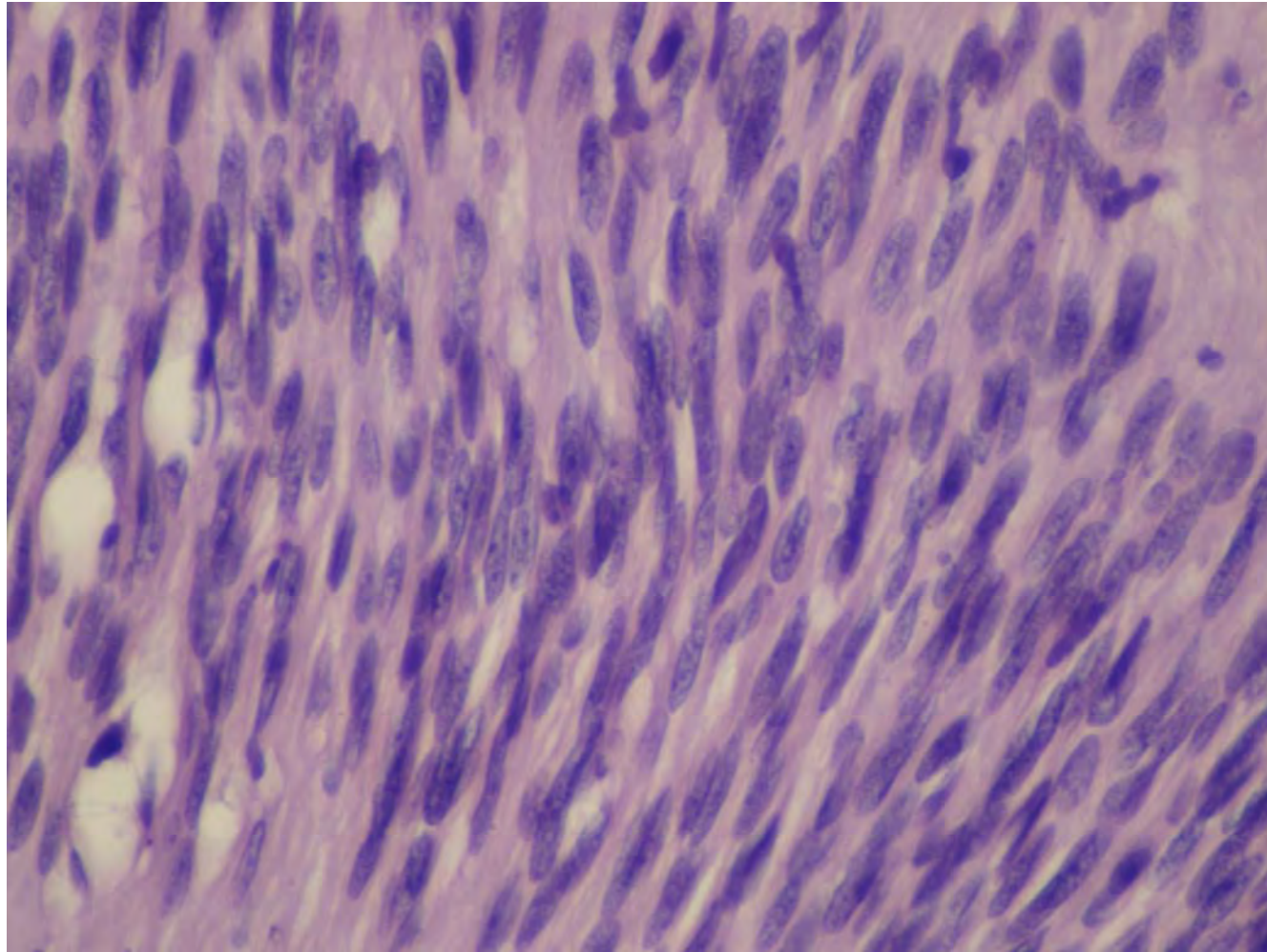
Case 2 - 2



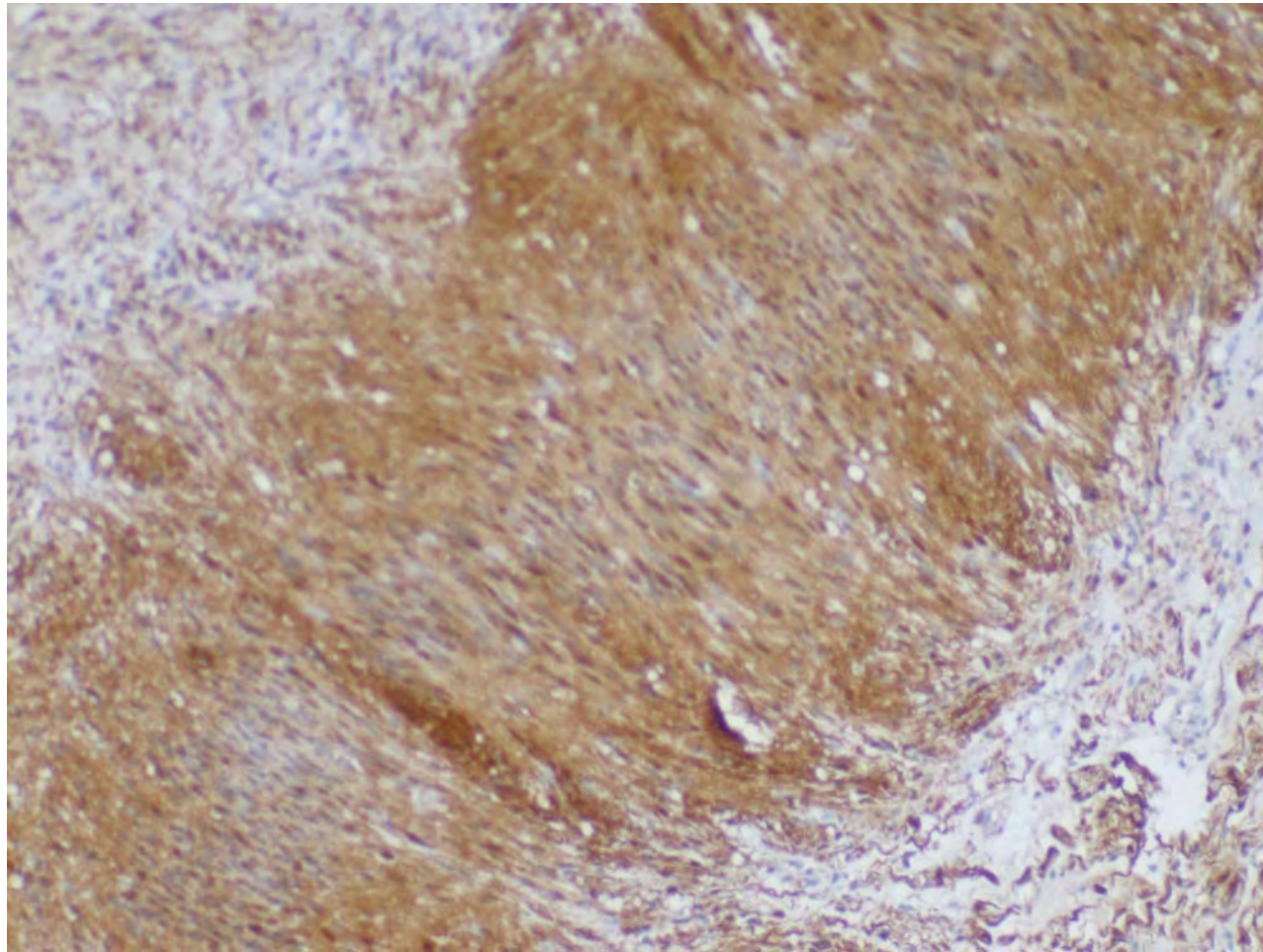
Case 2 - 3



Case 2 - 4



Case 2 S-100



HP Report

- Schwannoma

Oral cavity, Tongue dorsum, Anterior,
Excision