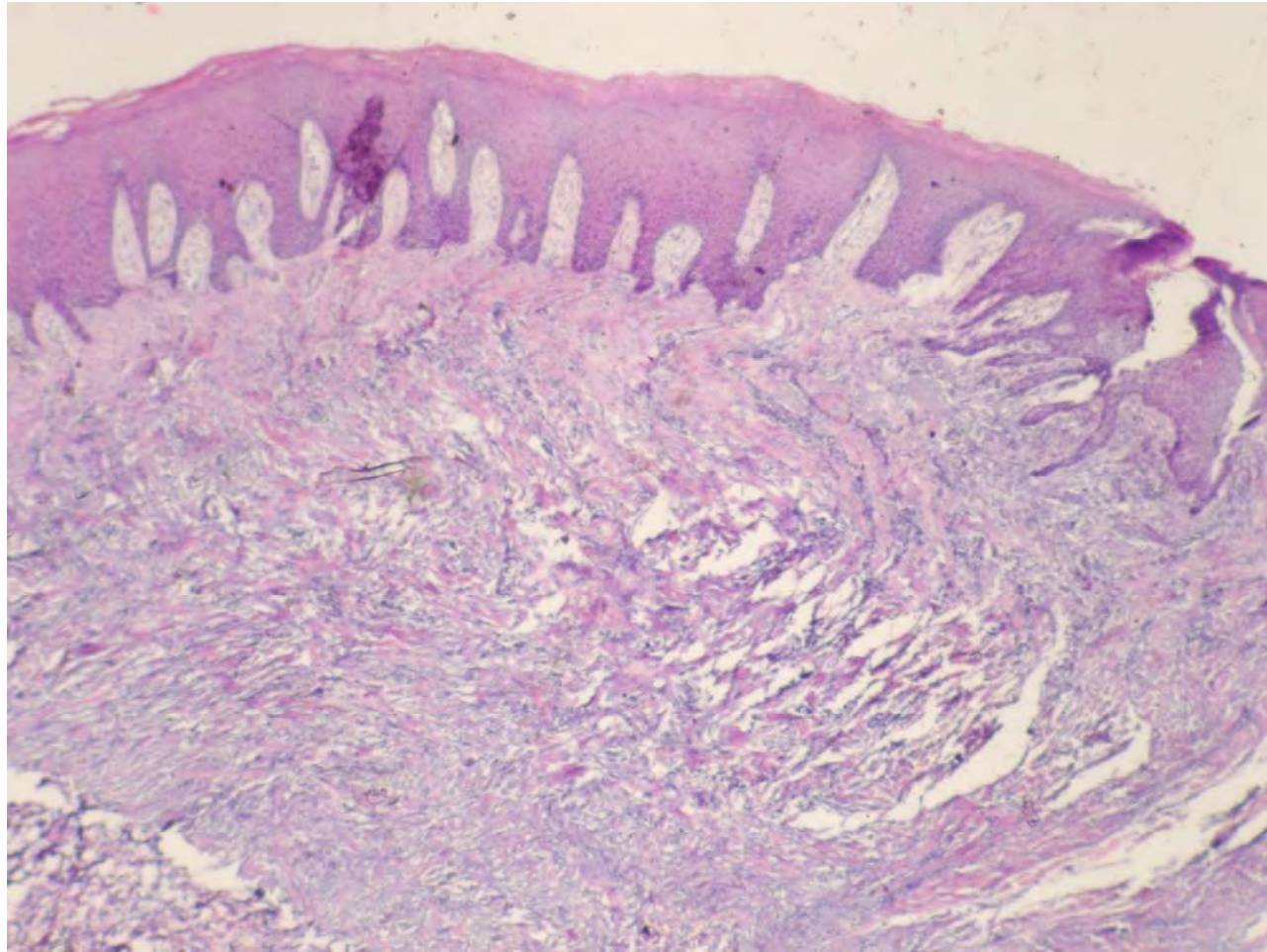
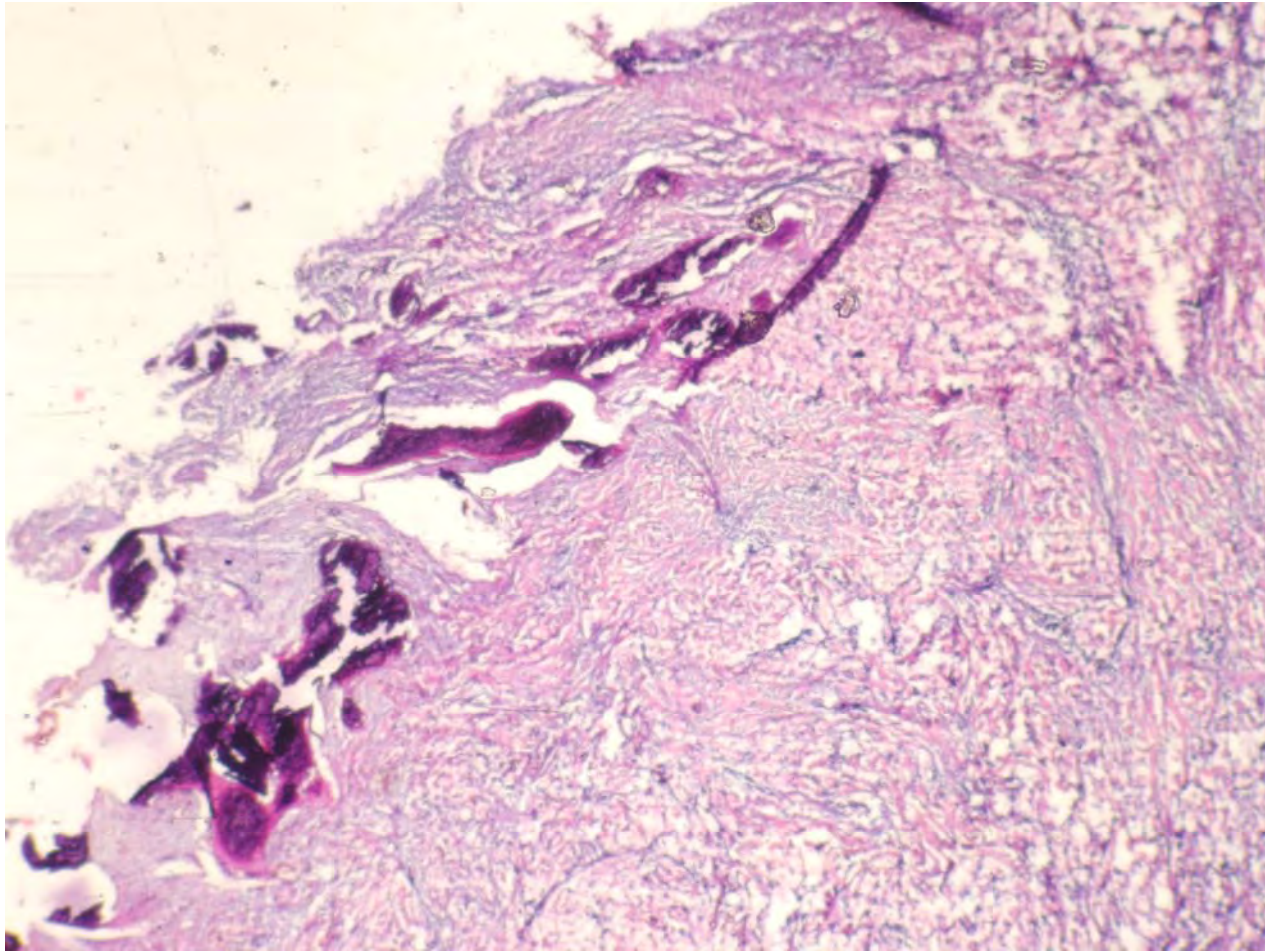


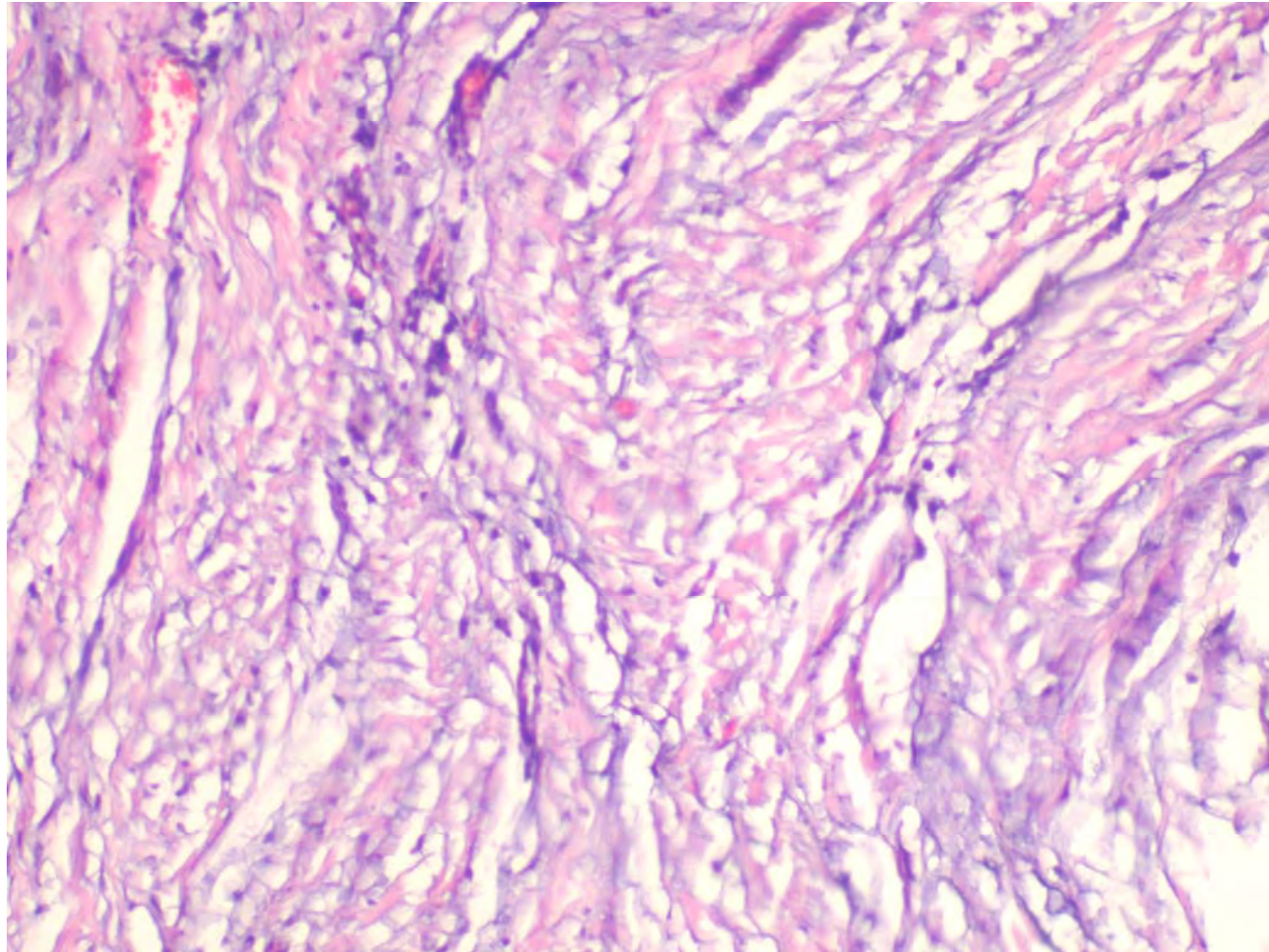
Case 1 - 1



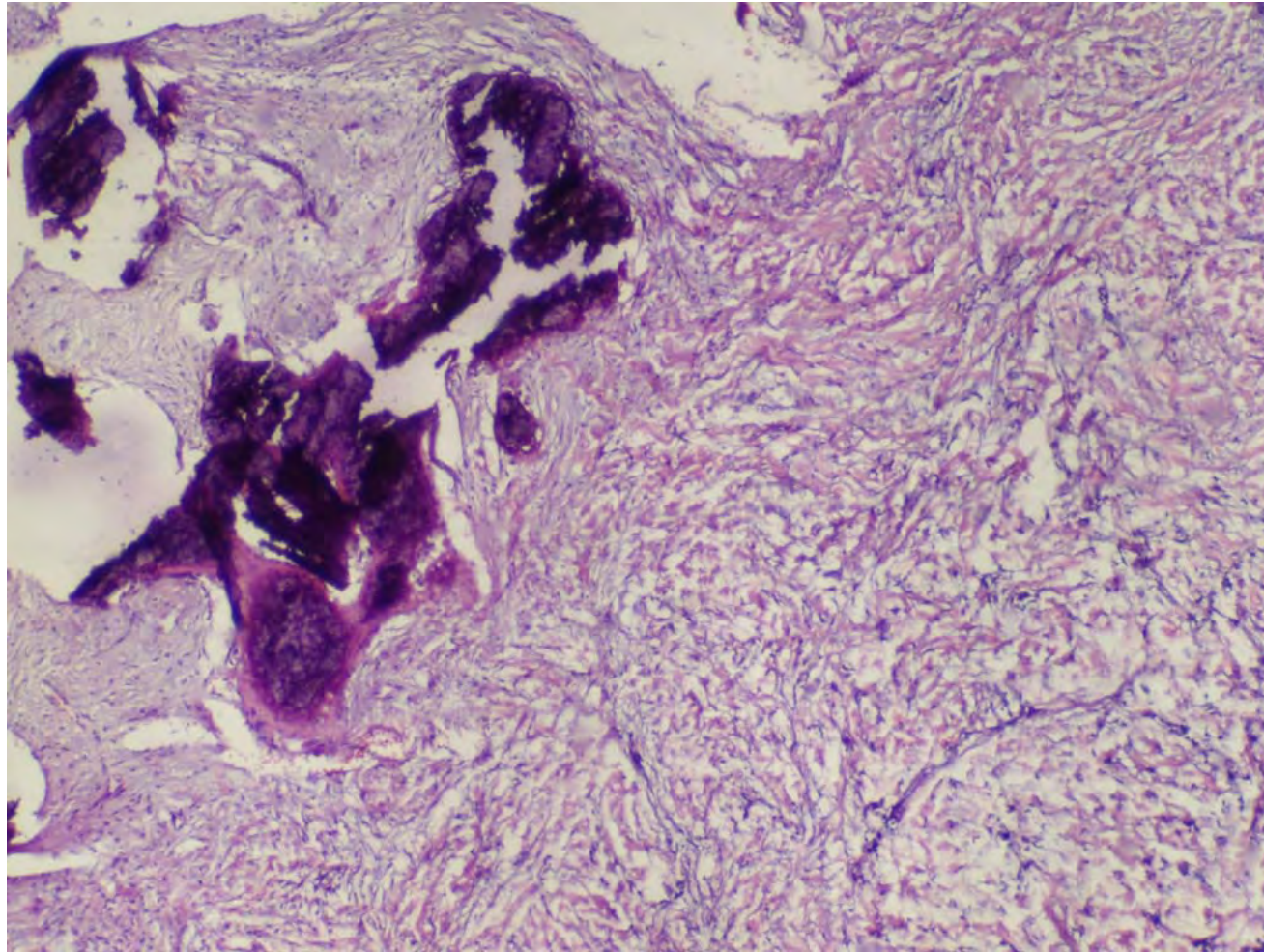
Case 1 - 2



Case 1 - 3



Case 1 - 4



HP Report

- Peripheral odontogenic fibroma
Oral cavity, Gingiva, tooth 26, 27 area,
Excision