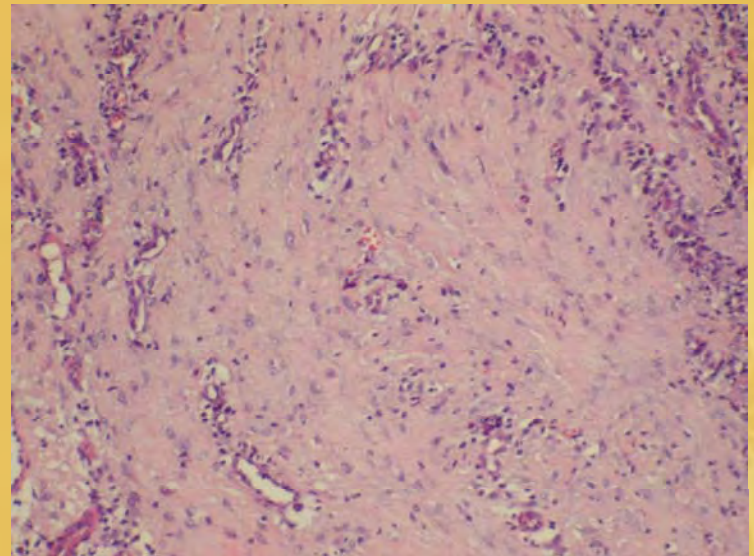
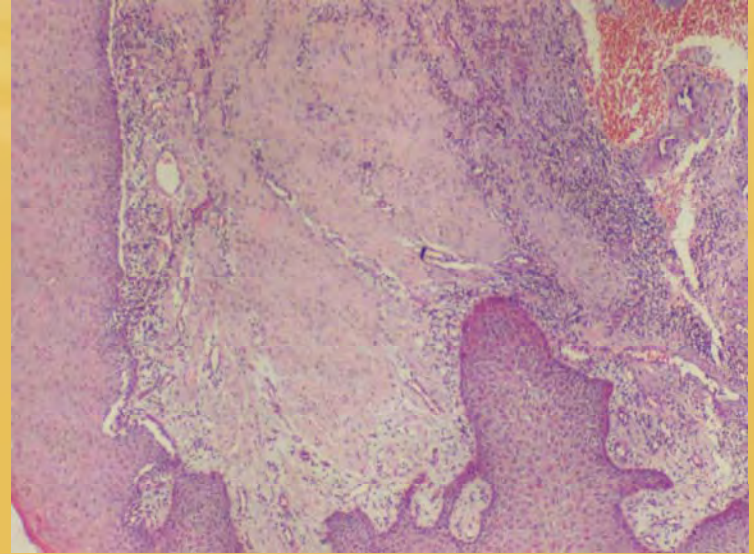
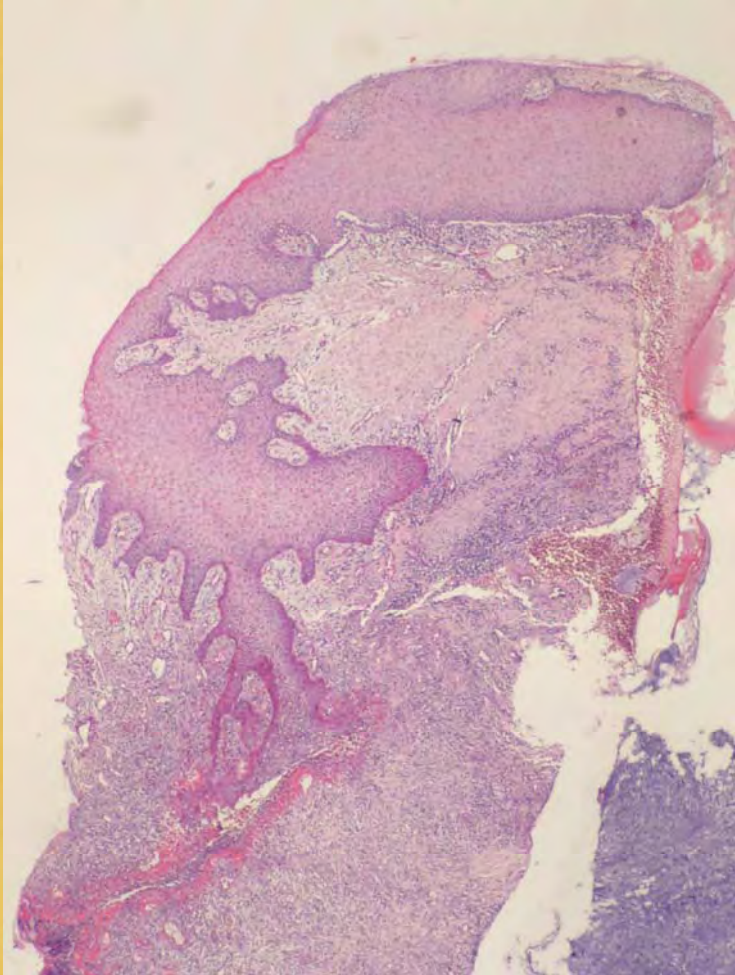




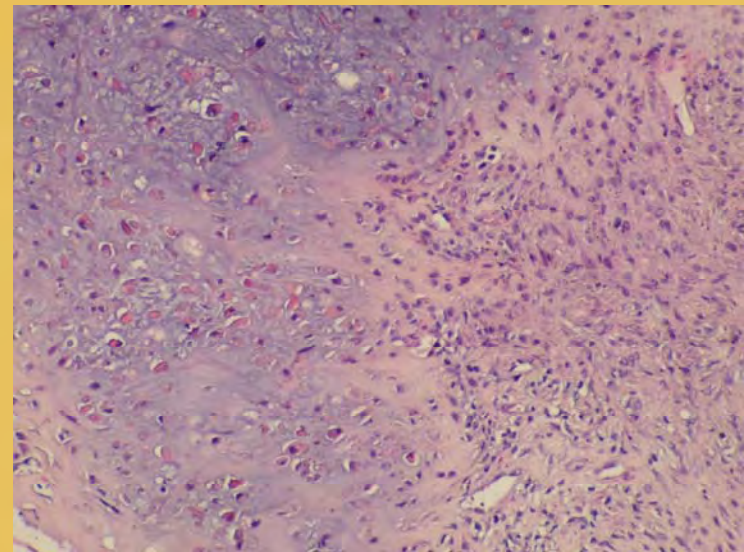
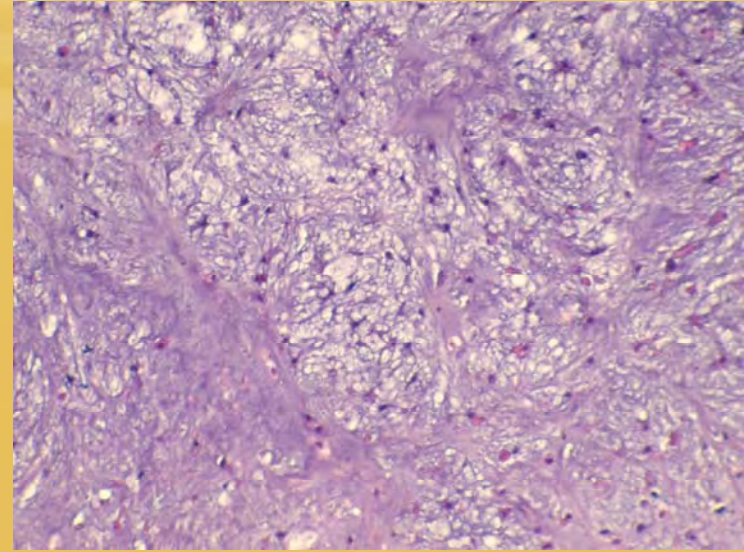
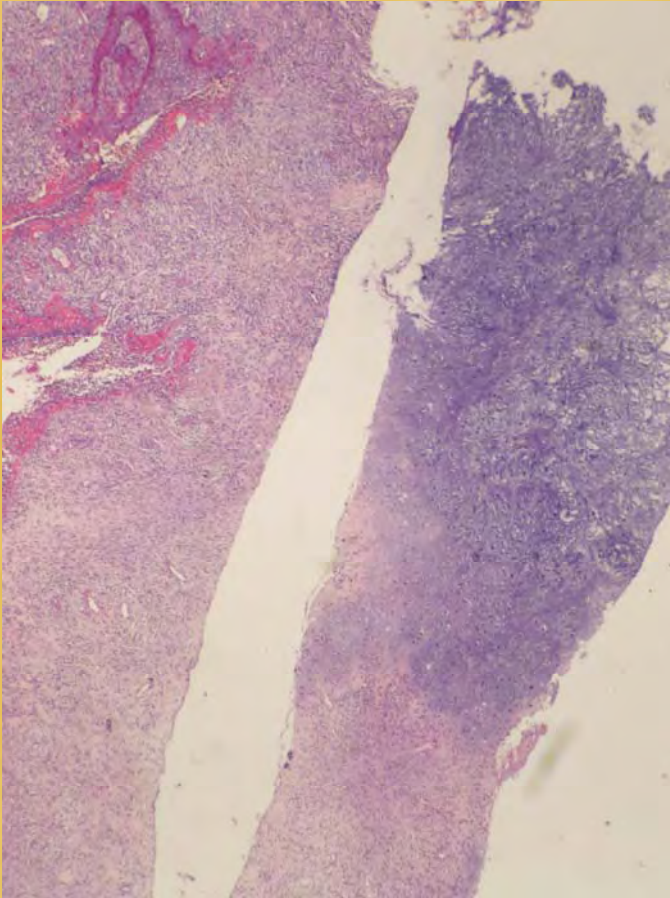
# Case 4



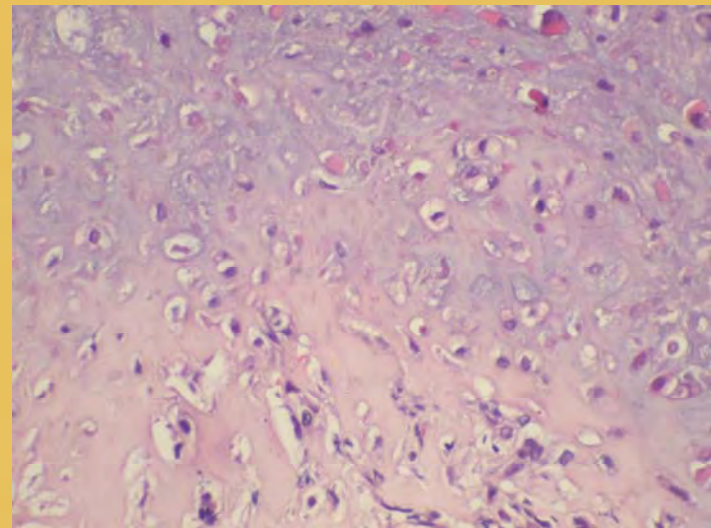
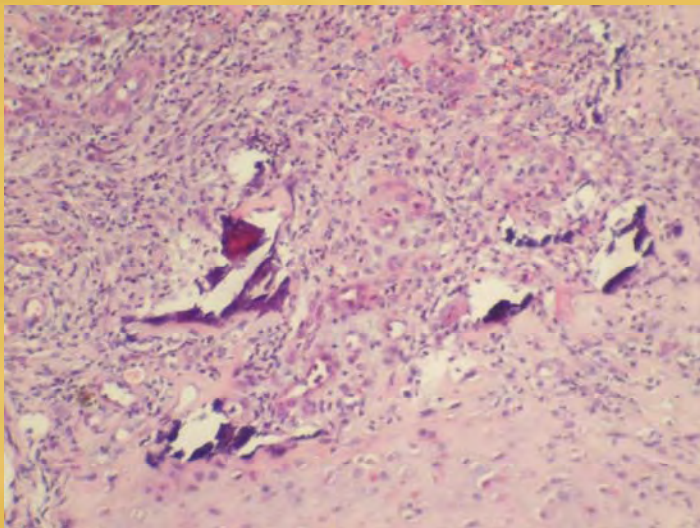
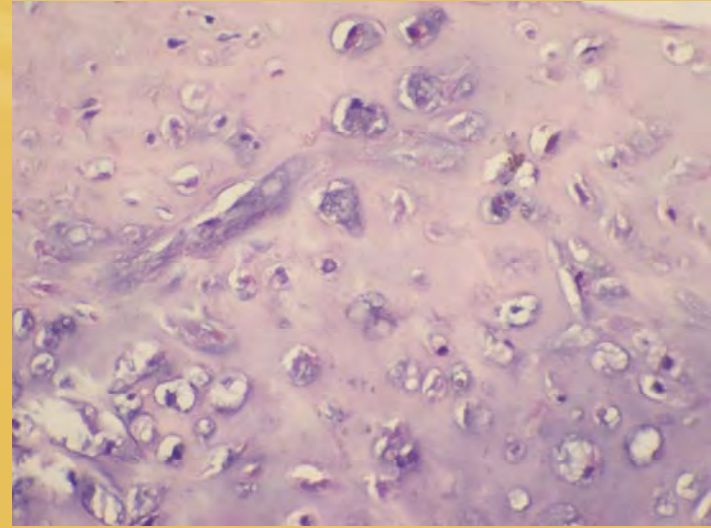
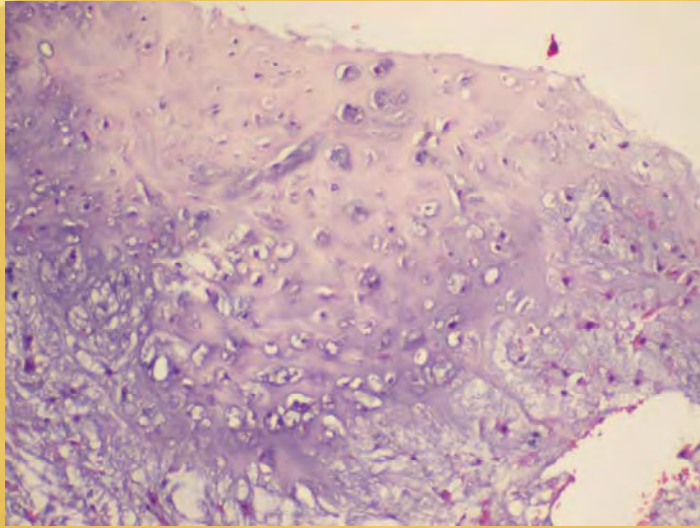
# Microscopic Examination -- 1



# Microscopic Examination -- 2



# Microscopic Examination -- 3





# Final Diagnosis

- **Chondrosarcoma**

**Oral cavity, Hard palate, Left, Incision**

