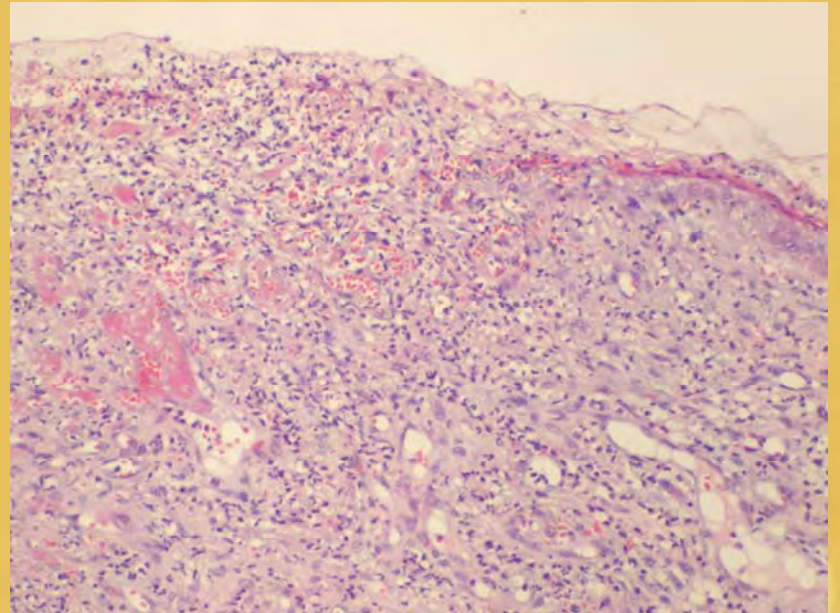
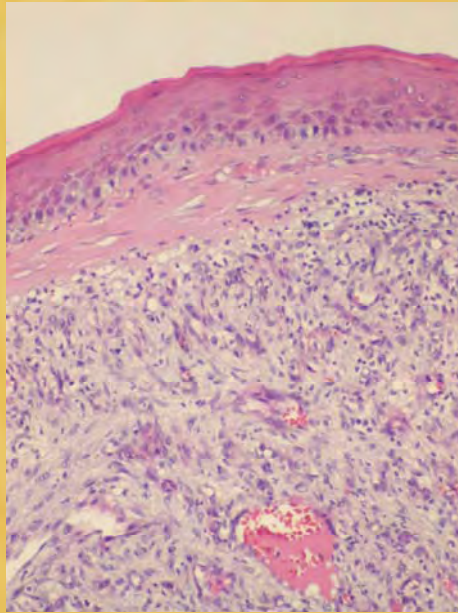
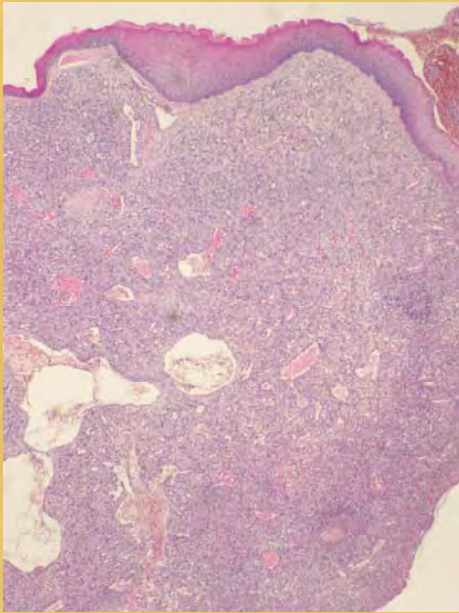




# Case 2

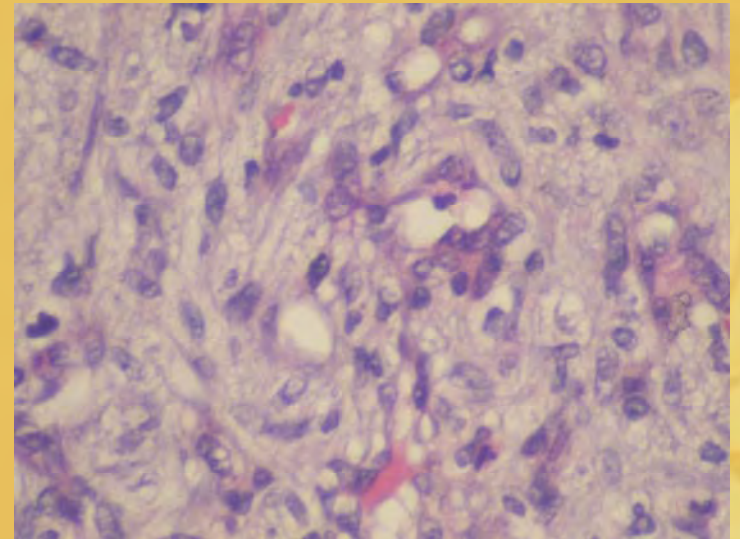
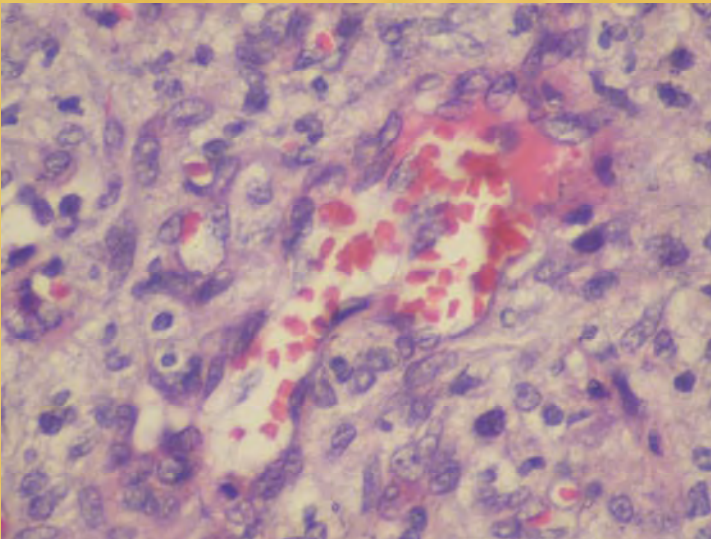
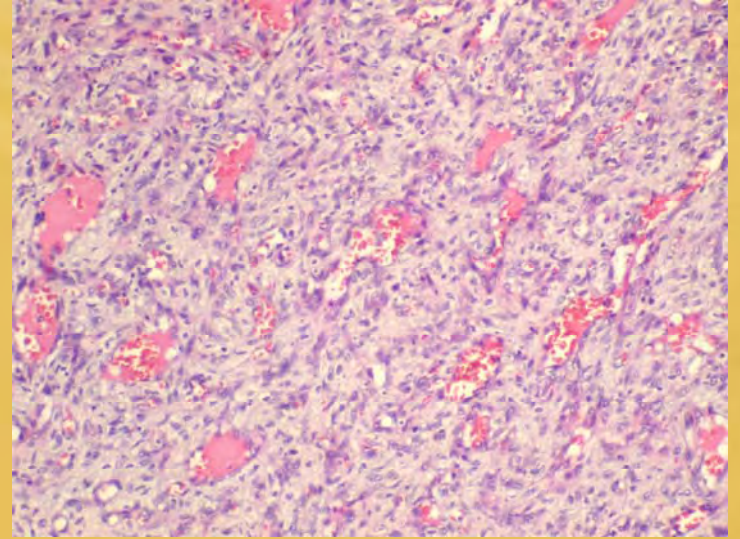
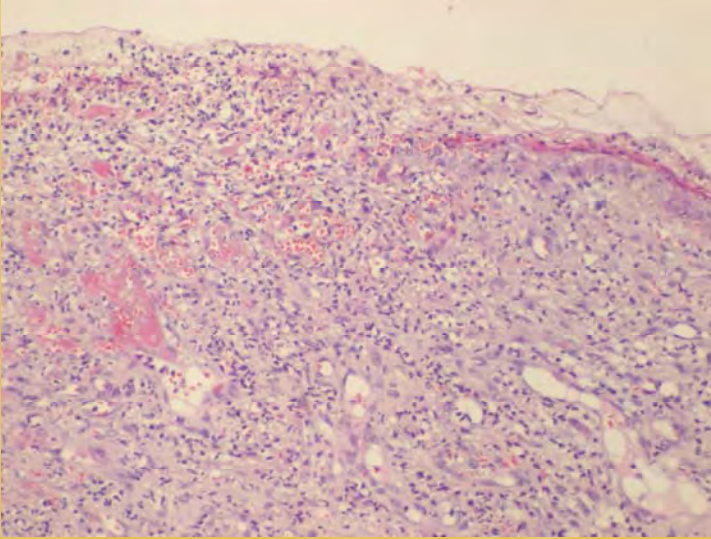


# Microscopic Examination -- 1





# Microscopic Examination -- 2





# Final Diagnosis

- **Pyogenic granuloma, atypical**  
**Oral cavity, Gingiva buccal, Upper Left,**  
**Excision**
- 