



Case Report

報告者：第六組

指導老師：口腔病理科全體醫師

報告日期：96/11/23

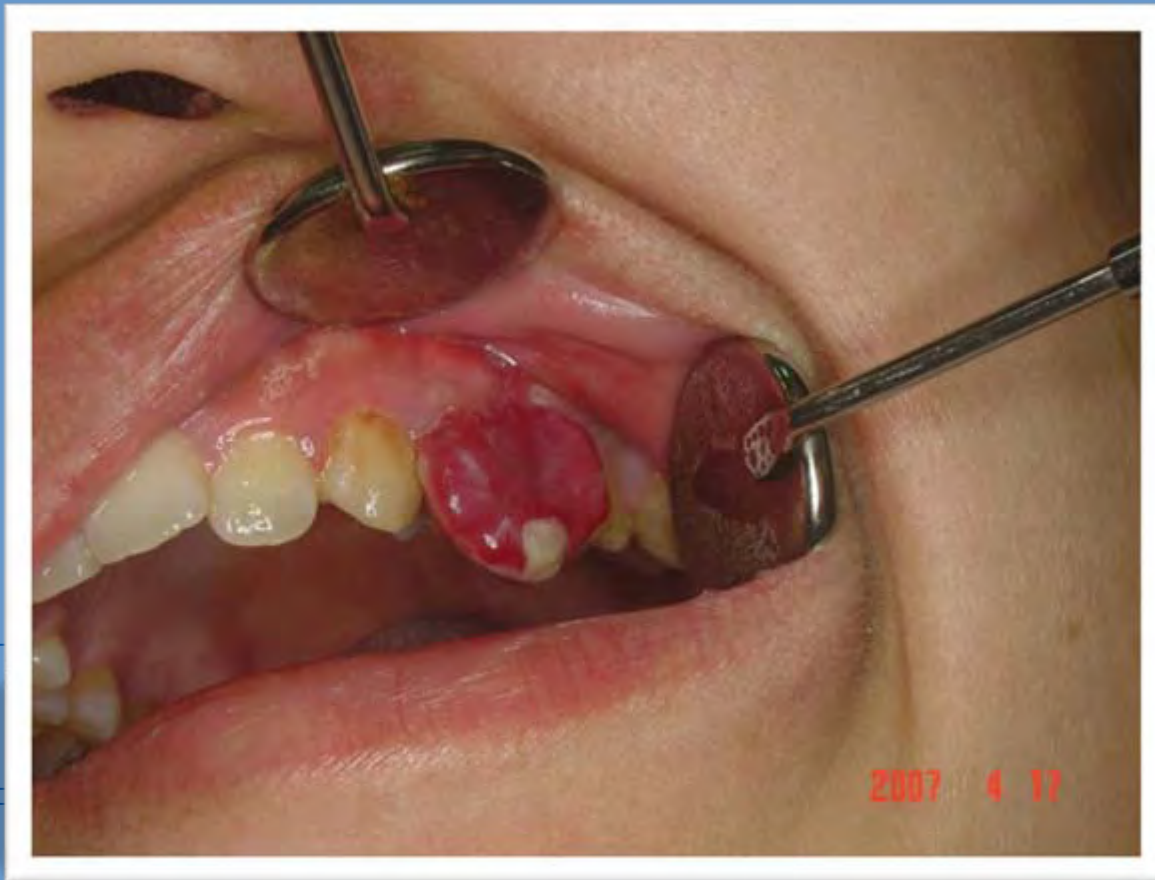

General Deta

- ✓ Name : XXX
- ✓ Sex : female
- ✓ Age : 26
- ✓ Native : 高雄
- ✓ Marrital status : married
- ✓ Attending Dr. : XXX
- ✓ First visit : XXX

Chief complaint


- ✓ A mass over left upper teeth





Present illness

- ✓ The 26 y/o female found that she had *a mass over buccal gingiva of tooth 24 · 25* in the beginning of March this year. And at 3/13 she did the biopsy examination. After a period of time, she found a mass at the same site, so she went to OS OPD for excision biopsy at 4/17. And the specimen was sent for H-P examination
- ✓ Pregnancy for 30 weeks





Past medical history

- ✓ 蕁麻疹
- ✓ 食物(鳳梨)過敏
- ✓ denied any drug history
- ✓ denied any systemic disease



Past dental history

- ✓ No record

Personal History

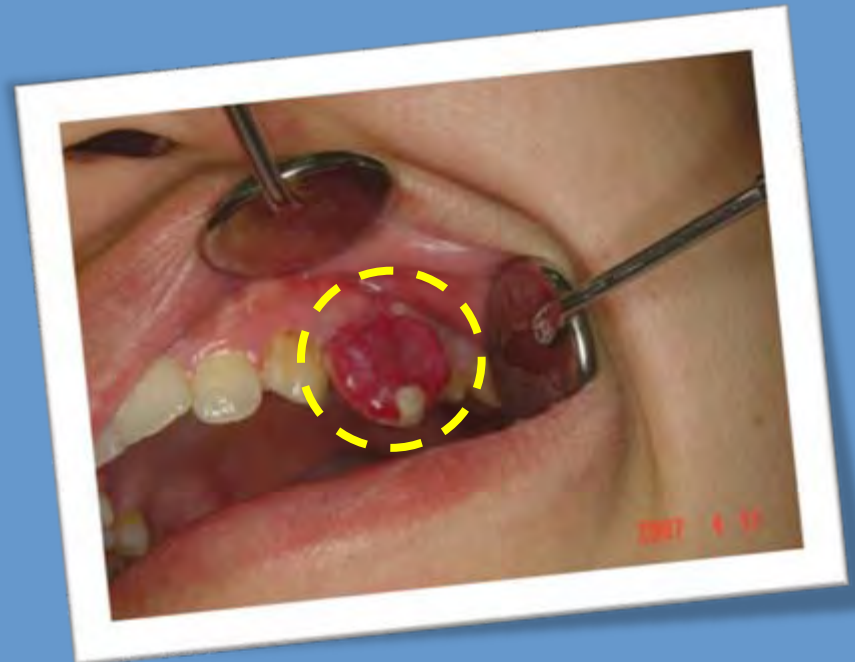
- ✓ Alcohol : (-)
- ✓ Betel quid : (-)
- ✓ Cigarette : (-)



Intraoral examination

✓ A dome-shaped swelling mass with ulcerated surface, measured approximately 1.2 cm x 1.6 cm in diameter located over 24 & 25 buccal gingiva.

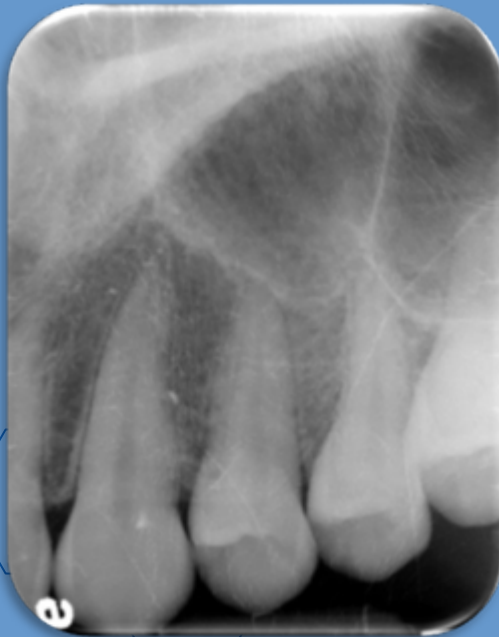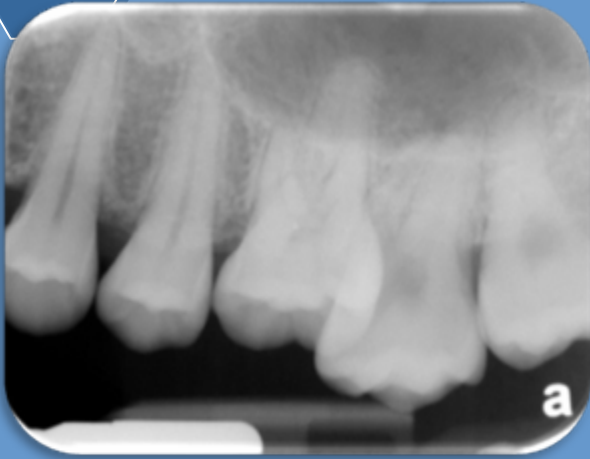
✓ Pedunculated base, red surface color and firm consistency





Intraoral examination

- ✓ Size : 1.2 cmx1.6 cm
- ✓ Color : red
- ✓ Pain : no record
- ✓ Tenderness : (+)
- ✓ Swelling : (+)
- ✓ Fixed : (+)
- ✓ Bleeding tendency : (+)
- ✓ Induration : (-)



Radiographic Examination —periapical film



- ✓ No bony destruction
- ✓ No separating teeth
- ✓ 27 supraeruption
- ✓ 26. 27 crowding



Different Diagnosis






Inflammation or cyst or neoplasm

- ✓ Redness : (+)
- ✓ Swelling : (+)
- ✓ Local heat : (-)
- ✓ Tenderness : (+)
- ✓ Fluctuation : (-)
- ✓ Induration : (-)
- ✓ Consistency : firm




→ **neoplasm or inflammation**



Intrabony or Peripheral

- ✓ No evidence of bony destruction or expansion
- ✓ Main lesion is gingival lesion


→ peripheral





Working Diagnosis

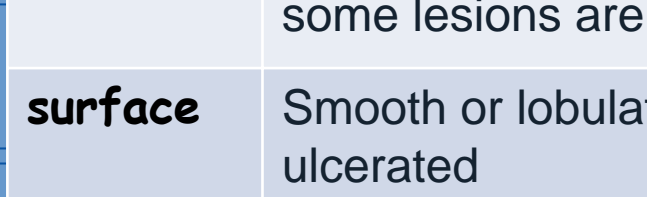
- ① Pregnancy tumor (Pyogenic granuloma)
- ② Peripheral giant cell granuloma
- ③ Peripheral ossifying fibroma
- ④ Hemangioma







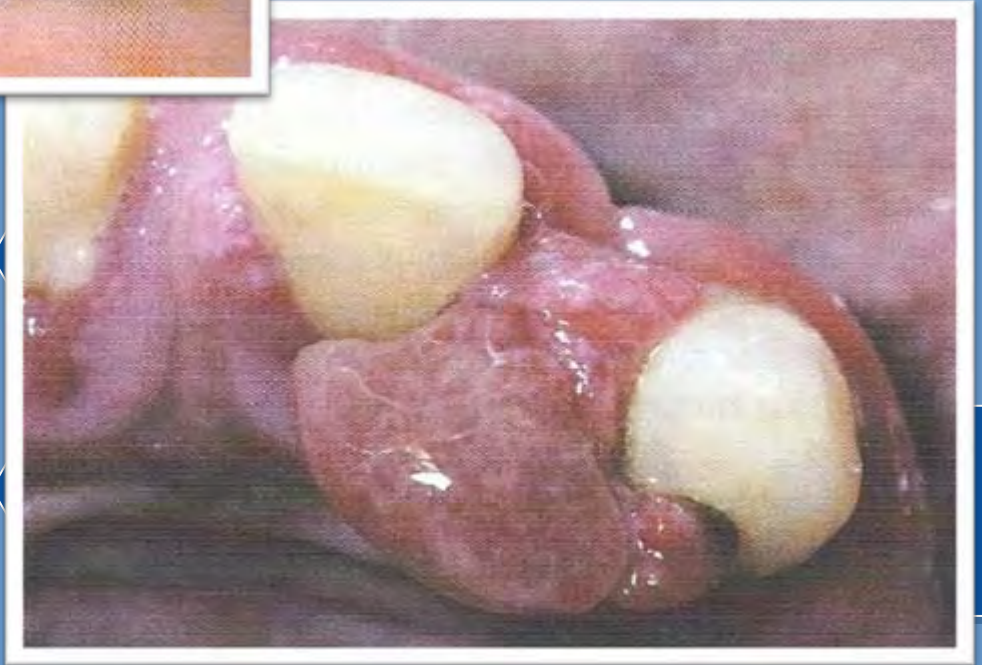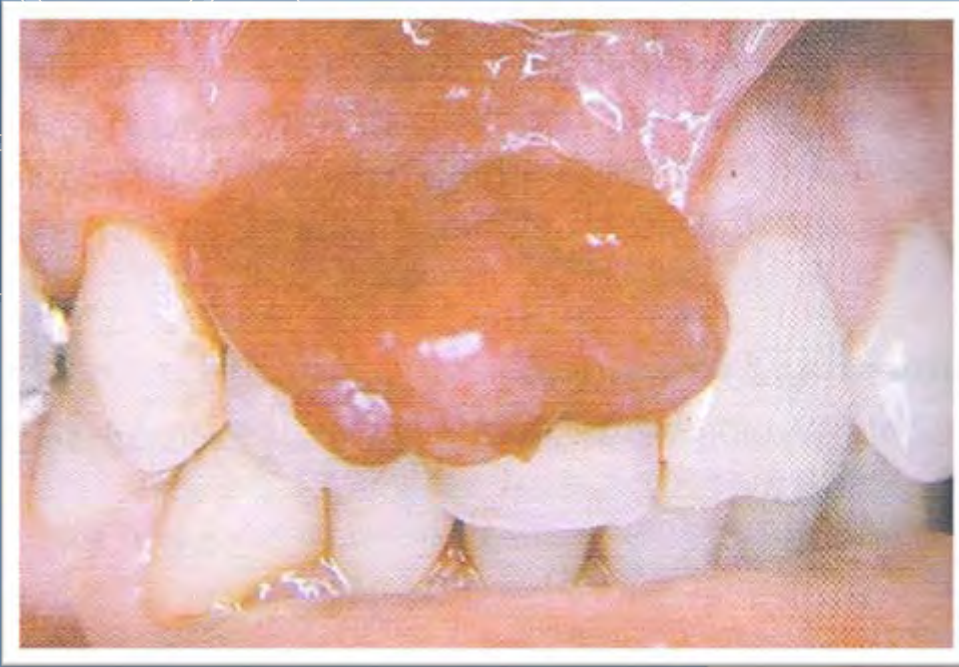
Pyogenic granuloma v.s. our case

| | Pyogenic granuloma | Our case |
|----------------|---|---|
| gender | female and second and third trimester pregnancy | <i>female and third trimester pregnancy</i> |
| size | 1 cmx1 cm~2 cmx2 cm | <i>1.2 cm x 1.6 cm</i> |
| site | interdental gingiva Maxilla>mandible Anterior>posterior Facial>lingual | <i>24, 25 buccal gingiva</i> |
| shape | usually pedunculated, although some lesions are sessile | Dome shape, <i>pedunculated</i> |
| surface | Smooth or lobulated, often ulcerated | <i>Smooth, ulcerated</i> |



Pyogenic granuloma v.s. our case

| | Pyogenic granuloma | Our case |
|--------------------|----------------------------|------------|
| color | From pink to red to purple | <i>red</i> |
| Bleeding | + | + |
| tenderness | ? | + |
| induration | ? | — |
| mobility | ? | fixed |
| consistency | ? | firm |
| Fluctuation | ? | — |





Peripheral giant cell granuloma v.s. Our case

| | Peripheral giant cell granuloma | Our case |
|---------------|--|-------------------------|
| Gender | 60% case occur in females | <i>Female</i> |
| Age | almost any age(50~60 y/o) | 26 y/o |
| Size | Most smaller than 2 cm in diameter | <i>1.2cm x 1.6 cm</i> |
| Site | <ul style="list-style-type: none">• develop in either the anterior or posterior regions of the gingival or edentulous alveolar ridge•Mandible more often than maxilla | 24 、 25 Buccal gingival |
| Shape | Sessile or pedunculated | Dome, pedunculated |
| Margin | Well-defined | <i>Well-defined</i> |

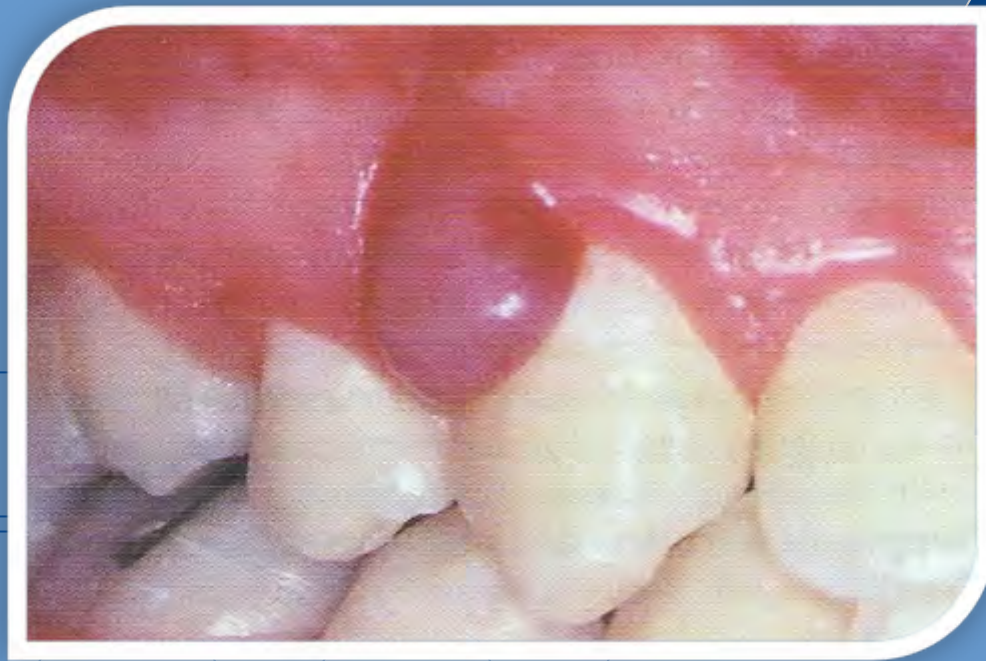
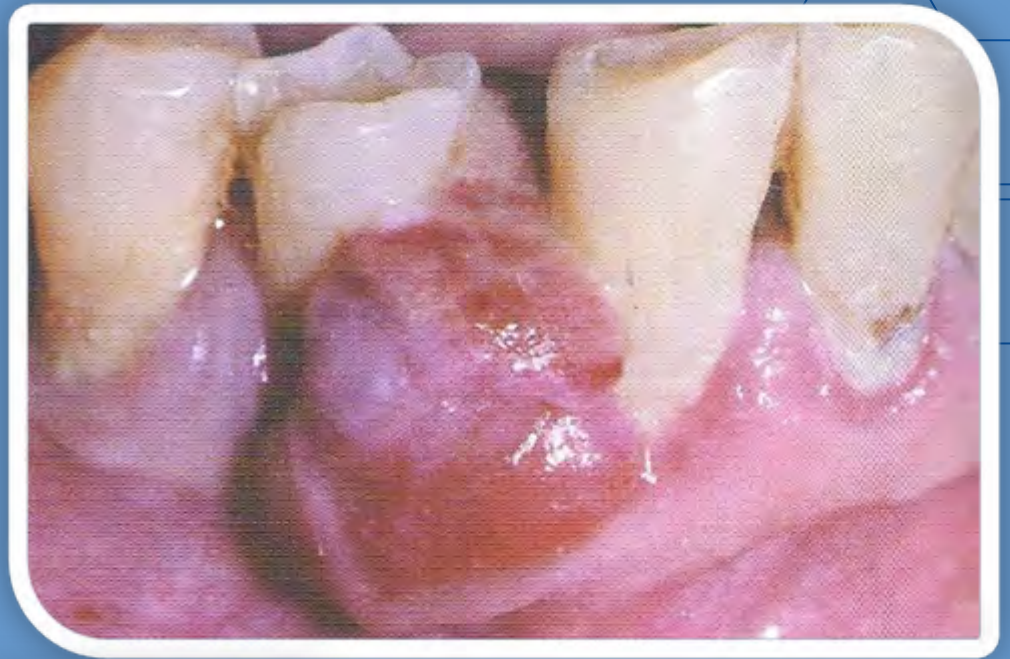

Peripheral giant cell granuloma v.s. Our case

| | Peripheral giant cell granuloma | Our case |
|--------------------|---------------------------------|------------|
| Consistency | ? | Firm |
| Color | Red or reddish-blue | <i>Red</i> |
| Ulcer | Ulcerated in 50% case | <i>+</i> |
| Induration | ? | - |
| Tenderness | + | <i>+</i> |
| Mobility | ? | Fixed |
| Surface | smooth | ulcerated |



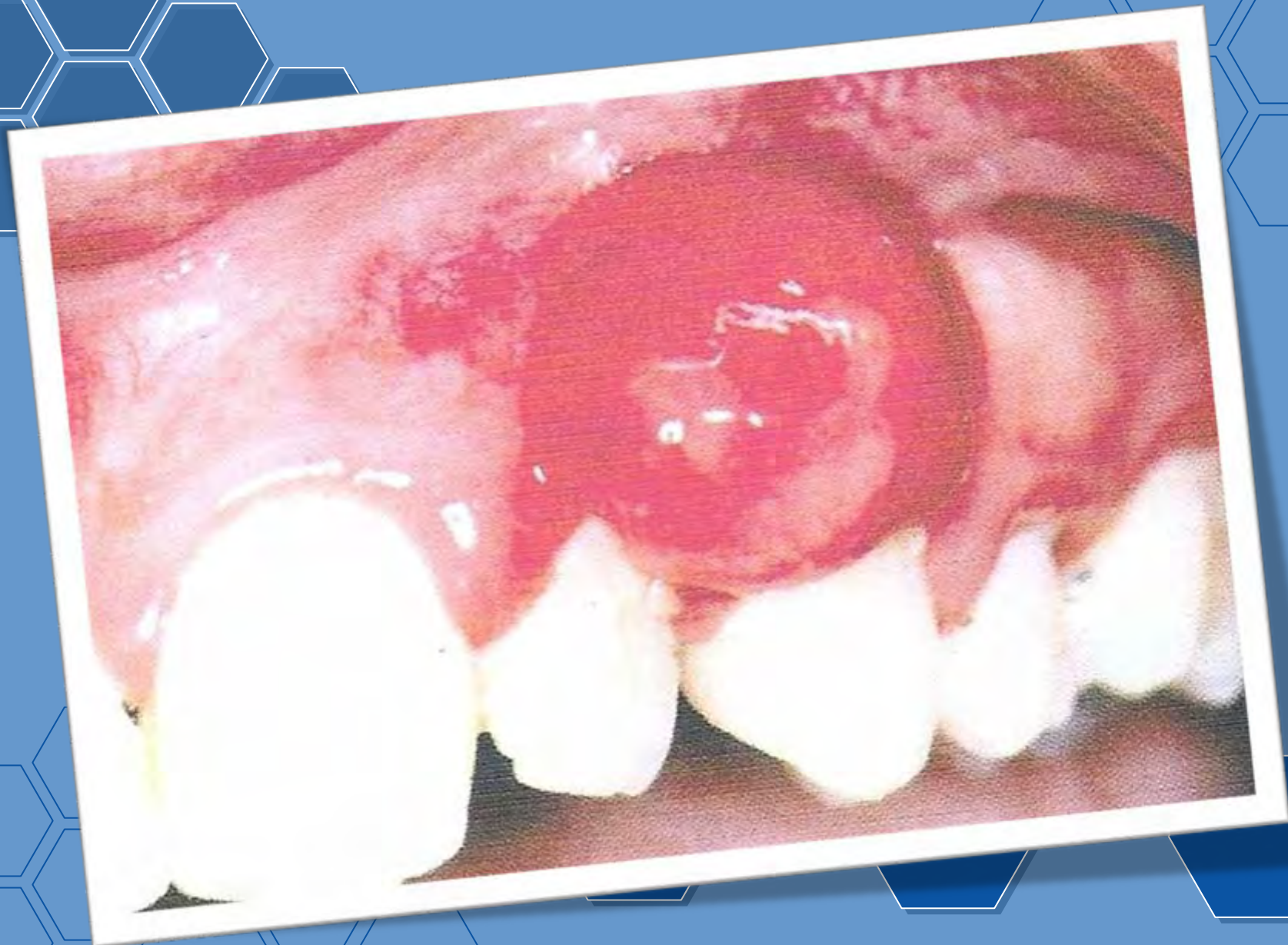Peripheral giant cell granuloma develops within soft tissue, "cupping" resorption of the underlying alveolar bone sometimes is seen.





Peripheral ossifying fibroma v.s. our case

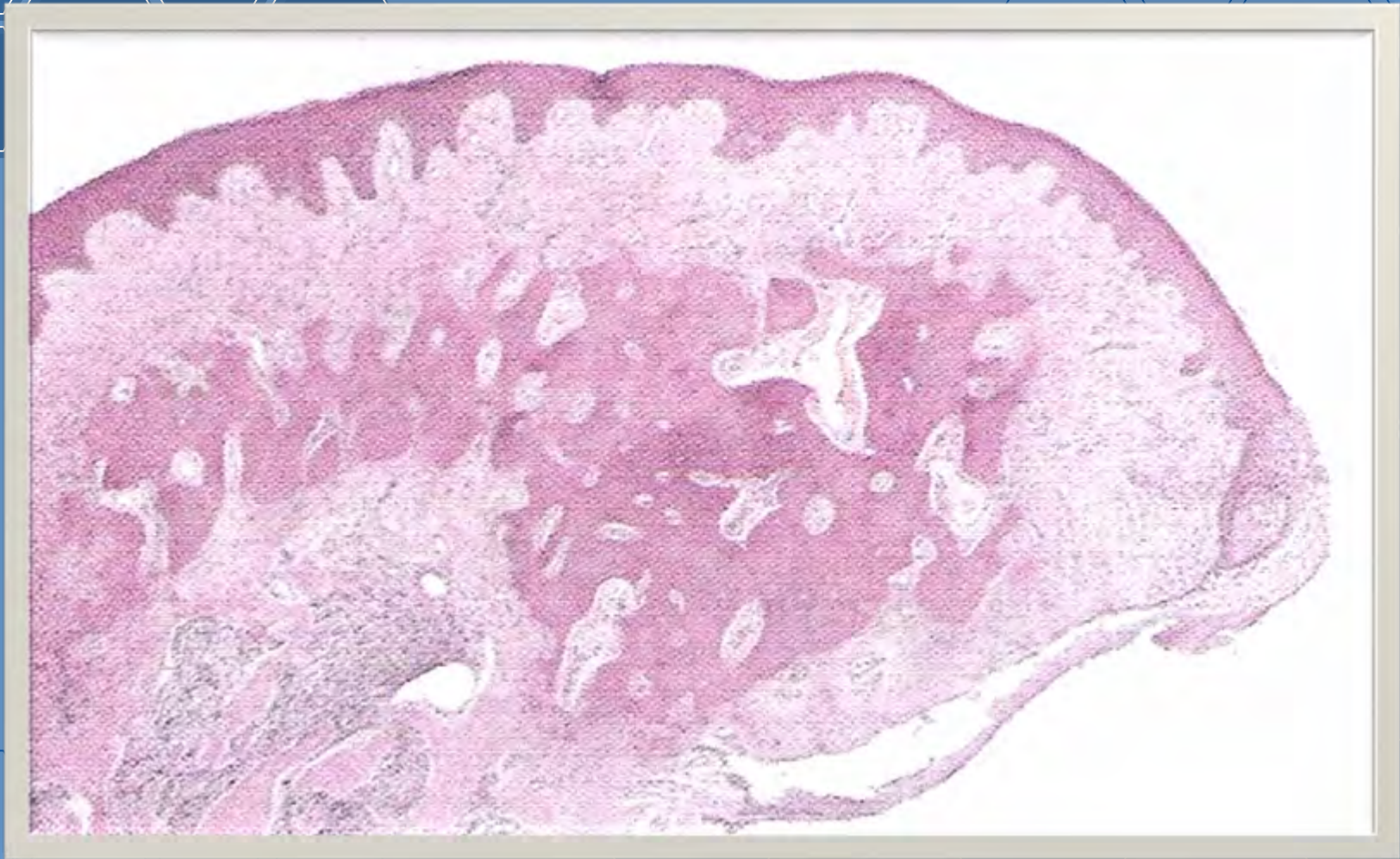
| | Peripheral ossifying fibroma | Our case |
|--------------------|---|-----------------------------|
| Gender | Female | <i>Female</i> |
| Age | Teenagers and young adults (peak prevalence : 10~19) | 26 y/o |
| Size | Less than 2 cm | <i>1.2cm X 1.6 cm</i> |
| Site | Interdental papilla Maxilla > mandible Anterior > posterior | 24、25 buccal gingiva |
| Shape | Nodular(pedunculated / sessile) | Dome(<i>pedunculated</i>) |
| Margin | Well-defined | <i>Well-defined</i> |
| Consistency | Firm | <i>firm</i> |
| Color | Red to pink | <i>Red</i> |





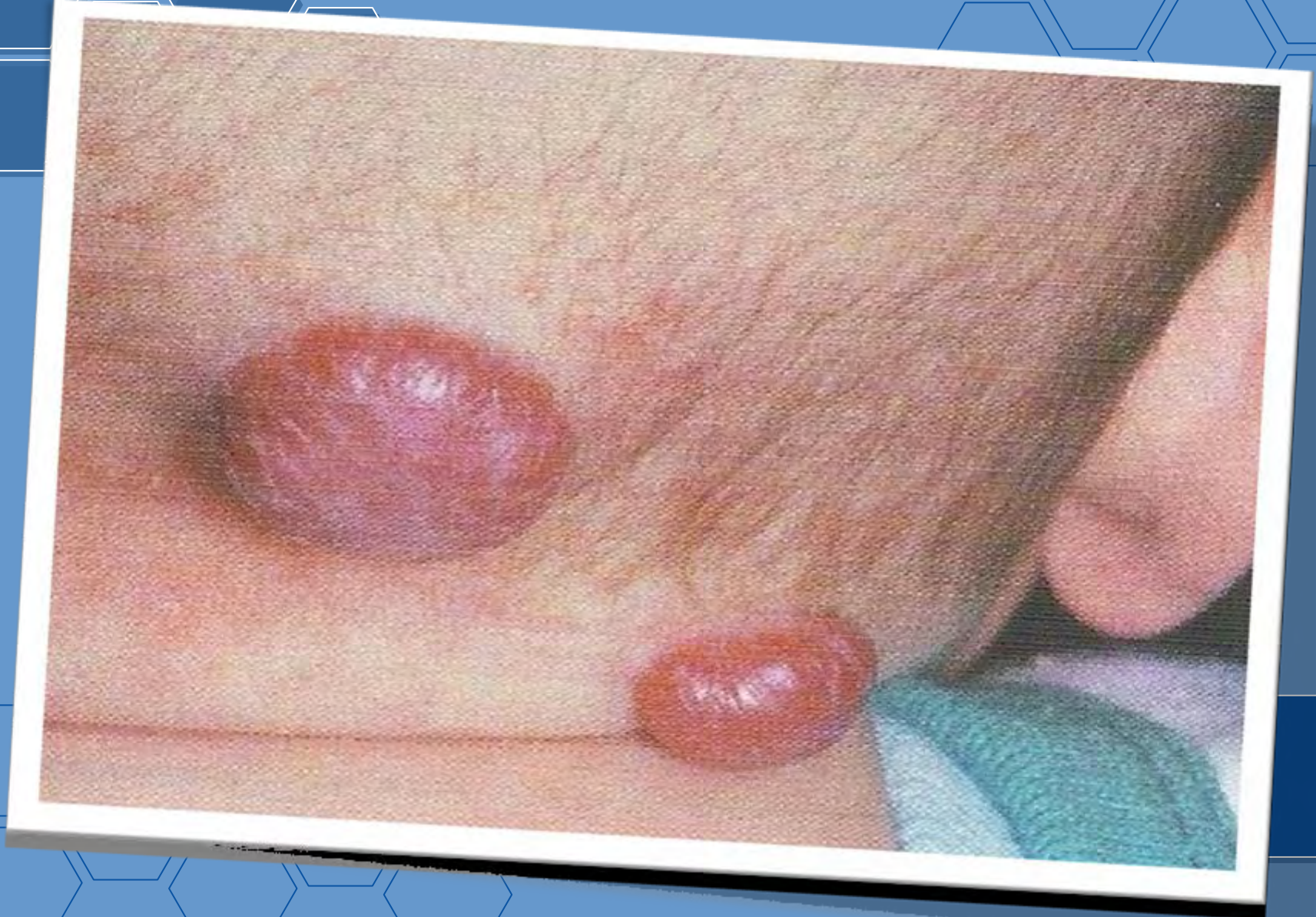Peripheral ossifying fibroma v.s. our case

| | Peripheral ossifying fibroma | Our case |
|----------------------|---------------------------------------|-------------------------|
| Fluctuation | (-) | (-) |
| Ulcer | +/- | (+) |
| Induration | (-) | (-) |
| Tenderness | ? | (+) |
| Mobility | Fixed | <i>Fixed</i> |
| Surface | Smooth Ulcerated (more frequently) | <i>Ulcerated</i> |
| Duration | Weeks or months | About more than 1 month |
| Bleeding | (-) | (+) |
| X-ray finding | R-O foci within the soft tissue mass | No R-O |



Hemangioma v.s. our case

| | Peripheral ossifying fibroma | Our case |
|--------------------|--|------------------------|
| Gender | Female | <i>Female</i> |
| Age | Infancy , 5~10% of 1 y/o | 26 y/o |
| Size | | 1.2cm X 1.6cm |
| Site | Head and neck | 24 、 25 buccal gingiva |
| Shape | Superior : bosselated Deeper : only slightly raised | Dome (pedunculated) |
| Margin | Well-defined | <i>Well-defined</i> |
| Consistency | Firm and rubbery | <i>Firm</i> |
| Color | Superficial : bright-red Deeper : bluish | <i>Red</i> |
| Bleeding | (+) | <i>(+)</i> |
| Fluctuation | | <i>(-)</i> |







Clinical Impression

Pregnancy tumor

(Pyogenic granuloma)





Thanks for your attention

