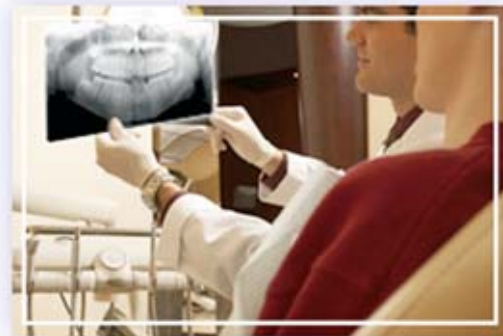

Non-syndrome Multiple Supernumerary Teeth: A Case Report

Kaan Gündüz, DDS, PhD; Mehtap Muğlali, DDS, PhD



Abstract

Aim: The purpose of this case report is to present a case of a non-syndrome male patient with multiple supplemental supernumerary teeth in three quadrants of his mouth.

Background: Supernumerary teeth are described as the teeth formed in excess of the number found in a normal dentition. Prevalence of supernumerary teeth varies between 0.1% and 3.8% in the general Caucasian population. Multiple supernumerary teeth are not a common occurrence, although a single or a few supernumerary tooth/teeth in each case have been widely reported in the literature.

Report: An 11-year-old male presented for a routine preventive dental visit. A routine panoramic radiograph showed the presence of multiple supernumerary teeth which were located in the maxillary right canine incisor region, the maxillary left premolar region, and the mandibular right premolar region. The family's medical history was non-contributory, and an extraoral examination did not reveal any abnormality.

Summary: It is rare to find multiple supernumerary teeth in individuals with no other associated diseases or syndromes. This case report presents a case of a non-syndrome male patient with multiple supplemental supernumerary teeth in three quadrants of his mouth.

Keywords: Non-syndrome, supernumerary teeth, multiple supernumerary teeth

Citation: Gündüz K , Muğlali M. Non-syndrome Multiple Supernumerary Teeth: A Case Report. J Contemp Dent Pract 2007 May;(8)4:081-087.

Introduction

Supernumerary teeth is a term used to describe more than the normal number of a full complement of teeth in either the primary or permanent dentitions.¹ Supernumerary teeth have been reported in the literature over the years as a well-recognized clinical phenomenon.² Multiple supernumerary teeth are associated with cleidocranial dysplasia and Gardner syndrome.^{2,3} However, it is rare to find multiple supernumeraries in individuals with no other associated disease or syndrome.³ In such cases the maxillary anterior region is the common site of occurrence.⁴

This case report presents a case of a non-syndromic male patient with multiple supplemental supernumerary teeth in three quadrants of his mouth.

Case Report

An 11-year-old male presented to the Oral Diagnosis and Radiology Clinic for routine control. Family medical history was non-contributory. Extraoral examination did not reveal any abnormality. A routine panoramic showed the presence of three supernumerary teeth which were located in the maxillary right canine incisor region, maxillary left premolar region, and the mandibular right premolar region (Figure 1).

A general physician was consulted who confirmed there was no associated syndrome. The situation was explained to the patient and his mother, and the patient was followed up through periodic examinations.

A follow up panoramic radiograph was taken after 12 months and revealed there were three separate supernumerary teeth located in the maxillary right molar and premolar regions and the maxillary left premolar region (Figure 2).

Periapical radiographs were then done to rule out the presence of supernumerary teeth (Figures 3, 4, 5, and 6). Inspection of the previous radiographs showed no signs of the other three supernumerary teeth. The patient and his mother were informed about the radiographic findings and counseled accordingly. A decision was made to wait and observe the patient.

Discussion

It is rare to find multiple supernumerary teeth with no associated diseases or syndromes. The few studies have found the prevalence of supernumerary teeth in permanent dentition to range from 0.15% to 3.8%.⁶ Scheiner⁷ reported an occurrence of 11.1% for multiple supernumerary teeth, while Asami⁸ found the prevalence for

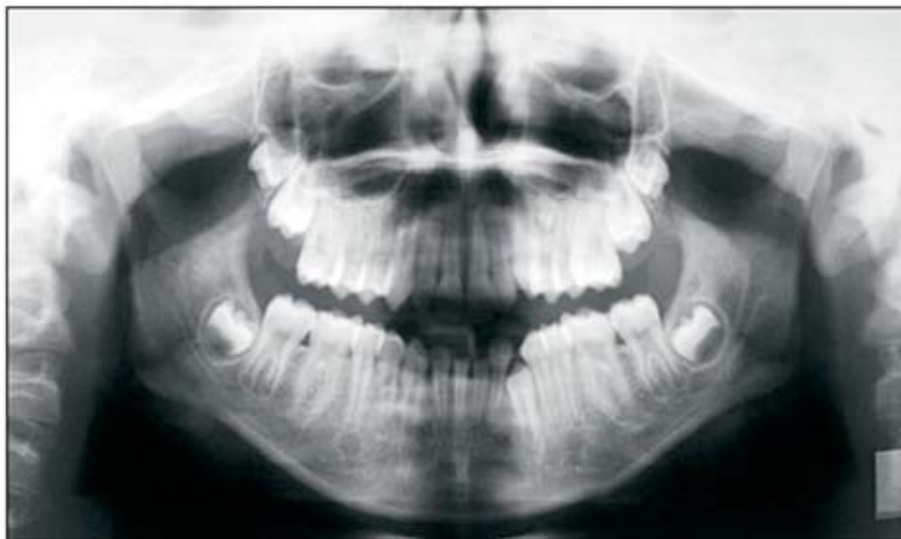

Figure 1. First panoramic radiograph of the patient at age 11 years showing the presence of three supernumerary teeth in both maxillary premolar regions and mandibular right premolar region.

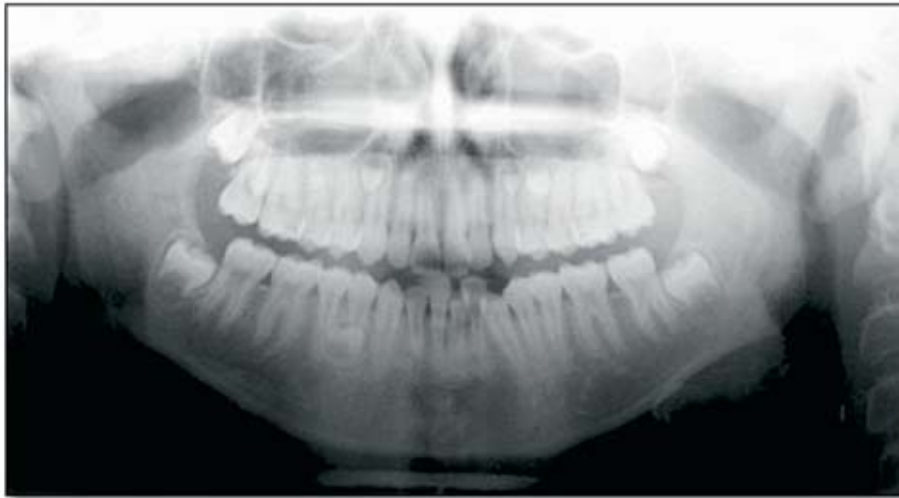


Figure 2. Panoramic taken at 13 years-of-age showing three distinct supernumerary teeth located in the maxillary right molar and premolar region and maxillary left premolar region.

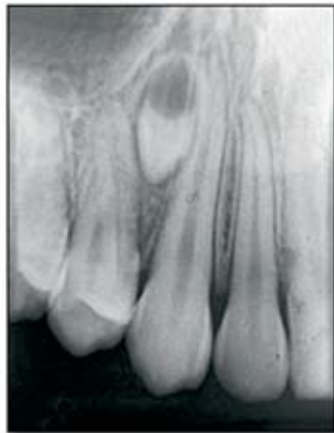

Figure 3. Periapical radiograph showing the presence of a supernumerary tooth located between the roots of the maxillary right first premolar and the canine.

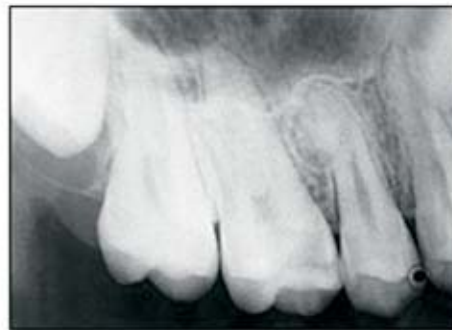

Figure 4. Periapical radiograph showing the presence of a supernumerary premolar tooth and a supernumerary molar tooth in right maxilla.

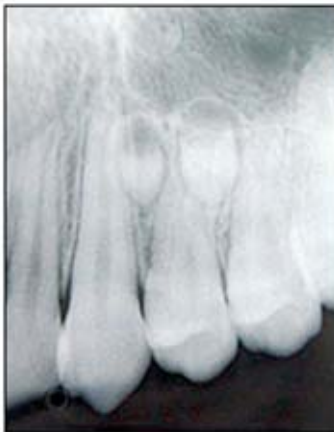

Figure 5. Periapical radiograph showing the presence of supernumerary teeth in the left maxilla.

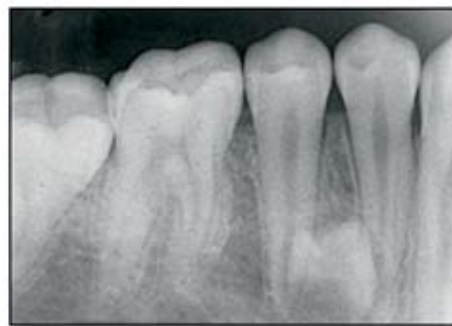

Figure 6. Periapical radiograph showing the presence of a supernumerary premolar tooth which was located between the roots of the mandibular right premolar teeth.

multiple supernumerary teeth to be 1%, and Arx⁹ found it to be 2%. However, where 'multiple supernumerary teeth' is taken to mean five or more supernumerary teeth, the prevalence has been reported as less than 1%.¹⁰ In the present case six supernumerary teeth were found, and three of them were formed at a later stage than other supernumerary teeth.

The exact etiology of supernumerary teeth is still unknown although many theories have been suggested. Two popularly accepted theories are as follows:

- The dichotomy theory of tooth germs is a concept in which the tooth bud is thought to split into two or different sized parts, resulting in two teeth of equal size or one normal and one dismorphic tooth, respectively. This hypothesis is supported by animal experiments in which split germs have been cultivated *in vitro*.¹¹
- The other theory suggests supernumerary teeth are formed as a result of local, independent, or conditioned hyperactivity of dental lamina.¹¹

Several researchers have also proposed multiple supernumerary teeth are part of a post permanent dentition.^{6,10} The exact mode of inheritance has not been established; however, a familial tendency has been noted.¹²

According to common opinion, multiple supernumerary teeth in the dental arch are mostly seen in the maxillary anterior region followed by the maxillary molar region.^{2,4,6} However, it has been reported multiple supernumerary teeth are very rarely seen, and the prevalence of supernumerary teeth in the premolar region has been reported as 0.2-10.9% in various studies.⁶ In this present case three of the six supernumerary teeth were seen in the premolar regions, while two supernumerary teeth were seen in the maxillary anterior region. Only one

supernumerary tooth was seen in the maxillary molar region.

It has been stated development of supernumerary teeth may cause various pathologies. Approximately 75% of supernumerary teeth are impacted and asymptomatic, and most of these teeth are diagnosed coincidentally during radiographic examination.⁶ Early diagnosis is important in order to minimize the risk of complications resulting from supernumerary teeth. If they have caused delay or non-eruption of permanent teeth, displacement of permanent teeth, root resorption of adjacent teeth due to the pressure and cystic formations, then extraction is recommended.¹⁻¹³ However, extraction of asymptomatic supernumerary teeth that do not affect the dentition may not always be necessary, but they should be followed through periodic examinations. Since there is a risk of tooth bud recurrence, extraction in these patients is still a remote possibility and follow-up on these patients is recommended.^{5-6,13}

In the present case an unexpected finding is the full complement of permanent dentition was present in normal occlusion with none of the associated potential problems. The patient was completely asymptomatic, and the presence of six supernumerary teeth was an incidental finding. As a result, the decision was made to observe the patient's progress over time.

Summary

Multiple supernumerary teeth are usually associated with syndromes but can occur, although rarely, without such an association. This case report presents a case of a non-syndrome male patient with multiple supplemental supernumerary teeth in three quadrants of his mouth. The importance of the use of a panoramic radiograph to evaluate a patient's condition is emphasized whenever a supernumerary tooth is detected irrespective of whether the patient has any syndrome or not.

References

1. Gorlin RJ, Goldman HM.(1970) Thoma's oral pathology. 6th edn. St Louis: C V Mosby Co.
2. Shafer WG, Hine MK, Levy BM. (1993) A textbook of Oral Pathology, 4th edn. Philadelphia: WB Saunders Co.; p.49.
3. Yusof WZ. Non syndrome multiple supernumerary teeth: literature review. J Can Dent Assoc 1990; 56: 147-149.
4. Hedge SV, Munshi AK. Late development of supernumerary teeth in premolar region: A case report. Quintessence Int 1996; 27: 479-481.
5. King NM, Lee AMP, Wan PKC. Multiple supernumerary premolars: their occurrence in three patients. Aust Dent J 1993; 38: 11-16.
6. Açıkgöz A, Açıkgöz G, Tunga U, Otan F. Characteristics and prevalence of non-syndrome multiple supernumerary teeth: a retrospective study. Dentomaxillofac Radiol 2006; 185-190.
7. Scheiner MA, Sampson WJ. Supernumerary teeth: a review of the literature and four case reports. Aus Dent J 1997; 42: 160-165.
8. Asaumi JI, Shibata Y, Yanagi Y, Hisatomi M, Matsuzaki H, Konouchi H, Kishi K. Radiographic examination of mesiodens and their associated complications. Dentomaxillofac Radiol 2004; 33: 125-127.
9. Arx T. Anterior maxillary supernumerary teeth: a clinical and radiographic study. Aus Dent J 1992; 37: 189-195.
10. Rajab LD, Hamdan MAM. Supernumerary teeth: a review of the literature and a survey of 152 cases. Int Pediatr Dent 2002; 12: 244-254.
11. Liu JF. Characteristics of premaxillary supernumerary teeth: A survey of 112 cases. ASDC J Dent Child 1995; 62:262-265.
12. Sedano HO, Gorlin R. Familial occurrence of mesiodens. Oral Surg, Oral Med, Oral Pathol 1969; 27: 360-362.
13. Mason C, Rule DC, Hopper C. Multiple supernumeraries: the importance of clinical and radiographic follow-up. Dentomaxillofac Radiol 1996; 25: 109-113.

About the Authors

Kaan Gündüz, DDS, PhD



Dr. Gündüz is an Associate Professor in the Department of Oral Diagnosis and Radiology of the Faculty of Dentistry at Ondokuz Mayıs University in Samsun, Turkey where he received his dental degree in 2000 and his doctorate in Oral Diagnosis and Radiology in 2006.

e-mail: kgunduz@omu.edu.tr

Mehtap Muğlalı, DDS



Dr. Muğlalı is an Associate Professor in the Department of Oral and Maxillofacial Surgery of the Faculty of Dentistry at Ondokuz Mayıs University in Samsun, Turkey. She received her dental degree in 1992 and her doctorate in 1998 from Ankara University in Ankara, Turkey.