



Anti-TNF- α induced mucous membrane pemphigoid-like disease

Giacomo Setti, DDS, MSc, PhD,^a Cristina Vaschieri, BS,^b Stefania Caramaschi, MD,^c Cristina Magnoni, MD, PhD,^d Ugo Consolo, MD, DDS,^a and Pierantonio Bellini, MD^a

Mucous membrane pemphigoid (MMP) is an autoimmune blistering disease affecting various mucous membranes, with rare skin involvement. We present a case of a 40-year-old woman with recurring desquamative gingivitis, implicating etanercept, an anti-TNF- α agent, in MMP-like lesions confined to the oral mucosa. Suspicion arose due to temporal correlation between drug administration and lesion onset, confirmed by recurrence upon resumption and resolution upon suspension. Laboratory findings supported MMP diagnosis. Notably, the patient had a history of autoimmune urticaria and axial spondylarthritis. A probable adverse drug reaction was established using the Naranjo scale. Possible mechanisms involve the role of TNF- α in MMP pathophysiology and its interaction with viral triggers, exemplified by severe acute respiratory syndrome-coronavirus 2 (SARS-CoV-2) infection. This case underscores the intricate relationship among autoimmune conditions, medications, and external factors in mucocutaneous disorders, advocating for comprehensive patient assessment and interdisciplinary collaboration for optimal management. (Oral Surg Oral Med Oral Pathol Oral Radiol YEAR;VOL:page range) (Oral Surg Oral Med Oral Pathol Oral Radiol 2024;138:e95–e100)

Mucous membrane pemphigoid (MMP) is a chronic, autoimmune disease causing subepithelial blistering disease involving a variety of mucous membranes, including the conjunctiva, oral cavity, genitals, and, more rarely, the larynx, esophagus, and trachea. Skin involvement is rare, but mild lesions may occur.¹

True incidence of MMP is uncertain; the incidence of ocular MMP is 0.8 per million per year in the United Kingdom and 0.7 per million per year for both Australia and New Zealand. Figures out of Germany and France in the last decade estimate an incidence of 2.0 and 1.8 per million, respectively.^{1,2} Moreover, women are affected more often than men (2:1). The average age of MMP onset is in the elderly population, between the sixth and the seventh decades of life; however, although rarely, the disorder can occur at any age, including in children and adolescents. To date, no ethnic or geographic predilections are known.^{1,3}

The oral MMP subtype has shown a predilection for a White ethnicity and an onset age between 54 and

76 years.⁴ Diagnostic delays have been reported, ranging from 2 to 60 months from development of the first symptoms to diagnosis.^{4–6} There is a high prevalence of other autoimmune disorders coexisting with MMP, as revealed by a retrospective evaluation of self-reported patient surveys, particularly autoimmune thyroid disease.⁴

The majority of MMP cases initially develop in the oral mucosa.¹ Oral involvement usually has a slow onset, characterized by episodes of spontaneous relapses and remissions. The gingiva is the most involved site (80%), followed by the buccal lining mucosa (58%), palate (26%), alveolar ridge (16%), tongue (15%), and lip (7%).^{1,5} Clinical manifestation as desquamative gingivitis represents the hallmark of oral MMP, although other differential diagnoses (e.g., lichen planus and pemphigus vulgaris) should be excluded^{1,5}; appearance of lesions varies from mild, scattered, and tiny red patches to generalized erythema.¹ Blisters rupture easily, leaving erosions with irregular shapes surrounded by an inflammatory halo and covered by a pseudo-membrane. Scarring is uncommon. A wide variety of symptoms, including soreness, pain, bleeding, and sensations of mucosal shedding, are reported.^{1,5} The overall symptomatology leads to insufficient oral hygiene, facilitating the onset of plaque-related gingivitis and, later, chronic periodontitis.⁷

BP180 (collagen XVII) and laminin 332 are the main autoantigens of MMP, with a linear deposition of IgG, IgA, and/or C3 along the epithelial basement membrane zone (BMZ) as a peculiar feature.^{5,8} Even though MMP's pathophysiology still needs to be clarified, in vitro and in vivo studies have elucidated how the inflammatory response arises as a consequence of the loss of tolerance to BMZ proteins, resulting in the generation of plasma cells that produce circulating IgG

^aDepartment of Surgical, Medical, Dental, and Morphological Science, University of Modena and Reggio Emilia, Modena, Italy.

^bDermoLAB, Department of Surgical, Medical, Dental and Morphological Science, University of Modena and Reggio Emilia, Modena, Italy.

^cDepartment of Medical and Surgical Sciences for Children and Adults, University of Modena and Reggio Emilia, Modena, Italy.

^dDermatology Unit, Department of Surgical, Medical, Dental and Morphological Sciences, University of Modena and Reggio Emilia, Modena, Italy.

Corresponding author: Giacomo Setti. E-mail address: giacomo.setti@unimore.it

Received for publication Mar 23, 2024; returned for revision Jun 26, 2024; accepted for publication Jul 4, 2024.

© 2024 The Author(s). Published by Elsevier Inc. This is an open access article under the CC BY-NC-ND license (<http://creativecommons.org/licenses/by-nc-nd/4.0/>)

2212-4403/\$-see front matter

<https://doi.org/10.1016/j.oooo.2024.07.002>

and/or IgA autoantibodies.^{1,3} Severe manifestations of the disease are related to the presence of both isotypes directed against laminin 332 or BP180⁹ and are characterized by the presence of autoantibodies targeting multiple epitopes on BP180.¹⁰

TNF- α , a pro-inflammatory cytokine, is involved in inflammation and the immune response via the triggering of important inflammatory pathways, such as NF κ B and MAPK, through binding to the TNF receptor 1 (TNFR1) or TNF receptor 2 (TNFR2).¹¹ TNF- α becomes elevated in psoriasis, rheumatoid arthritis, psoriatic arthritis, juvenile idiopathic arthritis, ankylosing spondylitis, pemphigus vulgaris, and bullous pemphigoid (BP).¹² TNF- α blockers (or anti-TNF- α) are biologic drugs involved in the treatment of several diseases, such as psoriasis vulgaris, rheumatoid arthritis, inflammatory bowel disease, pemphigus vulgaris, and unresponsive skin BP.^{13,14}

Etanercept is a genetically engineered fusion protein composed of a dimer of the extracellular portions of human TNF-R2 fused to the Fc portion of human IgG.¹⁵ It acts as a soluble TNF-receptor capable of binding cytokine-forming unstable complexes with TNF- α trimers, inhibiting their binding to TNF-R1 and TNF-R2.¹⁵ Adverse reactions of anti-TNF- α , including the manifestation of BP, are described in the literature, and different hypotheses have been proposed to explain their pathogenesis.¹³ Herein, a case of a suspected TNF- α -induced, oral MMP-like disorder is reported.

CASE PRESENTATION

In December 2022, a 40-year-old White woman was referred to the oral medicine service to investigate a recurring desquamative gingivitis. She reported an outbreak since November 2022 of gingival inflammation and mucosal bullae that leave no scars when collapsing and completely recover in 5 days or less. She had a history of autoimmune urticaria, severe axial spondylarthritis, hypothyroidism, and episodes of fever and allergy to non-steroidal anti-inflammatory drugs. The patient was also following a program for medically assisted reproduction.

The patient's drug history was disclosed: anti-TNF- α etanercept (Benepali), 50 mg every 1 week hypodermically for 21 months; omalizumab (Xolair), an mAb that binds to and neutralizes IgE, 150 mg hypodermically, every 2 months for 1 year; buprenorphine (Busette), an opioid transdermal patch, every 1 month for 2 years; rupatadine (Pafinur), an antihistamine, 10 mg, 1 per day; and levothyroxine (Tirosint), a hormonal substitute, 125 mg daily.

The patient reported the first outbreak of oral lesions during an episode of symptomatic severe acute respiratory syndrome-coronavirus 2 (SARS-CoV-2) infection.

Moreover, she reported an improvement in her oral mucosal condition after etanercept suspension. The patient was not vaccinated against SARS-CoV-2, refusing to receive the vaccination despite recommendations.

The oral examination showed overall gingival inflammation along with lesions including erosions, bullae, and membranes likely corresponding to blisters roofs, involving both the gingiva and lining mucosa (Figure 1A, 1B, and 1C); the Nikolsky sign was negative. Extraoral examination revealed neither lesions nor bullae involving the nasal mucosa or conjunctiva. Other than the known autoimmune urticaria, no skin lesions were disclosed on the scalp, arms, trunk, or legs.

Considering the patient's medical and drug history as well as the oral findings and symptoms, an adverse drug reaction (ADR) was suspected.

Two tissue samples were taken while the patient was under local anesthesia to perform histological examination as well as direct immunofluorescence (DIF). In addition, indirect immunofluorescence (IIF) and enzyme-linked immunosorbent assay (ELISA) tests were performed on the patient's serum. Hematoxylin and eosin staining described a squamous mucosa with acanthosis, accompanied by subepithelial cleft and preserved basal cells; fibrosis, reactive vascular proliferation, and mild chronic infiltrate are present in the subepithelial connective tissue (Figure 2A). Moreover, DIF resulted positive for IgG and C3 along the basement membrane, and IIF revealed a positive IgG titer on monkey esophagus substrate (dilution 1:10; Figure 2B, 2C, 2D, and 2E). Moreover, an ELISA for IgG autoantibodies against BP180 and BP230 yielded 52.64 U/mL and 2.43 U/mL, respectively (the cut off value was 9 U/mL). Considering the whole laboratory results, the diagnosis of MMP was suggested.

During follow-up, the potential association between etanercept injection and blister development was directly observed. The patient was taking 1 dose/week as prescribed for axial spondylarthritis, and lesions systematically reappeared 2 or 3 days after injection (see Table I). Conversely, another mandatory 3-week etanercept interruption led to mucosal healing and no new blisters (Figure 1D, 1E, and 1F). A 1:1 galenic formulation of clobetasol propionate 0.05% in Orabase to create a tailor-made mouthguard was prescribed; administration was then slowly adjusted from twice-a-day to 1 to 3 applications a week until November 2023. Nystatin mouthwashes were also prescribed.

Other than the reported suspensions, etanercept injections were regularly administered 1 per week from the beginning of follow-up (12 months); during such period, MMP-like lesions chronically arose but were alleviated by the topical therapy, as were the other

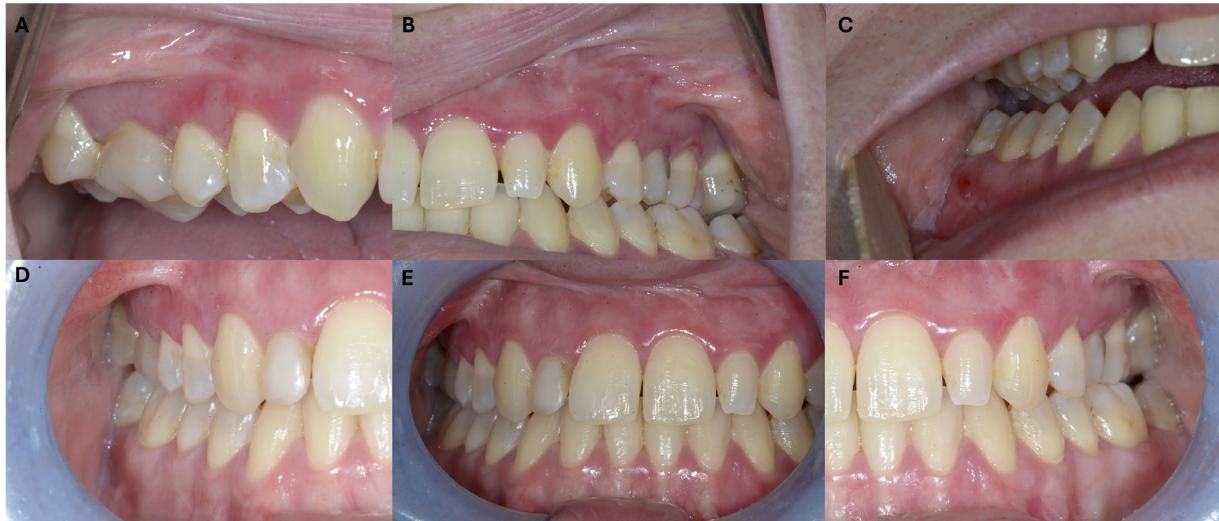

Fig. 1. (A) Generalized gingival inflammation accompanied by erosions, blisters, and their remnants affecting gingiva, right side. (B) Generalized gingival inflammation accompanied by erosions, blisters, and their remnants affecting gingiva, left side. (C) Generalized gingival inflammation accompanied by erosions, blisters, and their remnants affecting both the gingiva and lining mucosa, right side. (D) Clinical pictures taken following a 3-week interruption of etanercept treatment, right side. (E) Clinical pictures taken following a 3-week interruption of etanercept treatment, midline. (F) Clinical pictures taken following a 3-week interruption of etanercept treatment, left side.

symptoms. Since December 2023, axial spondylarthritis treatment was switched to certolizumab pegol (Cimzia), an anti-TNF- α administered twice a month; the switch did not prevent lesions from developing but resulted in less frequent manifestations.

DISCUSSION

The observed correlation between the onset of lesions and the timing of etanercept injections, along with the consistent recurrence and resolution of blisters upon drug interruption and resumption, supports the likelihood of their association. Moreover, the positive laboratory findings, including histology, DIF, IIF, and ELISA, provide further evidence supporting the diagnosis of MMP of the oral subtype.

To the best of our current knowledge, this case presents a novel occurrence of MMP-like lesions attributed to anti-TNF- α treatment, uniquely characterized by the isolated involvement of the oral mucosa.

Pemphigoid-like lesions are known but infrequent ADRs, most of them involving the skin and, rarely, the mucosae only. Zhang et al. (2022) reported 17 cases of drug-induced skin BP,¹³ of which 3 directly connected to etanercept,^{16–18} in 1 case of a 65-year-old woman undergoing treatment with 25 mg etanercept twice weekly for more than 2 years, only the oral cavity was involved.¹⁷

TNF- α seems to play an important role in BP and its serum levels correlate with disease severity.¹⁹ Moreover, an in vitro observation suggests that the chemokine (e.g., TNF- α plus IL-4 or INF- γ)

microenvironment can influence cultured eosinophils to alternatively secrete Th1 and Th2 chemokines.²⁰ Thus, TNF- α can also induce altered immune responses dominated by Th1 or Th2, depending on the micro immune profile (i.e., the levels of IL-4 and INF- γ). Such shifting in Th1/Th2 response can promote autoreactive B cells proliferation, as well as the class-switching of autoantibodies, a dominant immune type in BP development.^{13,20}

So far, 3 main hypotheses can provide a likely explanation about the TNF- α mechanism of action inducing BP. The first hypothesis is based on the increase in cell apoptosis that was found in patients exposed to anti-TNF- α therapies; in this event, novel autoantigens become available, leading to autoantibody formation.^{13,21} The second hypothesis considers the imbalance in cytotoxic T cell responses caused by anti-TNF- α ; such an effect directly affects the reduction in autoreactive B cell suppression, leading to autoantibody production.^{13,21} Third, TNF- α directly interacts with the BMZ proteins with a mechanism of binding and modification, favoring the susceptibility of such structures to immune attack.^{13,21}

In the presented case, BP180 antigen exposure or changes in the autoimmune/inflammatory microenvironment concomitant or subsequent to SARS-CoV-2 infection could have accelerated the immune response driven by etanercept, resulting in a recurrent disease along with drug exposure.^{13,16,21,22}

Even considering the complexity of this patient's autoimmune condition, it is possible to attribute the

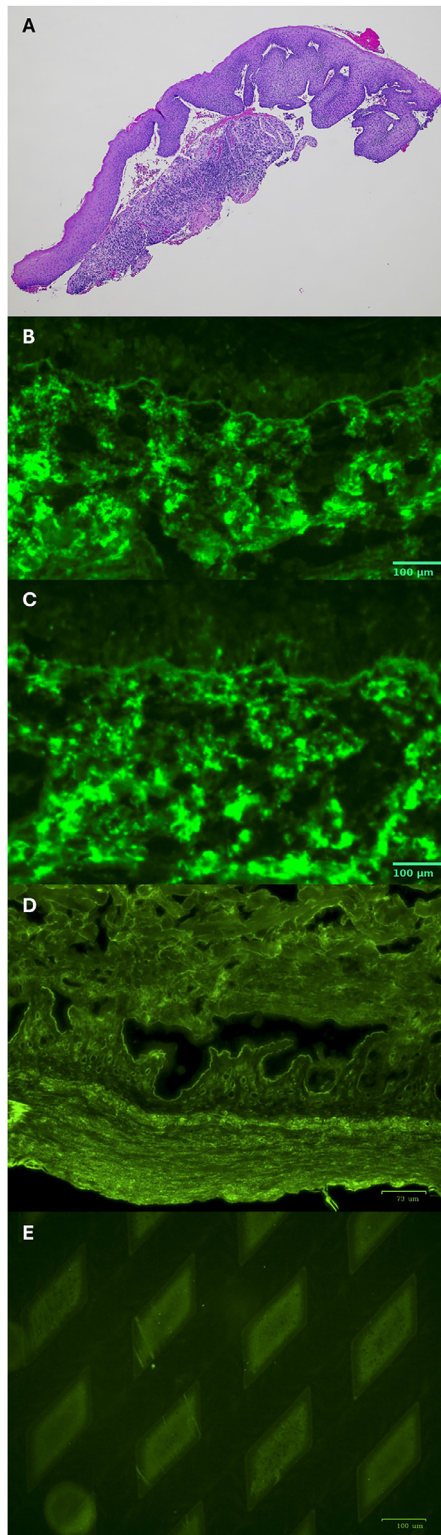


Fig. 2. (A) Squamous mucosa with acanthosis, accompanied by subepithelial cleft and preservation of basal cells; fibrosis, reactive vascular proliferation, and mild chronic infiltrate are present in the subepithelial connective tissue. Hematoxylin and eosin (H&E) staining, 4 times. (B) Direct immunofluorescence. Anti-human-IgG FITC (1:10; Agilent Technologies, Glostrup, Denmark) show linear deposition on peri-

MMP-like lesions to an ADR.⁴ The several etanercept interruptions satisfy the challenge–de-challenge–re-challenge criteria; moreover, a “probable” score (7 of 13) was obtained on the Naranjo scale system for estimating the probability of an ADR.^{21,23} The Naranjo scale was proposed in 1981 to provide a simple method to help standardize the assessment of causalities from ADRs in a variety of clinical situations. Its systematic application to different cases of suspected ADRs has provided reliable answers.²³ The tool consists of 10 questions answered as “Yes,” “No,” or “Do not know”; each answer is assigned a different point value (-1, 0, +1, and +2) and the final score is assigned a probability outcome. Namely definite (≥ 9), probable (5 to 8), possible (1 to 4), or doubtful (≤ 0). Questions are designed to evaluate the correlation between ADR development and time and/or exposure, as well as dose dependence or placebo effect.

In contrast to other causality assessment tools, such as the global introspection method (the World Health Organization—Uppsala Monitoring Centre scale²⁴) or probabilistic method,²⁵ the Naranjo scale is designed to reduce intra-rater and inter-rater variability, making its outcomes more reliable and valid. However, none of the available causality assessment tools have been universally accepted as the gold standard; each tool suffers intrinsic limitations as well as disagreement emerging from their compared applications.²⁶ The literature suggests a link between viral infections and autoimmune responses, involving several potential mechanisms, such as molecular mimicry, persistent antigenic stimuli, central tolerance breach, and nonspecific bystander activation.^{27–29} The dysregulation of pro-inflammatory cytokines associated with viral infections is likely implicated in the initiation of autoimmune reactions.³⁰ The role of SARS-CoV-2 infection as a trigger influencing the patient’s response to anti-TNF- α was considered. Only a few reports of BP induced by SARS-CoV-2 were available, accounting for hyper-autoimmunity and hyper-inflammation sustained by IL-6 and IL-13,³¹ as well as IL-1B, IL-17, and TNF- α ³² upregulation. These same cytokines have been implicated in BP’s pathogenesis.³³ In addition, reported cases of BP induced by the SARS-CoV-2 vaccination attribute the disease’s development at first to the involvement of

lesional mucosa at the epithelial-connective junction. (C) Direct immunofluorescence. Anti-human-C3 FITC (1:20 respectively, Agilent Technologies, Glostrup, Denmark) show linear deposition on peri-lesional mucosa at the epithelial-connective junction. (D) Indirect immunofluorescence. Salt split skin highlight linear positivity on the roof of the blister. (E) NC16a coating substrate on BIOCHIP (Dermatology Mosaic 7, EUROIMMUN, Germany); fluorescent rhombus shape are recognizable.

Table I. Pathological disease course, main events, and timeline

July 16, 2021	Treatment for axial spondylitis with etanercept (TNF- α inhibitor) prescribed by the rheumatologist.
November 2, 2022	Etanercept administration suspended following guidelines due to symptomatic COVID-19 infection (-CoV-2). Patient reported manifestation of gingival lesions and inflammation during the -CoV-2 disease, with complete mucosal healing achieved in 5 days.
November 26, 2022	SARS-CoV-2 Infection negativization
November 30, 2022	Resumption of etanercept injection at 1 per week.
December 5, 2022	Administration of anti-pneumococcal and anti-influenza vaccinations carried out without interruption of etanercept therapy. Oral blistering lesions developed.
December 12, 2022	Clinical evaluation by the Oral Medicine Service. According with primary care physician, etanercept was suspended.
December 30, 2022	Complete recovery of oral mucosa health achieved after 2 weeks of etanercept suspension. No new blisters or desquamative gingivitis observed.
January 2, 2023	Resumption of etanercept injection at 1 per week.
January 4, 2023	Mucosal and gingival inflammation, along with blisters, detected. Drug injection suspended again for 2 weeks.
January 21, 2023	Complete resolution of oral lesions seen after suspension of etanercept. No new blisters or desquamative gingivitis observed.
January 23, 2023	Resumption of etanercept injection at 1 per week.
January 25, 2023	Multiple gingival blisters appeared.
December 15, 2023	Therapy for axial spondylarthritis switched from Benepali (etanercept) to Cimzia (certolizumab pegol).

COVID-19, coronavirus disease 2019; SARS-CoV-2, severe acute respiratory syndrome-coronavirus 2.

extracellular antigens/epitopes (BP180-NC16A domain), with a serological model dominated by BP180 antibodies.³⁴ A recent observation hypothesized a molecular similarity between the viral spike protein and BMZ-specific structures (e.g., BP180 and BP230) to explain 2 cases of BP outbreak after receiving the first vaccination dose.³⁵ On the other hand, no reports of interactions between anti-TNF- α and SARS-CoV-2 infection concerning the manifestation of a bullous disease are available in the literature.

CONCLUSION

The case presented in this study highlights the complex interplay between autoimmune conditions, medication use, and external triggers, such as viral infections in the manifestation of mucocutaneous disorders.

Overall, this case underlines the importance of comprehensive patient evaluation, including thorough medication history and consideration of potential triggers, in the diagnosis and management of mucocutaneous disorders. Collaborative efforts between different specialists are crucial for optimizing patient care and improving outcomes in patients with complex autoimmune conditions.

FUNDING

The authors declare that no funding was received for this research.

DECLARATION OF INTEREST

None.

CREDIT AUTHORSHIP CONTRIBUTION STATEMENT

Giacomo Setti: Writing – review & editing, Writing – original draft, Methodology, Conceptualization. **Cristina Vaschieri:** Writing – original draft, Investigation. **Stefania Caramaschi:** Writing – review & editing, Investigation. **Cristina Magnoni:** Writing – review & editing, Supervision. **Ugo Consolo:** Supervision. **Pierantonio Bellini:** Writing – review & editing, Supervision.

REFERENCES

- Du G, Patzelt S, van Beek N, Schmidt E. Mucous membrane pemphigoid. *Autoimmun Rev.* 2022;21:103036.
- Wertenteil S, Garg A, Strunk A, Alloo A. Prevalence estimates for pemphigoid in the United States: a sex-adjusted and age-adjusted population analysis. *J Am Acad Dermatol.* 2019;80:655-659.
- Kridin K. Subepidermal autoimmune bullous diseases: overview, epidemiology, and associations. *Immunol Res.* 2018;66:6-17.
- Lee J, Seiffert-Sinha K, Attwood K, Sinha AA. A retrospective study of patient-reported data of bullous pemphigoid and mucous membrane pemphigoid from a US-based registry. *Front Immunol.* 2019;10:2219.
- Rashid H, Lamberts A, Borradori L, et al. European guidelines (S3) on diagnosis and management of mucous membrane pemphigoid, initiated by the European Academy of Dermatology and Venereology - Part I. *J Eur Acad Dermatol Venereol.* 2021;35:1750-1764.
- Sultan AS, Villa A, Saavedra AP, Treister NS, Woo SB. Oral mucous membrane pemphigoid and pemphigus vulgaris—a retrospective two-center cohort study. *Oral Dis.* 2017;23:498-504.
- Jascholt I, Lai O, Zillikens D, Kasperkiewicz M. Periodontitis in oral pemphigus and pemphigoid: a systematic review of published studies. *J Am Acad Dermatol.* 2017;76:975-978. e973.

8. Schmidt E, Rashid H, Marzano AV, et al. European guidelines (S3) on diagnosis and management of mucous membrane pemphigoid, initiated by the European Academy of Dermatology and Venereology - Part II. *J Eur Acad Dermatol Venereol.* 2021;35:1926-1948.
9. Bernard P, Antonicelli F, Bedane C, et al. Prevalence and clinical significance of anti-laminin 332 autoantibodies detected by a novel enzyme-linked immunosorbent assay in mucous membrane pemphigoid. *JAMA Dermatol.* 2013;149:533-540.
10. Oyama N, Setterfield JF, Powell AM, et al. Bullous pemphigoid antigen II (BP180) and its soluble extracellular domains are major autoantigens in mucous membrane pemphigoid: the pathogenic relevance to HLA class II alleles and disease severity. *Br J Dermatol.* 2006;154:90-98.
11. Mocci G, Marzo M, Papa A, Armuzzi A, Guidi L. Dermatological adverse reactions during anti-TNF treatments: focus on inflammatory bowel disease. *J Crohns Colitis.* 2013;7:769-779.
12. D'Auria L, Mussi A, Bonifati C, Mastroianni A, Giacalone B, Ameglio F. Increased serum IL-6, TNF-alpha and IL-10 levels in patients with bullous pemphigoid: relationships with disease activity. *J Eur Acad Dermatol Venereol.* 1999;12:11-15.
13. Zhang J, Wang SH, Zuo YG. Paradoxical phenomena of bullous pemphigoid induced and treated by identical biologics. *Front Immunol.* 2022;13:1050373.
14. Canizares MJ, Smith DI, Connors MS, Maverick KJ, Heffernan MP. Successful treatment of mucous membrane pemphigoid with etanercept in 3 patients. *Arch Dermatol.* 2006;142:1457-1461.
15. Fantuzzi F, Del Giglio M, Gisondi P, Girolomoni G. Targeting tumor necrosis factor alpha in psoriasis and psoriatic arthritis. *Expert Opin Ther Targets.* 2008;12:1085-1096.
16. Wilmer EN, Becker N, Chen A, Kroupouzou G. Etanercept-induced generalization of chronic, localized, anogenital bullous pemphigoid in a psoriatic patient. *JAAD Case Rep.* 2016;2:25-27.
17. Bordignon M, Belloni-Fortina A, Pigozzi B, Tarantello M, Alai-bac M. Bullous pemphigoid during long-term TNF-alpha blocker therapy. *Dermatology.* 2009;219:357-358.
18. Kluk J, Goulding JM, Bhat J, Finch TM. Drug-induced bullous pemphigoid: cases triggered by intravenous iodine and etanercept. *Clin Exp Dermatol.* 2011;36:871-873.
19. Boussemart L, Jacobelli S, Batteux F, et al. Autoimmune bullous skin diseases occurring under anti-tumor necrosis factor therapy: two case reports. *Dermatology.* 2010;221:201-205.
20. Liu LY, Bates ME, Jarjour NN, Busse WW, Bertics PJ, Kelly EA. Generation of Th1 and Th2 chemokines by human eosinophils: evidence for a critical role of TNF-alpha. *J Immunol.* 2007;179:4840-4848.
21. de Nicolas-Ruanes B, Ballester-Martinez A, Garcia-Mouronte E, Berna-Rico E, Azcarraga-Llobet C, Fernandez-Guarino M. From molecular insights to clinical perspectives in drug-associated bullous pemphigoid. *Int J Mol Sci.* 2023;24:16786.
22. Liu Y, Li L, Xia Y. BP180 is critical in the autoimmunity of bullous pemphigoid. *Front Immunol.* 2017;8:1752.
23. Naranjo CA, Busto U, Sellers EM, et al. A method for estimating the probability of adverse drug reactions. *Clin Pharmacol Ther.* 1981;30:239-245.
24. Meyboom RHB, Hekster YA, Egberts ACG, Gribnau FWJ, Edwards IR. Causal or casual? *Drug Safety.* 1997;17:374-389.
25. Théophile H, Arimone Y, Miremont-Salamé G, et al. Comparison of three methods (consensual expert judgement), (algorithmic and probabilistic approaches) of causality assessment of adverse drug reactions. *Drug Safety.* 2010;33:1045-1054.
26. Shukla AK, Hraj R, Misra S, Ahmed SN, Nanda M, Chaudhary D. Agreement between WHO-UMC causality scale and the Naranjo algorithm for causality assessment of adverse drug reactions. *J Family Med Prim Care.* 2021;10:3303-3308.
27. Gianani R, Sarvetnick N. Viruses, cytokines, antigens, and autoimmunity. *Proc Natl Acad Sci U S A.* 1996;93:2257-2259.
28. Marcuzzi A, Melloni E, Zauli G, et al. Autoinflammatory diseases and cytokine storms-imbalance of innate and adaptive immunity. *Int J Mol Sci.* 2021;22:11241.
29. Rojas M, Restrepo-Jimenez P, Monsalve DM, et al. Molecular mimicry and autoimmunity. *J Autoimmun.* 2018;95:100-123.
30. Sundaresan B, Shirafkan F, Ripperger K, Rattay K. The role of viral infections in the onset of autoimmune diseases. *Viruses.* 2023;15:782.
31. Oya K, Kakurai M, Izumi K, Ishii N, Nomura T. Bullous pemphigoid with autoantibodies against full-length BP180 protein after COVID-19 infection. *J Eur Acad Dermatol Venereol.* 2023. 37:e1266-e1267.
32. Olson N, Eckhardt D, Delano A. New-onset bullous pemphigoid in a COVID-19 patient. *Case Rep Dermatol Med.* 2021;2021:5575111.
33. Riani M, Le Jan S, Plee J, et al. Bullous pemphigoid outcome is associated with CXCL10-induced matrix metalloproteinase 9 secretion from monocytes and neutrophils but not lymphocytes. *J Allergy Clin Immunol.* 2017;139:863-872. e863.
34. Zou H, Daveluy S. Pemphigus vulgaris after COVID-19 infection and vaccination. *J Am Acad Dermatol.* 2022;87:709-710.
35. Gambichler T, Hamdani N, Budde H, et al. Bullous pemphigoid after SARS-CoV-2 vaccination: spike-protein-directed immunofluorescence confocal microscopy and T-cell-receptor studies. *Br J Dermatol.* 2022;186:728-731.