Clinical pathologic conference case: An older woman with a painless, deep, and indurated ulcer on her mandibular alveolar mucosa

Sharon J. Akrish, DDS,[a,b,c] Adi Rachmiel, DMD,[a,c] Imad Abu El-Naaj, DMD,[d] and Ofer Ben-Izhak, MD[b,c]

(Oral Surg Oral Med Oral Pathol Oral Radiol 2020;129:3−7)

CLINICAL PRESENTATION

A 79-year-old female presented to her oral surgeon with a 3 × 2 cm indurated ulcerated mass on her mandibular left alveolar mucosa and a palpable enlarged submandibular lymph node, which were present for 2 weeks (Figure 1). Four years earlier, the patient had been diagnosed with diffuse large B-cell lymphoma of the germinal center type, involving the liver and spleen. At that time, treatment consisted of 6 cycles of (R-CHOP) chemotherapy. The patient was in remission at the time of presentation.

CLINICAL DIFFERENTIAL DIAGNOSIS

In the oral cavity, a clinically asymptomatic and indurated deep ulcer, especially with an enlarged cervical lymph node, is highly suspicious for a malignancy of either hematolymphatic origin (lymphoma) or epithelial origin (squamous cell carcinoma). Other clinical entities that present with a similar clinical appearance include traumatic ulcerative granuloma with eosinophilia (TUGSE), deep fungal infection, and post-transplant lymphoproliferative disorder (PTLD). TUGSE is a chronic, benign, self-limiting lesion of the oral mucosa with an unclear pathogenesis. Although it may appear at any intraoral site, the most common location is the tongue. Treatment is local and following a biopsy procedure, spontaneous resolution is seen. Within the oral cavity, deep fungal infections that present as an indurated, deep ulcer include histoplasmosis and mucormycosis. Intraoral cases are relatively rare and usually appear with the disseminated form of the disease, primarily in immunocompromised patients. A differentiating feature from the current case presented is that most cases are symptomatic, painful lesions. PTLD is a lymphoid proliferation or lymphoma that develops in immunocompromised patients after they receive a solid organ or bone marrow allograft. Evidence shows that the majority of PTLD are caused by an Epstein-Barr virus (EBV) infection. About 20% to 30% of PTLD cases occur in the head and neck region. Within the oral cavity, the common location is the tongue, palate, and gingiva.

MICROSCOPIC AND RADIOGRAPHIC FEATURES (FIGURES 2−5)

Microscopic features

An excisional biopsy was conducted, and the tissue specimen was sent to the pathology department. The tissue sections showed ulcerated mucosa with polymorphous, dense, mixed inflammatory infiltrate, a few apoptotic cells, and scattered large pleomorphic blasts reminiscent of Reed-Sternberg cells. The atypical B-lymphocytes were found at the base of the ulcer, without deep extension, and stained positive for CD30 and latent membrane protein-1 (LMP-1) of EBV, partially expressed CD20 and PAX-5, and were negative for CD79a, BCL-6, and cytokeratin. EBV positivity was also identified by using EBV-encoded RNA-1 in situ hybridization. Numerous CD3-positive small T lymphocytes and CD68-positive histiocytes surrounded the atypical B lymphocytes. Ki-67 showed brisk cell proliferation of the atypical B cells. The tissue specimen was also sent for polymerase chain reaction (PCR) analysis, which is a standard tool for distinguishing polyclonal B-cell populations from monoclonal B-cell populations. PCR analysis revealed monoclonal IgH rearrangement.

Radiographic features (Figure 6)

Panoramic radiography did not show intraosseous changes or infiltration, although the CT scan revealed an enlarged submandibular lymph node.

DIAGNOSIS AND MANAGEMENT

On the basis of the microscopic and immunophenotypic features, together with the lack of deep extension of the atypical B lymphocytes, a diagnosis of

[a]Department of Oral and Maxillofacial Surgery, Rambam Medical Center, Bat Galim, Haifa, Israel.
[b]Department of Pathology, Rambam Medical Center, Bat Galim, Haifa, Israel.
[c]Technion School of Medicine, Bat Galim, Haifa, Israel.
[d]Department of Oral and Maxillofacial Surgery, Baruch Padeh Medical Center, Faculty of Medicine, Bar Ilan University, Galilee, Israel.
Received for publication Feb 5, 2018; returned for revision May 24, 2018; accepted for publication May 30, 2018.
© 2018 Elsevier Inc. All rights reserved.
2212-4403/$-see front matter
https://doi.org/10.1016/j.oooo.2018.05.050

Fig. 1. Clinical photograph from the left maxillary alveolar mucosa with an indurated, deep ulcer.

EBV-positive mucocutaneous ulcer (EBV-MUC) was rendered. As the patient is currently not taking immunosuppressive medications, it is suspected that her advanced age is the contributing factor in the development of EBV-MUC.

Following the biopsy procedure, no further treatment was rendered. Six months later, there was nearly complete resolution of the lesion with a small area of residual leukoplakia and scar tissue. There was no evidence of a recurrence or lymph node enlargement (Figure 7); therefore, it was decided to continue monitoring the patient on frequent recall appointments and spare her any further surgeries at this time.

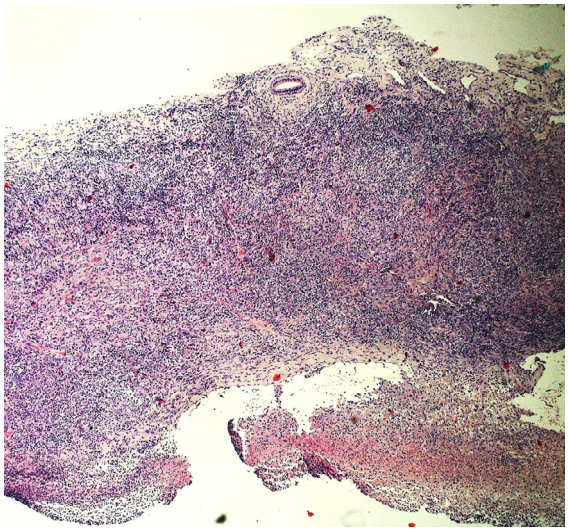

Fig. 2. Epstein-Barr virus−positive mucocutaneous ulcer (EBV-MUC). **A,** Low-power view showing an ulcerated fragment of loose fibrous connective tissue with an intense inflammatory reaction without deep extension. (hematoxylin and eosin [H&E], original magnification × 40). **B,** Higher-power view of the polymorphous, dense, mixed inflammatory infiltrate (H&E, original magnification × 100).

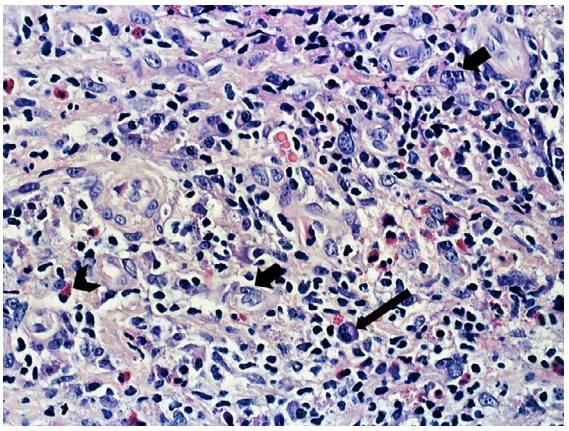

Fig. 3. Epstein-Barr virus−positive mucocutaneous ulcer (EBV-MUC). High-power view of the inflammatory infiltrate with large atypical B lymphocytes and some large pleomorphic lymphoid blasts reminiscent of Reed-Sternberg cells *(short black arrows)*, binucleated plasma cells *(long black arrow)*, and numerous scattered eosinophils *(black arrowhead)*. (hematoxylin and eosin [H&E], original magnification × 200)

DISCUSSION

EBV-MUC is a distinctive, localized, and self-limiting type of EBV lymphoproliferative disorder. It is found in patients with various causes of immunosuppression, which include advanced age, AIDS, immunosuppressive medications, and transplantatioin.[1]

Microscopic differential diagnosis

Distinguishing EBV-MUC from the more aggressive and systemic PTLD is essential because of the different treatment regimens. Unlike PTLD, EBV-MUC manifests as isolated mucosal lesions. In addition, EBV-MUC does not present with increased whole blood EBV DNA, even though tissue specimens positively express EBV-encoded RNA and LMP-1.[2]

TUGSE, a reactive lesion of unknown etiology, shares many of the microscopic features found in EBV-MUC.[3] TUGSE presents microscopically as an ulcerated lesion that contains a polymorphic inflammatory infiltrate rich in T cells and atypical B cells, as well as numerous eosinophils found deep within the connective tissue infiltrating between the skeletal muscle fibers. Like EBV-MUC, Hirshberg et al. published a study that described CD30+ atypical B cells in 25% of their TUGSE cases.[3]

Distinguishing EBV-MUC from a B-cell lymphoma microscopically is challenging, especially in patients with a history of lymphoma. Furthermore, as was

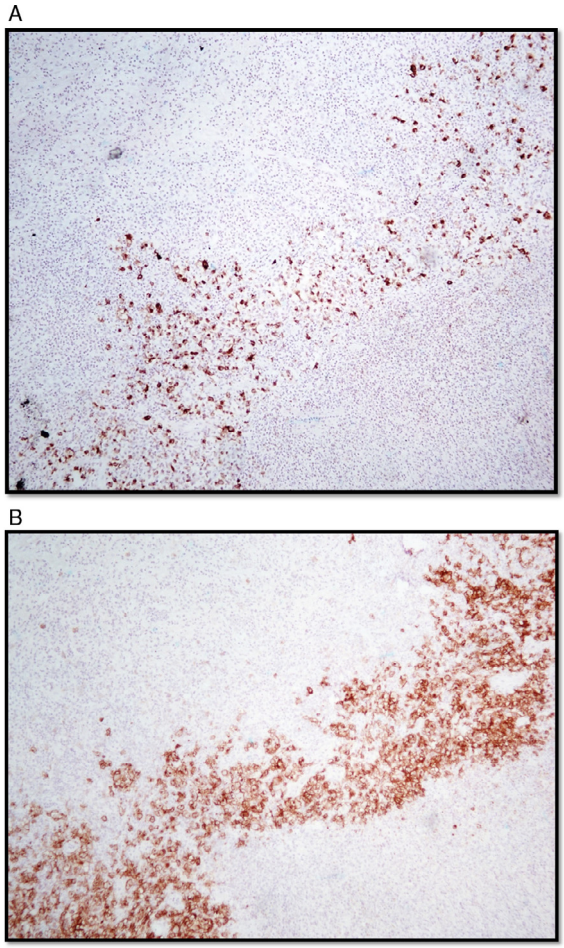

Fig. 4. Immunohistochemical stains of LMP-1 **(A)** and CD30 **(B)** showing strong staining of the lesional cells, limited to the base of the ulcer without deep extension (original magnification × 100).

shown in the current case, PCR for IgH rearrangement may show a monoclonal proliferation of EBV-infected B lymphocytes, as with a lymphoid malignancy.[1] However, in EBV-MUC, the atypical B cells are limited to the base of the ulcer, with minimal extension into the deep connective tissue. In addition, immunohistochemical stains, such as CD3 and CD68, will reveal numerous histiocytes and reactive T cells that surround the atypical B cells. T-cell/histiocyte-rich B-cell lymphomas, which are rare variants of B-cell lymphoma, may be microscopically indistinguishable from EBV-MUC, but no intraoral cases have yet been published.[4] In addition, unlike some cases of EBV-MUC, T-cell/histiocyte-rich B-cell lymphomas do not express CD30.[5]

Fig. 6. Panoramic radiograph confirming that the lesion is limited to the soft tissue without intraosseous extension.

Intraoral EBV-MUC, although a common location for EBV-MUC, is relatively rare. Other cases have been described in the oropharynx, skin, and gastrointestinal tract.[6]

A PubMed search of all intraoral cases published in the English language literature from 2012 to 2017, in addition to the current case, revealed 10 single or small series case reports with a total of 20 patients[2,6-13] (Table I).

Clinicopathologic analysis revealed that the tongue (n = 7) and the palate (n = 5) were the most common intraoral locations followed by the gingiva (n = 4) and the labial mucosa (n = 1). Clinically, the majority were asymptomatic, deep, and indurated mucosal ulcers.

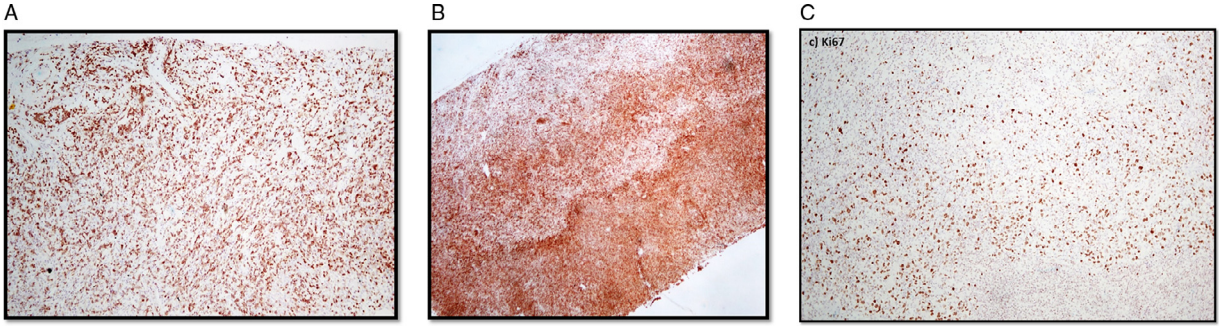

Fig. 5. Strongly and diffusely positive immunohistochemical stains of Epstein-Barr virus−positive mucocutaneous ulcer (EBV-MUC). **A,** CD3-T-cell marker (original magnification × 100). **B,** CD68-histiocyte cells marker (original magnification × 40). **C,** Ki67-proliferation marker (original magnification × 100).

Fig. 7. Clinical photograph from the left alveolar mucosa 6 months after the biopsy procedure showing nearly complete healing of the ulcer.

Only a minority of patients experienced tenderness, pain, or trismus. The precise source of immunosuppression can be divided into "medication related" (60%) and "age related" immunosuppression (35%). One case was unknown. Mycophenolate (33%) and methotrexate (33%) were the most common immunosuppressive drugs that contributed to EBV-MUC.[2,6,8,11] Azathioprine, cyclosporine-A, and antiretroviral medications[6,10] were mentioned in 1 case each. Eight patients were being treated for a systemic disease (rheumatoid arthritis, sarcoidosis, and HIV infection),[6,8,10,11] and 2 were being treated for a malignancy (breast cancer and lymphoma).[7,13] Only 3 patients from a single case report were organ transplant recipients (15%).[2] Conservative treatment was the treatment of choice in all cases, with many resolving spontaneously after cessation of the immune-inducing medications. No transformation to a malignancy or recurrence was reported.

EBV is a member of the herpesvirus family, and salivary contact is the mode of EBV transmission. It has been reported that over 90% of the adult population has been exposed to EBV, and once infected, the person becomes a lifelong carrier.[14] Initially, EBV enters through the squamous epithelium of the oropharynx, where it causes an acute infection and then enters a latent stage.[15] The virus may persist in memory B cells, and therefore, reactivation may occur wherever B cells reside.[16] In healthy individuals, an EBV-specific cytotoxic T-lymphocyte (CTL) response to latent viral proteins act to prevent the expansion of these activated B cells. In the immunocompromised patient, CTL is often suppressed, and there is a compromised ability for antibody feedback inhibition of the lymphoid proliferation.[17] When combined with a system overload of EBV, an EBV-associated lymphoproliferative disease or a lymphoid malignancy may result. Chronic stimulation of EBV on epithelial cells may allow the oncovirus to acquire the capacity to activate intracellular signaling that control B-cell proliferation, a process that appears to be partially responsible for the lymphoid malignancies often found in immunocompromised patients.[18] EBV has been implicated as the causative

Table I. Twenty patients presenting with intraoral EBV-MUC

Cases	Age/gender	Location	Source of immunosuppression	
			Disease	Medications
Akrish S et al., 2017	76/f	Man gingiva	Old age	none
Satou et al., 2017	52/f	Tongue	DLBCL	PBSCT
Chen B et al., 2017	58/f	Man gingiva	RA	MTX
Dojcinov S et al., 2010	80/f	Palate	Old age	none
	84/f	Tongue	Old age	None
	64/f	Tongue	Old age	none
	68/f	Tongue	Old age	none
	80/m	Tongue	RA	MTX
	42/m	Max gingiva	Sarcoidosis & MG	AZA
	48/f	Tongue	SLE	CYA
	60/f	Labial mucosa	RA	MTX
Roberts T et al., 2016	49/f	Palate & Gingiva	n/a	n/a
Bunn B et al., 2015	54/m	Palate	HIV	Antiretroviral
	36/f	Palate	HIV	n/a
Kenemitsu M et al., 2015	45/m	Max gingiva	SLE	MYC
Maghales M et al., 2015	81/f	Palate	Old age	none
Hart M et al., 2014	33/m	Tongue	Kidney transplant	MYC
	63/f	Gingiva	Kidney transplant	MYC
	18/m	Buc muc and Tonsil	Heart transplant	MYC
Attard A et al., 2012	81/f	Tongue	Breast cancer	MTX

AZA, azathioprine; *Buc muc,* buccal mucosa; *CYA,* cyclosporine-A; *DLBCL,* diffuse large B-cell lymphoma; *EBV-MUC,* Epstein-Barr virus−positive mucocutaneous ulcer; *Man,* mandible; *Max,* maxilla; *MG,* myasthenia gravis; *MTX,* methotrexate; *MYC,* mycophenolate; *PBSCT,* peripheral blood stem cell transplantation; *RA,* rheumatoid arthritis; *SLE,* systemic lupus erythematosus.

factor in several other reactive and neoplastic intraoral lesions. Reactive lesions include hairy leukoplakia, a white patch found on the lateral tongue in immunocompromised patients, primarily patients with HIV infection; acute sialadenitis, where EBV is one of the causative agents[19]; and viral lymphadenitis (mononucleosis).[20] EBV as an etiologic factor in Sjögren disease is still being debated.[21] Intraoral EBV-associated neoplastic lesions are rare and include lymphoepithelial carcinoma of the salivary gland (undifferentiated carcinoma),[22] nasopharyngeal carcinoma,[23] endemic Burkitt lymphoma,[24] and extranodal natural killer-/T-cell lymphoma, nasal type.[25]

CONCLUSIONS

The clinicopathologic features of EBV-MUC, especially when presenting with a monoclonal IgH rearrangement, may strongly resemble a hematologic malignancy. Recognizing the subtle microscopic and immunohistochemical features of EBV-MUC may allow for an accurate diagnosis and prevent excessive treatments. EBV-MUC has a self-limiting, indolent clinical course, and although the management guidelines have yet to be ascertained, conservative therapy seems to be the treatment of choice.[4] In fact, as in our reported case as well as in others, the lesion often resolves spontaneously once the underlying immunosuppression is corrected.

REFERENCES

1. Gru A, Jaffe E. Cutaneous EBV-related lymphoproliferative disorders. *Semin Diagn Pathol*. 2017;34:60-75.
2. Hart M, Thakral B, Yohe S, et al. EBV-positive mucocutaneous ulcer in organ transplant recipients: a localized indolent posttransplant lymphoproliferative disorder. *Am J Surg Pathol*. 2014;38:1522-1529.
3. Hirshberg A, Amariglio N, Akrish S, et al. Traumatic ulcerative granuloma with stromal eosinophilia: a reactive lesion of the oral mucosa. *Am J Clin Pathol*. 2006;126:522-529.
4. De Wolf-Peeters C Delabie J, Campo E, et al. T cell/histiocyte-rich large B-cell lymphoma. In: Swerdlow SH, ed. *WHO Classification of Tumours of Haematopoietic and Lymphoid Tissues*. 4th ed. Lyon, France: IARC Press; 2008:238-239.
5. Achter R, Verhoef G, Vanuytsel L, et al. Histiocyte-rich, T-cell-rich B-cell lymphoma: a distinct diffuse large B-cell lymphoma subtype showing characteristic morphologic and immunophenotypic features. *Histopathology*. 2002;40:31-45.
6. Dojcinov S, Venkataraman G, Raffeld M, et al. EBV positive mucocutaneous ulcer—a study of 26 cases associated with various sources of immunosuppression. *Am J Surg Pathol*. 2010;34:405-417.
7. Satou A, Kohno A, Fukuyama R, et al. Nakamura S. Epstein-Barr virus-positive mucocutaneous ulcer arising in a post-hematopoietic cell transplant patient followed by polymorphic posttransplant lymphoproliferative disorder and cytomegalovirus colitis. *Hum Pathol*. 2017;59:147-151.
8. Chen B, Fang C, Chuang S. Epstein-Barr virus-positive mucocutaneous ulcer. *Kaohsiung J Med Sci*. 2017;33:50-51.
9. Roberts T, Chen X, Liao J. Diagnostic and therapeutic challenges of EBV-positive mucocutaneous ulcer: a case report and systematic review of the literature. *Exp Hematol Oncol*. 2016;27:5-13.
10. Bunn B, van Heerden W. EBV-positive mucocutaneous ulcer of the oral cavity associated with HIV/AIDS. *Oral Surg Oral Med Oral Pathol Oral Radiol*. 2015;120:725-732.
11. Kanemitsu M, John D, Lim A, et al. Clonal Epstein-Barr virus-positive mucocutaneous ulcer mimicking a mature B-cell lymphoma in a patient with mycophenolate-induced immune suppression. *Leuk Lymphoma*. 2015;56:1908-1910.
12. Magalhaes M, Ghorab Z, Morneault J, et al. Age-related Epstein-Barr virus-positive mucocutaneous ulcer: a case report. *Clin Case Rep*. 2015;3:531-534.
13. Attard A, Praveen P, Dunn P, James G. Epstein-barr virus−positive mucocutaneous ulcer of the oral cavity: the importance of having a detailed clinical history to reach a correct diagnosis. *Oral Surg Oral Med Oral Pathol Oral Radiol*. 2012;114:e37-e39.
14. Henle G, Henle W. Seroepidemiology of the virus. In: Epstein MA, Achong BG, eds. *The Epstein-Barr Virus*. Berlin, Germany: Springer-Verlag; 1979:297-320.
15. Sixbey J, Nedrud J, Raab-Traub N, et al. Epstein-Barr virus replication in oropharyngeal epithelial cells. *N Engl J Med*. 1984;310:1225-1230.
16. Babcock G, Decker L, Volk M, et al. EBV persistence in memory B cells *in vivo*. *Immunity*. 1998;9:395-404.
17. Thompson M, Kurzrock R. Epstein-Barr virus and cancer. *Clin Cancer Res*. 2004;10:803-821.
18. Louie S, Schwartz R. Immunodeficiency and the pathogenesis of lymphoma and leukemia. *Semin Hematol*. 1978;15:117-138.
19. Brook I. Diagnosis and management of parotitis. *Arch Otolaryngol Head Neck Surg*. 1992;118:469-471.
20. Rickinson A. Epstein-Barr virus. *Virus Res*. 2002;82:109-113.
21. Wen S, Shimizu N, Yoshitama H, et al. Association of Epstein-Barr virus (EBV) with Sjogren's syndrome. Differential EBV expression between epithelial cells and lymphocytes in salivary glands. *Am J Pathol*. 1996;149:1511-1517.
22. Tsai C, Chen C, Hsu C. Expression of Epstein-Barr virus in carcinomas of major salivary glands: a strong association with lymphoepithelioma-like carcinoma. *Hum Pathol*. 1996;27:258-262.
23. Raab-Traub N. Epstein Barr virus and nasopharyngeal carcinoma. *Semin Cancer Biol*. 1992;3:297-307.
24. Henle G, Henle W. Immunofluorescence in cells derived from Burkitt's lymphoma. *J Bacteriol*. 1966;91:1248-1256.
25. Chan J, Quintanilla-Martinez L, Ferry J, et al. Extranodal NK/T cell lymphoma, nasal type. In: Swerdlow SH, ed. *WHO Classification of Tumours of Haematopoietic and Lymphoid Tissues*. 4th ed. Lyon, France: IARC Press; 2008:285-288.

Reprint requests: Sharon J. Akrish, Yahalom 2 Caesarea, 38900 Israel
sjakrish@gmail.com