

Remodeling of Neocondyle

K. R. Ashok Kumar, R. Ravikumar, T. R. Marimallappa, Hijam Thoithoibi Chanu

Department of Oral and Maxillofacial Surgery, Sri Siddhartha Dental College and Hospital, Tumkur, Karnataka, India

Abstract

Temporomandibular joint (TMJ) ankylosis in children is one of the most complex and challenging problems managed by oral and maxillofacial surgeons. TMJ ankylosis in growing children often leads to facial deformity, difficulty in chewing and swallowing, severe malocclusion, poor oral hygiene, multiple decayed teeth, and impairment of speech. A good functional and esthetic outcome can be achieved after reconstruction with the autogenous grafts. Here, we present a case of a 9-year-old patient treated with condylectomy and ipsilateral coronoidectomy, followed by reconstruction with costochondral graft with 5 years of follow-up. During this period, the reconstructed graft remodeled into a neocondyle and also regrowth of the coronoid process. The mouth opening and facial symmetry were acceptable.

Keywords: Costochondral graft, neocondyle, temporomandibular joint ankylosis

INTRODUCTION

The term ankylosis is derived from the Greek word meaning “stiffening of a joint.” Ankylosis may be defined as a fibrous or bony union of the condyle of the mandible and glenoid fossa of the temporal bone.^[1] Temporomandibular joint (TMJ) ankylosis in children can lead to devastating effects such as facial deformity, difficulty in chewing and swallowing, severe malocclusion, poor oral hygiene, multiple decayed teeth and impairment of speech, and acute compromise of airway.^[2-5] Various autogenous bone grafts such as costochondral graft (CCG), metatarsal heads, fibula, sternoclavicular joints, clavicle, and iliac crest are being used for the reconstruction of condyle.^[4,5,6] Among these, CCG is the most commonly used, first described by Harold Gilles in 1920, and was popularized by Poswillo.^[2,6] However, the use of CCG has gained popularity because of its biologic and anatomic similarity, ease in obtaining and adapting the graft and its regenerative growth potential, and low morbidity of the donor site.^[1,5,7] Reconstruction with CCG in children provides a growth potential, and it is hoped that it maintains the mandibular symmetry throughout the growth period.

However, excessive and unpredictable growth of the CCG on the grafted site leading to facial asymmetry, progressive dental midline shift, occlusal change, chin deviation, and enlargement of the CCG has been reported in many literature.^[8,9] This article presents a case report of a patient who underwent CCG reconstruction of condyle after resection of ankylotic mass

which remodeled into a neocondyle and also the regrowth of coronoid process with 5 years of follow-up.

CASE REPORT

A 9-year-old male patient reported with the chief complaint of inability to open the mouth and difficulty in chewing for 1 year. His parents gave a history of trauma to the chin 2 years back and noticed progressive limitation of mouth opening. On clinical examination, gross asymmetry was noted with mild deviation of the mouth toward the left side and fullness of the left side and flattening of the right side of the jaw. Interincisal opening of 10 mm was observed [Figure 1]. On local examination, a bony mass was palpable on the left preauricular region. Left TMJ was nonauscultatory. Provisional diagnosis of left TMJ ankylosis was made. Orthopantomogram and computed tomography scan of the TMJ revealed the presence of bony ankylotic mass in the left TMJ region showing displaced condyle fused medially to the ramus [Figures 2 and 3]. Surgical resection of the bony ankylotic mass and ipsilateral coronoidectomy was performed through Alkayat-Bramley incision to improve the mouth opening;

Address for correspondence: Dr. Hijam Thoithoibi Chanu, Department of Oral and Maxillofacial Surgery, Sri Siddhartha Dental College and Hospital, BH Road, Agalakote, Tumkur - 572 107, Karnataka, India. E-mail: hijamthoi9@gmail.com

Access this article online

Quick Response Code:



Website:
www.amsjournal.com

DOI:
10.4103/ams.ams_70_19

This is an open access journal, and articles are distributed under the terms of the Creative Commons Attribution-NonCommercial-ShareAlike 4.0 License, which allows others to remix, tweak, and build upon the work non-commercially, as long as appropriate credit is given and the new creations are licensed under the identical terms.

For reprints contact: reprints@medknow.com

How to cite this article: Ashok Kumar KR, Ravikumar R, Marimallappa TR, Chanu HT. Remodeling of neocondyle. *Ann Maxillofac Surg* 2019;9:481-3.

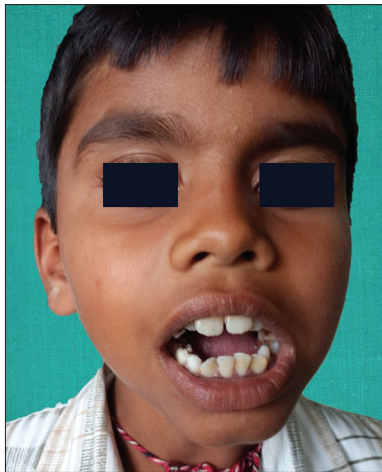

Figure 1: Preoperative photograph showing limited mouth opening

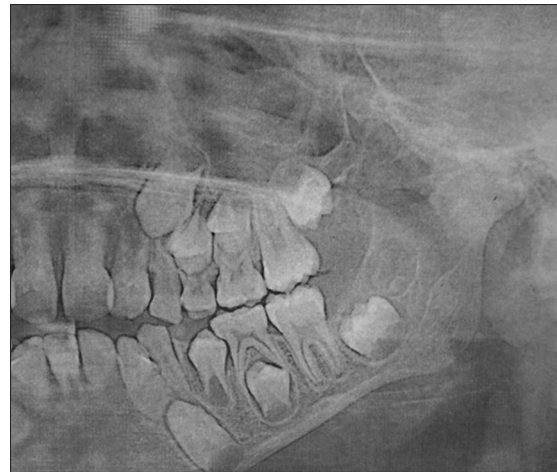


Figure 2: Preoperative orthopantomogram showing the ankylosed condylar mass

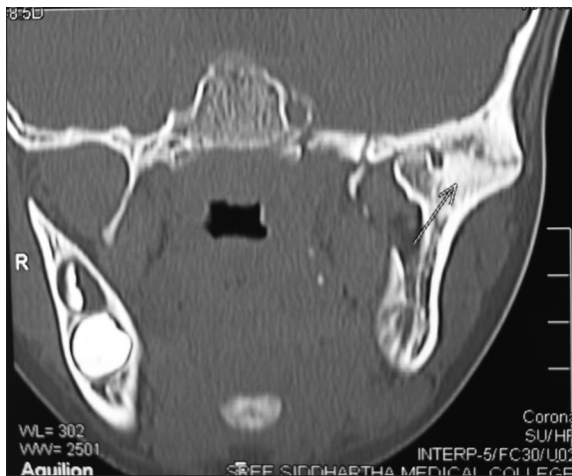

Figure 3: Preoperative coronal computed tomography

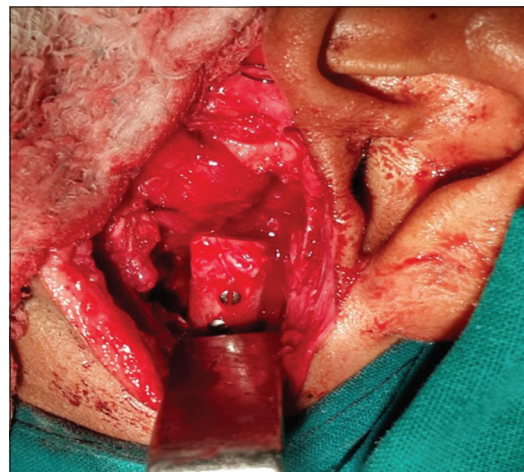


Figure 4: Intraoperative photograph showing costochondral graft fixed with 2 mm × 10 mm titanium screws

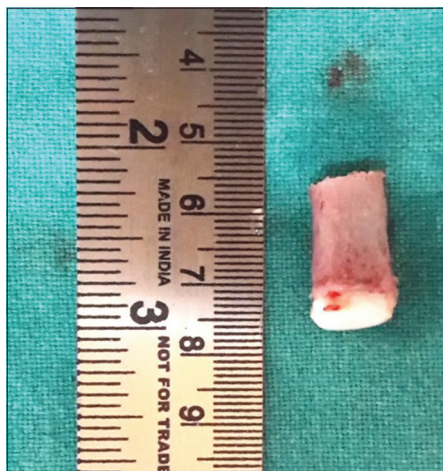


Figure 5: Photograph showing costochondral graft taken from the sixth rib

temporalis myofascial flap was rotated over the defect. Condyle was reconstructed using CCG harvested from the sixth rib fixed with 2 mm × 10 mm titanium screws [Figures 4 and 5]. Aggressive physiotherapy was advised after the day of the surgery up to 6 weeks. The patient was followed up for 5 years with

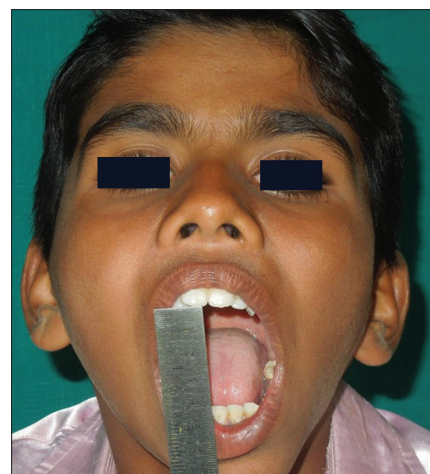


Figure 6: Postoperative mouth opening 5 years after left temporomandibular joint reconstruction

satisfactory mouth opening [Figure 6]. Remodeling of CCG into neocondyle and regrowth of coronoid process was noted

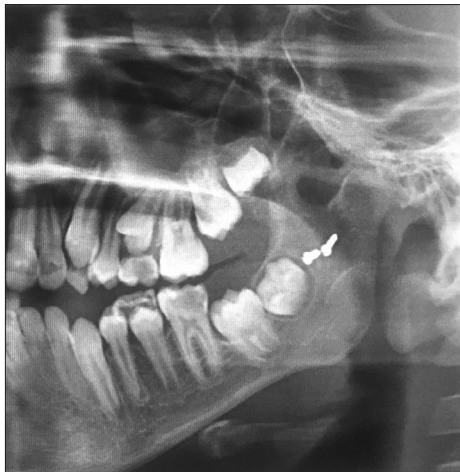

Figure 7: Five years postoperative orthopantomogram

with no obvious facial asymmetry or unpredictable growth of the mandible [Figures 7 and 8].

DISCUSSION

In growing children, CCG is a material of choice for reconstruction of TMJ because of three important functions; cartilaginous portion acts as an interpositional material, bony portion restores the vertical height of the ascending ramus, and junction between cartilaginous portion and bony portion acts as a growth center.^[1,5,7] These grafts remodel to resemble condyle overtime. Furthermore, several reports of unpredictable growth or overgrowth of mandibular CCG has been reported.^[2,8] Guyuron and Carlos (1992) concluded that the CCG has unpredictable growth pattern along with normal mandibular growth.^[1] Perrott and Kaban and Peltomaki *et al.* described two types of overgrowth such as (1) linear overgrowth resulting in asymmetric or bilateral prognathism and (2) tumor-like overgrowth and re-ankylosis and hypothesized that both types of overgrowth are caused by an excessively large cartilaginous cap on the graft. A cartilaginous cap >1–2 mm transfers an excessive portion of the growth center resulting in linear overgrowth. In some cases, micromotion occurs at the junction of the cartilage and bone during normal mandibular function which results in tumor-like overgrowth.^[4,10] In our case, symmetrical growth pattern may be due to the maintenance of 1–2 mm cartilaginous cap. Various authors also suggested that the coronoid process may reattach to form an elongated process or remain separated with the formation of the false joint with the mandibular ramus.^[9] However, we noticed regrowth of the resected coronoid process which may be due to the pull of temporalis muscle attached to it.

CONCLUSION

Management of TMJ ankylosis in growing children is challenging and requires early intervention and management with autogenous bone graft with growing potential. Meanwhile, regular and long-term follow-up is necessary till the completion of growth since there are cases of unpredictable growth pattern

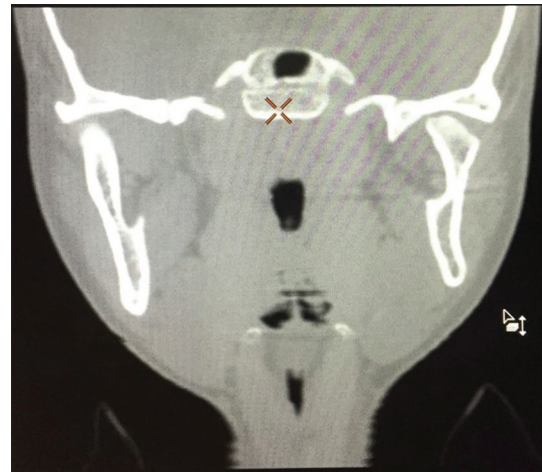


Figure 8: Five years postoperative coronal computed tomography showing the formation of the left neocondyle

of the mandible which can lead to facial asymmetry requiring further orthognathic surgery.

Declaration of patient consent

The authors certify that they have obtained all appropriate patient consent forms. In the form, the patient's parents have given their consent for his images and other clinical information to be reported in the journal. The patient's parents understand that his name and initials will not be published and due efforts will be made to conceal their identity, but anonymity cannot be guaranteed.

Financial support and sponsorship

Nil.

Conflicts of interest

There are no conflicts of interest.

REFERENCES

1. Mabongo M. Temporomandibular joint ankylosis in children. *J Dent Med Sci* 2013;12:35-41.
2. Verma A, Yadav S, Singh V. Overgrowth of costochondral graft in temporomandibular joint ankylosis: An unusual case. *Natl J Maxillofac Surg* 2011;2:172-4.
3. Bhat C, Patil S, Kale N, Salunkhe N. Temporomandibular joint fibrous ankylosis – A case report. *J Appl Dent Med Sci* 2016;2:112-5.
4. Kaban LB, Bouchard C, Troulis MJ. A protocol for management of temporomandibular joint ankylosis in children. *J Oral Maxillofac Surg* 2009;67:1966-78.
5. Ko EW, Huang CS, Chen YR. Temporomandibular joint reconstruction in children using costochondral grafts. *J Oral Maxillofac Surg* 1999;57:789-98.
6. Medra AM. Follow up of mandibular costochondral grafts after release of ankylosis of the temporomandibular joints. *Br J Oral Maxillofac Surg* 2005;43:118-22.
7. McFadden LR, Rishiraj B. Treatment of temporomandibular joint ankylosis: A case report. *J Can Dent Assoc* 2001;67:659-63.
8. Baek RM, Song YT. Overgrowth of a costochondral graft in reconstruction of the temporomandibular joint. *Scand J Plast Reconstr Surg Hand Surg* 2006;40:179-85.
9. Mohanty S, Kohli S, Dabas J, Kumar RD, Bodh R, Yadav S. Fate of the coronoid process following coronoidotomy and its effect on the inter-incisal opening – A clinical and radiological assessment. *J Oral Maxillofac Surg* 2017;75:1263-73. [doi: 10.1016/j.joms.2017.01.012].
10. Chugh A, Pasricha N, Bedi RS, Pandey P. Management of temporomandibular joint ankylosis in children: Current perspective. *Asian J Oral Health Allied Sci* 2011;1:160-4.