

Extraskelatal Myxoid Chondrosarcoma of the Parotid Gland

Nyimi Bushabu Fidele^{1,2}, Wu Tianfu¹, Bing Liu¹, Yanfang Sun², Zhao Yifang²

¹Department of Oral Maxillofacial Head and Neck Oncology Surgery, School and Hospital of Stomatology, The State Key Laboratory Breeding Base of Basic Science of Stomatology and Key Laboratory of Oral Biomedicine Ministry of Education, School and Hospital of Stomatology, Wuhan University, Wuhan, China,

²Department of Oral and Maxillofacial Surgery, Teaching Hospital of Kinshasa University, University of Kinshasa, Kinshasa, Democratic Republic of the Congo

Nyimi Bushabu Fidele and Wu Tianfu are equal contributors

Abstract

Extraskelatal myxoid chondrosarcoma (EMC) is a rare tumor with an estimated incidence of <3% among of all soft-tissue sarcomas. It is characterized by a multinodular architecture, abundant myxoid matrix, and malignant chondroblast-like cells arranged in cords. The tumor is an entity from chondrosarcomas of bones, commonly found in the soft tissues of the lower extremities at 80%. There are very limited reports of this tumor in the head and neck, especially in the parotid gland. The purpose of this paper is to describe an EMC located at an unusual site in the parotid gland, and briefly, the literature review with special reference to the clinicopathological features and the treatment approach was discussed.

Keywords: Clinical features, extraskelatal myxoid chondrosarcoma, parotid gland, treatment

INTRODUCTION

Extraskelatal myxoid chondrosarcoma (EMC) is a malignant soft tissue tumor characterized by a multinodular architecture, abundant myxoid matrix, and malignant chondroblast-like cells arranged in cords, clusters, or delicate networks. It was first described by Enzinger and Shiraki in 1972 as a distinct tumor type.^[1] EMC has been classified by the WHO as a tumor of uncertain differentiation in its classification of tumors of soft tissues and bones.^[2] Chondrosarcomas are the third most common primary malignancy of bone after myeloma and osteosarcoma that produces cartilaginous matrix.^[3] Myxoid chondrosarcoma is an intermediate subtype, which is found in either bones or soft tissues. EMC is a separate entity from chondrosarcomas of bones commonly found in the soft tissues of the lower extremities (80%) and in the trunk (20%). To the best of our knowledge, 42 EMC cases of the head and neck region have been reported in literature, including the present report. Of these EMCs, only one previous case arose from the parotid gland region. The purpose of this paper was to describe an EMC reported at an unusual site in the parotid gland. In addition, the literature review was briefly discussed with special reference to the possible clinicopathological features and the treatment of EMC.

CASE REPORT

A 56-year-old female was admitted in the Department of Oral Maxillofacial Head and Neck Oncology Surgery with a history of painless mass of the left posterior region of the parotid gland. The swelling was slowly progressive over a period of 2 months and there were no associated systemic symptoms. Physical examination revealed a parotid mass 1.5 cm × 2 cm × 2 cm in size, firm in consistency, and with no palpable cervical lymph nodes. The preoperative computed tomography (CT) scan depicted a 4.5 cm × 3.4 cm × 3.2 cm sized irregular lobular mass involving the deep lobe of the left parotid gland. Margins were clear, uneven texture, and the compression of the left internal jugular vein with the forward displacement was observed. The cervical lymph nodes were not enlarged [Figure 1a]. The coronal CT demonstrated a soft tissue mass that extended up to the left temporal bone [Figure 1b]. Parotid gland pleomorphism adenoma or facial nerve neurilemmoma was the clinical differential diagnosis. Following discussion

Address for correspondence: Dr. Bing Liu,

Department of Oral Maxillofacial Head and Neck Oncology Surgery, School and Hospital of Stomatology, Wuhan University, Wuhan 430079, China.

E-mail: liubing9909@whu.edu.cn

This is an open access journal, and articles are distributed under the terms of the Creative Commons Attribution-NonCommercial-ShareAlike 4.0 License, which allows others to remix, tweak, and build upon the work non-commercially, as long as appropriate credit is given and the new creations are licensed under the identical terms.

For reprints contact: reprints@medknow.com

How to cite this article: Fidele NB, Tianfu W, Liu B, Sun Y, Yifang Z. Extraskelatal myxoid chondrosarcoma of the parotid gland. *Ann Maxillofac Surg* 2019;9:439-43.

Access this article online

Quick Response Code:



Website:
www.amsjournal.com

DOI:
10.4103/ams.ams_145_18

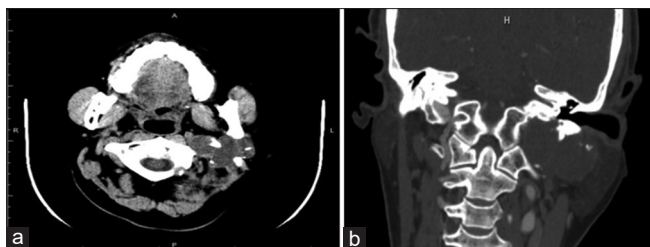

Figure 1: CT Scan showed an irregular lobular mass on the left parotid gland involving deep lobe with clear boundary and showing compression of the left internal jugular vein without cervical lymph nodes enlargement (a), The coronal incidence demonstrating a heterogeneous soft-tissue mass extended upon to the left temporal bone, and the boundary was not a rough (b)

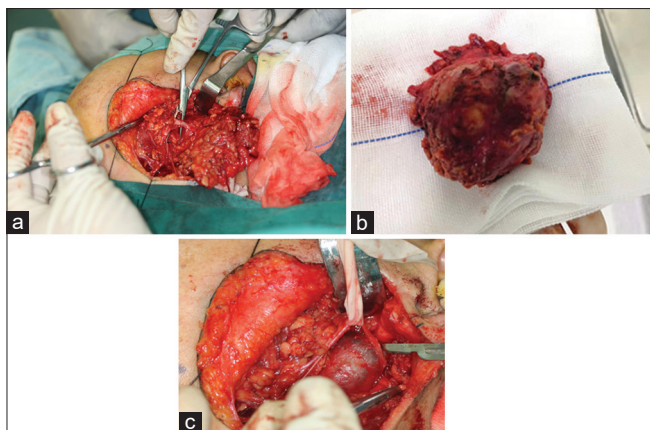


Figure 2: View of intraoperative shows conservation of facial nerve (a) with excision of tumour (b) Palpated vessels (c)

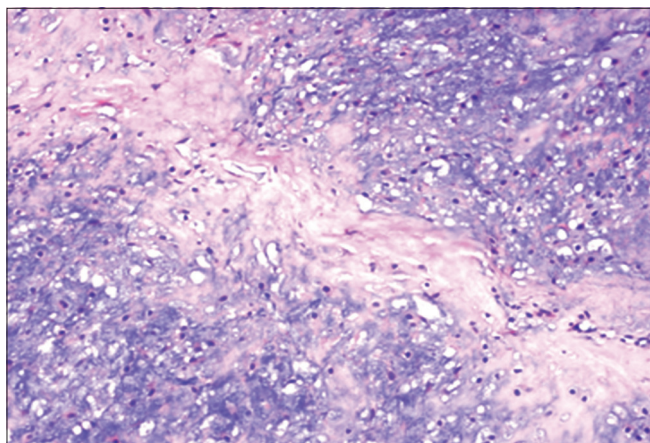


Figure 3: Histological features of the tumor showed cells embedded in a mucus-like matrix structure ($\times 10$), cells relatively small with uniform size and shape, alignment in strands and cords separated by large amount of myxoid stroma

and after obtaining consent from the patient, left partial parotidectomy with conservation of facial nerve was performed under general anesthesia. During the course of the surgery, the tumor was identified with an intact capsule and jugular vein, and the carotid artery was palpated [Figure 2a-c].

MATERIALS AND METHODS

A biopsy specimen was collected, fixed immediately in 4% buffered paraformaldehyde, and embedded in paraffin and then cut at a thickness of approximately 4 μm . The study was performed strictly in accordance with the guidelines set forth by the Review Board of the Ethics Committee in the Hospital of Stomatology, Wuhan University. Macroscopic pathology showed the tumor was grossly jelly like with a localized myxoid transparent appearance and irregular. In hematoxylin and eosin-stained section ($\times 10$), the tumor was highlighting nodular or lobulated growth pattern. The tumor cells were small with uniform size and shape, with a small hyperchromatic nucleus and a moderate amount of eosinophilic cytoplasm that was occasionally vacuolated. These cells were embedded in an abundant mucus-like matrix, with rare mitoses and cartilage differentiation. Alignment of the tumor cells in strands and cords separated by myxoid stroma was characteristic of EMC [Figure 3].

In accordance to a pathology book on salivary glands,^[4] immunohistochemical studies were performed on paraffin sections of the parotid gland mass using antibodies against antigens. To evaluate the immunoreactivity, we assessed the staining areas of the markers. The numbers of stained cells were counted at an original magnification of $\times 200$ in five random fields by two investigators. The images were then analyzed using the ImageJ version 1.48v. Immunocytochemical staining showing reactivity for marker S-100, vimentin, and Ki-67 was focally and weakly positive ($< 5\%$) as well. The tumor cells did not react with antibodies to the keratin, calponin, desmin, P63, NSE, and Syn. Based on these findings, the diagnosis of EMC was rendered. After a follow-up period of 12 months, the postoperative course was uneventful, and as of the time of writing, no recurrence had appeared.

DISCUSSION

EMCs are a group of rare malignancies of soft-tissue sarcomas whose ultrastructural and molecular features are distinct from that of myxoid chondrosarcoma. Clinical examination of EMC has no specific findings which separates it from other types of chondrosarcomas. Pain, tenderness, and detection of a palpable mass may characterize some cases.^[5] Tumors arising in specific sites can produce associated symptoms and large or superficial tumors may ulcerate the skin. EMC is low-grade malignant tumors with a predilection for males;^[6] as from 42 cases found in literature, males were affected in 59.52% ($n = 25$) and females in 35.71% ($n = 15$), and 4.86% ($n = 2$ cases) were unavailable [Table 1]. In addition, the age group ranging from 36 to 66 was the most affected (45.23%; $n = 19$) as for the present case. Imaging characteristics are nonspecific, most tumors appear lobulated, and highly myxoid tumors have a homogeneous high signal on T2-weighted magnetic resonance imaging image.^[5] Furthermore, as the tumor may undergo hemorrhagic and necrotic degeneration, signal characteristics on T1-weighted magnetic resonance images could be varied,

Table 1: Epidemiological summary of extraskelatal myxoid chondrosarcoma of the head and neck reported in the literature

Authors' names	Publication years	NC	Age/sex	Location	Treatment	Follow-up (months)	Recurrence/observation
Present case	-	1	56/male	Parotid gland	Surgery	12	None/alive
Ceylan <i>et al.</i> ^[5]	2006	1	35/female	Nasal cavity	Surgery	9	None/alive
Ratnadeep and Abhishek ^[7]	2011	1	61/male	Nasal cavity	Surgery	3	Yes/alive
Angiero ^[8]	2012	1	102/female	Buccal mucosa	Surgery	UA	UA
Oh <i>et al.</i> ^[9]	2013	1	62/female	Neck	Surgery	UA	UA
Antonescu <i>et al.</i> ^[10]	1998	2	82/male	Neck	Surgery	60	Yes/died
			53/male	Neck	Surgery	4	None/alive
Navdeep <i>et al.</i> ^[11]	2017	1	65/male	Neck	Surgery	UA	UA
Zaki <i>et al.</i> ^[12]	2015	1	65/male	Neck	RT + CT	2	None/alive
Acero <i>et al.</i> ^[13]	2003	1	22/female	Infratemporal fossa	Surg + RT	36	None/alive
Jérôme-Marson <i>et al.</i> ^[14]	2003	2	67/male	Nasal cavity	RT	7	UA
			71/female	Sphenoid sinus	RT	4	UA
Sotomayor <i>et al.</i> ^[15]	2007	1	80/male	Base of the tongue	IB	14 days	Died
Shao <i>et al.</i> ^[16]	2016	1	56/male	Parotid gland	Surgery	12	None/alive
Jawad <i>et al.</i> ^[17]	1991	1	45/male	Maxillary sinus	Surgery	18	None/alive
Drilon <i>et al.</i> ^[18]	2008	1	UV	Head and neck	UA	UA	UA
Jung <i>et al.</i> ^[19]	2011	1	69/female	Masticator Space	Surg + RT	3	None/alive
Romañach <i>et al.</i> ^[20]	2017	1	13/male	Masticator space	Surg + RT	12	Yes/died
Englert <i>et al.</i> ^[21]	1978	1	43/male	Mandibular metastasis	Palliative	UA	UA
Tsuneyoshi <i>et al.</i> ^[22]	1981	2	16/male	Nasal cavity	Surgery	5	Yes/died
			66/male	Neck	Surgery	2	None/alive
Charabi <i>et al.</i> ^[23]	1989	1	34/female	Temporal bone	Surgery	18	None/alive
Liu-Shindo <i>et al.</i> ^[24]	1989	1	51/female	Skin, over the mentum	Surg + RT	15	None/alive
Salcman <i>et al.</i> ^[25]	1992	1	28/female	Intracranial	Surg + RT	22	Yes/alive
Sato <i>et al.</i> ^[26]	1993	1	43/female	Intracranial	Surg, RT, CT	UA	Yes/died
Worley <i>et al.</i> ^[27]	1999	1	42/male	External auditory meatus	Surgery	9	None/Alive
Oshiro <i>et al.</i> ^[28]	2000	1	66/male	Neck, scapula	UA	12	None/alive
De Las Casas <i>et al.</i> ^[29]	2000	1	44/male	Spheiodal sinus	Surg + RT	16	None/alive
Goh <i>et al.</i> ^[30]	2001	2	65/male	Epidural	UA	UA	UA
			70/male	Supraclavicular	UA	UA	UA
Deik <i>et al.</i> ^[31]	2009	1	94/male	Supraclavicular	UA	UA	UA
Bahri <i>et al.</i> ^[32]	2002	1	67/female	Parapharyngeal space	Surg + RT	7	None/alive
González-Lois <i>et al.</i> ^[33]	2002	1	17/female	Intracranial	Surg + RT	20	Yes/alive
Cummings <i>et al.</i> ^[34]	2004	1	63/male	Jugular foramen	UV	UV	UA
Jörg <i>et al.</i> ^[35]	2006	1	8/male	Maxilla	Surgery	18	None/alive
Saint-Blancard <i>et al.</i> ^[36]	2006	1	67/female	Neck	Surgery	UA	UA
Nakazora <i>et al.</i> ^[37]	2006	1	48/male	Clavicle	Surgery	36	None/alive
Betz <i>et al.</i> ^[38]	2007	1	88/UV	Nasal septum	Surgery	13	Yes/alive
Kim <i>et al.</i> ^[39]	2007	1	10/male	Sinonasal cavity	Surg + RT	UA	UA
O'Brien <i>et al.</i> ^[40]	2008	1	26/female	Cerebellopontine angle	Surg + RT	12	None/A
Willems <i>et al.</i> ^[41]	2008	1	32/male	Neck	UA	UA	UA
Kaplan <i>et al.</i> ^[42]	2010	1	37/female	Maxillary sinus	Surg + RT	18	None/alive

Surg=Surgery; UA=Unavailable; RT=Radiotherapy; CT=Chemotherapy; IB=Incisional biopsy; NC=Number of case

ranging from low, intermediate, to high intensity compared to muscles. Calcification is usually absent as in this report and, if present, it is not prominent. Since its original description, EMC of the head and neck is a rare entity, occurring less than 3% of all soft-tissue sarcomas,^[2] including the nasal cavity, buccal mucosa, neck region, infratemporal fossa, sphenoidal

sinus, base of the tongue, and the parotid gland [Table 1]. To date, there is only one previous report of EMC involving the parotid gland.

The pathogenesis of EMC remains controversial. Surgical or accidental trauma may be key factors, along with the inhalation

of chemical carcinogens such as hydrocarbons.^[17] Our patient did not report any head and neck region trauma. Another theory suggested that these tumors arise from a primitive mesenchymal or a synovial intimal cell with a propensity for differentiation. EMC is lobulated or multinodular and varies from gray to tan in color with a gelatinous and mucoid consistency. The pathological characteristics of the surface of EMC are myxoid or jelly-like, with a localized myxoid-like transparent appearance; cysts, hemorrhage, or necrosis may be observed. Under a light microscope, EMC usually exhibits a nodular structure with abundant myxoid stroma.^[43] Histologically, it is characterized by a collection of round-to-spindle-shaped cells; arranged in cords, strands, and nests; and surrounded by a mucinous, hypovascular matrix. The cell nuclei demonstrate minimal to absent pleomorphism, hyperchromatic nuclei, and are surrounded by eosinophilic cytoplasm which is occasionally vacuolated.^[44] Even though EMC is now recognized as a distinct lesion from chondrosarcomas of the bones, the term EMC probably still a misnomer for this tumor and does not highlight its true chondrosarcomatous differentiation. Three distinct histologic patterns of EMC have been described in the literature such as solid type, the rhabdoid phenotype (a rare type) and the classical EMC as described in the present paper, which presents as a low grade tumor with loose matrix, fibrils and myxoid material.^[45] Compared to the solid tumor type, the latter usually has a large vesicular nucleus and increased mitotic activity. The classical EMC is the most common type that is less aggressive than chondrosarcomas of the bone.

The treatment of EMC is largely surgical excision as demonstrated in Table 1. Even with adequate surgical margins, however, the technical complexities related to this anatomical region, complete tumor resection often is not achieved, thus resulting in a poorer prognosis.^[13] Therefore, en bloc resection and the longitudinal follow-up are necessary. The present case was treated by superficial parotidectomy, and after postoperative follow-up of 12 months, no signs of recurrence had appeared unlike as reported in the case of Ratnadeep and Abhishek^[7] in which recurrence was detected three months after surgery. Even though the overall prognosis of EMC is difficult to estimate due to rarity of the tumor, one report demonstrated 5-year survival rate to be 82% and 65% survival rate at 10-year with 48% of local recurrence and 46% of metastases.^[18] There are prognostic variations depending on cellularity, cellular maturity, differentiation, and amount of myxoid matrix. Dedifferentiated EMC is assumed to be more aggressive.^[19] Some reports suggest that the tumor showing increased cellularity and atypia is more aggressive^[10,44] and the presence of rhabdoid cells may be an adverse histologic variable.^[28] In addition, older patients with larger tumors, especially greater than 10 cm, have poorer prognosis. To date, the use of radiotherapy for EMC is controversial, and optimal chemotherapy regimen remains unclear determined. Some studies show that these tumors are resistant to radiotherapy, while others maintain that radiotherapy should be considered.^[28]

While hematoxylin-eosin staining remains the gold standard for salivary gland tumor diagnosis, immunohistochemistry (IHC) is more commonly being used to obtain better understanding of the morphogenesis of the disease and to enhance diagnostic accuracy.^[7] IHC marker panels can support and may be useful in refining the diagnosis of EMC. Vimentin is the only marker consistently expressed in EMC,^[5,16,43] while S-100 protein, synaptophysin, cytokeratin, and epithelial membrane antigen are focally expressed in a minority of tumors. In the present case, S-100 protein and vimentin had the highest expression. Reactivity with vimentin, S-100 protein, and EMA has also been reported.^[46] The analysis of IHC markers associated with the location of the lesion; cytology and radiology factors constitute systematic keywords for the diagnosis of EMC. Therefore, a meticulous academic exercise for analysis and interpretation of the findings is mandatory. In the recent study, Ki-67 index was remarkably higher in cellular variant (N30%) but 5%–10% in a classic EMC variety,^[16] which was similar to the present report. The low proliferative index as shown by Ki-67 (<5%), i.e., low mitotic activity, appears to be associated with a good outcome.

CONCLUSION

Although some reports have been published about EMC in the head and neck region, there is an extremely limited report in the parotid gland. EMC should remain in the differential diagnosis for a soft-tissue parotid gland mass. The histological and immunohistochemical features associated with clinical features are essential for the diagnosis of such lesions.

Financial support and sponsorship

Nil.

Conflicts of interest

There are no conflicts of interest.

REFERENCES

1. Enzinger FM, Shiraki M. Extraskelatal myxoid chondrosarcoma. An analysis of 34 cases. *Hum Pathol* 1972;3:421-35.
2. Fletcher CD, Bridge JA, Hogendoorn PC, Mertens F. WHO Classification of Tumors of Soft Tissue and Bone. Lyon: IARC; 2013.
3. Dorfman HD, Czerniak B. Bone cancers. *Cancer* 1995;75:203-10.
4. Eric RC, Robert AO. Textbook and Color Atlas of Salivary Gland Pathology. Salivary Gland Pathology: Diagnosis and Management. 2nd ed. Johnson City, Tennessee: Willey Blackwell; 2016.
5. Ceylan K, Kizilkaya Z, Yavanoglu A. Extraskelatal myxoid chondrosarcoma of the nasal cavity. *Eur Arch Otorhino Laryngol* 2006;263:1044-7.
6. Miettinen M. Cartilage and bone-forming tumors and tumor-like lesions. *Diagnostic Soft Tissue Pathology*. Philadelphia, PA: Churchill-Livingstone; 2003. p. 407-9.
7. Ratnadeep G, Abhishek M. Maxillofacial extraskelatal myxoid chondrosarcoma: A case report and discussion. *Korean J Pathol* 2011;45:639-43.
8. Angiero F. Extraskelatal myxoid chondrosarcoma of the left buccal mucosa. *Anticancer Res* 2012;32:3345-50.
9. Oh YJ, Yang I, Yoon DY, Cho SJ, Lee Y, Woo JY, *et al.* Extraskelatal myxoid chondrosarcoma of the neck. *Dentomaxillofac Radiol* 2013;42:31808012.
10. Antonescu CR, Argani P, Erlandson RA, Healey JH, Ladanyi M,

- Huvos AG. Skeletal and extraskelatal myxoid chondrosarcoma: A comparative clinicopathologic, ultrastructural, and molecular study. *Cancer* 1998;83:1504-21.
11. Navdeep RS, Christine L, John P. Extraskelatal myxoid chondrosarcoma of the neck. *Otolaryngol Case Rep* 2017;2:22-5.
 12. Zaki M, Laszewski P, Robinette N, Saleh H, Raza N, Sukari A, *et al.* Unresectable extraskelatal myxoid chondrosarcoma of the neck: Early tumor response to chemoradiotherapy. *Cureus* 2015;7:e432.
 13. Acero J, Escrig M, Gimeno M, Montenegro T, Navarro-Vila C. Extraskelatal myxoid chondrosarcoma of the infratemporal fossa: A case report. *Int J Oral Maxillofac Surg* 2003;32:342-5.
 14. Jérôme-Marson V, Uro-Coste E, Lacoste-Collin L, Gomez-Brouchet A, Serrano E, Delisle MB. Extraskelatal myxoid chondrosarcoma of the nasopharynx. *Ann Pathol* 2003;23:253-7.
 15. Sotomayor EA, Sarma DP, Xiao S. Extraskelatal myxoid chondrosarcoma of oropharynx. *Int J Pathol* 2007;6:1.
 16. Shao R, Lao IW, Wang L, Yu L, Wang J, Fan Q. Clinicopathologic and radiologic features of extraskelatal myxoid chondrosarcoma: A retrospective study of 40 Chinese cases with literature review. *Ann Diagn Pathol* 2016;23:14-20.
 17. Jawad J, Lang J, Leader M, Keane T. Extraskelatal myxoid chondrosarcoma of the maxillary sinus. *J Laryngol Otol* 1991;105:676-7.
 18. Drilon AD, Popat S, Bhuchar G, D'Adamo DR, Keohan ML, Fisher C, *et al.* Extraskelatal myxoid chondrosarcoma: A retrospective review from 2 referral centers emphasizing long-term outcomes with surgery and chemotherapy. *Cancer* 2008;113:3364-71.
 19. Jung G, Cho KJ, Choi CH, Kim MJ. Dedifferentiated extraskelatal myxoid chondrosarcoma of the masticator space. A case reports. *Korean J Pathol* 2011;45(S1): S101-5.
 20. Romañach MJ, Carlos R, Nuyens M, de Andrade BA, de Almeida OP. Extraskelatal myxoid chondrosarcoma of the masticator space in a pediatric patient. *J Clin Exp Dent* 2017;9:e825-31.
 21. Englert TP, Kahn MR, Bushkoff SH, Mendelow H. Mandibular metastasis of an extraskelatal myxoid chondrosarcoma arising on the plantar surface of the foot: Report of case. *J Oral Surg* 1978;36:401-5.
 22. Tsuneyoshi M, Enjoji M, Iwasaki H, Shinohara N. Extraskelatal myxoid chondrosarcoma – A clinicopathologic and electron microscopic study. *Acta Pathol Jpn* 1981;31:439-47.
 23. Charabi S, Engel P, Bonding P. Myxoid tumours in the temporal bone. *J Laryngol Otol* 1989;103:1206-9.
 24. Liu-Shindo M, Rice DH, Sherrod AE. Extraskelatal myxoid chondrosarcoma of the head and neck: A case report. *Otolaryngol Head Neck Surg* 1989;101:485-8.
 25. Salcman M, Scholtz H, Kristt D, Numaguchi Y. Extraskelatal myxoid chondrosarcoma of the falx. *Neurosurgery* 1992;31:344-8.
 26. Sato K, Kubota T, Yoshida K, Murata H. Intracranial extraskelatal myxoid chondrosarcoma with special reference to lamellar inclusions in the rough endoplasmic reticulum. *Acta Neuropathol* 1993;86:525-8.
 27. Worley GA, Wareing MJ, Sergeant RJ. Myxoid chondrosarcoma of the external auditory meatus. *J Laryngol Otol* 1999;113:742-3.
 28. Oshiro Y, Shiratsuchi H, Tamiya S, Oda Y, Toyoshima S, Tsuneyoshi M, *et al.* Extraskelatal myxoid chondrosarcoma with rhabdoid features, with special reference to its aggressive behavior. *Int J Surg Pathol* 2000;8:145-52.
 29. De Las Casas LE, Singh HK, Halliday BE, Xu F, Strausbauch PH, Silverman JF. Myxoid chondrosarcoma of the sphenoid sinus and chondromyxoid fibroma of the iliac bone: Cytomorphologic findings of two distinct and uncommon myxoid lesions. *Diagn Cytopathol* 2000;22:383-9.
 30. Goh YW, Spagnolo DV, Platten M, Caterina P, Fisher C, Oliveira AM, *et al.* Extraskelatal myxoid chondrosarcoma: A light microscopic, immunohistochemical, ultrastructural and immuno-ultrastructural study indicating neuroendocrine differentiation. *Histopathology* 2001;39:514-24.
 31. Deik A, Azizi E, Shapira I, Boniece IR. Supraclavicular extraskelatal myxoid chondrosarcoma presenting with a sensorimotor polyneuropathy associated with anti-Hu antibodies. *Oncology (Williston Park)* 2009;23:718-21.
 32. Bahri I, Boudawara T, Sellami A, Khabir A, Ghorgel M, Drira M, *et al.* A rare tumor of the parapharyngeal space: Myxoid chondrosarcoma. *Rev Laryngol Otol Rhinol (Bord)* 2002;123:255-8.
 33. González-Lois C, Cuevas C, Abdullah O, Ricoy JR. Intracranial extraskelatal myxoid chondrosarcoma: Case report and review of the literature. *Acta Neurochir (Wien)* 2002;144:735-40.
 34. Cummings TJ, Bridge JA, Fukushima T. Extraskelatal myxoid chondrosarcoma of the jugular foramen. *Clin Neuropathol* 2004;23:232-7.
 35. Jörg S, August C, Stoll W, Alberty J. Myxoid chondrosarcoma of the maxilla in a pediatric patient. *Eur Arch Otorhinolaryngol* 2006;263:195-8.
 36. Saint-Blancard P, Jancovici R, Ceccaldi B, Lagace R, Sastre-Garau X. Extraskelatal myxoid chondrosarcoma of the neck: Report of a case with lymph nodes metastasis. *Rev Med Interne* 2006;27:160-2.
 37. Nakazora S, Kusuzaki K, Matsubara T, Shintani K, Matsumine A, Fukutome K, *et al.* Extraskelatal myxoid chondrosarcoma arising from the clavicle. *Oncol Rep* 2006;16:115-8.
 38. Betz CS, Janda P, Arbogast S, Leunig A. Myxoma and myxoid chondrosarcoma of the nasal septum: Two case reports. *HNO* 2007;55:51-5.
 39. Kim YJ, Im SA, Lim GY, Chun HJ, Park HJ, Kim MS, *et al.* Myxoid chondrosarcoma of the sinonasal cavity in a child: A case report. *Korean J Radiol* 2007;8:452-5.
 40. O'Brien J, Thornton J, Cawley D, Farrell M, Keohane K, Kaar G, *et al.* Extraskelatal myxoid chondrosarcoma of the cerebellopontine angle presenting during pregnancy. *Br J Neurosurg* 2008;22:429-32.
 41. Willems SM, Schrage YM, Baelde JJ, Briaire-de Bruijn I, Mohseny A, Sciort R, *et al.* Myxoid tumours of soft tissue: The so-called myxoid extracellular matrix is heterogeneous in composition. *Histopathology* 2008;52:465-74.
 42. Kaplan I, Shah SS, Nicolaou-Ioannou Z, Fliess DM. Clinical-pathological conference: Case 1. *Head Neck Pathol* 2010;4:214-20.
 43. Meis-Kindblom JM, Bergh P, Gunterberg B, Kindblom LG. Extraskelatal myxoid chondrosarcoma: A reappraisal of its morphologic spectrum and prognostic factors based on 117 cases. *Am J Surg Pathol* 1999;23:636-50.
 44. Oliveira AM, Sebo TJ, McGrory JE, Gaffey TA, Rock MG, Nascimento AG. Extraskelatal myxoid chondrosarcoma: A clinicopathologic, immunohistochemical, and ploidy analysis of 23 cases. *Mod Pathol* 2000;13:900-8.
 45. Hachitanda Y, Tsuneyoshi M, Daimaru Y, Enjoji M, Nakagawara A, Ikeda K, *et al.* Extraskelatal myxoid chondrosarcoma in young children. *Cancer* 1988;61:2521-6.
 46. Stacchiotti S, Dagrada GP, Morosi C, Negri T, Romanini A, Pilotti S, *et al.* Extraskelatal myxoid chondrosarcoma: Tumor response to sunitinib. *Clin Sarcoma Res* 2012;2:22.