

原文題目(出處)：	Regeneration or replacement? A case report and review of literature. Dental Traumatology Dental Traumatology 2016; 32:71-9
原文作者姓名：	Ali Reza Farhad1, Ali Shokrane, Neda Shekarchizade
通訊作者學校：	Neda Shekarchizade, Department of Endodontics, School of Dentistry, Isfahan University of Medical Sciences, Isfahan, Iran
報告者姓名(組別)：	黃翊鈞 Intern B 組
報告日期：	2016/9/6

內文：

A. Abstract

一、 Endodontic treatment of immature necrotic teeth is a real challenge. Recently, a biologically based treatment strategy, referred to as regeneration, has been introduced. Tissue regeneration requires the presence of

1. stems cells
2. a scaffold
3. growth factors

Endodontic regeneration may improve the prognosis of immature necrotic teeth by reestablishing the functional pulpal tissue and further development of the root. However, the tissue formed in the pulpal space may not be original pulp tissue, and in some cases, it may result in uncontrolled calcification of the pulp. This study reports a case of successful endodontic regeneration and compares this process with the normal development of the contralateral tooth. Finally, it discusses the nature of the tissue formed during endodontic regeneration.

二、 An **open apex** is seen in an immature tooth, in which the root is still developing. The apex is completely formed approximately 3 years after tooth eruption. During development of the root, pathological changes in the pulp can hinder the apposition of dentin, resulting in the cessation of root development. In such circumstances, **the developmental stage of the root is the main factor to be considered in treatment planning.**

1. **In reversible pulpitis**, regardless of the stage of root development, vital pulp therapy is the treatment of choice.
2. In **irreversible pulpitis or necrotic pulp**, the root developmental stage determines the best treatment option:
 - i. if the apex is completely formed, conventional root canal therapy is carried out
 - ii. if the apex is open, other treatment options, including:
 - a. **apexification with calcium hydroxide [Ca (OH)2]**
 - b. **use of an apical plug**
 - c. **a regeneration procedure**

三、 An immature tooth with a necrotic pulp does not have residual progenitor pulpal cells to continue root development. The main goals of conventional root canal therapy, including:

1. complete cleaning
2. shaping
3. appropriate obturation

Cannot be achieved in an immature root. Moreover, the **short, weak, and fracture-prone root** of an immature tooth becomes even **weaker** after mechanical

instrumentation of the root canal. Apexification with $\text{Ca}(\text{OH})_2$ or an apical plug may solve many of the problems associated with conventional root canal therapy; however, there is still the risk of horizontal root fracture especially at the cervical area and tooth mobility due to compromised crown-to-root ratio.

1. Frank proposed apexification with $\text{Ca}(\text{OH})_2$, in which $\text{Ca}(\text{OH})_2$ is used in multiple visits during a long period of treatment to induce an apical barrier. In addition to the extended treatment period, long-term contact of dentin with $\text{Ca}(\text{OH})_2$ decreases the mechanical strength of dentin, making the tooth susceptible to fracture.
 2. Torabinejad and Chivian suggested the use of a mineral trioxide aggregate (MTA) plug as an alternative technique for apexification with $\text{Ca}(\text{OH})_2$. An MTA plug provides a barrier at the apical region. A high success rate has been reported for this procedure ; however, horizontal root fracture is still possible and the root cannot develop further.
 3. Cvek reported a higher incidence of cervical root fracture in root-filled immature teeth compared to mature teeth. Therefore, preserving the pulp vitality of immature teeth with deep caries or dental trauma is of great importance.
 4. Nygaard & Ostby, a pioneer in regenerative procedures in endodontics, has shown that a new, highly vascular tissue may be formed in the unfilled portion of the root canal at the apical third of a mature root with a necrotic pulp and a periapical lesion. Accordingly, the ideal outcome for teeth with an immature root and necrotic pulp would be formation of vascularized tissue in the canal space capable of inducing normal root development.
- 四、The regeneration process depends on the presence of osteoblast and odontoblast progenitor stem cells in the apical dental papilla, which are resistant to infection and necrosis within the canal due to their vicinity to periodontal blood vessels. The aim is to create a suitable environment so that the periapical stem cells can proliferate into the root canal space for regeneration of pulp tissue and continuation of root development .
- 五、In the present case report, a regenerative endodontic procedure was performed in the upper left central incisor, which had undergone pulp necrosis and developed periapical lesion due to trauma. The success of treatment was evaluated and compared with upper right central incisor, which had a healthy pulp with normal root development. Finally, a literature review covering the regenerative endodontic procedures is presented, and the nature of the tissue formed during this process is discussed.

B. Case report

- 一、A healthy 8-year-old male patient with a history of trauma to the maxillary left central incisor (tooth #9) was referred to the Department of Endodontics, School of Dentistry, Isfahan University of Medical Sciences. The medical history of the patient was non-contributory. The patient had a history of trauma to the upper central incisors 45 days before the initial visit with no prior treatment at the time of trauma. The patient's chief complaints were fever, pain, and swelling of the upper lip. The patient had malaise and an elevated temperature (37.7°C).

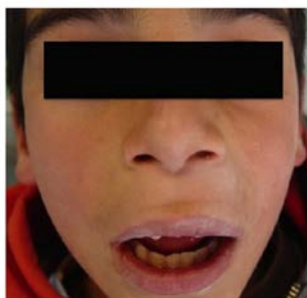

Fig. 1. Extra-oral swelling of the left corner of the upper lip was present.

Table 1. Pulpal and periapical diagnosis of the case and control teeth

Tooth number	Cold	Heat	EPT	Per	Palp	Mob
#7	N	N	R	+	+	WNL
#8	N	N	R	+	+	WNL
#9	0	0	0	++	++	+1
#10	N	N	R	+	+	WNL

Cold and Heat tests, N, normal; 0, no response; +, mild; ++, moderate; EPT, electrical pulp tester; Per, percussion; Palp, palpation; R, response; 0, no response; Mob, mobility; WNL, within normal limit; +1, the first distinguishable sign of movement greater than normal; +2, horizontal tooth movement no >1 mm; +3, horizontal tooth movement no >1 mm, with or without the visualization of rotation or vertical depressability.

二、 Extra-oral examination revealed an upper left facial swelling (Fig. 1). Intra-oral examination showed a buccal vestibule swelling next to the maxillary left central incisor. Clinical examination of the upper anterior teeth indicated a complicated crown fracture of tooth #9 and an uncomplicated crown fracture of tooth #8. Tooth #9 exhibited no response to thermal and electrical pulp tests. The patient reported pain on percussion and palpation tests of tooth #9. The tooth showed increased mobility, and the periodontal probing was within normal limits. The adjacent maxillary anterior teeth responded normally to cold when tested and were slightly sensitive to percussion and palpation (Table 1). Radiographic examination revealed immature root of teeth #8 and #9 and a periapical radiolucent lesion associated with tooth #9 (Fig. 2a). Based on clinical and radiographic findings, a pulpal diagnosis of necrotic pulp and periapical diagnosis of acute apical abscess were made for tooth #9. As immature permanent teeth with necrotic pulp, with or without apical pathosis, and incomplete root development with an apical opening of 1 mm or larger are considered suitable candidates for regenerative endodontics, this treatment was selected. A written informed consent was obtained from the patient's guardian after explaining the treatment procedure, risks, and benefits.

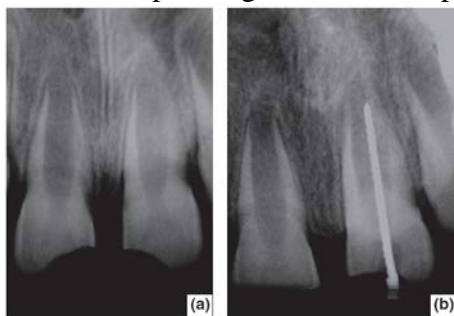


Fig. 2. (a) Diagnostic radiograph before treatment. Teeth #8 and #9 show open apex and crown fractures. (b) Working length radiograph. A #100 K-file was introduced into the root canal. Working length was 22 mm.

三、 Local anesthesia was induced using 2% lidocaine with 1:100 000 epinephrine. After application of a rubber dam, an access cavity was prepared in tooth #9. Upon entry into the root canal, purulent discharge was noted. The working length was determined using an apex locator (Root ZX II; Dentsply, J-Morita Inc., Irvine, CA, USA) and confirmed by a periapical radiograph (Fig. 2b). The root canal was passively irrigated with 20 ml of 5.25% sodium hypochlorite (NaOCl) without instrumentation and gently dried with sterile paper points. A creamy mix of Ca(OH)₂ was placed in the root canal, and the tooth was restored temporarily with Cavit (3M ESPE, Neuss, Germany). The fractured dentinal surfaces of tooth #9 were

completely covered after the medicament was placed to create a bacterialtight seal.

- 四、 Tooth #8, with an **uncomplicated crown fracture**, was restored with **resin-modified glass-ionomer liner** (Vitrebond™ Plus Light Cure Ionomer Liner/Base; 3M Center, St. Paul, Minnesota, USA) and **composite resin**.
- 五、 After 3 weeks, the patient was asymptomatic; intra and extra-oral swelling had subsided, and the maxillary left central incisor was no longer tender to percussion or palpation. After rubber dam isolation and induction of local anesthesia with 3% plain mepivacaine (Septodont, Cedex, France), the temporary restoration was removed and the canal was irrigated with 5.25% NaOCl. A sterile **#20 K-file** was used to induce bleeding within the root canal from the periradicular tissues. After **15 min**, **MTA powder** (Pro-Root MTA; Dentsply Tulsa Dental, Tulsa, OK, USA) and distilled water were mixed according to the manufacturer's instructions. Using a sterile amalgam carrier, approximately **3 mm of MTA** was placed in the **coronal third** of the root canal. MTA was gently adapted to dentinal walls with a **moist cotton pellet**. The moist cotton pellet was placed on the MTA, and the tooth was temporarily restored. After **1 week**, the temporary restoration was removed and **resin-modified glass-ionomer** (Vitrebond™ Plus Light Cure Ionomer Liner/Base) was placed on the MTA and the tooth was temporarily restored; the patient was referred for permanent restoration of tooth #9.
- 六、 The patient was **recalled at 6, 9, 15, and 18 months** postoperatively for clinical and radiographic follow ups (Fig. 3). At follow-up appointments, the tooth was asymptomatic and functional. **No recurrence of pain and/or swelling** was reported by the patient during this period. At 18-month recall, teeth #8 and #9 responded normally to **cold** and **electrical pulp tester** vitality tests (Table 2). Radiographic examinations revealed that the periapical lesion had healed, exhibiting similar root development to that of maxillary right central incisor. The root length and thickness had increased and apical closure was evident (Fig. 3).

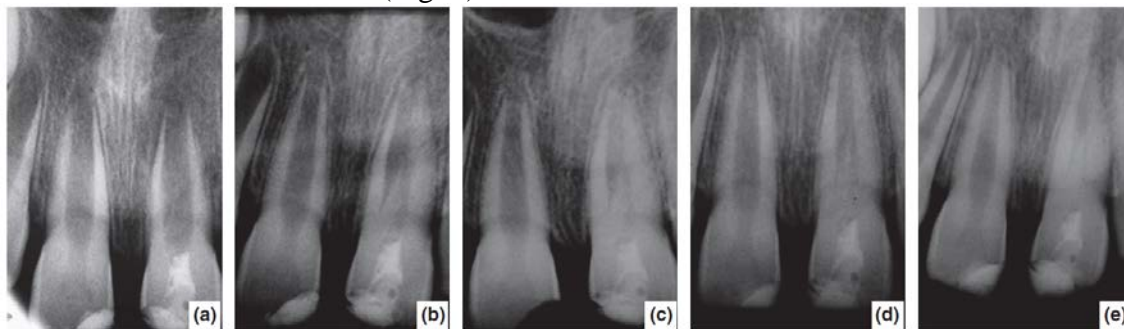


Fig. 3. Radiographic follow-up examination: (a) 3 weeks, (b) 6 months, (c) 9 months, (d) 15 months and (e) follow-up radiograph after 18 months: the root length and thickness have increased, and apical closure is evident.

Table 2. Clinical testing for tooth #9 at the follow-up appointments

Follow up at month	Cold	Heat	EPT	Per	Palp	Mob
6	N	0	R	0	0	WNL
9	N	0	R	0	0	WNL
15	N	0	R	0	0	WNL
18	N	0	R	0	0	WNL

Cold and Heat tests, N, normal; 0, no response; +, mild; ++, moderate; EPT, electrical pulp tester; Per, percussion; Palp, palpation; R, response; 0, no response; Mob, mobility; WNL, within normal limit; +1, the first distinguishable sign of movement greater than normal; +2, horizontal tooth movement no >1 mm; +3, horizontal tooth movement no >1 mm, with or without the visualization of rotation or vertical depressability.

C. Discussion

The factors required for successful endodontic regeneration include

1. absence of infection within the root canal space
2. proper coronal seal
3. physical scaffold
4. signaling molecules
5. stem cells.

一、Disinfection of the root canal space

1. Removal of the necrotic pulp and disinfection of the root canal are important prerequisites for a proper response to regenerative endodontic treatments; this aim is partially achieved by irrigation of the root canal with **5.25% NaOCl solution**. NaOCl is a potent antibacterial agent, which effectively dissolves necrotic and organic debris. Its dissolving capacity depends on its **concentration and the frequency** of using the fresh solution. After irrigation of the root canal with NaOCl and **sterile saline solution**, **2% chlorhexidine** has been recommended for the final rinse. Chlorhexidine has antibacterial activity with **adequate substantivity**. As chlorhexidine **lacks tissue dissolving capacity**, it should not be used as the sole irrigation solution for this purpose.
2. Galler et al. showed that short exposure to chlorhexidine **before ethylenediaminetetraacetic acid (EDTA)** treatment increased transforming growth factor- β 1 (TGF- β 1) β 1 release. They indicated that if chlorhexidine was in contact with the dentin for a longer period (10 min), protein stability might be negatively affected and growth factor release might be reduced due to its acidity, or binding of cationic chlorhexidine to hydroxyapatite.
3. Disinfection of the root canal space is completely achieved using **antibiotic mixture** or **Ca(OH)₂ paste** as an intracanal medicament. Both **Ca(OH)₂** and **low concentration of triple antibiotic paste** are biocompatible. Hoshino et al. introduced triple antibiotic paste consisting of **ciprofloxacin, metronidazole, and minocycline**. They reported that this combination effectively eliminates 消除 bacteria from the infected root canals and promotes regeneration of periapical tissues. Banchs and Trope used this antibiotic combination for regeneration purposes. The triple antibiotic paste is effective in eliminating bacteria in vivo and in vitro.
4. Tooth discoloration 變色 is a commonly encountered problem after endodontic regeneration, which is mainly attributed to the **minocycline** in the formulation of **triple antibiotic paste**. Thibodeau and Trope replaced minocycline in the triple antibiotic paste with **cefaclor** to prevent dentin discoloration due to minocycline. Reynolds et al. covered the pulp chamber

dentinal tubules with resin bonding agent before placement of antibiotic paste in order to minimize tooth discoloration due to minocycline. Miller et al. reversed tooth discoloration due to triple antibiotic paste with internal bleaching.

5. da Silva et al. used 5.25% NaOCl along with Endovac to create negative apical pressure in an animal model in regenerative endodontic treatment for root canal disinfection; however, no intracanal antibiotic was used in this process. The success of this new technique was confirmed by histological analysis 組織學分析. The technique resulted in shorter duration of procedure and also prevented tooth discoloration by omitting 省略 the need for an intracanal medicament (34).
6. Ca(OH)₂ can be used to disinfect the root canal system. Ca(OH)₂ is an antimicrobial 抗菌 agent and can dissolve the necrotic tissue in the root canal system. It can also induce apical closure by hard tissue formation (13, 35). In addition, it serves as a physicochemical barrier 物理屏障, prevents proliferation of residual microorganisms 防止殘留微生物增生 within the root canal system, and prevents re-contamination 防止再污染 of the root canal through the oral cavity (35). On the other hand, due to high pH, it can destroy cells in the periapical area (19, 36). Thus 因此, it may prevent the ingress of stem cells 幹細胞的浸透 into the root canal (36).
7. Ruparel et al. showed that higher concentrations of triple antibiotic paste (1, 10, and 100 mg ml⁻¹) had detrimental 有害 effects on stem cells, but lower concentrations (0.1 mg ml⁻¹, and 0.01 mg ml⁻¹) had no detectable effect on stem cell survival. They showed that stem cells remain viable 存活 at 0.01–100 mg ml⁻¹ concentrations of Ca(OH)₂. Bose et al. showed that the increase in the thickness of canal walls was significantly greater with the use of triple antibiotic paste compared to the use of Ca(OH)₂. In the present case, the root canal was irrigated with 20 ml of 5.25% NaOCl, and Ca(OH)₂ was placed in the root canal for 3 weeks to achieve proper disinfection.

二、 Coronal seal

1. One of the main prerequisites for successful regeneration is the prevention of bacterial ingress into the disinfected root canal. To achieve a hermetic seal, placing glass-ionomer cement on Cavit has been suggested, which is referred to as coronal double restoration. Eugenol-containing temporary cement should not be used because it prevents polymerization of composite resin as the final restoration. In the present case, Cavit was used as a temporary restoration to cover all fracture surfaces and achieve a bacterial-tight coronal seal.

三、 Scaffold

1. A scaffold provides a framework for the growth and proliferation of cells and blood vessels. An ideal scaffold should selectively bind to cells, have growth factors, and disintegrate with time. Scaffolds can bind to various factors and promote growth and differentiation of cells. A scaffold can be manufactured of synthetic materials such as polyglycol or natural substances such as cellular non-mineralized tissue matrix or collagen alone. Endodontic regeneration has been brought about with or without a physical scaffold. In a large number of studies, a blood clot has been used as a scaffold, which in addition to being a scaffold contains factors that can

- induce growth and differentiation of cells into odontoblast-like cells. Collagen is used alone or in conjunction with a blood clot as a scaffold.
2. Yamauchi et al. carried out a histomorphometric analysis on a canine tooth and showed that during the regeneration process, when blood clot and crosslinked collagen were used as a scaffold, formation of hard tissues of the canal walls increased significantly. After induction of hemorrhage 出血, the mesenchymal stem cells penetrate into the root canal space, but this process does not take place in the absence of a blood clot within the root canal. After disinfection of the canal, a blood clot forms in the root canal space containing platelet-derived growth factors and a scaffold rich in proteins. In an animal study, teeth with blood clots exhibited superior radiographic results compared to those without blood clots.
 3. Sometimes, during the regeneration treatment, there is insufficient or no hemorrhage even in cases for which a local anesthetic without a vasoconstrictor has been used; this can be due to incomplete root development. Absence of a blood clot reflects unsuccessful endodontic regeneration in human and animal studies.
 4. Jung et al. attributed the failure of endodontic regeneration treatment modality to the inability to induce hemorrhage in the root canal. On the other hand, there are some reports about successful endodontic regeneration without induction of hemorrhage. Although the presence of a blood clot increases the chances of favorable results, its presence may not be absolutely necessary.
 5. Whitmann introduced platelet-rich plasma (PRP), and its use has been suggested as a scaffold for endodontic regeneration. PRP consists of growth factors, which induce collagen synthesis, recruit other cells to the injury site, induce production of anti-inflammatory agents, initiate vascular growth, induce cellular differentiation, control local inflammatory response, and assist in the healing of injured soft and hard tissues. PRP increases the concentration of growth factors, which can attract the stem cells in periapical tissues to the root canal. The advantages of PRP include relatively easy use and a shorter time to induce vital tissues within the root canal; its disadvantages include the need for blood from young patients, use of equipment and drugs for its preparation, and the high cost of treatment.
 6. Buurma et al. and Gotlieb et al. suggested the use of polymer scaffolds, of which polylactic acid, polyglycolic acid, polylactic-co-glycolic acid, and Polyepsilon caprolactone can be mentioned.
 7. In the case presented here, a proper scaffold was produced for the ingress and growth of stem cells by the induction of hemorrhage and formation of a blood clot.
- 四、 Signaling molecules
1. Dentin contains a mixture of growth factors and cytokines sequestered in the matrix during dentinogenesis. This fossilized pool of bioactive growth factors provides a source of signaling molecules for future regenerative events after tissue injury. Previous studies have shown that the use of EDTA can expose this reservoir of growth factors from dentin. MTA placed on the blood clot may provide the signaling molecules for the growth of stem cells. Asgary et al. showed that the direct contact of human dental pulp stem cells with MTA resulted in adhesion, spreading, and proliferation of these cells. They indicated that transforming growth factor- β 1 (TGF- β 1), fibroblast

growth factor 4 (FGF4), bone morphogenetic protein (BMP) 2, and BMP4 were expressed in MTA group, and the expression of TGF- β 1 gene was significantly more in MTA than in calcium-enriched mixture (CEM) group. TGF- β 1, FGF4, BMP2, and BMP4 are inducers of odontogenic differentiation and activity.

2. In addition, Tomson et al. showed that MTA may release TGF- β 1 from dentine.
3. Petrino et al. recommended the use of a collagen matrix for the coronal placement of MTA at an appropriate level of the root canal
4. However, Torabinejad and Parirokh reported that placing a collagen matrix or other barriers may decrease the conductive and inductive properties of MTA.

Regenerated tissue

5. A loose connective pulp-like tissue fills the root canal space up to the MTA plug 3.5 weeks after the regeneration process. The pulp-like tissue may be produced due to:
 - i. the proliferation of the residual apical pulp tissue after the regeneration processor
 - ii. the proliferation and differentiation of the apical papilla after its penetration into the canal space.

This scenario is the ideal and desired outcome; however, it is seldom found.
6. It has been demonstrated that the stem cells originating from the apical papilla have a higher potential to differentiate into odontoblast-like cells, compared to stem cells with an origin of dental pulp. The tissue located at the apical portion of the root canal space is rich in cells and blood vessels. The majority of cells found in periapical tissues and in the loose connective tissue in the root canal are fibroblasts or mesenchymal cells. A layer of flat cells similar to root odontoblasts are found along predentin in the apical area of the root canal. It is not clear whether these odontoblast-like cells are primary odontoblasts or newly differentiated odontoblasts, which have originated from the apical papilla after the regeneration process. There are only a few collagen fibers in the root canal space. Nerve-like fibers are not found along the blood vessels as in the mature pulp, indicating that loose connective tissue in the canal space is a newly formed immature pulp-like tissue. A layer of epithelial-like cells similar to Hertwig's epithelial root sheath (HERS) surrounds the root apex, which regulates the continuation of root maturation. STRO-1-positive stem cells have been identified in the loose connective tissue near the apical foramen, which might have originated from the apical papilla because the stem cells from the developing apical papilla have more numerous STRO-1-positive cells compared to stem cells with an origin of mature tooth pulp. Mesenchymal stem cells with a papillary origin can differentiate into odontoblasts under suitable environmental conditions.
7. da Silva et al. in a histological study showed that the tissue inside the root canal space after regenerative endodontic treatment was ingrowth of periodontal connective tissue instead of pulp tissue. The pulpal tissue, periodontal ligament (PDL), dentin, cementum, and bone have been identified in the root canal space of teeth, which have undergone endodontic regenerative treatment.

8. Torabinejad et al. carried out a histological evaluation of the tissue formed in the root canal space of ferret teeth, which had undergone a regenerative endodontic treatment. They showed that the newly formed tissue inside the root canal space mainly consisted of **bone along with cementum and PDL ingrowth from periradicular tissues, without any evidence of pulp tissue regeneration.**
9. Andreasen and Bakland, in a recent review, described **four types of healing outcomes** in autotransplanted 自體移植 premolars namely:
 - i. pulp re-vascularization with accelerated dentin formation, which results in the obliteration of the root canal
 - ii. growth of cementum and PDL
 - iii. growth of cementum, PDL, and bone
 - iv. growth of bone and bone marrow
10. A histological study evaluated the tissue within the root canal of dog's teeth after endodontic regenerative treatment. The results showed **cementum-like, bonelike, and PDL-like** tissues within the root canal space. Within the root canal, two types of hard tissue were identified:
 - i. **a dentin-associated mineralized tissue (DAMT)**, which was attached to or was adjacent to the dentin wall and had no blood vessels
 - ii. **bony islands** in the canal space without any connection with the dentin wall, which **consisted of blood vessels, cells, and bone marrow-like tissue**

The nature of **DAMT** is different from that of dentin and bone, and it appears to be an extension of cementum. Although the absence of blood vessels and immunostaining patterns in DAMT are similar to those in the **cementum**, its organization and collagen fiber maturation are different. The **bony islands** were similar to those of the **alveolar bone**. The odontoblast cell layer, dentinlike structures, and pulp-like tissues were not found.
11. Histological evaluations in animal studies have shown that the tissue within the root canal is **not pulpal tissue** and therefore **does not have a function** similar to that of pulpal tissue. However, histological findings in animal studies **may be different** from those of human studies.
12. Experimental use of **TGF- β 1** on the pulpal tissue in dogs showed that growth factors produce the necessary signals for the differentiation of **odontoblast-like cells**. **TGF- β 3** and **other members of the BMP family** are also involved in signaling for the differentiation of **odontoblast-like cells**. Therefore, epigenetic signaling can be repeated for the differentiation of **odontoblasts by growth factors** during the endodontic regeneration process.
13. **Epithelium-derived epigenetic signaling** results in the differentiation of odontoblasts during root development. However, in mature teeth, due to the absence of epithelium, alternative derivatives are required for this signaling.
14. **Epithelium-derived epigenetic signals** are not produced after the development of teeth, and as concentration of growth factors is not controlled during the regenerative endodontic treatment and their concentration is not the same as the signals during tooth development, the differentiated cells during the regeneration process will **not be primary odontoblasts** and **might be odontoblast-like cells**; therefore, the tissue formed in the pulp space will **not be a primary or initial tissue**.
15. Trope used the term '**revascularization**' for events that occur after dental trauma due to the belief that the tissue formed after treatment is not

- predictable, but it will certainly contain blood vessels.
16. Huang and Lin believed the term ‘revascularization’ was more appropriate for events that occur after dental trauma and suggested the expression ‘induced or guided tissue **generation** and **regeneration**’ for the process.
 17. Lenzi and Trope believed the term ‘**revitalization**’ was more appropriate because it better describes the non-specific vital tissue in the root canal.
 18. Hargreaves et al. suggested the term ‘**maturogenesis**’ because the aim is to reproduce the dentin–pulp complex with functional properties, which results in continuous maturation of the root.
 19. Wigler et al. (95) believed the term ‘**maturogenesis**’ was more appropriate and suggested that the term ‘revascularization’ or ‘revitalization’ should not be used.
 20. Treatment of an empty root canal with regenerative strategy is a real challenge. Further studies are necessary on the type of scaffold, the source and recruitment of stem cells, and the correct signaling molecules for induction of maturation and neovascularization to understand the basic cellular processes involved in endodontic regenerative treatment. Initial studies reported that induction of hemorrhage in the root canal space is the possible local source for viable cells, indicating that viable cells originate from **blood, cementum, PDL, or the alveolar bone** and therefore **do not have pulpal origin**. Despite the publication of many case reports and case series, there are inadequate data on the processes involved in this treatment approach. It is a matter of controversy whether the tissue within the root canal has been produced due to repair or regeneration. Revascularization allows the **vital** filling of the pulp space, which is **different from the initial tissue** present within the root canal space. In **only one case report**, the presence of parallel real odontoblasts within a wellorganized pulp tissue was shown. The discrepancy between this case and a large number of other cases in this respect has been attributed to the fact that in this case, **the pulp suffered from pulpitis and was not necrotic**. The exact term ‘**regeneration**’ is used when **a pulpal tissue is formed within the root canal space**. Based on this definition, at present, none of the treatment strategies can be regarded as regeneration and should be considered **a reparative treatment strategy**.
 21. Healing occurs by primary or secondary intention. In primary intention, all components of tissues regenerate and tissues return to their normal micro-architecture and function, which is called ‘**regeneration**’. In secondary intention, tissues **do not** return to their normal architecture and function. Instead, the tissue is **repaired and replaced** by the formation of scar tissue. As in regenerative endodontic treatment, the tissue formed in the root canal space is **not** a complete reformation of initial tissues and is **not** formed by **primary** intention but by secondary intention, we feel the term ‘**replacement**’ might be more appropriate.
 22. In the case presented, as calcification of root canal space was seen on radiographs at follow up, it is hypothesized that the tissue forming in the root canal space may contain **odontoblast-like, osteoblast-like, and cementoblast-like cells or a combination of the previously mentioned cells**, which produce **dentoid, osteoid and cementoid tissues**, resulting in an increase in length and thickness of the root and apical closure.
- 五、 Root maturation
1. Ideally, root maturation in immature teeth consists of an **increase in root**

length, an increase in the thickness of root canal walls, and formation of the root apex.

2. Chen et al. reported that the potential of root maturation in immature necrotic teeth depends on the vitality of Hertwig's epithelial sheath. Therefore, there might be a relationship between dental history and the quality of root maturation. A longer duration of pulp necrosis can cause a lower quality of root development after regenerative endodontic treatment.
3. Lenzi and Trope discussed the possibility of necrosis of cells capable of revitalization, cells with the capacity to recruit new vital tissue, or the progenitor cells at the apex with longstanding infection.
4. Nosrat et al. evaluated the dental histories in all the studies since 2004, which showed successful results with regeneration treatment. The results indicated that in cases in which the treatment was successful, the duration of pulp necrosis was <6 months.
5. The first factor affecting the choice of the treatment plan is the patient's age. The recommended age for regenerative endodontic treatment is 8–18 years. The patient in the present case was in the recommended age bracket for such a treatment modality. The second factor is the time interval between the trauma and the patient's presentation.
6. Based on the study by Nosrat et al., our patient in this case had an optimal condition for this treatment option because Hertwig's epithelial sheath (HERS) was most probably vital. The radiographic evidence, in this case, showed an increase in root length and thickness at 6 and 9 months and complete formation of the apex at 18 months.
7. In comparison to the contralateral tooth in which natural development occurred, calcification of root canal space was seen on radiographs at follow-up sessions in the tooth treated with regenerative endodontic technique. It is assumed that stem cells entering the root canal space may differentiate to odontoblast-like, osteoblast-like, and/or cementoblast-like cells, which produce dentinoid, osteoid, and/or cementoid tissues.

D. Conclusion

1. To determine whether a therapeutic intervention can be considered successful or not, the aim of treatment should be clearly defined. If the aim is to induce periapical tissue healing and osseous regeneration and if the patient is asymptomatic, the process can be considered successful. The clinical 'success' outcome of endodontic regeneration can be in two forms:
 - i. The entire length of root canal space up to the MTA is filled with a vital tissue, which results in thickening of dentinal walls and continued root development
 - ii. only the apical part of the root canal space is filled with vital tissue followed by complete apical closure, while the more coronal parts of the root canal do not undergo further changes.

If the aim is to achieve regeneration of the original pulp tissue, the process is considered a failure. In summary, the regeneration treatment procedure can be considered a clinical success but a biological failure.

E. Conflict of interest

The authors declare no conflict of interests for this paper.

題號	題目
1	下列何者非 Regeneration therapy 的要素之一? (A) Stem cells

	(B) Bacteria (C) Scaffolds (D) Grow factors
答案(B)	出處：Cohen's Pathways of the Pulp. P.603
題號	題目
2	下列何者非適當的 Scaffolds of regeneration therapy 所需有的條件?
	(A) Regulate differentiation (B) Provide a spatially correct position of cell location (C) Regulate immune system (D) Regulate proliferation
答案(C)	出處：Cohen's Pathways of the Pulp. P.605