

原文題目(出處)：	Responses of the pulp, periradicular and soft tissues following trauma to the permanent teeth. Aust Dent J 2016;61:(1 Suppl) 39-58
原文作者姓名：	CY Yu, PV Abbott
通訊作者學校：	School of Dentistry, The University of Western Australia, Western Australia, Australia.
報告者姓名(組別)：	朱庭葳 (Intern B 組)
報告日期：	105.09.06

內文：

一、 Abstract

1. Trauma to the permanent teeth

- (1) Involves not only the teeth but also the pulp, the periodontal ligament, alveolar bone, gingiva and other associated structures. A tooth may sustain more than one injury at the same time.
- (2) In more severe trauma cases, there are many different cellular systems of mineralized hard and unmineralized soft tissues involved, each with varying potential for healing.
- (3) Healing subsequent to dental trauma has long been known to be very complex.

2. In this review

- (1) The tissue responses are described under the tissue compartments typically involved following dental trauma: the pulp, periradicular and associated soft tissues.
- (2) The factors involved in the mechanisms of trauma are analyzed for their effects on the tissue responses.
- (3) Understanding of the possible tissue responses is imperative for clinicians to overcome the confusion and manage dental trauma adequately and conservatively in order to minimize the consequences following trauma.

二、 Introduction

1. Dental trauma is the injury sustained by a tooth and its supporting structures from acute transmission of impact energy.
2. In order to re-establish the integrity, these tissues
 - (1) Respond with inflammation at the local level to defend the body against infection and foreign substances.
 - (2) Dispose of necrotic damaged tissues, which facilitate repair and regeneration from adjacent viable tissues.
3. There are many tissue types involved
 - (1) Including pulp, PDL, gingiva and mucosa, enamel, dentine, cementum and alveolar bone.
 - (2) A multitude of factors will directly or indirectly affect the magnitude of the tissue inflammatory process.
 - (3) The responses of these tissues will determine the treatment required and the outcome/consequence of the involved teeth.
4. This paper will present the tissue responses to trauma.
 - (1) The factors will be considered subsequently under the categories of mechanical and biological factors.

(2) Tissue responses can be favorable or unfavorable in nature.

Table 1. Possible responses of the pulp and root canal system, the periradicular tissues, and the soft tissues following trauma to a tooth

	Pulp/root canal system	Periradicular tissues	Soft tissues
Favourable responses	Recovery and return to normal Tertiary dentine formation Pulp revascularization Pulp fibrosis Pulp canal calcification	Recovery and return to normal Fibrous healing Transient apical breakdown	Recovery and return to normal Transient marginal breakdown Fibrous healing (scar)
Unfavourable responses	Chronic pulp inflammation (pulpitis) Pulp necrobiosis with Pulp necrosis without infection, with infection Infection of the root canal system Internal root resorption surface, inflammatory, and/or replacement Combinations of the above: <i>simultaneously and/or sequentially over time</i>	Cessation of root development Disturbances to root development Bone resorption crestal, apical, and/or lateral External root resorption surface, inflammatory, replacement, and/or invasive Ankylosis: with or without root resorption Combinations of the above: <i>simultaneously and/or sequentially over time</i>	Loss of attachment/ permanent marginal breakdown Gingival recession Combinations of the above: <i>simultaneously and/or sequentially over time</i>

5. The most common injuries are relatively minor
 - (1) Enamel infractions, uncomplicated crown fractures, concussions and subluxations.
 - (2) Rarely pose a risk to the health or survival of the injured teeth. Favorable responses need no or minimal intervention apart from follow-up.
6. Unfavorable responses
 - (1) Lateral luxations, intrusions and avulsions with replantation.
 - (2) The most serious and complicated consequences: pulp necrosis and infection of the root canal system, external inflammatory root resorption, external replacement root resorption, ankylosis, bone resorption, loss of attachment and gingival recession followed by subsequent tooth loss.
7. Several recent studies have revealed that emergency management of dental injuries can sometimes lead to inferior healing consequences.
 - (1) When assessing wound healing after trauma, one must also consider that these responses may occur concurrently or sequentially over time.
 - (2) A thorough biological understanding of the possible tissue responses and mechanisms of trauma.
 - (3) Appropriate treatment can be performed and the consequences of the trauma can be minimized.

三、 Tissue responses to trauma

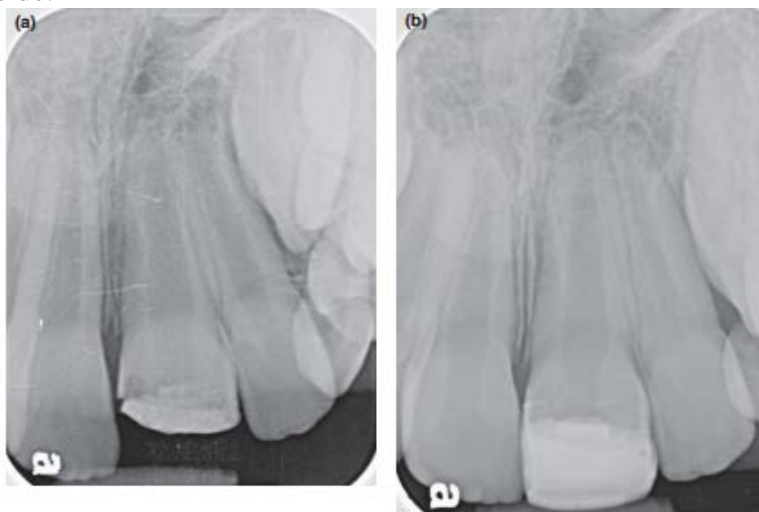
1. Initiates a sequence of events in the involved tissues with the ultimate goal to heal.
 - (1) Haemostasis
 - (2) Inflammation (whereby leukocytes migrate into the wound in order to protect the wound against infection and perform wound cleansing)
 - (3) Proliferation (to close the wound defect with newly formed connective and epithelial tissue)
 - (4) Reorganization by remodelling.
2. The healing process is basically the same in all tissues
 - (1) If the inflammatory process is minimal, healing of these tissues will take place, which is considered to be favorable.
 - (2) If the inflammatory process is sustained by a continuous stimulus, such as bacterial infection, no healing or an unfavorable response will take place and an active inflammatory process will continue until the entire tooth is lost.

四、 **Pulp** responses following trauma to a tooth

1. The dental pulp is often involved in dental trauma. Two main scenarios are involved in pulp injuries
 - (1) Pulp exposure to oral bacteria via exposed dentinal tubules in uncomplicated crown fractures.
 - (2) Direct exposure of the pulp wound surface in complicated crown or crown-root fractures.
 - Pulp may also be 'sterile-exposed' to the PDL: the apical foramen in luxation injuries or at the level of a root fracture in root fractures.
 - (3) These two trauma scenarios can also occur simultaneously: crown fracture with a concurrent luxation injury.
 2. Direct impact on the health of the pulp, which may give rise to various pulp responses
 - (1) Localized or generalized tertiary dentine formation
 - (2) Pulp revascularization, pulp canal calcification (PCC)
 - (3) Chronic pulp inflammation, internal root resorption
 - (4) Pulp necrosis and subsequent infection of the root canal system.
- A. **Favorable responses**
- a. Recovery and return to normal
 - In teeth with an exposed pulp, healing of the pulp can be expected via tertiary dentine formation if wound protection is secured by pulp capping or pulpotomy.
 - The apical foramen is wide enough, pulp revascularization may take place in teeth that have had apical severance of the neurovascular supply.
 - b. **Tertiary dentine formation**: reactionary or reparative
 - Highly specialized loose connective tissue with a capacity for specific responses to trauma and microbial insults. It retains the ability to form dentine throughout life.
 - In reaction to noxious insults such as attrition, caries, tooth fractures and luxation injuries, it produces reactive and reparative tertiary dentine at a rate rising to the level of that of primary dentine. (←→After the completion of root formation, the pulp continues forming secondary dentine but at a much reduced rate.)
 - (a) Mild injuries, such as enamel infractions or minor uncomplicated crown fractures, may cause mild localized inflammation in the pulp that may resolve and the exposed dentinal tubules become sclerotic (tubular sclerosis).
 - (b) Mild to moderate injuries, such as crown fractures with deeper dentine exposure, stimulate the surviving odontoblasts leading to a focal up-regulation of secretory activity with focal secretion of a reactionary dentine matrix in the dentinal tubules and predentine.
 - (c) The injuries cause death of the involved odontoblasts, the newly differentiated odontoblasts from the undifferentiated mesenchymal cells in the pulp proper or paravascular mesenchymal cells produce reparative dentine of considerable diversity with various degrees of tubularity, depending on the phenotype of the cells involved.
 - In complicated crown fractures
 - (a) The pulp is lacerated and exposed to the oral environment. Responds with localized inflammation to haemorrhage, breakdown of lacerated tissue, and bacteria and their toxins at the exposure site.
 - (b) The subsequent changes: proliferation with granulation tissue formation or destruction with localized abscess formation and eventual pulp necrosis.
 - (c) A proliferative response of the pulp is more likely to occur with an exposed pulp where the salivary rinsing prevents impaction and accumulation of contaminated debris.
- Over a period of 7 days, pulp inflammation is superficial and limited to a

depth of 1–2 mm.

- When exposed dentine or the pulp wound surface is adequately protected by therapeutic measures from bacterial invasion, the pulp will recover and the inflammation will subside.



- (d) An exposed pulp is not an infected or diseased pulp. Given the right healing conditions, the pulp is a survivor. When the pulp's neurovascular supply remains intact after trauma (without a concomitant luxation injury), the pulp's immune defence against injury and infection functions the same as that in tissues in the rest of the body.★★★
- (e) The entrance to the exposed pulp wound is covered with a restorative material, which limits bacterial contamination, a dentine bridge (reparative dentine) will be formed which walls off the exposure.
- However, most dentine bridges contain multiple tunnel defects, which do not decrease over time.
- Root fracture can be considered a luxation injury of the coronal fragment. The type of tissue healing is based on competition between the pulp and the periodontium.
 - (a) In concussion or subluxation of the coronal root fragment, the pulp often remains unaffected at the fracture site. The pulp will react in a manner similar to a coronal pulp exposure under optimal conditions

→ i.e. with an intact blood supply and absence of bacterial infection. The dentine bridge will unite the coronal and apical fragments and act as a callus for subsequent cementum deposition from the PDL, leading to a hard tissue healing.
- c. **Pulp revascularization**

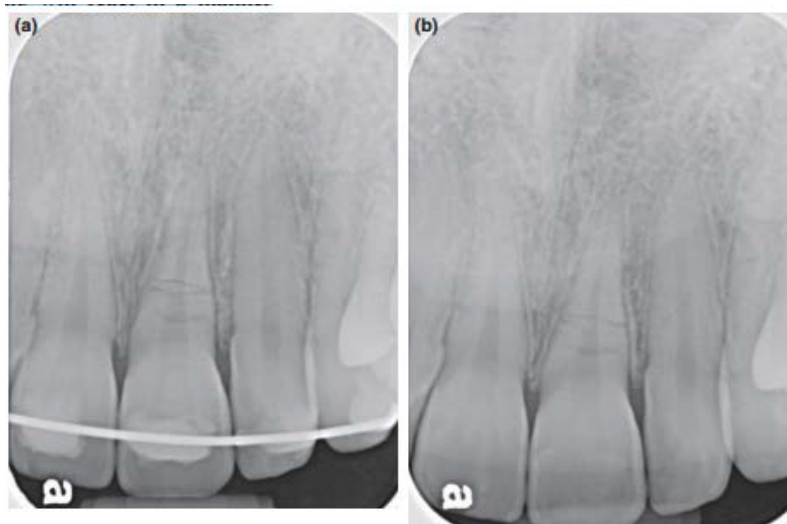

Fig. 2 Root fracture of the left central incisor of a 14-year-old girl with subluxation of the coronal fragment. (a) Immediately after stabilization with a splint. (b) Healing by calcification is evident at 8 months. The pulp remains responsive to the pulp sensibility testing.

- Partial or total disruption of the neurovascular supply to the pulp may occur after a luxation injury or a root fracture where the coronal fragment becomes displaced.
- Even with complete severance of the neurovascular supply, pulp healing by revascularization can occur, provided bacterial infection does not occur and the size of the apical foramen (>1.0 mm) is adequate to permit neurovascular in-growth.

→ Capillaries extend into the ischaemic pulp through the open apical foramen within a few days of injury and the speed depends on the width of the pulp-periodontal interface.
- End-to-end anastomoses occur in the ruptured apical vascular supply.
 - (a) The healing processes begin apically and move coronally.
 - (b) In some cases, anastomoses to pre-existing microvasculature in the pulp may lead to the survival of the original pulp with an intact odontoblastic layer.

- (c) However, in many cases the revascularization of the pulp appears to occur mainly by ingrowth of new vessels.
- Children and adolescents are the major group suffering traumatic dental injuries.
 - Preserving the pulp blood supply, especially in teeth with incomplete developed roots, is the goal of management after injuries to teeth.
- d. **Pulp fibrosis**
- The predominant cells in the pulp are fibroblasts.
 - With injuries,
 - (a) The locally released cytokines may stimulate the fibroblasts to repair and occlude the damaged tissue.
 - (b) With the unbalanced ratio of the tissue levels of matrix metalloproteinases (MMPs) and their inhibitors (TIMPs), the overall collagen content in the pulp may be increased with a decrease in the number of cells leading to pulp fibrosis.
 - (c) The fibrous sheaths associated with blood vessels and nerves may persist in the pulp even as the structures diminish in number with age or injuries.
 - (d) The reduction in the volume of the pulp canal space may also give rise to a relative increase in the amount of fibrous connective tissue.
 - These degenerative changes in the pulp do not automatically lead to pulp necrosis.
- e. **Pulp canal calcification**
- PCC is a relatively common outcome after luxation injuries (i.e. with displacement) and after pulp revascularization in teeth with incomplete root formation or in the coronal fragment in teeth with root fractures.
 - (a) PCC is significantly related to the degree of displacement of the tooth in the alveolar socket.★★★
 - A mild to moderately displaced tooth, such as in lateral luxation and extrusion, is more likely to develop pulp canal calcification than a severely displaced tooth (which is more likely to have pulp necrosis).
 - It is closely related to the damage to the pulp neural supply in the pulp neurovasculature.
 - Dentine formation in the root canal usually becomes very extensive
 - (a) Loss of sympathetic control of the secretory activity of odontoblasts.
 - (b) Pulp haemorrhage after trauma can become the nidi for calcification and lead to the narrowing of the pulp canal space.
 - The character of the pulp wound healing varies according to the origin of the repopulating endothelial cells that provide progenitor cells.
 - (a) In the case of invasion of PDL
 - Derived progenitor cells into the root canal, connective tissue will form together with cementum deposited along the root canal walls.
 - (b) In the case of an open apex
 - Bone may also invade the root canal with accompanying PDL fibres.
 - (c) In most cases
 - The hard tissues formed progressively can be dentine, osteo-dentine, alveolar bone or cementum depending on the origin and differentiation of cells involved.★
 - The new hard tissue is deposited along root dentine walls leading to the gradual reduction of the root canal space.
 - PCC also occurs in teeth with transient apical breakdown, reflecting the wound healing processes in revascularization of the injured pulp.

- (a) Pulp inflammation and periapical bone resorption co-exist with an abundance of nerve sprouts.
- (b) Secreted neuropeptides may stimulate immunological processes and proliferation that in turn initiate an increase in mineralization in the revascularized pulp tissue.
- Teeth with incomplete root formation at the time of injury sometimes show pulp necrosis confined to the coronal part of the pulp, while the apical portion survives showing pulp canal calcification, which ensures occlusion of the wide apex with calcified tissue.
 - In the displaced coronal fragment of a tooth with a root fracture, pulp revascularization with subsequent pulp canal calcification will proceed on its own concurrently with the healing of the root fracture by the faster dominant connective tissue healing of the periodontal ligament, resulting in connective tissue healing of the root fracture.
- B. **Unfavorable** responses
- The oral cavity is quite a hostile environment for wound healing as saliva contains 108–109 bacteria per millilitre. (An infection to be established, bacterial colonization with a bacterial count of 10⁵ per gram of tissue is sufficient.)
 - Bacteria and their toxins may invade the pulp through exposed dentinal tubules or directly to the exposed wounded pulp tissue.
 - Rupture of the neurovascular supply to the pulp may result in bacterial contamination of the blood clot through the damaged periodontal ligament space, resulting in subsequent infection of the ischaemic pulp.
 - The progression of pulp inflammation is similar to other connective tissues, typically through the following stages: inflammation, necrosis, infection and loss of pulp tissue (i.e. to become a pulpless, infected root canal system).
 - (a) Infection leads to the formation of an inflamed, non-tissue specific granulation tissue at the expense of the proliferation and migration of tissue specific progenitor cells.
 - (b) The rigid chamber in which the pulp resides limits the initial phase of the inflammatory response in establishing an antibacterial defence.
 - Anatomic obstructions of the root canal system limit the effective access of the immune defence system that makes complete microbial kill impossible.
- a. **Chronic pulp inflammation**
- Deep exposure of dentinal tubules in crown fractures and exposed pulp in complicated crown fractures which are left untreated for a prolonged period of time will have extensive proliferation of granulation tissue at the affected site.
 - Bacteria and other noxious irritants from the oral environment are of low-grade irritation, chronic pulp inflammation may occur, initially locally and gradually generally.
 - Hard tissue deposition or pulp fibrosis in the coronal portion of the pulp occurs concurrently with the chronic inflammatory infiltrates in the remaining pulp tissue.
- b. **Pulp necrobiosis**
- Plaque and debris are permitted to accumulate over and impact into the exposed pulp, bacteria will colonize into the wound, causing a localized pulp abscess with intense inflammation in the adjacent pulp tissue.
 - Pulp necrobiosis implies the concurrent presence of both inflamed and necrotic, infected pulp tissue.
 - The necrotic infected tissue is usually in the coronal portion of the pulp with the inflamed tissue apically.

c. **Pulp necrosis**

- In cases of extensive or total severance of apical blood supply in luxation injuries, pulp healing is unlikely in fully formed teeth with an apical diameter ≤ 0.5 mm. Hence pulp necrosis occurs.
- Pulp necrosis without infection
 - (a) The pulp has its main neurovascular supply through the apical foramen.
 - (b) Trauma may cause a sudden, complete severance of the apical blood supply if the tooth has been displaced from its normal position in the alveolar socket (e.g. luxations), leading to infarction and coagulation necrosis of the pulp.
 - (c) If the tooth is intact (free from cracks, caries, restorations or periodontal disease), in the absence of bacteria, the necrotic pulp may remain sterile and poses no adverse effects on the surrounding periradicular tissues for a prolonged period (even for years), as long as it does not subsequently become invaded by bacteria.
- Pulp necrosis with infection
 - (a) An untreated pulp exposure ultimately leads to pulp necrosis.
 - (b) Bacterial invasion is the dominant cause via the exposed dentinal tubules or by plaque and contaminated debris accumulating over the exposure.
 - As the bacterial count increases, the inflammation will spread circumferentially until the whole pulp becomes necrotic.
 - (c) Pulp necrosis as a result of coronal pulp exposure is of the liquefaction type, similar to that seen following carious exposure.
- Bacterial invasion of the ischaemic necrotic pulp is highly likely.
 - (a) Sources of bacterial contamination can be the presence of bacteria-harboring blood clots in a severed PDL along the root surface or mechanically damaged cervical root surfaces (bacteria from dental plaque).
 - (b) Colonization of bacteria in the ischaemic pulp is the predominant reason for the absence of complete revascularization.★
 - It causes the formation of a leukocyte zone which separates infected necrotic tissue from the ingrowing apical connective tissue.
 - (c) Bacteria are found in the necrotic pulp as well as in the leukocyte zone, but seldom in the adjacent connective tissue.
- Pulp necrosis in developing teeth is significant as it may lead to cessation of root formation leaving weak, fractureprone roots.
- When bacteria gain access to the coronal fragment in root fractures, the pulp will become necrotic and infected, which in turn triggers the accumulation of inflamed, granulation tissue between the coronal and apical fragments, leading to non-healing of the fractured root.

d. **Infection of the root canal system**

- Once a necrotic pulp has been invaded, the bacteria or their toxins will spread throughout the entire root canal system.
- The necrotic pulp serves as a source of nutrients for the bacteria, which ingest the necrotic tissue and render the tooth pulpless.
- This may occur with 1–2 months of the initial invasion of the bacteria.

e. **Internal root resorption**

- Internal root resorption is a relatively rare occurrence after traumatic injuries in comparison to external root resorption.
- Internal root resorption is characterized by the loss of root dentine along the canal walls as a result of clastic activity stimulated by pulp inflammation.
 - (a) The outmost unmineralized protective layer covering the internal root surface of

the root canal, predentine and the odontoblast layer, must be damaged following traumatic injuries, resulting in exposure of the underlying mineralized dentine to clastic cells whose origin is thought to be pulp, coming from the apical part of the pulp.

- (b) The progression of internal root resorption depends on ongoing pulp inflammation, commonly sustained by bacterial infection. Without bacterial stimulation, the resorption will be self-limiting.
- There are three forms of internal resorption: surface, inflammatory and replacement.
 - (a) **Internal surface resorption**
 - Internal surface root resorption is repair-related.
 - It usually occurs at the pulp side of the fracture in root fractures or near the apical foramen in luxated teeth.
 - The resorption process starts at the line of the fracture and progresses into the root canal wall of the coronal fragment.
 - Surface resorption is not progressive. It is self-limiting.
 - Following root fracture, it is a sign of hard tissue healing of the fractured root.
 - The resorption lacunae are subsequently lined with tertiary dentine.
 - (b) **Internal inflammatory resorption**
 - Internal inflammatory root resorption is infection-related and involves progressive destruction of internal root dentine at any point along the length of the pulp space.
 - This response is a necessary step in the pulp's fight against the invading bacteria residing in dentinal tubules and the root canal system.
 - The resorptive lacunae might be filled with granulation tissue. When it occurs in the cervical third of the root canal in luxated teeth, it may mimic external invasive root resorption, which gives a clinical appearance of a 'pink spot' in the cervical area of the crown.
 - The pulp tissue apical to the resorptive lesion must have a viable blood supply in order to provide nutrients to clastic cells, whereas the infected necrotic coronal pulp tissue provides stimulation for the clastic cells. With the progression of the resorptive process, communication with the periodontal ligament may occur.
 - The resorbing clastic cells are thought to be cut off from the blood supply and nutrients. The bacteria will then infect the entire root canal system which will become a pulpless, infected root canal system, with the development of apical periodontitis.
 - (c) **Internal replacement resorption**
 - Internal replacement root resorption is repair-related but is progressive with the invasion of bone-like structure in the root canal system.
 - It is caused by low-grade inflammation such as chronic irreversible pulpitis or pulp necrobiosis.
 - The resorptive lacunae in the dentine are accompanied by the concomitant deposition of metaplastic hard tissue that resembles bone or cementum instead of dentine, resulting in an irregular enlargement of the pulp space with calcification.
 - The undifferentiated mesenchymal cells may migrate from the apical pulp

which is inflamed. These mesenchymal cells are multipotent. In the absence of highly specific molecular signals for the differentiation of 'true' odontoblasts in the reparative dentinogenesis, the cells retain the osteoblastic phenotype and secrete a matrix that resembles bone more than dentine.

→ The metaplastic tissue may also derive from mesenchymal cells transmigrated from the vasculature or originated from the periodontium, analogous to the ingrowth of connective tissues into the pulp space using the blood clot as scaffolding, or after pulp revascularization.

(d) A variant of internal replacement resorption is 'internal tunnelling resorption'.

→ It usually occurs in the coronal fragment following root fractures or in teeth with luxation injuries.

→ The resorptive process tunnels into the dentine adjacent to the predentine and progresses coronally, with concomitant deposition of cancellous bone-like tissues.

→ In root fractures, it is a sign of connective tissue healing.

3. Combinations of the above: simultaneously and/or sequentially over time

(1) The pulp response to trauma is a dynamic process.

(2) Each possible response may not be an individual occurrence or a final, long-term response to the injury. Two or more responses may occur simultaneously and/or sequentially over time.

(3) Pulp healing, pulp canal calcification or pulp necrosis are the three major possible responses of the pulp following dental trauma. All three responses can occur at different times. For example,

(4) Internal inflammatory root resorption may occur simultaneously with chronic pulp inflammation and pulp necrobiosis.

(5) In root fractures, internal surface root resorption often precedes fracture healing of hard tissue or connective tissue and PCC of the fractured fragment.

(6) One of the risks of pulp necrosis in traumatized teeth is the development of external infection-related inflammatory root resorption. This risk emphasizes the need for careful monitoring of pulp responses to trauma.

(7) Tooth loss after trauma can occur later due to complications caused by the demise of the pulp followed by infection of the root canal system.

(8) In crown-root fractures, subsequent insult to the injured pulp and peri-radicular tissue from bacterial invasion can supersede the concern of pulp injuries and become a primary problem in management. The feasibility of restoring the remaining tooth structure apical to the fracture line for adequate coronal protection of the pulp becomes a primary prognostic factor.

五、 **Periradicular** tissue responses following trauma to a tooth

1. The periradicular tissues supporting and investing the tooth comprise the PDL, the cementum, the alveolar bone lining the tooth socket (the alveolar bone proper) and the dentogingival junction. In immature teeth, Hertwig's epithelial root sheath (HERS) determines continuation of root growth and development.

2. The periradicular tissue is a complex mixture of mineralized and non-mineralized tissue of ectomesenchymal origin derived from the dental follicle (with the exception of the dentogingival junction, which is from reduced enamel epithelium of enamel organ origin).

3. In the hostile oral environment, an effective immune response takes priority in dental wound healing in order to protect the sterile periradicular tissues from invading bacteria.

(1) Activation of the neutrophils, lymphocytes, macrophages and osteoclasts may lead to bone resorption, as well as root resorption.

- (2) Ischaemia or contusion of the PDL leads to repair-related replacement resorption or ankylosis.
- (3) The final outcome of periradicular healing depends on the race between different cellular ingrowths, as well as bacterial invasion to the damaged root surface.
- (4) the pattern of healing depends on two decisive factors: the regeneration potential and the speed with which the tissue cells bordering the damaged area react.

A. Favourable responses

a. Recovery and return to normal

- The survival of the PDL cell layer next to the cementum root surface appears to be crucial for periradicular tissue healing including alveolar bone.
 - (a) The PDL recovers well after separation injuries such as extrusion. Loss of PDL at the alveolar bone end tends to regenerate.
 - (b) The lost alveolar bone proper and alveolar bone can be completely regenerated due to the remarkable bone-inducing capacity of PDL residing on the root surface.
 - (c) When transplanted to the connective tissue of the buccal mucosa, the PDL residing on the root surface has the potential to form a new lamina dura.
 - (d) Loss of PDL on the cementum root surface leads to ankylosis. However, if defects are less than 4 mm, ankylosis may be transient in nature followed by complete healing.
- Loss of cementum following root fracture leads to the formation of new cementum on the exposed root dentine.
 - (a) This repair originates from existing cementoblasts located next to the regions of tissue loss.
 - (b) The newly formed cementum may have a multi-layered appearance resembling alveolar bone, which is the result of a transient ankylosis.
- Initial surface bone resorption may occur when the overlying periosteum is torn from the cortical bone plate when displacement of attached gingiva or the alveolar mucosa occurs during luxation injuries.
- Bone deposition relies on the survival of the innermost cellular layer of periosteum which has the osteogenic potential and is strongly influenced by age.
 - (a) When alveolar bone sustains ischaemic and crushing injuries in intrusions, a better healing by bone regeneration is often observed in children with immature root formation.
 - (b) The alveolar bone surrounding the tooth in children is known to be more resilient, whereby trauma to the periodontium might be attenuated.

b. Fibrous healing

- After the resolution of inflammation, the precursors of fibrous connective tissue may colonize the root surface before the appropriate progenitors, which have the potential to restore the normal architecture of the periodontium.
 - Osteoclasts attract collagen-producing fibroblasts.
- When trauma causes substantial loss of the alveolar crest, the adjacent damaged PDL on the root surface may be repaired by fibrous connective tissue from the oral mucosa, which is thought to have less osteogenic potential than the proper PDL, resulting in the lowering of the alveolar crest from its original position after trauma.
- When there is moderate displacement of the coronal root fragment in root fractures, pulp revascularization of the coronal segment takes place.
 - (a) This allows periodontally-derived cells to dominate the healing response.
 - (b) The interposed fibrous connective tissue between the fractured root dentine surfaces matures into Sharpey's fibres.

c. Transient apical breakdown (TAB)

- TAB is part of the natural healing process of the pulp and periodontium after the neurovascular supply of the pulp is severed at the narrow apical foramen in teeth with mature root formation as a result of luxation injuries.
 - The alleged luxation injuries are usually mild, mainly subluxation with some minor extrusion or lateral luxation.
 - The greater the tooth displacement in the alveolar socket such as intrusion or avulsion, the less likelihood of TAB occurring.
- The revascularization process
 - (a) Engages osteoclastic activity simultaneously at the base of the alveolar socket and in the apical foramen usually at about 1 to 3 months after injuries.
 - (b) The resorption of the alveolar bone surrounding the root apex and of the root dentine within the apical foramen creates space for the ingrowth of the neurovascular tissue into the pulp space.
 - (c) This process is transient in nature and stops once the revascularization of the pulp has completed, which is usually at about six months after the injury.
 - (d) The resorbed apical root surface is repaired by deposition of new cementum by the pre-existing PDL.
- TAB of the apical fragment may also be observed in root fractures in which the coronal pulp is severed. However, this phenomenon is not observed in immature teeth where the open apex accommodates ingrowth of new neurovasculature.

B. Unfavorable responses**a. Cessation of root development**

- Root development is determined by an active proliferation of the Hertwig's epithelial root sheath (HERS), a continuous sleeve of epithelial cells in the apical region separating the pulp (dental papilla) from the surrounding dental follicle.
 - (a) On the pulp side of the HERS, cells of the dental papilla are induced and differentiate into odontoblasts.
 - (b) On the PDL side, cells of the dental follicle are induced and differentiate into PDL cells including cementoblasts, fibroblasts and osteoblasts.
- The survival of HERS after trauma is decisive for further root development.
 - (a) Any significant damage to this structure will result in partial or total cessation of further root development.
 - (b) Such damage could be trauma sustained during intrusion, avulsions followed by replantation and jaw fractures.
- Root dentine formation depends on the survival of odontoblasts of the pulp along the root canal wall after trauma.
 - With the combined development of pulp necrosis in contusion injuries of the HERS, the root is thin, weak and susceptible to crack and fracture under functional loading (less proprioception due to loss of pulp), which leads to eventual loss of the tooth.

b. Disturbances to root development

- The HERS is responsible for the morphology and shape of the developing roots.
 - (a) Trauma sustained during intrusion and lateral luxation can cause direct physical damage to HERS.
 - (b) Partial damage to HERS can lead to partial root development with a diminutive gracile root.
 - (c) Incomplete repositioning of displaced teeth leads to damage of the HERS which has been found to be related to root development disturbances.

- Severe luxation injuries of primary teeth (such as intrusion or avulsion) may also have an impact on the neighbouring developing permanent tooth germs.
 - (a) Apical to the site of active enamel and dentine formation in the enamel-forming organ of permanent successors is the cervical loop, which determines the early root development.
 - (b) Root duplication may occur when the cervical loop is divided.
 - (c) When the cervical loop is displaced in relation to the mineralized root portion, root dilaceration occurs.
- c. **Bone resorption**
 - The alveolar process is the tooth-supporting region of the mandible or maxilla.
 - It consists of three components: the alveolar bone proper (bundle bone), the cortical bone plates and the cancellous bone with bone marrow.
 - The bundle bone (the bone lining the socket, lamina dura) provides attachment for the principle fibre bundles of PDL. It has many perforations to allow the transmission of nerves and blood vessels of the PDL.
 - The alveolar process can be injured following trauma, either indirectly in lateral luxation, intrusion and avulsion; or directly in alveolar and bone fractures.
 - Alveolar bone is highly vascular and is readily accessible to blood-derived inflammatory cells.
 - (a) The cells responsible for bone resorption are the osteoclasts that are derived from the mononuclear phagocyte progenitor cells (MP).
 - They have the capacity to digest mineralized matrices including alveolar bone and dentine.
 - (b) For the resorption to occur, the alveolar bone needs to be cleared of a surface layer of osteoid, a non-mineralized collagen, prior to osteoclastic attack.
 - (c) Osteoblasts are responsible for the removal of non-mineralized collagen via the activity of matrix metalloproteinase (MMP, a collagenase). This activity may be increased by parathyroid hormone (PTH) in regulating calcium homeostasis or inflammatory mediators in inflammation.
 - Bacterial toxins and by-products can lead to inflammatory bone resorption independent of osteoblasts via the differentiation of leukocytes into osteoclasts.
 - (a) Develop as early as 2–3 weeks after injury
 - (b) Caused by infection-induced release of osteoclast activating factors.
 - Osteoclasts play an important role, both in the periradicular tissue healing events after dental trauma, as well as in the body defence against tissue damage and infection following trauma.
 - (a) Osteoclasts in hard tissue wound healing can be considered as analogous to the macrophages in soft tissue wound healing.
 - (b) Marked osteoclastic activity may lead to bone resorption at the crestal (marginal periodontal), as well as apical and lateral (periradicular) regions.
 - Crestal – marginal periodontal
 - (a) The alveolar crest is the meeting place where the outer cortical plates meet the bundle bone (the bone lining the alveolus), usually 1.5 mm to 2.0 mm below the level of the cemento-enamel junction of the tooth.
 - (b) The crestal bone may sustain crushing injuries during lateral and intrusive luxations.
 - An inflammatory response is elicited, which results in the liberation of cytokines that activate osteoclasts to remove the damaged hard bone tissue prior to healing.

- When trauma causes substantial loss of the alveolar crest, it rarely regains its original position after trauma, probably due to replacement of the proper PDL by connective tissue from the oral mucosa, which does not have the same osteogenic potential.
- Apical and/or lateral – periradicular
 - (a) Infection of a necrotic pulp and subsequent development of an infected root canal system is a frequent complication after teeth sustain luxation injuries and replantation after avulsion.
 - (b) Alveolar bone resorption is a necessary step in the fight against invading bacteria into the sterile periradicular tissue.
 - (c) Periradicular bone resorption and the development of a granuloma at the apical and/or lateral region form a line of defence against the bacteria residing in the root canal system.
 - d. External root resorption
 - The cementum layer covering the root dentine is essential in the root's resistance to resorption since the most external aspect of cementum has a layer of cementoblasts over a zone of unmineralized cementoid.
 - (a) This unmineralized surface discourages osteoclast adhesion and binding to the root surface and therefore root resorption.
 - (b) The crushing injury of the PDL sustained during intrusion, lateral luxation or avulsion with subsequent replantation causes loss of the PDL and inevitably the associated cementoid-cementum layer along the root surface.
 - (c) The exposed root dentine surface allows free access for osteoclasts and macrophages to adhere to the exposed mineralized dentine surface, causing root resorption while removing the damaged PDL and cementum on the root surface.
 - The cementum layer is also essential in the root's resistance against the penetration of bacterial toxins in the root canal space to the PDL via the dentinal tubules.
 - (a) During root formation, odontoblast differentiation takes place adjacent to the basal aspect of HERS and lays down the first dentine matrix (mantle dentine).
 - (b) The innermost layer of cells in the HERS secretes a material containing enamel matrix protein, which combines with the mantle dentine forming a hypercalcified intermediate cementum layer.

→ It is this layer that offers an effective barrier against the movement of bacterial toxins in the root canal space into the surrounding periodontal tissues.
 - The type of root resorption is determined by the surface area of the root damage, the content of the adjacent root canal system (the presence or absence of bacterial infection), and the relative proximity of the cells to the damaged root.
 - External surface resorption
 - (a) Represents the healing response to a localized injury to the PDL.

→ In minor trauma such as concussion and subluxation, bleeding and edema of the PDL may lead to a localized pressure area.

→ The cementum closest to the damaged PDL will be resorbed by macrophages and osteoclasts, resulting in a saucer-shaped cavity on the root surface.

→ It may affect all parts of the root in luxation injuries, or next to the fracture line at the periodontal side in root fractures.
 - (b) If the underlying dentinal tubules are not exposed and the adjacent cementoblast layer is intact, the cementoblasts will cover the damaged root surface and the resorptive cavity will be repaired by new cementum and with the insertion of new Sharpey's fibres.

- (c) The process of surface resorption is not progressive, but self-limiting and repair-related.
 - The PDL width at the repaired sites is normal and follows the contours of the root defects.
 - Surface root resorption is considered to be a favourable healing outcome.
- **External inflammatory resorption**
 - (a) A result of a combined injury to the pulp and PDL such as in lateral luxation, intrusion and replantation after avulsion, and where bacteria primarily located in the root canal space and dentinal tubules trigger osteoclastic activity on the root surface.
 - (b) It can affect all parts of the root and is more frequent and rapid in immature teeth, probably due to the thin root dentinal walls and wide dentinal tubules.
 - (c) The process of inflammatory root resorption is infection-related and is rapidly progressive until the root canal is exposed.
 - Luxation injuries involving the PDL and associated cementum on the root surface expose the underlying dentinal tubules.
 - Toxins from bacteria in the root canal can diffuse through the exposed dentinal tubules to the damaged root surface.
 - This sustained inflammation in the PDL results in continuation of the osteoclastic process, leading to the resorption of root structure along with resorption of the lamina dura and adjacent alveolar bone.
 - (d) When bacteria are eliminated from the root canal system by endodontic treatment, the resorptive process will be arrested. The resorptive cavity will then be filled in with cementum or bone, depending on the type of cells located next to the resorptive site (PDL or bone marrow-derived tissue).
- **External replacement resorption**
 - (a) External replacement resorption represents healing after extensive damage to the root surface involving the innermost layer of the periodontal ligament such as in intrusion and replantation following avulsion.
 - (b) In avulsion injuries, extensive damage to the periodontal ligament on the root surface is further complicated by the detrimental effect of extraoral time and drying as well as insufficient storage medium protection of the periodontal ligament and the pulp.
 - (c) The large area of damaged root surface will favour repopulation with bone producing cells, resulting in ankyloses.
 - (d) External replacement resorption is largely a result of damage to the PDL on the root surface during the actual displacement injury.
 - (e) The process is progressive, but the rate at which the root is replaced by alveolar bone largely depends on the extent of cell damage to the periodontal ligament on the root surface and on systemic factors which normally regulate bone remodelling in addition to the age of the patient.
 - Replacement root resorption is usually very aggressive in children. In adults, the tooth undergoing progressive replacement resorption can be retained for long periods of time due to the slow remodelling rate of bone.
- **External invasive resorption**
 - (a) External invasive resorption is an insidious form of external root resorption which may occur in teeth that have sustained luxation injuries where the protective cementoid-cementum layer is damaged.

- (b) The resorption process is often aggressively destructive and occurs as a late complication following dental trauma.

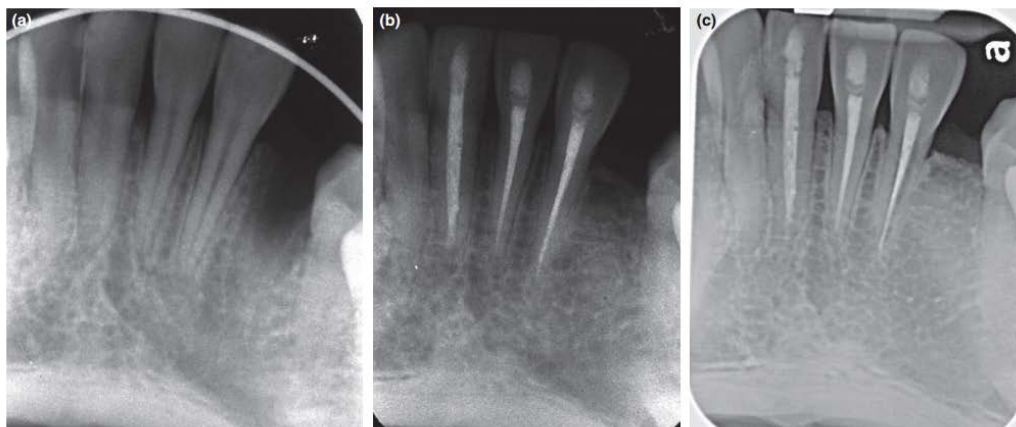


Fig. 4 Ankylosis of the mandibular left central incisor and ankylosis with progressive external replacement resorption of the mandibular left lateral incisor of a 21-year-old female 8 years after replantation of both avulsed teeth. (a) Immediately after repositioning and stabilization. (b) One-year review. (c) Review after 8 years.

- (c) Characteristically

- The cervical region of the root is invaded by a fibrovascular tissue derived from cells in the PDL which progressively resorbs dentine, cementum and enamel.
- The dental pulp remains protected by an intact layer of predentine until late in the process.
- The adjacent marginal alveolar bone usually remains intact.

e. **Ankylosis: with or without root resorption**

- Ankylosis is the fusion of alveolar bone to the intact cementum or to the previously resorbed cementum or dentine with no intervening PDL.
 - It is a common complication following replantation of avulsed teeth.
 - The progression of ankylosis is related to the initial extent of damage to the PDL on the root surface following trauma.
 - (a) With minor to moderate injuries over a small surface area, an initial ankylosis can later be reversed by the adjacent undamaged PDL and replaced with new cementum and PDL if functional mobility is allowed.
 - (b) Large areas of damage to the PDL (>4 mm) on the root surface due to trauma such as avulsion will elicit healing processes by the bony fusion of the damaged root surface and alveolar bone, resulting in ankylosis which is unlikely to be stopped or reversed and instead will remain permanent due to there being too few surviving PDL cells in relation to the larger damaged zone.
 - The cementum layer is extensively damaged together with the PDL loss, the ankylosed root then becomes an integral part of the alveolar bone remodelling system. It is gradually resorbed and replaced by bone (replacement resorption), depending upon the turnover rate of bone.
 - In growing children, the ankylosed tooth may disturb the normal growth of the alveolar process, resulting in decreased height of the alveolar process with a marked infraocclusion of the tooth as well as migration of the adjacent teeth
- f. Combinations of the above: simultaneously and/or sequentially over time
- The various responses of the periradicular tissues to trauma may occur simultaneously and/or sequentially over time, depending on the extent of tissue injuries and subsequent wound infection.
 - Intracoronal bleaching is usually carried out to correct a discoloured anterior tooth

following trauma. Young children or adolescents often undergo orthodontic treatment.

→ Both bleaching and orthodontic treatment alone have been found to be potential predisposing factors for invasive resorption.

→ Therefore, teeth with a history of luxation injury with bleaching or orthodontic treatment can be more susceptible to the development of this complex type of resorption

- Clinical and radiographic examination of traumatized susceptible teeth should be performed at regular intervals throughout life.

六、 Soft tissue responses following trauma to a tooth

1. The oral soft tissues, including facial skin, lips, gingiva, marginal periodontium and oral mucosa, can be injured either as a sole injury or concurrently with other injuries to the teeth and alveolar bones.

→ the following discussion will emphasize the responses of gingiva and marginal periodontium following trauma to a tooth.

2. The gingiva is often torn during crown-root fractures; gingival laceration is often associated with tooth displacement, such as luxations, avulsions, alveolar bone fractures.

(1) With minor displacement in gingival laceration or with proper soft tissue wound proximation and stabilization, the integrity of the marginal periodontium can be re-established due to its remarkable ability for regeneration.

3. Extensive gingival laceration involving the underlying periosteum and alveolar bone, loss of attachment and gingival recession may occur.

4. Bacterial invasion and subsequent inflammation is the major cause of unfavourable gingival responses.

A. Favourable responses

a. Recovery and return to normal

- With minor displacement due to gingival laceration, gingival regeneration will usually occur.
- The junctional epithelium has a remarkable ability to regenerate from the apical basal layer. Junctional epithelium is derived from the reduced enamel epithelium of the tooth germ.
- As the tooth erupts and the crown passes through the overlying oral epithelium, the reduced enamel epithelium fuses with the oral epithelium so that the epithelial continuity is never lost.
- In erupting immature teeth, when tissue loss with gingival laceration does not involve the cemento-enamel junction, the normal appearance and gingival contour around the tooth will be re-established with time with further physiological eruption and gingival retraction.

b. Transient marginal breakdown

- In lateral luxation and intrusion injuries, the junctional epithelium may be torn and the periodontal ligament may be compressed, leading to the marginal crestal bone of the alveolar socket becoming damaged.
- Removal of the injured tissue and marginal alveolar bone by macrophages and osteoclasts takes place prior to periodontal healing. This often results in formation of granulation tissue at the gingival crevice because of the torn junctional epithelium. A loss of attachment becomes clinically evident together with the resorption of the marginal crestal bone.

→ After 6–8 weeks, re-attachment of the junctional epithelium and re-establishment of the trans-septal and circular periodontal fibres take place. This phenomenon has been termed transient marginal breakdown.

- Repositioning following luxation plays an important role in the marginal bone healing. Optimal oral hygiene is also essential for healing to occur.
- c. **Fibrous healing (scar)**
 - When primary wound healing is compromised due to the extent of the traumatic injuries or bacterial contamination, wound dehiscence with exposure of sequestered bone takes place.
 - (a) A thin superficial layer of the exposed bone will be lost. The osteogenic layer of the periosteum is thus disrupted. Osteogenesis can only take place from the periphery of the wound where progenitor cells have not been disturbed.
 - (b) The overlying gingiva will undergo secondary wound healing.
 - This results in limited alveolar bone and gingival repair, and fibrous tissue often forms in its place.
 - Because of its intraoral location, the scarring often has minimal aesthetic consequences.
- B. **Unfavourable responses**
 - a. **Loss of attachment: permanent marginal breakdown**
 - Loss of attachment and marginal alveolar bone is a frequent phenomenon when multiple teeth are involved in lateral luxations, intrusions, and alveolar and jaw fractures.
 - The loss can be very extensive and lead to tooth loss, particularly in older patients.
 - Several factors may be involved.
 - (a) Crushing of marginal alveolar bone occurs during intrusions and lateral luxations; or loss of marginal alveolar bone can occur during alveolar or jaw fractures.
 - (b) Loss of the osteogenic periosteum covering the wound and disruption of the localized blood supply takes place due to the exposure of the alveolar bone caused by extensive gingival laceration.
 - (c) Degloving of the gingival tissue is a severe form of gingival laceration, where an impact force parallel to the front of the maxilla and mandible causes displacement of the gingiva and oral mucosa into the sulcular area.
 - (d) Extensive damage to the marginal periodontal ligament on the cervical root surface leads to compromised bone induction capacity and hence poor marginal bone healing between the severely displaced teeth.
 - Subsequent wound infection of the denuded alveolar bone with teeth covered by plaque accumulation due to poor oral hygiene leads to non-specific granulation tissue formation and growth that hinders proper healing of the marginal periodontium. When sequestration of the alveolar bone occurs during the healing period, a permanent loss of marginal alveolar bone and periodontal attachment in the particular region will occur.
 - b. **Gingival recession**
 - Gingival recession is characterized by the displacement of the free gingival margin apically from the cemento-enamel junction, leaving part of the root surface exposed.
 - The gingival and marginal periodontium form a natural seal around the tooth, protecting the alveolar bone from infection.
 - The dimension of these soft tissues (epithelium and the underlying connective tissue), which are attached to the tooth (cementum and enamel) coronal to the alveolar crest, remains relatively stable.
 - Plaque-associated inflammation is considered to be the main aetiological factor for gingival recession.
 - An inflammatory response can lead to recession and is always associated with

underlying bone dehiscence, particularly if the gingival tissue is thin due to a narrow keratinized gingiva.

- When a tooth fracture occurs below the gingival margin as in crown-root fractures, accumulation of bacterial plaque at the fracture interface will cause apical migration of the junctional epithelium, and hence gingival recession.
- Gingival lacerations are often associated with injuries where teeth are displaced, such as luxations and avulsion. When tissue loss with gingival laceration exposes the cemento-enamel junction, unsightly gingival recession may result.

C. Combinations of the above: simultaneously and/or sequentially over time

- a. Transient marginal breakdown may gradually progress to permanent marginal breakdown if bacterial plaque is allowed to establish at the site of injury.
- b. With time, unsightly gingival recession may occur subsequent to the loss of attachment and loss of crestal bone height.

七、 Factors affecting the tissue responses to trauma

1. Traumatic dental injuries are caused by physical impact that generates sufficient mechanical energy to produce the tissue injury.
 - (1) In children, the main causes of dental trauma are falls and injuries sustained during play, often involving single tooth injuries.
 - (2) In adolescents and adults, sports accidents, fights and motor vehicle accidents may result in more complex trauma involving several teeth simultaneously.
2. In recent decades, there has been a growing trend in sportsrelated dental injuries as a result of the growth in physical and fitness awareness.
3. Although the traumatic scenarios may be different, the mechanical and biological factors involved in the mechanisms of trauma determine the type and severity of resulting injury sustained by the tissue.

Table 2. Mechanical and biological factors affecting the responses of tissues following trauma to a tooth

Mechanical factors	Biological factors
Type of impact direct or indirect trauma	Degree of displacement of the tooth (luxation)
Energy of impact includes mass and velocity ($E = mc^2$)	Stage of root development Extent of pulp involvement
Resiliency of the impacting object	Concurrent and combined injuries to the same tooth
Shape of the impacting object	
Direction of the impacting force	

4. The mechanical factors characterize an impact to the tooth and have an indirect effect on tissue responses, whereas the biological factors have a more direct effect on tissue responses.
5. These factors usually work in combination to influence the outcome or the type of injury to a particular tooth and its surrounding tissues.

A. **Mechanical factors**

a. **Type of impact – direct or indirect trauma**

- Direct trauma
 - (a) Occurs when the tooth itself is struck by, or against, an object. This usually implies that the anterior region of the dentition will be involved.
 - (b) The teeth and surrounding tissues can be indirectly injured (indirect trauma) when the mandible is forcibly closed against the maxilla after a blow to the chin

- or mandible.
- **Indirect trauma**
 - (a) Usually results in premolars and molars sustaining crown or crown-root fractures, as well as jaw fractures in the condylar regions and symphysis.
 - (b) The effect of indirect trauma decreases progressively and sharply as the distance to the impact site increases.
 - b. **Energy of impact – includes mass and velocity**
 - The energy of impact depends on its mass and velocity.
 - (a) Increase in mass and/or velocity increases energy.
 - (b) Velocity plays a greater role since energy is the result of mass times the square of velocity ($E = mc^2$).
 - **High velocity** impacts with low mass often lead to crown fractures, where most of the energy of impact dissipates, with little left to have any major effects on the periradicular and surrounding soft tissues.
 - This may explain why crown fractures are more prevalent in teeth with minor luxation injuries.
 - **Low velocity** impacts with high mass (e.g. striking the tooth against the ground) may lead to the greatest damage to the supporting structures and minimal effect on the tooth structure.
 - In teeth with extrusion, avulsion, or lateral luxation, the energy of the impact is transferred to the periradicular and surrounding soft tissues, with less frequent occurrence of concurrent crown fractures.
 - c. **Resiliency of the impacting object**
 - Hardness or softness of the impacting object also affects the extent of injury with similar energy of impact.
 - Hitting the teeth against a **resilient surface** often results in periradicular tissue injuries of several teeth simultaneously. This is because the low velocity and resilient surface distribute the energy among several teeth and give the teeth time to adapt to the force and transmit it to the supporting periradicular tissue.
 - When the teeth are hit by or against a **hard nonresilient surface**, the impact energy will not be distributed as much and typically leads to a single-tooth injury with few teeth being involved simultaneously.
 - d. **Shape of the impacting object**
 - The shape of the impacting object determines the energy of impact at the point of contact (impaction).
 - A **sharp object** has a small contact area upon impaction which favours clean crown fractures with a minimum of tooth displacement as the energy is concentrated rapidly over a limited area.
 - A **blunt object** has a larger contact area upon impaction, and the injuries tend to be periradicular injuries such as luxations or root fractures as the energy is transmitted to the apical region of the tooth due to the increased area of resistance to the impacting force in the crown region.
 - e. **Direction of the impacting force**
 - The direction of the impacting force on the tooth crown determines the type of injury.
 - Most often the impact hits the tooth facially and perpendicularly to the long axis of the root.
 - (a) A fracture always occurs at the weakest point according to the laws of fracture mechanisms. The cleavage lines are determined by the orientation of the enamel prisms and dentinal tubules.

- (b) The enamel is weakest parallel to the enamel rods and the dentine is weakest perpendicular to the dentinal tubules.
 - (c) The root surface is forced against bone marginally and apically, creating high compressive forces in opposite directions.
 - (d) Shearing strains develop between the marginal and apical zones, and the root will fracture along the plane joining the two compression areas.
 - When the tooth is firmly anchored in alveolar bone, tensile strain will develop at the area where the tooth emerges from the alveolar bone, resulting in a horizontal fracture. Any pre-existing defects in the enamel and dentine, such as caries, infractions, cracks, non-carious cervical lesions and restorations, also alter the mechanical behaviour.
- B. **Biological factors**
- a. **Degree of displacement of the tooth (luxation)**
 - The degree of displacement of the tooth in the alveolar socket is a major factor affecting both the pulp and the periodontal tissue healing as it affects the pulp's neurovascular supply, as well as the protective layer of cementum with its PDL.
 - The degree of displacement (luxation) reflects the severity of trauma sustained by the tooth.
 - (a) Teeth with no or little displacement have a far better prognosis as there is no or little damage to the neurovascular bundle, as well as to the cementum and the PDL.
 - (b) Hence, concussion and subluxation injuries have the most favourable prognosis, followed by extrusion, lateral luxation, intrusion and avulsion, where major damage to the pulp neurovasculature and cementum/PDL takes place in the latter two injuries.
 - Prompt and optimal repositioning
 - (a) Allows approximation of wound surfaces and leads to a more rapid and predictable pulp revascularization.
 - (b) In addition, occlusal interferences can be avoided and psychological aesthetic consequences can be addressed.
 - (c) Incomplete repositioning leads to a slight delay in wound healing (approximately 2 weeks). However, the outcome of PDL healing is the same.
 - (d) Further trauma to the cervical cementum and periodontal ligament should be minimized in order to enhance marginal bone healing during repositioning after luxation injuries.
 - b. **Stage of root development**
 - The stage of root development is the most significant prognostic factor in determining pulp healing.
 - In teeth with a constricted apical foramen (i.e. complete root formation), the neurovascular supply is at a higher risk of disruption (by separation or crushing) with luxation injuries than are immature teeth with patent root apices.
 - The stage of root development is considered to be an expression of the ability of severed apical microvessels and nerve fibres to grow into the pulp canal space.
 - (a) The larger the diameter of the apical foramen, the higher the probability of pulp revascularization.
 - (b) The effect of the stage of root development focuses primarily on the diameter of the apical foramen at the time of injury, whereas the distance from the apical foramen to the pulp horn is not as prognostic.
 - c. **Extent of pulp involvement**
 - The extent of pulp involvement is not the same in all traumatic injuries and is determined by the type of injury.

- When considering pulp involvement, two aspects need to be considered,
 - (a) The neurovascular supply and size.
 - (b) Duration of pulp exposure to the oral environment.
 - d. **Pulp neurovascular supply**
 - The entire length of the pulp is involved in luxation injuries, whereas only a part of the pulp coronal to the fracture line is involved in crown, crown-root and root fractures.
 - The risk of pulp necrosis increases with the extent of luxation injury (i.e. concussion, subluxation, extrusion, lateral luxation, and intrusion – as listed in the order of the least to the greatest risk).
 - Compromise of the neurovascular supply can lead to altered tissue healing and function, such as PCC, root fracture healing with connective tissue and internal inflammatory root resorption.
 - Loss of the neurovascular supply allows ingress of bacteria and pulp death, such as pulp necrosis and non-healing of root fractures (granulation tissue formation).
 - e. **Pulp exposure – size and duration**
 - The extent of pulp exposure to the oral environment is a factor but not to the extent that many clinicians believe.
 - Young pulps can survive even with large traumatic exposure and for long periods of exposure time, as long as no concurrent luxation injury has occurred.
 - In teeth with intact pulp neurovascular supply, the dentine-pulp complex provides considerable resistance to bacterial invasion.
- C. Concurrent and combined injuries to the same tooth
- a. Concurrent injuries to the same tooth imply that more tissues are involved than if there is only one type of injury.
 - b. Combined injuries from repeated episodes of trauma render the pulp less likely to have optimal healing subsequently.
 - c. Previous traumatic stress also significantly reduces the tooth's resistance to fracture.
 - d. There is an eightfold increase in the risk of new trauma if a trauma episode occurs at an early age (at 9 years).
 - e. The risk of repeated trauma also increases in susceptible individuals with malocclusion of increased incisal overjet, protrusion of upper incisors or insufficient lip closure.

八、 Conclusions

1. The dental pulp, periradicular and oral soft tissues are unique in comparison to most other tissues in the body in their marked capacity for regeneration and repair.
2. Being an acute injury, dental trauma can be considered a dental disorder with little or no infection, which is in contrast to dental caries and periodontal diseases. The teeth at the time of trauma are often sound and thus the pulps and the surrounding tissues are clinically healthy.
3. Most dental trauma primarily involves children and adolescents who are still undergoing growth and development. Therefore, the body's healing ability is expected to be high.
4. Despite the complexity, intricacy and confusion involved in many different potential responses of the pulp, periradicular and soft tissues following multitudes of different types of dental trauma to a tooth, the underlying biological principles of tissue responses remain the same in relation to wound healing in general.
5. These unique features of dental trauma highlight the importance of proper, conservative and biologically tolerable management strategy in order to minimize the long-term consequences of trauma and maximize the likelihood of long-term retention of the involved teeth.

九、 Disclosure

The authors have no conflicts of interest to declare.

十、心得與感想

1. 此篇文章從三大組織的再生情況來提醒我們，在處置的步驟上為的是激發何種反應；避免產生何種作用。讓我們練習從最基本的觀念出發去治療。
2. 最後將外傷分為機械性和生物性的推敲十分有趣，是以前沒有遇過的想法。可以讓我們在得知病人的外傷是如何造成時，心理先有個底，預測牙齒會是怎樣的損傷。
3. 可惜照篇文章將外傷後的治療敘述的過於樂觀，可能在臨床上，並非所有外傷都如預期。必須要和病人溝通好，我們是在幫牙齒製造重生的機會，而不是一定救得回來。

題號	題目
1	下列有關齒濾泡 (dental follicle) 的敘述，何者正確？ (A) 源自外胚層 (B) 形成根部牙髓組織 (C) 形成根部造牙骨質細胞 (D) 僅在乳牙牙胚中出現
答 案 (C)	出處：101 年第二次專門職業及技術人員高等牙醫師分試、藥師、醫事放射師、助產師、物理治療師、職能治療師、呼吸治療師、獸醫師考專技高考_牙醫師 (一) #36284
題號	題目
2	下列那一種細胞中介物質 (mediators) 與根尖周圍炎之骨吸收無關？ (A) P 物質 (Substance P) (B) 前列腺素 (Prostaglandins) (C) 白球介素-1 β (Interleukins-1 β) (D) 腫瘤壞死因子 (Tumor necrosis factors)
答 案 (A)	出處：99 年第二次專門職業及技術人員高等考試牙醫師、呼吸治療師、助產師、職能治療師、獸醫師、醫事放射師考試暨牙醫師考試分試考試 牙醫學(三) 07