

原文題目(出處)：	A rare pathology: low-grade fibromyxoid sarcoma of the maxilla
原文作者姓名：	Spalthoff S, Bredt M, Gellrich NC, Jehn P
通訊作者學校：	Pathology Department, University of Basel, Switzerland)
報告者姓名(組別)：	王驪柳 Intern G 組
報告日期：	105/02/05

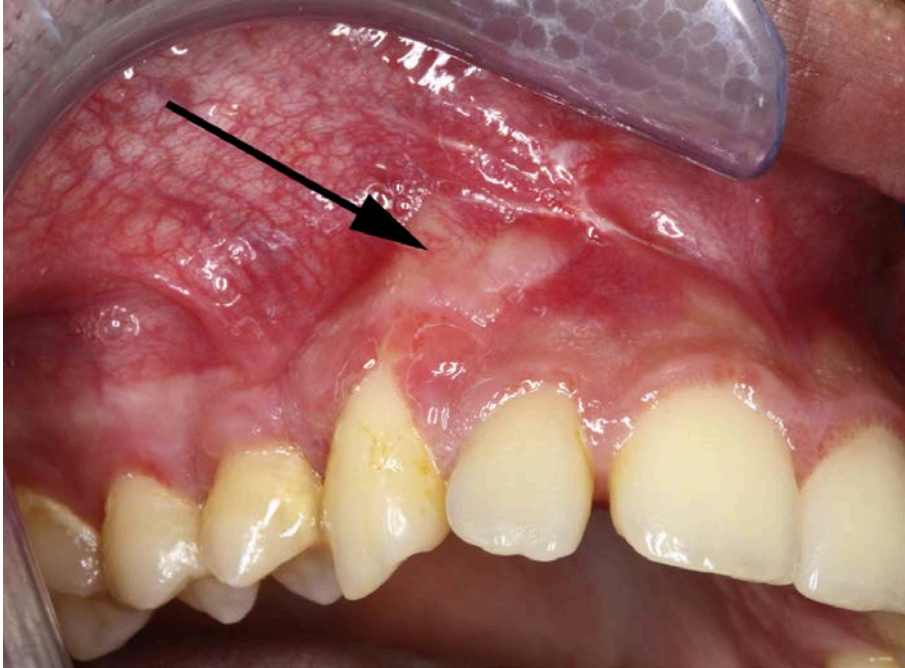
內文：

- Low-grade fibromyxoid sarcoma (LGFMS) is an extremely rare tumor first described by Evans in 1987. To date, only 5 cases have been reported in the maxillofacial region.
 - Presents a deceptively benign histologic appearance and very indolent, but fully malignant behavior.
 - Shows a prolonged clinical course with a late median recurrence of 3 years, but some recurrences have been noted up to 15 years later.
 - Metastases occur after a median of 5 years, with some reported as emerging as many as 45 years later.
 - The primary tumor usually affects the extremities and trunk, whereas metastases occur mostly in the lungs.
- There are currently 4 types of low-grade fibrosarcoma
 1. Low-grade fibromyxoid sarcoma (LGFMS)
 2. hyalinizing spindle-cell tumor with giant collagen rosettes (HSCT)
 3. sclerosing epithelioid fibrosarcoma
 4. fibrosarcoma not otherwise specified (adult fibrosarcoma).
- Some investigators also have mentioned
 1. dermatofibrosarcoma protuberans
 2. fibrosarcomatous dermatofibrosarcoma protuberans as clinically, morphologically, and genetically distinctive subtypes.
- The differential diagnosis of fibrous or myxoid soft tissue neoplasms is broad and often difficult
 - many neoplasms have overlapping histologic features.
- Cytogenetic analysis, such as fluorescence in situ hybridization (FISH) to identify a FUS gene rearrangement, can provide additional information.

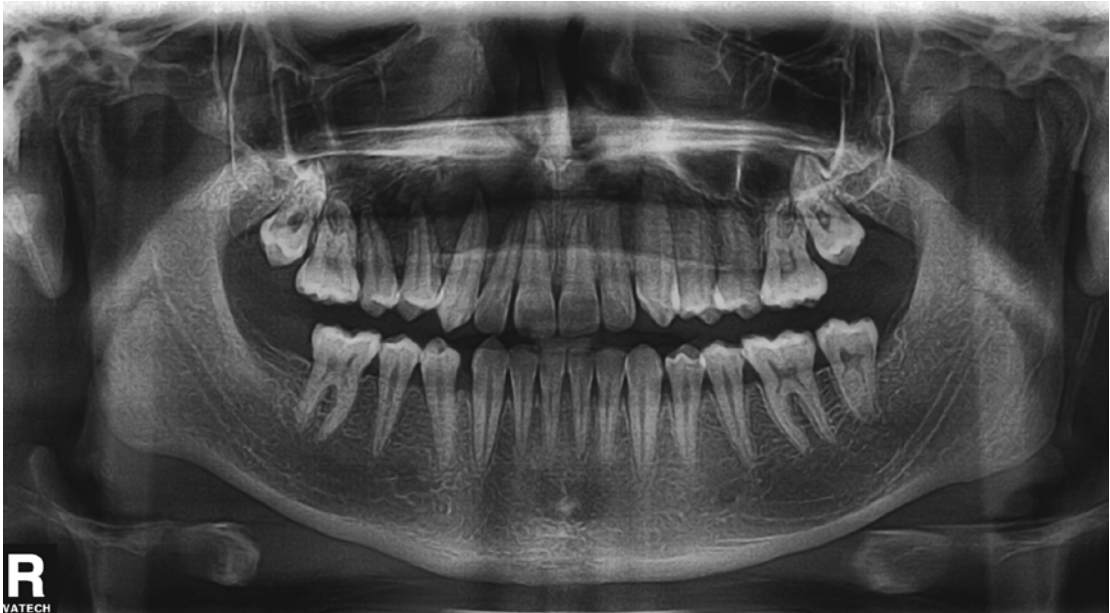Report of Case

- A 16-year old boy was referred to the authors' hospital in July 2014 with the histologic diagnosis of an aggressive intraosseous myxofibroblastic tumor, probably the LGFMS type, of the right maxilla.
- Histologic examinations were conducted by numerous pathologists, reflecting the difficulties in providing a correct diagnosis for the present case.
- Pathology showed tumor cells growing in nests surrounded by a partly spindle cell-like and partly myxoid stroma. Some cells were eosinophilic and others showed clear cell-like cytoplasm. Many mitoses were observed, with some atypical mitotic figures.
- Immunohistochemically, the tumor cells were positive for vimentin and weakly positive for CD117, but negative for smooth muscle actin, CD31, CD34, S100, and desmin. The Ki-67 proliferation index was 10 to 20%.
- FISH was positive for the FUS gene rearrangement, and cells showed strong and continuous expression of SOX9 and TFE3.
- In summary, the tumor could not be classified without doubt.

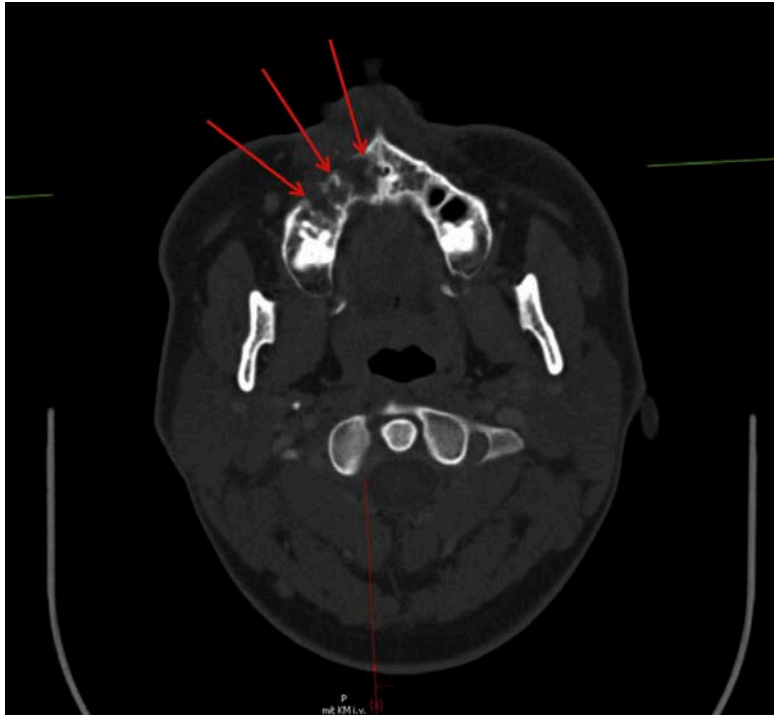- Physical examination showed mild swelling of the right upper lip and some intraoral scarring in the vestibular region as a result of the previous biopsy examination



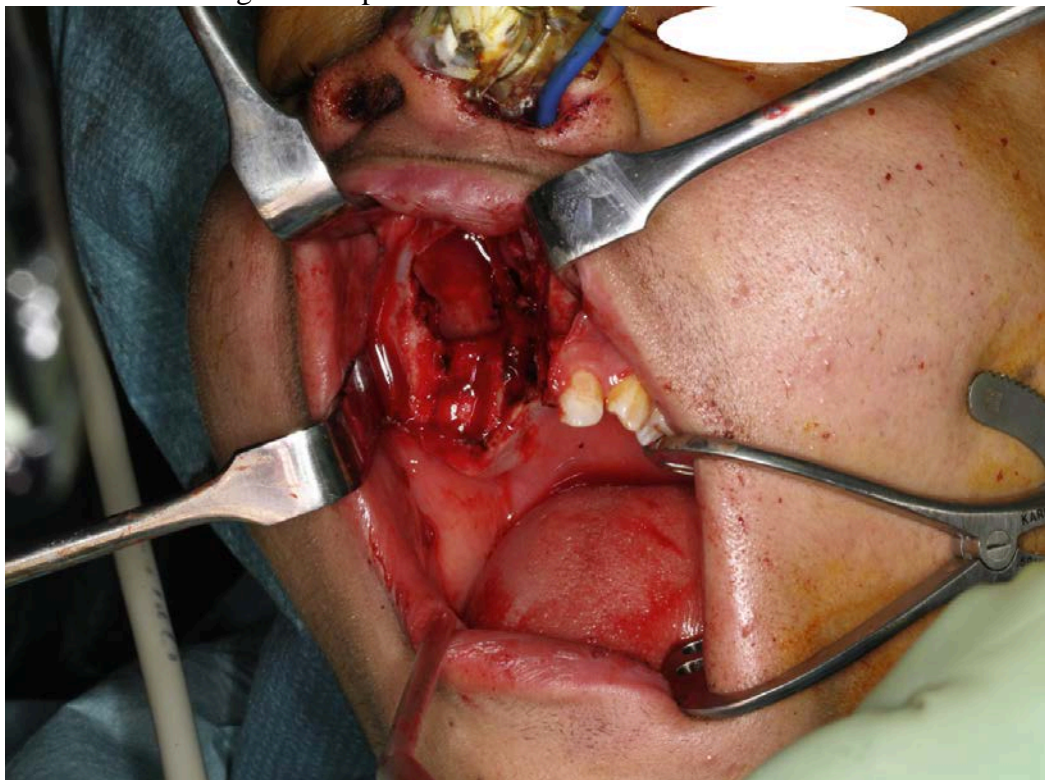- The patient reported that his clinical symptoms before the biopsy examination were quite mild; he had some swelling and the sensation of pressure.
- A panoramic radiograph showed a slight rotation of the upper right second incisor and the upper right canine with some loss of bone density



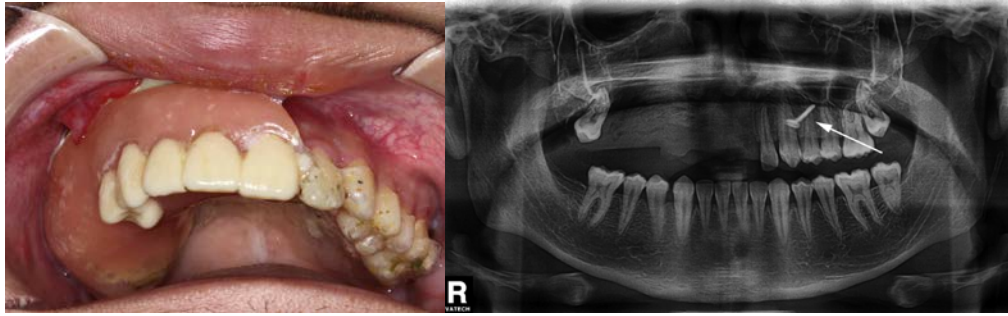
- The patient underwent computed tomography (CT) of the head, neck, and thorax, which showed an osseo-destructive tumor of the right maxilla of approximately 3 cm in diameter with no signs of metastases



- Excision of the entire tumor, including the surrounding soft tissue and teeth from the upper right first molar to the upper left second incisor, was planned.
- Magnetic resonance imaging of the head and neck visualized an irregular, contrast-enhanced tumor in the right maxilla that breached the bone and infiltrated the sinus, subcutis, and nasal floor. However, pathologic lymph nodes were not found.
- The patient was placed under general anesthesia and the tumor was resected en bloc without macroscopic exposure of the tumor. The nasal floor and lateral wall of the sinus were included in the resection. There were no surgical complications.



- The defect was obliterated with a tamponade and a temporary screw- fixed prosthesis was fitted at the left maxilla.



- A final pathologic examination conducted at the end of August confirmed complete resection of the tumor (pT1bR0).
 - Described as a spindle cell tumor that was partly myxoid and partly fibrous, with some nuclear pleomorphism, and denoted as probably being LGFMS.
 - FISH of the resected specimen did not show a FUS gene rearrangement.

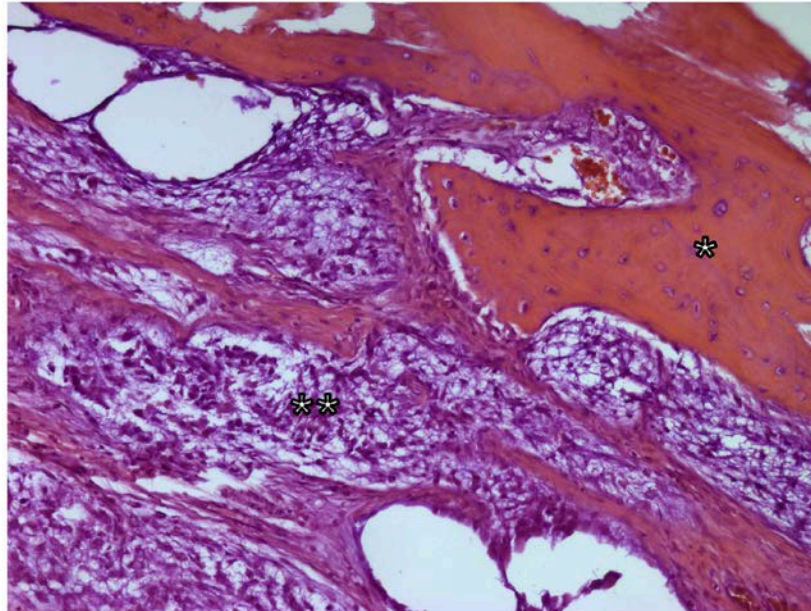


FIGURE 8. Fibromyxoid sarcoma (**) growing in the maxillary bone (*) (hematoxylin and eosin stain; magnification, ×100).

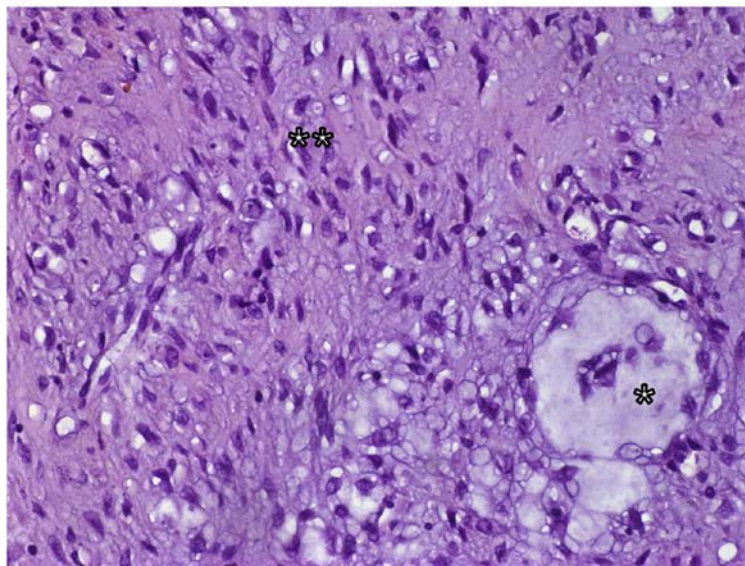
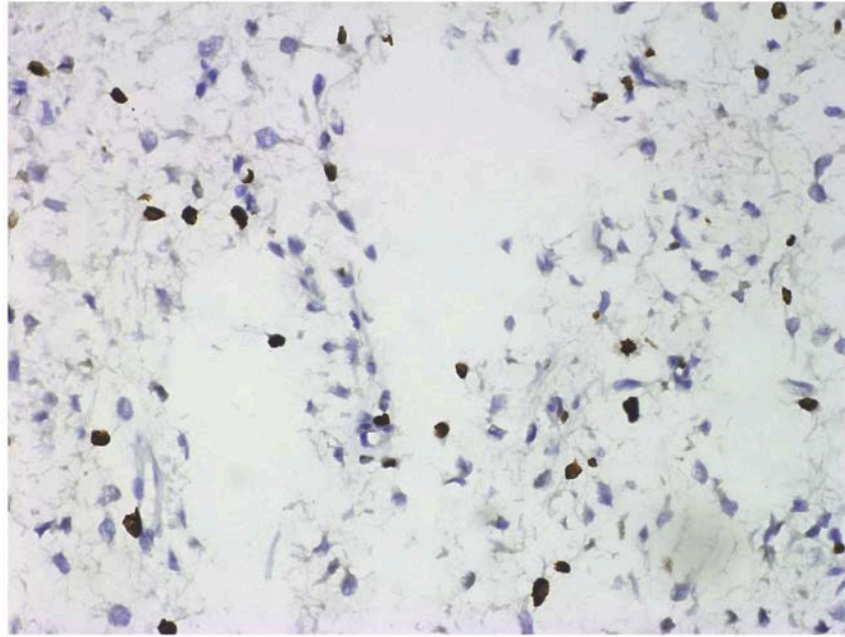
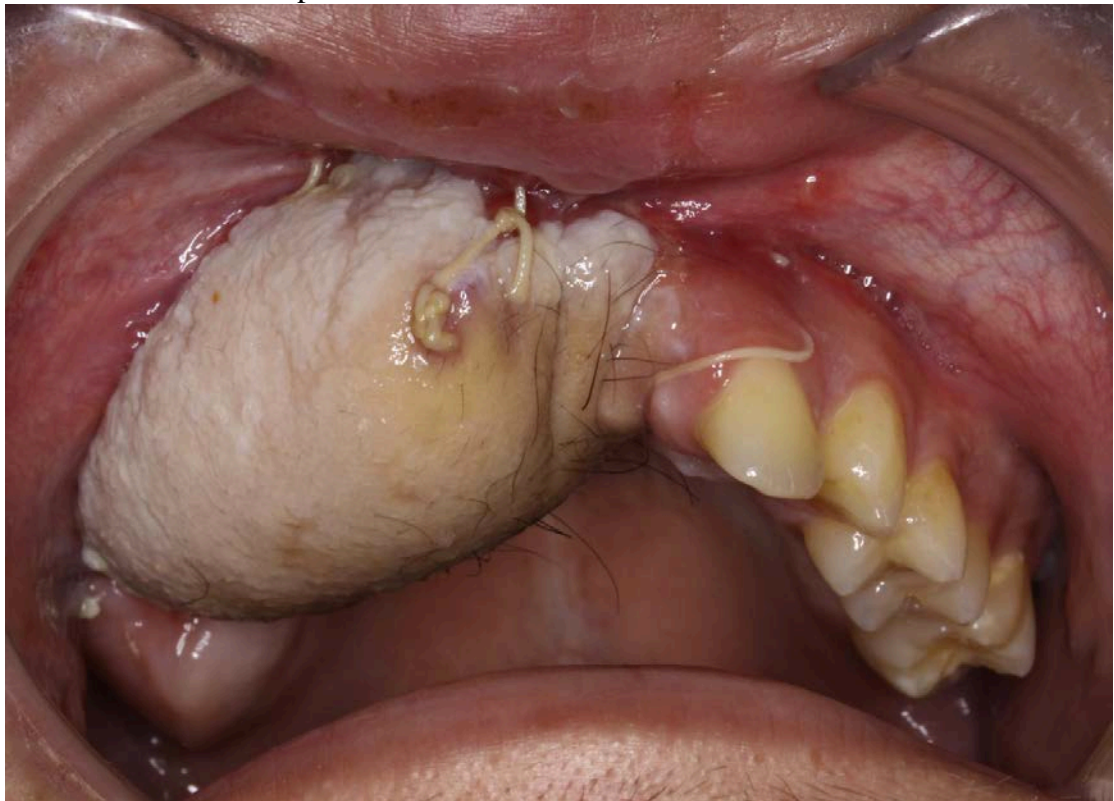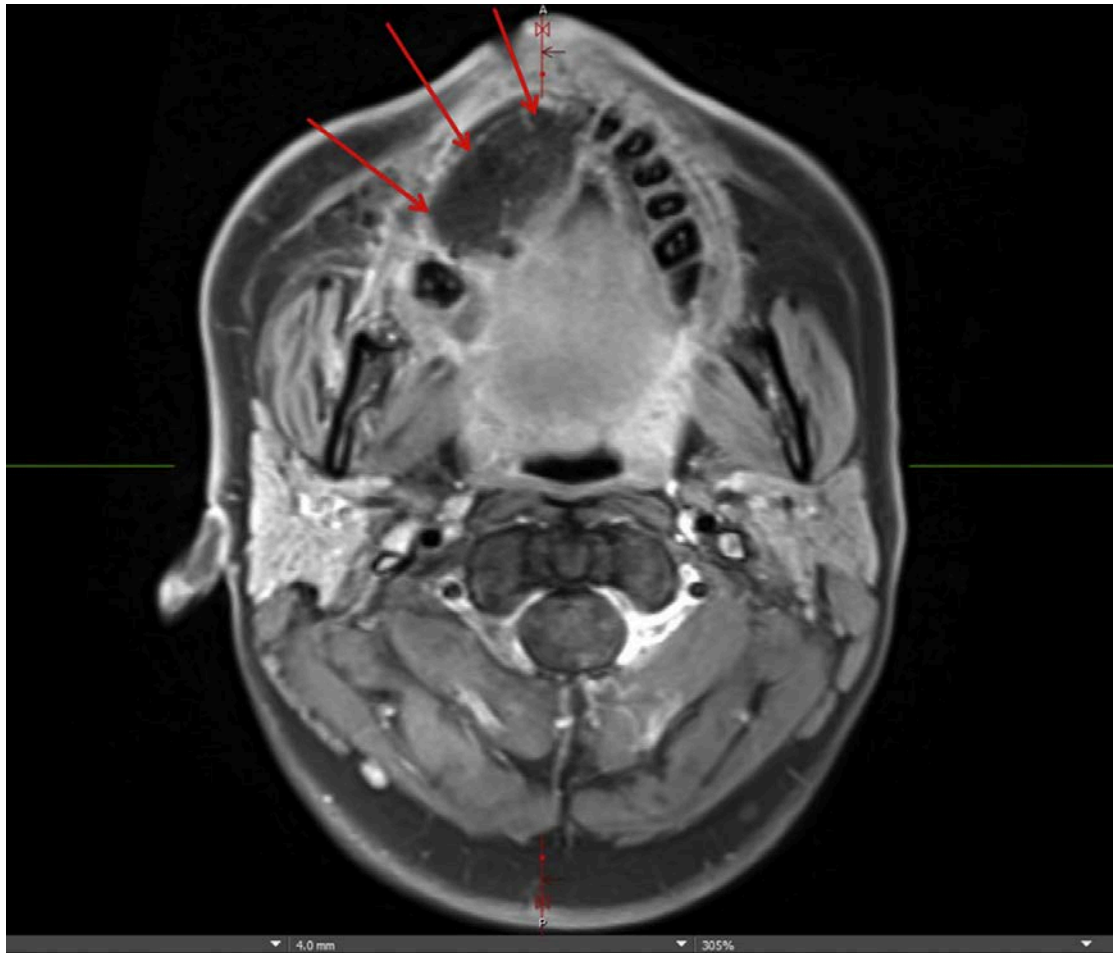


FIGURE 9. Histopathologic features of the tumor with fibroid (**) and myxoid (*) areas (hematoxylin and eosin stain; magnification, ×400)



- FIGURE 10.** Ki-67 expression (~10% positive cells) from immunohistochemical staining with MIB-1 (magnification, ×200)
- The defect was successfully closed and reconstructed using a free lower arm flap from the left side in September 2014.





- The patient recovered quickly from the surgery and did not show any signs of an oroantral fistula or infection of the maxillary sinus after 6 months. Clinical and radiologic follow-up at 6 months showed no evidence of recurrence or metastasis.

Discussion

- A long-term follow-up of 33 LGFMS cases described histologic findings of contrasting fibrous and myxoid zones, bland regular spindle cells, moderate to low cellularity, and slight nuclear polymorphism. Histologically, the present case presented with all these characteristics.
- In 2003, Storlazzi et al identified a novel gene fusion involving FUS and BBF2H7 in 2 patients with LGFMS, which was the first cytogenetic characterization of this rare tumor entity.
 - Reid et al found another fibrosarcoma with this mutation, the HSCT, and they suggested that LGFMS and HSCT were variations of the same entity.
 - In a retrospective analysis of 19 patients with LGFMS, Rose et al found the FUS and BBF2H7 mutation in approximately 82% of cases. They suggested that FISH of the FUS and BBF2H7 mutation was a sensitive diagnostic tool for LGFMS, but that it had no role in predicting the medium-term clinical outcome.

However, the proportion of LGFMS cases positive for this mutation varies considerably, with some suggesting a frequency of 20%, whereas others have reported frequencies of 80 to 95%.
 - In summary, the FUS and BBF2H7 mutation might be an important diagnostic marker, but its consequence on clinical outcome remains unclear

- and warrants further study.
- In the present case, the FUS and BBF2H7 mutation was found by the physicians in Basel; however, the pathologic analysis at the authors' hospital did not detect the FUS and BBF2H7 mutation.
- In 1996, Papadimitriou et al reported the first case of LGFMS in the maxillofacial region in a 4-year-old boy who presented with swelling of the left side of the mandible.
- The tumor was curetted and histologically diagnosed as fibromyxoma.
 - Microscopically, the tumor showed a predominantly lobular pattern of growth, and the lobes were composed of spindle-like cells embedded within mucinous or collagenized stroma; different degrees of cellularity and cells with pale intranuclear eosinophilic inclusions completed the picture, and the tumor cells stained positive for vimentin.
 - Three months later, the patient showed clinical and radiologic evidence of recurrence and underwent radical resection of the mandible.
 - At 15 years postoperatively, there was evidence of further recurrence in the mouth floor and of a circumscribed lung nodule. These were resected, and the patient received radiation therapy. The patient remained free of disease for 2.5 years.
- In 2008, Wu et al reported the case of a 4-year-old girl who was admitted to their hospital in 2000 for a head injury.
- She presented with a nodule at the left angle of the mandible that was initially believed to be a lymph node. After excision, histology showed LGFMS with margin involvement.
 - Microscopically, the tumor showed fibrotic and myxoid areas with variable cellularity. The tumor cells stained positive for vimentin and epithelial membrane antigen; re-excision was not performed.
 - In 2002, the patient presented with local recurrence and a radical excision with a clear margin was performed. The patient remained free of disease for 5 years.
- In 2006 Botev et al reported on a 57-year-old woman with a massive tumor of the left parotid gland.
- The fine-needle aspiration (FNA) biopsy finding was compatible with sarcomatous tissue. After complete resection of the tumor, the final histopathologic analysis confirmed LGFMS.
 - Microscopically, the tumor consisted of fibrous and myxoid tissue with variable cellularity. The fibrous component had spindle cells with a linear arrangement producing swirling growth patterns; the myxoid areas presented spindle- to stellate-shaped cells with an abundant intercellular matrix.
 - Postoperative radiotherapy was conducted, and the patient remained free of disease for 36 months.
- Tang et al published the case of a 2-year-old boy who presented with a slowly growing mass of the right cheek.
- CT depicted a large, well-circumscribed tumor that entirely filled the right temporal, infratemporal, and buccal spaces.
 - After complete resection, the tumor was classified as LGFMS. At 6 months postoperatively, the boy showed no evidence of disease.
- In 2013, He et al reported on a 14-year-old boy who presented with swelling of the right cheek that had been growing for 6 months.

- Four months previously, an FNA biopsy specimen had been misinterpreted as a lymphatic venous malformation and the patient was treated by injection of OK-432.
- Afterward, the tumor enlarged rapidly; therefore, complete excision was performed under general anesthesia.
- The histologic and immunohistochemical examination confirmed a diagnosis of LGFMS. The patient was free of disease at 6 months postoperatively.
- All these cases showed the typical clinical and pathologic signs of LGFMS as described by Evans. LGFMS exhibits a wide range of histologic appearances, which somehow do not relate to tumor behavior and patient survival.
- Surprisingly, in all these case reports, cytogenetic analyses were not presented. Because the FUS gene mutation seems to provide strong evidence for LGFMS, it would be interesting to examine these cases retrospectively.
- Until then, some differential diagnosis-related doubt remains, especially because other fibrous or myxoid soft tissue neoplasms have overlapping histologic features.
- The treatment strategy varies considerably, and long-term follow up is widely recommended because local recurrence and distant metastases are observed frequently, even many years after the primary diagnosis.
 - There are no data concerning patient survival that show the benefit of radical tumor resection, although radical resection is recommended by most surgeons as the treatment of choice.
 - The role of adjuvant chemotherapy or radiotherapy remains unclear, but seems to have no real benefit for the patient.
- In conclusion, this report has described a case of an intraosseous LGFMS of the maxilla, adding another facet to the colorful clinical picture of this rare soft tissue tumor. In accordance with most studies and after extensive staging without signs of metastases, the authors performed a radical tumor resection with safe margins. They have scheduled close follow-up for the patient.

題號	題目
1	關於纖維肉瘤(fibrosarcoma)的敘述何者錯誤 (A) 為惡性腫瘤 (B) 最常見於頭頸部 (C) 最常發生於年輕人或兒童 (D) 治療方式通常是手術切除
答案(A)	出處：Oral and Maxillofacial Pathology, 3e, P.553
題號	題目
2	顎骨中纖維肉瘤(fibrosarcoma)之放射線影像,最常呈現為 (A) 界線清楚之放射線透過性病變(radiolucent lesion) (B) 界線不清楚之放射線透過性病變(radiolucent lesion) (C) 混合放射線透過性和不透過性病變(mixed radiolucent and radiopaque lesion) (D) 放射線不透過性病變(radiopaque lesion)
答案(B)	出處：Oral Radiology, Principle & Interpretation, 6e, P.416