Hindawi Publishing Corporation
Case Reports in Dentistry
Volume 2015, Article ID 830472, 7 pages
http://dx.doi.org/10.1155/2015/830472

Case Report

Oral Manifestations of Crohn's Disease: A Case Report and Review of the Literature

Victoria L. Woo

Oral and Maxillofacial Pathology, School of Dental Medicine, University of Nevada, Las Vegas, NV 89117, USA

Correspondence should be addressed to Victoria L. Woo; victoria.woo@unlv.edu

Received 13 March 2015; Revised 16 June 2015; Accepted 24 June 2015

Academic Editor: Pia Lopez Jornet

Copyright © 2015 Victoria L. Woo. This is an open access article distributed under the Creative Commons Attribution License, which permits unrestricted use, distribution, and reproduction in any medium, provided the original work is properly cited.

Crohn's disease (CD) is an inflammatory disorder of the gastrointestinal tract that is likely caused by an inappropriate mucosal inflammatory response to intestinal bacteria in a genetically predisposed host. The lesions of CD can involve any region of the GI tract as well as extraintestinal sites such as the skin, joints, and eyes. The most common presenting symptoms are abdominal pain and prolonged diarrhea associated with fevers, fatigue, and malaise. Delayed growth and failure to thrive may also be observed in pediatric patients. Oral manifestations of CD are known as oral CD and may precede GI involvement, thus serving as early markers of this condition. We describe a 6-year-old male who presented with oral lesions as his initial manifestation of disease and review the current literature pertaining to oral CD.

1. Introduction

Crohn's disease (CD) is an immune-mediated disorder of the gastrointestinal (GI) tract which, along with ulcerative colitis, comprises the two major subsets of the inflammatory bowel disease (IBD). The underlying etiology is poorly understood but likely involves defects in mucosal immunity and intestinal epithelial barrier function in a genetically susceptible individual, leading to an inappropriate inflammatory response to intestinal microbes [1–3]. The lesions of CD can involve any portion of the alimentary tract from the mouth to anus [4, 5]. Extraintestinal sites such as the skin, joints, and eyes may be affected as well. The most common presenting symptoms are periumbilical abdominal pain and diarrhea associated with recalcitrant fevers, malaise, fatigue, and anorexia [1, 4, 5]. Oral involvement is identified in up to 80% of patients [4, 6, 7] and may precede GI involvement in some cases. We describe a pediatric patient whose initial presentation of CD was multifocal gingival erythema and swelling.

2. Case Report

A 6-year-old male presented with his mother for evaluation of painful and bleeding gingiva. The patient's mother reported that the gingival changes began seven months ago and that the onset was not associated with any identifiable inciting events, including mechanical, thermal, and chemical trauma; dietary changes; use of new dental hygiene products; or exposure to cinnamon-containing products or foodstuffs. She also denied a history of fever, malaise, and GI symptoms. The patient had seen his pediatrician two weeks prior and undergone a complete blood count (CBC) and metabolic panel, which revealed no abnormalities. A thorough dental prophylaxis had also been performed one week prior with no significant improvement in the appearance of his gingiva.

The patient's medical history was significant for asthma, for which he was using mometasone furoate inhaler once daily and albuterol sulfate inhaler on an as-needed basis. His mother stated that he took special care rinsing his mouth after use of the steroid inhaler as directed by his pediatrician. His review of systems and family history were otherwise unremarkable for cardiovascular, endocrinologic, GI, genitourinary, musculoskeletal, hematologic, and neurologic disorders.

Intraoral examination revealed a very subtle area of mucosal erythema involving the gingiva buccal to the right primary maxillary molar, canine, and lateral incisor (Figure 1) and a more well-defined area of erythema involving the alveolar mucosa facial to the left primary maxillary central

Figure 1: Mild mucosal erythema of the right anterior maxillary gingiva.

Figure 2: A demarcated area of mucosal erythema involving the left anterior maxillary alveolar mucosa.

and lateral incisors and canine (Figure 2). Also noted were multiple mucosal-colored swellings and ulcerations of the gingiva facial to the right permanent mandibular central and lateral incisors and primary canine (Figure 3). Mild tenderness was elicited on gentle palpation of the affected sites. The remainder of the oral mucosal examination was within normal limits. No bone loss was evident on radiographic examination.

As requested by the referring periodontist, biopsy of the affected mandibular gingiva was performed. Microscopic examination revealed curved portions of oral mucosa surfaced by spongiotic stratified squamous epithelium with evidence of mild inflammatory cell exocytosis; beneath the epithelium, there was a proliferation of fibrous connective tissue with a patchy infiltrate of lymphocytes and plasma cells (Figure 4(a)). In isolated areas, there were well-formed, noncaseating granulomas composed of epithelioid histiocytes and lymphocytes (Figure 4(b)). Periodic Acid-Schiff (PAS), Grocott-Gomori's methenamine silver (GMS), and Acid-Fast Bacilli (AFB) stains were performed to rule out deep fungal infections and mycobacterial infections such as tuberculosis and leprosy as causes of the granulomas. All stains were negative. Examination of the biopsy under both light and polarized light microscopy did not reveal foreign body material. Hence, a diagnosis of granulomatous inflammation was rendered with a comment pertaining to possible etiologies such as Crohn's disease, orofacial granulomatosis, and sarcoidosis.

Figure 3: Nodular swellings of the interdental papillae between the right permanent mandibular central and lateral incisors and primary canine. An ulceration of the free gingival margin between the incisors is seen. Also noted is a linear ulceration with hyperplastic margins involving the alveolar mucosa.

The patient was provided with a prescription for a mild topical steroid rinse and instructed to rinse and spit four times daily for 14 days. He was also referred to his pediatrician for additional evaluation to rule out for Crohn's disease and other systemic conditions associated with granulomatous inflammation, including sarcoidosis. The patient returned for follow-up three weeks later and demonstrated a modest reduction in the erythema of the maxillary gingiva and swelling of the mandibular gingiva. The patient's mother also reported less pain and bleeding during brushing. The patient was again advised to pursue diagnostic evaluation for systemic causes of granulomatous inflammation. Following evaluation by his pediatrician, he was referred to a pediatric gastroenterologist for consultation. The patient subsequently underwent endoscopic examination and biopsy which showed acute inflammation of the intestinal mucosa. A diagnosis of early Crohn's disease was made. The patient was placed on mesalamine, an anti-inflammatory aminosalicylate, and azathioprine, an immunosuppressant. At one-year follow-up by phone, the patient's mother reports that he continues to respond well to his medications. She states that his oral lesions have completely resolved and that he is currently free of intraoral and GI symptoms.

3. Discussion

CD is a multisystem, inflammatory disorder with a complex etiologic basis that is believed to involve an interplay of genetic, immunologic, and environmental factors [1]. It has been postulated that changes in the immune system and exposure to environmental risk factors are necessary triggers of disease [1]. The increasingly accepted theory is that CD is the result of an inappropriate mucosal inflammatory response to intestinal bacteria in a genetically predisposed host [2, 3]. Although a specific organism has yet to be consistently identified in CD patients [8, 9], the presence of bacteria appears to be an obligatory event in the pathogenesis of this disorder. This is supported by *in vivo* murine models of CD, in which the induction of mucosal inflammation is dependent on microbial stimulation [4]. As a corollary, it has also been shown that inflammation does not occur in

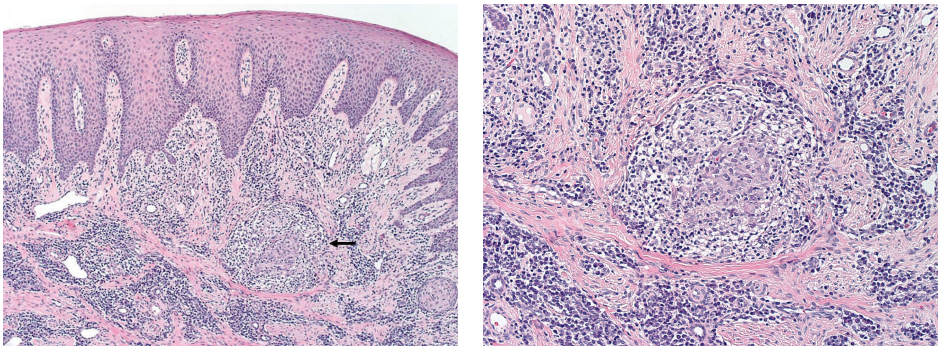

(a) (b)

Figure 4: Histopathologic images of the right mandibular gingiva. (a) Low-power view showing stratified squamous epithelium with scattered intraepithelial lymphocytes (exocytosis). The underlying fibrous connective tissues are characterized by a patchy chronic inflammatory cell infiltrate and an isolated granuloma (arrow) (hematoxylin and eosin, 40x). (b) High-power view showing a well-defined, noncaseating granuloma composed predominantly of epithelioid histiocytes and lymphocytes (hematoxylin and eosin, 100x).

mice raised in a bacteria-free environment [1, 4]. Although similar observations have been reported in human studies, the causative role of bacteria in these investigations remains speculative. It is noteworthy that the microbiota in the intestine is complex and consists of organisms that can potentially exert pro- and anti-inflammatory effects [4]. The shift towards an inflammatory state in CD is believed to be caused by alterations in the intestinal flora and the host's mucosal response, which is influenced by both genetics and immunity [4].

The role of genetics in the pathogenesis of CD was suggested early on with recognition of familial clustering and twin concordance among affected patients [4, 9–12]. A positive family history remains the most important independent risk factor for developing CD to date [4, 13]. More recently, genome-wide analysis studies have revealed more than 30 loci associated with CD [1, 14, 15]. Of significance may be the genetic polymorphisms that alter adaptive immunity and the mutations associated with inadequate surveillance of bacteria by the intestinal mucosa [16–20]. The cumulative effect of these genetic aberrations may be the development of abnormal immune tolerance to intestinal antigens [21, 22]. The inappropriate mucosal inflammatory response that ensues is likely a result of immune system dysregulation. Immunologic mechanisms proposed to be involved in CD include impairment of the innate immune system, leading to a sustained proinflammatory environment in the intestines [1]; excessive activation and differentiation of T-cell subsets against mucosal antigens [23–25]; and aberrant cytokine secretion [26, 27]. In particular, the cytokine IFN-γ appears to play a key role in maintaining the inflammatory milieu in the intestine [4]. Such findings may be significant in the development of more targeted CD therapies [4].

Lastly, certain environmental factors have been implicated in the pathogenesis of CD. These include sociodemographic factors such as economic growth, rises in income levels, and residence in urban areas [28, 29]; geographic factors such as exposure to northern climates [9]; and lifestyle factors such as tobacco smoking, use of oral contraceptives, diet, and psychological stress [9, 28].

CD has a reported incidence 3.1 to 14.6 cases per 100,000 person-years in North America and exhibits a bimodal age distribution, the first peak occurring in early adulthood and the second peak at 50 to 70 years of age [4]. The most common sites of involvement at initial diagnosis are the terminal ileum, ileocecal valve, and cecum [9]. However, any region of the GI tract may be affected, including other areas of the small and large intestines as well as the upper GI tract and oral cavity [4]. The clinical symptoms of CD can vary from patient to patient and depend primarily on the location and behavior of the lesions, disease severity and activity, and the involvement of extraintestinal sites. The most common symptoms include periumbilical or lower right quadrant pain, nonbloody diarrhea of greater than six months in duration, and weight loss accompanied by low-grade fever, malaise, and fatigue [4, 9]. This constellation of findings is believed to represent a harbinger for disease, especially in children [4]. In addition to the aforementioned symptoms, pediatric patients may experience fever of unknown origin, arthralgia, decreased growth, and failure to thrive [9, 30]. Laboratory findings are often nonspecific but may show evidence of GI malabsorption (e.g., low albumin, calcium, folate, iron, and red blood cell count), elevated erythrocyte sedimentation rate (ESR), elevated platelet counts, anemia, and increased acute phase reactants such as C-reactive protein [31–34]. Typical of most immune-mediated disorders, CD follows a chronic, indolent course characterized by periods of relapse and remission. However, the chronic nature of the inflammation ultimately predisposes patients to local complications such as strictures, fistulas, intra-abdominal abscesses, and bowel obstruction [9, 31]. These complications often compromise long-term intestinal function and may require surgical correction with time [4]. Recurrence of CD following surgery is common and is promoted by a number of factors such as a history of penetrating disease, young patient age, ileocolonic disease, and cigarette smoking [35, 36]. Lastly, CD patients are at risk for developing dysplasia or

Table 1: Oral manifestations of Crohn's disease.

Lesion	Site(s)	Characteristics
Persistent mucosal swelling	Lips, buccal mucosa	Labial enlargement, firm to palpation, typically painless
Cobblestoning of mucosa	Buccal mucosa, vestibule	Mucosal edema with or without fissuring
Mucogingivitis	Attached gingiva, alveolar mucosa	Patchy erythematous macules or plaques with or without hyperplasia
Linear ulcerations	Vestibule, buccal mucosa, tongue, palate	Deep ulcerations with or without hyperplastic margins
Mucosal tags or polyps	Buccal mucosa, vestibule	Hyperplasia of mucosa, firm or boggy to palpation

Adapted from Kalmar [31].

adenocarcinoma of the small intestine or colorectal mucosa [37]. Periodic colonoscopic surveillance is therefore a crucial aspect of management [9, 38, 39].

CD is characterized by an array of findings on endoscopic and microscopic examination. In contrast to ulcerative colitis, the pathologic lesions of CD occur in a segmented and discontinuous distribution [4, 9]. Identification of such "skip" lesions—sharply demarcated areas of disease surrounded by completely normal mucosa [9]—is considered a cornerstone in the diagnosis of CD. Once diagnosed, the patient must then undergo further evaluation such as imaging studies to assess the location and extent of lesions as well as the presence of complications [40–42].

It has been estimated that approximately 47% of patients with IBD exhibit extraintestinal manifestations (EIMs) which most frequently involve the skin, eyes, joints, liver, biliary tract, and lungs [4, 9]. Interestingly, the presence of one EIM has been shown to predispose to development of additional EIMs [4]. Involvement of the oral mucosa, termed oral CD, has a widely disparate prevalence rate of 0.5 to 80.0% [4, 6, 7, 43–47] that is likely attributable to differences in study inclusion criteria [4, 48]. It may precede, occur concurrently, or follow the onset of abdominal symptoms [31]. Synchronous or metachronous observation of oral lesions is most commonly described, although Plauth et al. [45] reported oral CD as the presenting symptom in 60% of their patients. Oral lesions considered pathognomonic for CD include persistent lip swelling, cobblestoning of the oral mucosa, mucogingivitis, deep linear or serpiginous ulcerations surrounded by epithelial hyperplasia, and tissue tags or polyps (Table 1) [4, 5, 31, 49, 50]. These may be associated with pain, impairment of oral function, and psychosocial stress [45]. It is important to bear in mind that affected patients may not always present with these classic lesions and detection of oral CD can be challenging, particularly if the lesions are subtle or the patient is in early stages of disease. Other oral findings that may be seen include aphthous ulcerations, angular cheilitis, stomatitis, glossitis, and perioral dermatitis [4]. However, these are considered nonspecific for CD as they may represent primary manifestations of disease or occur secondary to nutritional deficiencies induced by intestinal malabsorption, dietary restriction, or medications [4, 50]. Oral CD often demonstrates a young age of presentation and is most frequently seen in adolescents and young adults [45]. Interestingly, Hussey et al. [51] reported that only 29% of the children in their study continued to harbor CD-specific oral lesions over a mean follow-up of 55 months and emphasized the need for timely recognition and biopsy in the pediatric population. Harty et al. [47] reported the presence of granulomatous inflammation in 100% of the biopsies performed in their study and reiterated the value of the easily accessible oral mucosa as a potential site for harvesting diagnostic material, especially in children.

The clinical differential diagnosis for oral CD in a pediatric patient is broad and encompasses a variety of conditions that may present with oral mucosal swellings, masses, and/or ulcerations as follows:

Multifocal Mucosal Swelling and Cobblestoning of Mucosa

- Idiopathic orofacial granulomatosis
- Neurofibromatosis
- Multiple endocrine neoplasia (MEN) 2B/III
- Multiple hamartoma syndrome (Cowden disease)
- Multifocal epithelial hyperplasia (Heck's disease)
- Amyloidosis.

Ulcerations (Linear and Aphthous-Like)

- Recurrent aphthous stomatitis
- Aphthous ulcerations associated with an underlying systemic disease including
  - celiac disease,
  - ulcerative colitis,
  - immunocompromised conditions (e.g., HIV and AIDS),
  - hematologic disorders (e.g., neutropenia, cyclic neutropenia, and leukemia),
  - nutritional deficiencies,
  - MAGIC syndrome (i.e., mouth and genital ulcers with inflamed cartilage),
  - PFAPA syndrome (i.e., periodic fever, aphthous stomatitis, pharyngitis, and cervical adenitis),
  - Behçet's syndrome.

Viral infections including

herpes simplex infection,
varicella zoster infection,
enterovirus infection (e.g., hand-foot-mouth disease and herpangina).

Traumatic ulcerations

Chemical or thermal burns

Pemphigus vulgaris

Mucous membrane pemphigoid

Erythema multiforme.

Swellings and/or Ulcerations That Exhibit Granulomatous Inflammation on Microscopic Examination

Foreign body reaction and foreign body gingivitis

Allergy

Orofacial granulomatosis, including Melkersson-Rosenthal syndrome and cheilitis granulomatosa

Sarcoidosis

Tuberculosis

Leprosy

Deep fungal infections (e.g., histoplasmosis, blastomycosis, paracoccidioidomycosis, and coccidioidomycosis)

Tertiary syphilis.

Diagnostic considerations prior to histologic examination include idiopathic orofacial granulomatosis; syndromes presenting with multiple mucosal swellings, such as neurofibromatosis, multiple endocrine neoplasia (MEN) 2B/III, and multiple hamartoma syndrome (Cowden disease); aphthous ulcerations in the presence or absence of an underlying systemic disease; and other vesiculoerosive diseases of various etiologies. The differential diagnosis for histologically confirmed oral granulomatous inflammation in a younger patient can be broadly subcategorized into disorders of localized or systemic etiology. Localized causes of granulomatous inflammation include a foreign body reaction (e.g., granulomatous gingivitis); allergic reaction to cinnamon or benzoate; and idiopathic orofacial granulomatosis, a diagnosis of exclusion that requires elimination of other defined causes of granulomatous inflammation. Systemic conditions associated with granulomatous inflammation include Crohn's disease, sarcoidosis, mycobacterial infections, deep fungal infections, and tertiary syphilis. Ultimately, the diagnosis of CD hinges on careful correlation between the patient's clinical history and findings on physical, radiographic, endoscopic, laboratory, and microscopic examinations.

The management of CD is dependent on the disease location and activity as well as the presence of complications [4]. The predominant classes of medications used in the treatment of CD include anti-inflammatory agents such as aminosalicylates and steroids, immunosuppressants or immunomodulators such as thiopurines and methotrexate, and biologic agents such as infliximab. The standard "step-up" protocol advocates use of oral corticosteroid therapy for patients with mild-to-moderate CD localized to the ileocecal region [52] and a combination of oral corticosteroids and immunosuppressants for patients with moderate-to-severe small bowel disease and relapsing or steroid-refractory disease [52–54]. Biologic agents are recommended for patients who do not respond to or cannot tolerate standard therapy and in whom corticosteroids are contraindicated [4]. Surgery is typically postponed for as long as possible as it is not considered curative and may be associated with a number of functional complications and recurrence of disease [4]. Recently, there has been a shift in favor of administering biologic agents such as infliximab in patients with newly diagnosed CD, a so-called "top-down" approach [55]. It is believed that introduction of biologics early in disease may disrupt the natural evolution of CD from the inflammatory stage to the advanced stages, which is generally less responsive to pharmacologic therapy and more often associated with the development of complications [4, 56]. Management is more complex in the pediatric population because of the potential impact of CD medications on growth and development. The overall goals of CD treatment in children are to achieve the best possible control of disease with the least adverse effects, to promote continued growth through nutrition, and to enable the child to maintain normal day-to-day activities such as attending school [57]. Although no standardized protocol exists, most clinicians follow a step-up approach of administering an aminosalicylate, antibiotics, and nutritional therapy, followed by the addition of corticosteroid, immunomodulatory, and biologic therapy as deemed necessary [57]. As with adult CD, there is early evidence to support the top-down approach but further studies are necessary before widespread implementation [57]. Exclusive enteral nutrition (EN), also known as tube feeding, is another therapeutic option in children with CD [58, 59]. Pain associated with oral CD can be managed with topical, systemic, or injectable steroids with or without the use of immunosuppressive agents such as azathioprine [31, 45]; however, oral lesions typically respond well to systemic treatment of intestinal CD [50].

In summary, we have described a 6-year-old male with oral lesions as his initial manifestation of CD. This case underscores the importance of recognizing the variable, sometimes subtle, presentation of oral CD and performing necessary diagnostic procedures, such as biopsy for histopathologic confirmation. Astute identification of oral lesions is key as studies have shown that only a minority of patients will continue to exhibit oral findings at follow-up [51]. In addition, it has been reported that the ability of physicians to identify oral CD was poor when a dentist's exam was used as a comparator [47]. The dental practitioner is therefore in a unique position to detect oral CD, which may be the only manifestation of occult disease in patients who are otherwise asymptomatic. This may lead to early diagnosis, timely treatment, and ultimately a better outcome in affected patients.

Conflict of Interests

The author declares that there is no conflict of interests regarding the publication of this paper.

Acknowledgment

Special thanks are due to Dr. Gillian Galbraith for her critical and constructive review of this paper.

References

[1] J. W. Mays, M. Sarmadi, and N. M. Moutsopoulos, "Oral manifestations of systemic autoimmune and inflammatory diseases: diagnosis and clinical management," *The Journal of Evidence-Based Dental Practice*, vol. 12, no. 3, supplement, pp. 265–282, 2012.

[2] D. C. Baumgart and S. R. Carding, "Inflammatory bowel disease: cause and immunobiology," *The Lancet*, vol. 369, no. 9573, pp. 1627–1640, 2007.

[3] C. Abraham and J. H. Cho, "Inflammatory bowel disease," *The New England Journal of Medicine*, vol. 361, no. 21, pp. 2066–2078, 2009.

[4] M. Boirivant and A. Cossu, "Inflammatory bowel disease," *Oral Diseases*, vol. 18, no. 1, pp. 1–15, 2012.

[5] R. A. Boraz, "Oral manifestations of Crohn disease: update of the literature and report of case," *ASDC Journal of Dentistry for Children*, vol. 55, no. 1, pp. 72–74, 1988.

[6] J. S. Hyams, "Extraintestinal manifestations of inflammatory bowel disease in children," *Journal of Pediatric Gastroenterology and Nutrition*, vol. 19, no. 1, pp. 7–21, 1994.

[7] S. Pittock, B. Drumm, P. Fleming et al., "The oral cavity in Crohn's disease," *The Journal of Pediatrics*, vol. 138, no. 5, pp. 767–771, 2001.

[8] F. Alawi, "Granulomatous diseases of the oral tissues: differential diagnosis and update," *Dental Clinics of North America*, vol. 49, no. 1, pp. 203–221, 2005.

[9] M. Rendi, "Crohn disease pathology," 2014, http://emedicine.medscape.com/article/1986158-overview.

[10] K. Karlinger, T. Györke, E. Makö, Á. Mester, and Z. Tarján, "The epidemiology and the pathogenesis of inflammatory bowel disease," *European Journal of Radiology*, vol. 35, no. 3, pp. 154–167, 2000.

[11] M. Orholm, V. Binder, T. I. A. Sørensen, L. P. Rasmussen, and K. O. Kyvik, "Concordance of inflammatory bowel disease among Danish twins. Results of a nationwide study," *Scandinavian Journal of Gastroenterology*, vol. 35, no. 10, pp. 1075–1081, 2000.

[12] C. Tysk, E. Lindberg, G. Jarnerot, and B. Floderus-Myrhed, "Ulcerative colitis and Crohn's disease in an unselected population of monozygotic and dizygotic twins. A study of heritability and the influence of smoking," *Gut*, vol. 29, no. 7, pp. 990–996, 1988.

[13] R. K. Russell and J. Satsangi, "IBD: a family affair," *Best Practice & Research: Clinical Gastroenterology*, vol. 18, no. 3, pp. 525–539, 2004.

[14] J. H. Cho and C. T. Weaver, "The genetics of inflammatory bowel disease," *Gastroenterology*, vol. 133, no. 4, pp. 1327–1339, 2007.

[15] J. C. Barrett, S. Hansoul, D. L. Nicolae, J. H. Cho, R. H. Duerr, and J. D. Rioux, "Genome-wide association defines more than 30 distinct susceptibility loci for Crohn's disease," *Nature Genetics*, vol. 40, no. 8, pp. 955–962, 2008.

[16] R. H. Duerr, K. D. Taylor, S. R. Brant et al., "A genome-wide association study identifies IL23R as an inflammatory bowel disease gene," *Science*, vol. 314, no. 5804, pp. 1461–1463, 2006.

[17] C. Abraham and J. H. Cho, "Functional consequences of NOD2 (CARD15) mutations," *Inflammatory Bowel Diseases*, vol. 12, no. 7, pp. 641–650, 2006.

[18] M. Hedl, J. Li, J. H. Cho, and C. Abraham, "Chronic stimulation of Nod2 mediates tolerance to bacterial products," *Proceedings of the National Academy of Sciences of the United States of America*, vol. 104, no. 49, pp. 19440–19445, 2007.

[19] C. R. Homer, A. L. Richmond, N. A. Rebert, J. Achkar, and C. McDonald, "ATG16L1 and NOD2 interact in an autophagy-dependent antibacterial pathway implicated in crohn's disease pathogenesis," *Gastroenterology*, vol. 139, no. 5, pp. 1630–1641, 2010.

[20] L. H. Travassos, L. A. M. Carneiro, M. Ramjeet et al., "Nod1 and Nod2 direct autophagy by recruiting ATG16L1 to the plasma membrane at the site of bacterial entry," *Nature Immunology*, vol. 11, no. 1, pp. 55–62, 2010.

[21] G. R. D'Haens, K. Geboes, M. Peeters, F. Baert, F. Penninckx, and P. Rutgeerts, "Early lesions of recurrent Crohn's disease caused by infusion of intestinal contents in excluded ileum," *Gastroenterology*, vol. 114, no. 2, pp. 262–267, 1998.

[22] R. K. Sellon, S. Tonkonogy, M. Schultz et al., "Resident enteric bacteria are necessary for development of spontaneous colitis and immune system activation in interleukin-10-deficient mice," *Infection and Immunity*, vol. 66, no. 11, pp. 5224–5231, 1998.

[23] S. Brand, "Crohn's disease: Th1, Th17 or both? The change of a paradigm: new immunological and genetic insights implicate Th17 cells in the pathogenesis of Crohn's disease," *Gut*, vol. 58, no. 8, pp. 1152–1167, 2009.

[24] P. P. Ahern, C. Schiering, S. Buonocore et al., "Interleukin-23 drives intestinal inflammation through direct activity on T cells," *Immunity*, vol. 33, no. 2, pp. 279–288, 2010.

[25] T. Kobayashi, S. Okamoto, T. Hisamatsu et al., "IL23 differentially regulates the Th1/Th17 balance in ulcerative colitis and Crohn's disease," *Gut*, vol. 57, no. 12, pp. 1682–1689, 2008.

[26] M. Saruta, Q. T. Yu, P. R. Fleshner et al., "Characterization of $FOXP3^{+}CD4^{+}$ regulatory T cells in Crohn's disease," *Clinical Immunology*, vol. 125, no. 3, pp. 281–290, 2007.

[27] M. J. Barnes and F. Powrie, "Regulatory T cells reinforce intestinal homeostasis," *Immunity*, vol. 31, no. 3, pp. 401–411, 2009.

[28] E. V. Loftus Jr., "Clinical epidemiology of inflammatory bowel disease: incidence, prevalence, and environmental influences," *Gastroenterology*, vol. 126, no. 6, pp. 1504–1517, 2004.

[29] C. S. Gismera and B. S. Aladrén, "Inflammatory bowel diseases: a disease (s) of modern times? Is incidence still increasing?" *World Journal of Gastroenterology*, vol. 14, no. 36, pp. 5491–5498, 2008.

[30] G. E. Block, F. Michelassi, M. Tanaka, R. H. Riddell, and S. B. Hanauer, "Crohn's disease," *Current Problems in Surgery*, vol. 30, no. 2, pp. 183–265, 1993.

[31] J. R. Kalmar, "Crohn's disease: orofacial considerations and disease pathogenesis," *Periodontology 2000*, vol. 6, pp. 101–115, 1994.

[32] A. Kornbluth and D. B. Sachar, "Ulcerative colitis practice guidelines in adults (update): american college of gastroenterology, practice parameters committee," *The American Journal of Gastroenterology*, vol. 99, no. 7, pp. 1371–1385, 2004.

[33] P. Chamouard, Z. Richert, N. Meyer, G. Rahmi, and R. Baumann, "Diagnostic value of C-reactive protein for predicting activity level of Crohn's disease," *Clinical Gastroenterology and Hepatology*, vol. 4, no. 7, pp. 882–887, 2006.

[34] J. Goh and C. A. O'Morain, "Review article: nutrition and adult inflammatory bowel disease," *Alimentary Pharmacology and Therapeutics*, vol. 17, no. 3, pp. 307–320, 2003.

[35] E. Langholz, "Review: current trends in inflammatory bowel disease: the natural history," *Therapeutic Advances in Gastroenterology*, vol. 3, no. 2, pp. 77–86, 2010.

[36] P. Papay, W. Reinisch, E. Ho et al., "The impact of thiopurines on the risk of surgical recurrence in patients with Crohn's disease after first intestinal surgery," *The American Journal of Gastroenterology*, vol. 105, no. 5, pp. 1158–1164, 2010.

[37] S. H. Itzkowitz, "Inflammatory bowel disease and cancer," *Gastroenterology Clinics of North America*, vol. 26, no. 1, pp. 129–139, 1997.

[38] J. A. Eaden and J. F. Mayberry, "Guidelines for screening and surveillance of asymptomatic colorectal cancer in patients with inflammatory bowel disease," *Gut*, vol. 51, supplement 5, pp. v10–v12, 2002.

[39] C. Canavan, K. R. Abrams, and J. Mayberry, "Meta-analysis: colorectal and small bowel cancer risk in patients with Crohn's disease," *Alimentary Pharmacology and Therapeutics*, vol. 23, no. 8, pp. 1097–1104, 2006.

[40] E. F. Stange, S. P. L. Travis, S. Vermeire et al., "European evidence based consensus on the diagnosis and management of Crohn's disease: definitions and diagnosis," *Gut*, vol. 55, no. 1, 2006.

[41] B. A. MacKalski and C. N. Bernstein, "New diagnostic imaging tools for inflammatory bowel disease," *Gut*, vol. 55, no. 5, pp. 733–741, 2006.

[42] G. Maconi, G. M. Sampietro, F. Parente et al., "Contrast radiology, computed tomography and ultrasonography in detecting internal fistulas and intra-abdominal abscesses in Crohn's disease: a prospective comparative study," *American Journal of Gastroenterology*, vol. 98, no. 7, pp. 1545–1555, 2003.

[43] A. J. Greenstein, H. D. Janowitz, and D. B. Sachar, "The extra intestinal complications of Crohn's disease and ulcerative colitis: a study of 700 patients," *Medicine*, vol. 55, no. 5, pp. 401–412, 1976.

[44] M. L. Bernstein and J. S. McDonald, "Oral lesions in Crohn's disease: report of two cases and update of the literature," *Oral Surgery, Oral Medicine, Oral Pathology*, vol. 46, no. 2, pp. 234–245, 1978.

[45] M. Plauth, H. Jenss, and J. Meyle, "Oral manifestations of Crohn's disease: an analysis of 79 cases," *Journal of Clinical Gastroenterology*, vol. 13, no. 1, pp. 29–37, 1991.

[46] H. J. Scheper and H. S. Brand, "Oral aspects of Crohn's disease," *International Dental Journal*, vol. 52, no. 3, pp. 163–172, 2002.

[47] S. Harty, P. Fleming, M. Rowland et al., "A prospective study of the oral manifestations of Crohn's disease," *Clinical Gastroenterology and Hepatology*, vol. 3, no. 9, pp. 886–891, 2005.

[48] M. Rowland, P. Fleming, and B. Bourke, "Looking in the mouth for Crohn's disease," *Inflammatory Bowel Diseases*, vol. 16, no. 2, pp. 332–337, 2010.

[49] A. C. Chi, B. W. Neville, J. W. Krayer, and W. C. Gonsalves, "Oral manifestations of systemic disease," *American Family Physician*, vol. 82, no. 11, pp. 1381–1388, 2010.

[50] M. Fatahzadeh, "Inflammatory bowel disease," *Oral Surgery, Oral Medicine, Oral Pathology, Oral Radiology and Endodontology*, vol. 108, no. 5, pp. e1–e10, 2009.

[51] S. Hussey, P. Fleming, M. Rowland et al., "Disease outcome for children who present with oral manifestations of Crohn's disease," *European Archives of Paediatric Dentistry*, vol. 12, no. 3, pp. 167–169, 2011.

[52] S. P. L. Travis, E. F. Stange, M. Lémann et al., "European evidence based consensus on the diagnosis and management of Crohn's disease: current management," *Gut*, vol. 55, supplement 1, pp. i16–i35, 2006.

[53] E. Prefontaine, J. K. Macdonald, and L. R. Sutherland, "Azathioprine or 6-mercaptopurine for induction of remission in Crohn's disease," *Cochrane Database of Systematic Reviews*, no. 4, Article ID CD000545, 2009.

[54] E. Prefontaine, J. K. Macdonald, and L. R. Sutherland, "Azathioprine or 6-mercaptopurine for induction of remission in Crohn's disease," *The Cochrane Database of Systematic Reviews*, no. 6, Article ID CD000545, 2010.

[55] G. D'Haens, F. Baert, G. van Assche et al., "Early combined immunosuppression or conventional management in patients with newly diagnosed Crohn's disease: an open randomised trial," *The Lancet*, vol. 371, no. 9613, pp. 660–667, 2008.

[56] G. R. D'Haens, "Top-down therapy for IBD: rationale and requisite evidence," *Nature Reviews Gastroenterology & Hepatology*, vol. 7, no. 2, pp. 86–92, 2010.

[57] A. B. Grossman, "Pediatric Crohn Disease," 2015, http://emedicine.medscape.com/article/928288-overview.

[58] A. K. Akobeng, "Crohn's disease: current treatment options," *Archives of Disease in Childhood*, vol. 93, no. 9, pp. 787–792, 2008.

[59] H. A. Büller, "Problems in diagnosis of IBD in children," *The Netherlands Journal of Medicine*, vol. 50, no. 2, pp. S8–S11, 1997.

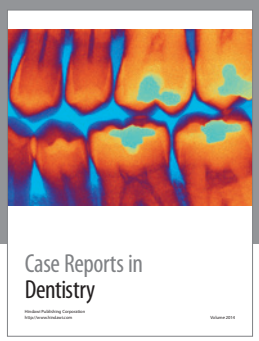







Hindawi
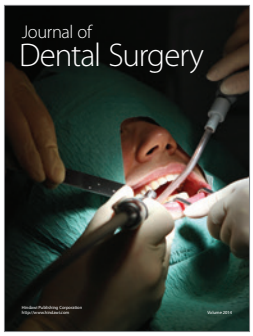
Submit your manuscripts at
http://www.hindawi.com