

Cleidocranial dysplasia: a review of the dental, historical, and practical implications with an overview of the South African experience

Tina Roberts, BChD, MChD,^a Lawrence Stephen, BChD, MSc, PhD,^b and Peter Beighton, MD, PhD, FRCP,^c
Cape Town, South Africa

UNIVERSITY OF THE WESTERN CAPE AND UNIVERSITY OF CAPE TOWN

Cleidocranial dysplasia (CCD) is an uncommon but well-known genetic skeletal condition. Several hundred affected persons are members of a large extended family in the Cape Town Mixed Ancestry community of South Africa. The clinical manifestations are often innocuous, but hyperdontia and other developmental abnormalities of the teeth are a major feature and may require special dental management.

Over the past 40 years, the authors have encountered more than 100 affected persons in Cape Town. Emphasis has been on dental management, but medical, genetic, and social problems have also been addressed. In this article, we have reviewed the manifestations of the disorder in the light of our own experience, and performed a literature search with emphasis on the various approaches to dental management and treatment options in CCD. Advances in the understanding of the biomolecular pathogenesis of CCD are outlined and the international and local history of the disorder is documented. (Oral Surg Oral Med Oral Pathol Oral Radiol 2013;115:46-55)

The purpose of this article was to review the dental manifestations and management of cleidocranial dysplasia (CCD) [OMIM 119600]. The history, genetic background, and general manifestations of CCD are also outlined and an overview is presented.

The disorder is a genetic skeletal dysplasia in which hypoplasia of the clavicles and deficient ossification of the anterior fontanelle are the major features. Affected persons have a characteristic facial appearance with a bulky forehead, hypertelorism, and midfacial hypoplasia.¹ General health is usually good and the intellect is unimpaired.² The adverse general health effects of CCD are usually not very severe or debilitating and there is no associated impairment in cognitive or intellectual functioning in affected persons.²

A variety of dental problems may occur in CCD. In particular, supernumerary teeth (hyperdontia) in the primary and secondary dentition may lead to dental crowding and malocclusion. Retention of the deciduous

teeth may exacerbate this situation. For these reasons, dental management is a significant aspect of the health care of affected persons.

Cleidocranial dysplasia is inherited as an autosomal dominant trait, with generation-to-generation transmission. Owing to the founder effect, the condition is comparatively common in the mixed ancestry community of Cape Town, South Africa.³ This group has genetic endowment from San and Xhosi Xhosi populations, with input from indigenous African, Indonesian, East Indian, and European sources. Numerous members of an extended family and a founder effect were initially documented by Jackson in 1951.³ Whereas the worldwide prevalence of CCD is generally regarded as being about 1 per million, in this Cape Town community, the minimum prevalence is 100 per million.

In view of the special importance of CCD in this country, we have reviewed the history of the disorder and described and depicted the clinical and radiological manifestations. To alert clinicians, special emphasis has been given to hyperdontia and to the dental complications and their management.

HISTORICAL REVIEW

The early history of CCD goes back to prehistorical times, by virtue of a possible example of CCD in a Neanderthal skull, which was documented by Greig in 1933.⁴ Greig was a Scottish surgeon who became curator of the Museum of the Royal College of Surgeons of Edinburgh. In Greek mythology, the ugly hero Ther-sites was described by Homer as being able to oppose his shoulders in front of his chest.⁵ Another example of a more objective case from ancient Greece is repre-

This project was supported by grants to P.B. from the South African Medical Research Council and the National Research Foundation. The authors do not have any conflicts of interest.

^aSpecialist in Oral Pathology, Faculty of Dentistry, University of the Western Cape, Cape Town, South Africa.

^bProfessor of Dentistry, Faculty of Dentistry, University of the Western Cape, Cape Town, South Africa.

^cEmeritus Professor, Division of Human Genetics, Faculty of Health Sciences, University of Cape Town, Cape Town, South Africa.

Received for publication Dec 7, 2011; returned for revision May 26, 2012; accepted for publication Jul 9, 2012.

© 2013 Elsevier Inc. All rights reserved.

2212-4403/\$ - see front matter

<http://dx.doi.org/10.1016/j.o.oooo.2012.07.435>

sented by a skeleton of a woman who lived in the Pylos region. Her absent clavicles and stunted stature were thought to be suggestive of CCD.⁶ A skeleton of an affected male who died of tuberculosis in 1809, which is displayed in the Museum of Pathological Anatomy, Vienna,^{7,8} shows the classical manifestations of CCD.

The earliest recognizable report of CCD in the medical literature has been attributed to Meckel in 1760.⁹ At the time of publication, Johann Frederick Meckel the Elder was professor of anatomy and surgical obstetrics at the University of Halle. Five years after Meckel's article, in 1765, Martin¹⁰ documented "natural displacement of the clavicle" in the French literature. The combination of clavicular and cranial defects was recognized by Scheuthauer (1871).¹¹ The Parisian physicians Marie and Sainton (1897)¹² documented an affected father and son, and in the following year they published a second article entitled "On hereditary cleidocranial dysostosis," thereby formally naming the disorder.¹³ In 1908, Hultcrantz¹⁴ reviewed 68 cases and published a detailed account of the anatomical changes.

Case reports accumulated, including a description of an extensive affected family in Cape Town.³ Extensive minor skeletal involvement was emphasized by Jensen,¹⁵ and the name of the disorder was changed to "cleidocranial dysplasia." By the millennium, the determinant gene had been mapped to the chromosomal locus 6p21.¹⁶ The gene termed *RUNX2* (runt-related transcription factor 2) has been sequenced and considerable intragenic heterogeneity has been recognized.¹⁷ It has been shown that the gene product is involved in the control of osteoblastic differentiation and chondrocyte mutation during endochondral ossification.¹⁸

Cleidocranial dysplasia in South Africa

Interest in CCD in South Africa was engendered by W.P.U. Jackson, a senior physician at Groote Schuur Hospital, Cape Town. His classic article, published in 1951, has received wide international recognition.³ In his own words:

"This story started when a small Cape Malay (Cape Mixed Ancestry community) boy of seven years was kicked in the face by a horse. He was admitted to Groote Schuur Hospital, Cape Town, and it was noticed that the vertex of his skull was largely missing and that he had gross frontal bossing with a deep median furrow. The outer ends of his clavicles were defective, and other abnormalities were shown by X-rays. From him we have managed to trace the whole family back to the first member to arrive in South Africa. We managed to trace 356 of his descendents of the progenitor, of whom at least 70 were have been affected with osteo-dental dysplasia (now known as cleidocranial dysplasia)."

Jackson went on to state that this individual was a sailor from a polygamous community in China who settled in Somerset West, Cape Province in 1896 and married several local women. Offspring with CCD were born in 4 of these unions and their numerous affected descendents are still aware of their family links. The kindred claim that their progenitor was from Java, Indonesia, rather than China, as suggested by Jackson.

In 1988, a research team from the Medical Research Council of South Africa Unit for Heritable Disorders of the Skeleton in the Department of Human Genetics, Medical School, University of Cape Town, were able to contact the affected family and undertook clinical, radiographic, and genealogical appraisal of 64 affected individuals at the Groote Schuur and Red Cross Memorial Hospitals. Collaboration with the Faculty of Dentistry, University of the Western Cape was established and detailed dental examinations were undertaken by Emeritus Professor J. Staz of the Faculty of Dentistry, University of the Western Cape. His findings were promulgated at the 21st International Congress of the South African Division of the International Association for Dental Research,¹⁹ and documented in the following year.²⁰ Interest in CCD continued, and in 1993, an appraisal of skeletons in the Museum of Pathological Anatomy, Vienna, facilitated publication and depiction of a skeleton of an affected individual.⁸ In 1995, researchers in Europe and the United States suggested that the CCD gene was situated in the chromosomal region 6p21. Genetic linkage investigations were then undertaken in the Department of Human Genetics, involving 38 members of a branch of the Cape Town family who had been identified in the earlier investigation. The investigation revealed that the determinant gene in this family mapped to the previously recognized same chromosomal locus 6p21.²¹ Other than the extended family in the Cape, the only report of CCD in South Africa concerns a girl, aged 15 years, of indigenous African stock, who was investigated at the Oral Health Dental Centre, Medunsa.²² She was the only member of her family known to be affected and presumably represents a new mutation for the determinant gene.

CLINICAL MANIFESTATIONS

General features

The major manifestations of CCD are clavicular hypoplasia (Figs. 1 and 2), delayed fusion of cranial sutures, and dental abnormalities. The defective clavicles permit undue mobility of the shoulders, which can often be approximated anteriorly (Fig. 3). Patency of the anterior fontanelle (Fig. 4) can produce a bulky configuration or a depression in the midline of the

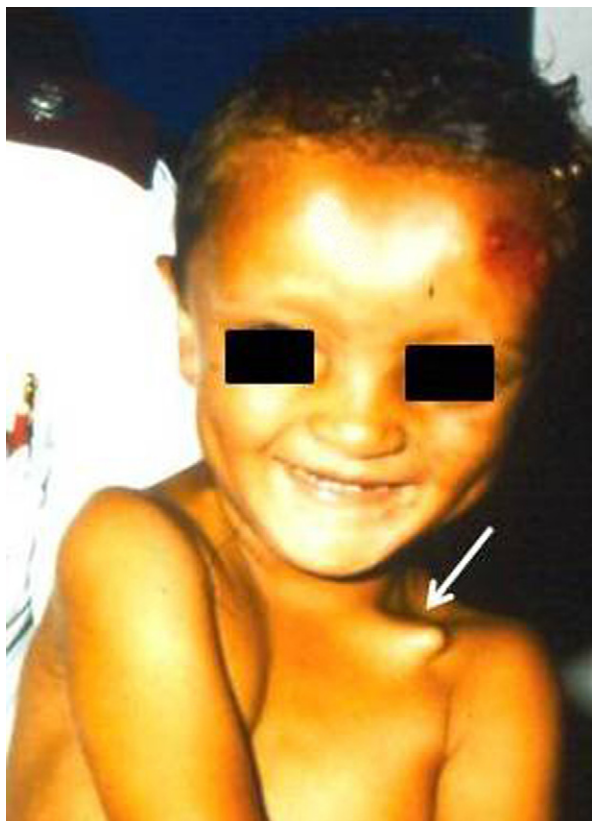

Fig. 1. Cleidocranial dysplasia; characteristic appearance. The forehead is bulky with a central depression, the eyes are widely spaced and the jaw is pointed. The clavicle is mal-formed (arrow).

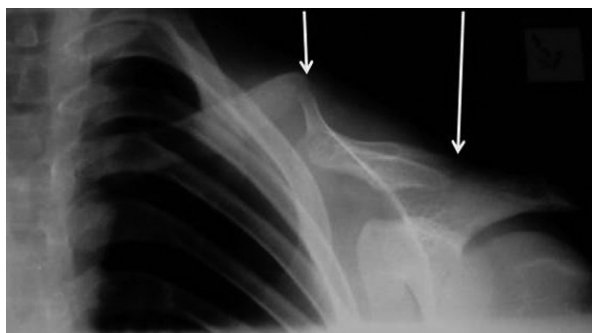

Fig. 2. Radiographically, clavicular hypoplasia and abnormal morphology are evident (arrows).

upper forehead. Hypertelorism and a pointed jaw are other features that contribute to a characteristic facial appearance.

The number of teeth may be excessive (hyperdontia), and lead to dental crowding and malalignment.²³ Skeletal abnormalities may also occur, including slight stature, short terminal phalanges, spinal malalignment, genu valgus (knock knees), and pes planus²⁴ (flat feet). Affected persons may experience recurrent infections

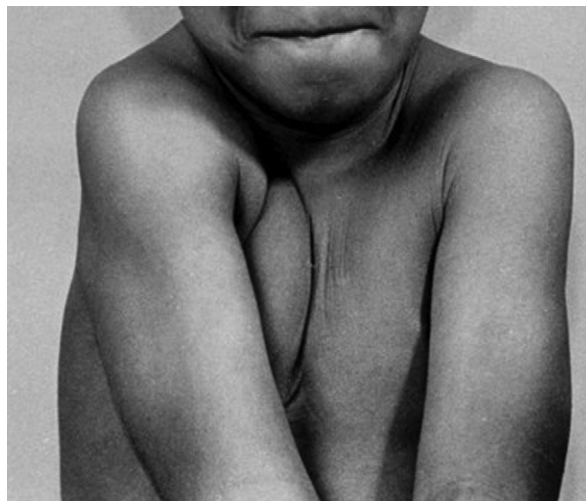


Fig. 3. Anterior apposition of shoulders in facilitated by bilateral clavicular hypoplasia.

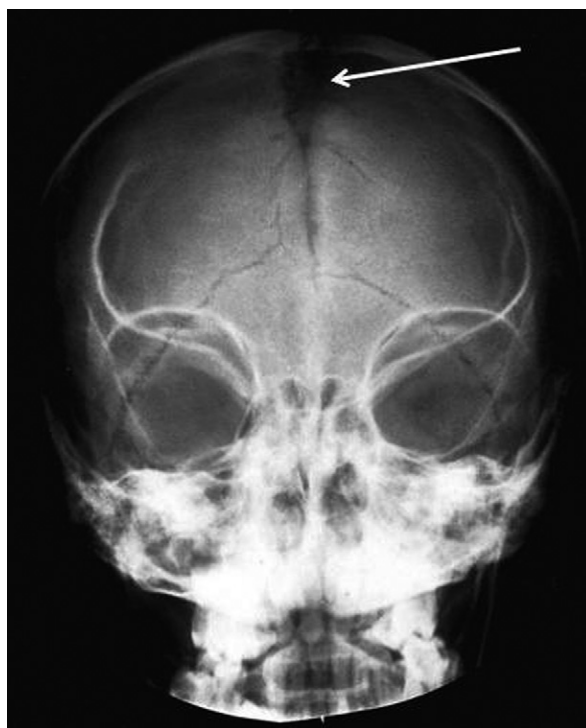

Fig. 4. Antero-posterior skull radiograph showing patency of the anterior fontanelle (arrow).

of the upper respiratory tract owing to maldevelopment of the sinuses, with a potential for hearing loss consequent upon chronic otitis media.²⁵ Despite these problems, CCD is very variable and often comparatively mild; apart from dental complications, affected persons usually have little disability.

Radiographically, Wormian bones may be evident in the cranial sutures (Fig. 5).²⁶ The clavicles may be

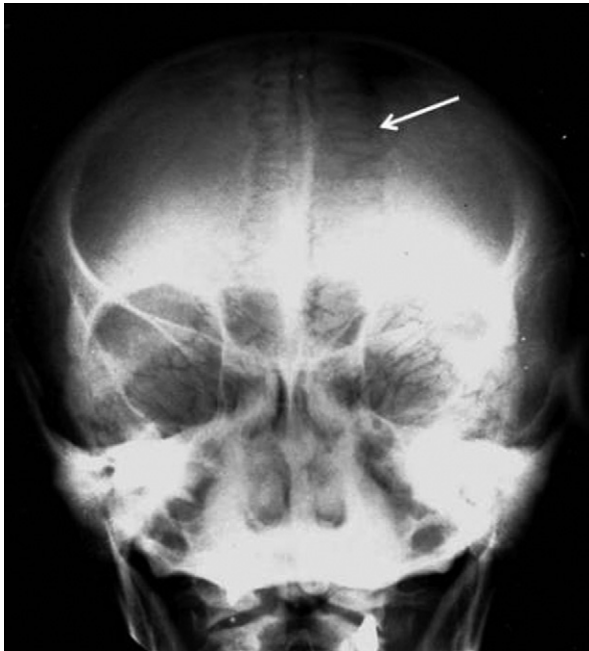

Fig. 5. Skull radiograph showing very marked persistence of Wormian bones in the cranial sutures (arrow).

hypoplastic or absent; these anomalies are usually bilateral but not symmetric. Other skeletal abnormalities include a wide pubic symphysis, dysplastic scapulae, coxa vara, and a variety of vertebral anomalies. These changes are variable and frequently clinically insignificant.

Hyperdontia in CCD

Hyperdontia is the major dental feature of CCD²⁷ (Fig. 6). This developmental abnormality can involve either, or both the primary and secondary dentition. In CCD, hyperdontia leads to dental impaction, overcrowding, and malocclusion, while midfacial hypoplasia can exacerbate these problems.

Articulation and mastication may be compromised, and the cosmetic appearance of the dentition may be unsightly. Excess teeth may be normal or misshapen and situated in front, behind, or within the normal upper and lower rows of teeth. The supernumerary teeth may be arranged uniformly as a double row or placed chaotically on the jaws. If they occur between the maxillary incisors, they are termed mesiodens; these represent between 45% and 68% of all supernumerary teeth. Isolated supernumerary teeth in the zygomatic regions are termed “premolar teeth.” Morphologically, these teeth may be fully formed, bifid, or represented by small tuberosities on the maxillary alveolar ridges.

Embryologically, hyperdontia is the consequence of hyperactivity of the fetal dental lumina, which leads to

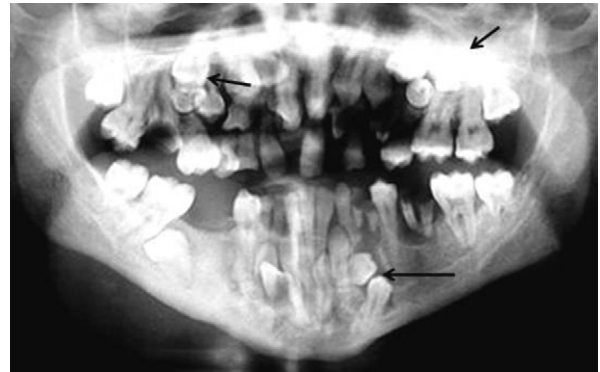


Fig. 6. Hyperdontia: pantamogram of an affected male showing multiple supernumerary teeth (arrows).

the formation of additional tooth germs. Histologically, the cementum layer of the roots of the unerupted teeth is absent.^{28,29} Paramolar or bifid teeth result from division of the tooth germs and represent a form of hyperdontia that differs from that present in CCD.

Other dental abnormalities in CCD

In addition to hyperdontia, other dental abnormalities in CCD include delayed eruption and retention of the primary and secondary dentition.^{23,26,30} The crowns of the teeth sometimes appear abnormal, the enamel may be hypoplastic, and dentigerous cysts and taurodontia are frequent findings.³¹ In the younger age group, spacing of the lower incisors, supernumerary tooth buds, and parallel-sided rami are consistent manifestations. Radiographic manifestations in children include rounded gonion angles, kyphotic sphenoid bones, and Wormian bones in the cranial sutures.²⁶

DIFFERENTIAL DIAGNOSIS OF CLEIDOCRANIAL DYSPLASIA AND HYPERDONTIA

As CCD is an autosomal dominant trait, recognition of occurrence of the disorder in family members is important in the diagnostic process. The presence of clavicular hypoplasia is strongly suggestive of CCD, but this anomaly can also occur as an isolated nonsyndromic entity, which is usually unilateral. Complete absence of both clavicles is a manifestation of the Yunis-Varon syndrome (OMIM 216340). In this rare genetic disorder, intellectual dysfunction and anomalies of the hands and feet are associated with malformations in other systems.³²

Defective cranial ossification leading to patency of the anterior fontanelle and Wormian bones in the sutures is an important feature of CCD. Similar manifestations occur in osteogenesis imperfecta (frequent fractures), pycnodysostosis (skeletal density),

and congenital hypothyroidism (disturbed thyroid metabolism).

Hyperdontia is frequently the presenting feature in CCD, and awareness of this diagnostic possibility is important in dental practice. Apart from CCD, supernumerary teeth may be sporadic or familial.³³ The familial form is inherited as an isolated autosomal dominant trait, with reduced penetrance and variable phenotypic expression. Hyperdontia may also be a component of specific genetic syndromes, including the Gardner syndrome (OMIM 175100) (familial polyposis of the colon and osteomata), Hallerman-Streiff syndrome (OMIM 234100) (narrow face, hypotrichosis, microphthalmia), and the orofaciogigital syndrome type I (OMIM 311200). In these conditions, the hyperdontia is overshadowed by other nondental syndromic manifestations that can have a significant impact on normal development and health. In these circumstances, diagnostic precision facilitates appropriate medical management and meaningful genetic counseling. Equally, in special demographic circumstances, such as the high frequency of CCD in Cape Town, the presence of hyperdontia raises a strong possibility that the affected person has CCD.

GENETIC BACKGROUND OF ORAL MANIFESTATIONS IN CCD

Although CCD is comparatively uncommon, it has a wide geographic distribution. This situation can be explained by the benign nature of the disorder and the ongoing random occurrence of new mutations in the determinant gene. In this scenario, there is little biological pressure against autosomal dominant transmission from generation to generation and a chance mutation or a founder effect can be perpetuated in a particular population. This situation is exemplified by the large extended CCD family in Cape Town, in which numerous persons are affected.³

The molecular defect in CCD is situated at the chromosomal locus of 6p21¹⁶ and the causative gene in the South African family is located at this site.²¹ The determinant gene, *RUNX2* codes for a core-binding transcription factor protein (CBFA1), which is involved in the differentiation of osteoblasts and bone formation.^{1,17,18} *RUNX2* plays an important role in the epithelial-mesenchymal interactions that control progressive tooth morphogenesis and histodifferentiation of the epithelial enamel organ.

The supernumerary teeth in CCD may result from the lack of inhibition or incomplete resorption of tooth bud formation. Supernumerary teeth may also result from the presence of remnants of dental laminae following dental extraction. These epithelial cell rests are usually resorbed during the normal tooth morphogenesis.³⁴

Experimental studies have revealed that mice lacking the *RUNX2* gene fail to develop bone and tooth structure, whereas mice with mutant *RUNX2* genes show arrested tooth development.³⁵ The most common site of *RUNX2* gene expression during odontogenesis is the papillary mesenchyme; levels are highest before the development of the tooth crown but taper after completion of crown formation.³⁶ In mice, the *RUNX2* gene is also expressed in the mesenchyme of the dental follicle and periodontal ligament before tooth eruption. A lack of both alleles of the *RUNX2* gene results in absence of osteoblastic differentiation, whereas haploinsufficiency of *RUNX2* in mice impairs the differentiation and recruitment of osteoclasts together with reduction in the capacity of periodontal ligament cells to induce active osteoclastic differentiation. These processes could, in part, account for delayed tooth eruption patterns in humans with CCD.³⁷⁻³⁹

Bone is formed by 2 processes, namely, endochondral and intramembranous osteogenesis, both of which require the presence of the *RUNX2* protein. The formation and development of both the cranium and clavicles occur by intramembranous ossification. Although the clavicles are the first embryonic bones to ossify, the maturation process is slow. In mice, clavicular defects result from the disruption of intramembranous bone formation during embryogenesis. Low levels of functional *RUNX2* protein are implicated as the causative agent. Although this process begins during early embryonic development, the effects are evident in adult mice. The mouse model offers a reasonable explanation of the clavicle and cranial abnormalities occurring in CCD in humans. It also suggests that the levels of normal *RUNX2* proteins are critical for the successful intramembranous ossification during embryogenesis.

There is considerable intragenic heterogeneity in CCD, and numerous different mutations have been identified within the *RUNX2* gene.^{40,41} Evidence has been advanced for genotype-phenotype correlation,⁴² including dental abnormalities.⁴³ In a series of 24 Japanese persons with CCD, it was found that small stature and the number of supernumerary teeth were positively correlated.⁴⁴ Disparity in hyperdontia in affected siblings has been documented.⁴⁵ In a further study of affected persons in Japan, mutational analysis revealed that a wide range of supernumerary teeth can occur in the presence of identical *RUNX2* mutations.⁴⁶ These authors suggested that hyperdontia in CCD might be regulated by environmental influences, together with epigenetic factors and copy number variation.

Table I. Cleidocranial dysplasia: orodental anomalies and management options

<i>Anomaly</i>	<i>Management option</i>	<i>Rationale</i>	<i>Reference</i>
Retained deciduous teeth	Removal	Assist eruption of permanent teeth	49,50,51,64
Supernumerary teeth	Removal	Assist eruption of permanent teeth	49,50,51,56,64
Permanent teeth abnormalities	Removal	Construction of removable full/partial dentures (not indicated in childhood)	54,58,60,61,64,66
	Retention	Abutments for fixed appliances (not indicated in childhood)	63,65
Unerupted teeth	Surgical exposure	Support for overdenture	50,51,55
	Orthodontic eruption	Function and esthetics and alignment	47,48, 51,52
	Implants	Support overdenture	53,64
		Guide impacted teeth into occlusion	51,59,62
	Surgical translocation and/or autotransplantation	Function and esthetics	47,48,52,57,62
Malocclusion	Fixed or removable orthodontic appliances	Function and esthetics	47,49,58
Palatal vault narrow-high arched	Expansion with removable orthopedic appliance	Reduce crowding	64

DENTAL MANAGEMENT IN CCD

The options for dental management of craniofacial abnormalities in CCD are summarized in Table I.

The aim of dental management in CCD is to achieve an optimal functional and cosmetic result by early adulthood.⁴⁷ A multidisciplinary approach is necessary. Depending on the type and severity of anomalies present, a team of maxillofacial surgeons, orthodontists, and prosthodontists may be needed to develop an individualized treatment protocol. Careful planning of all stages is essential and commitment from the team is vital, as the treatment may continue over a long period. The commitment of the patient to the treatment plan is also crucial, as serial extractions of impacted and supernumerary teeth may be necessary.

Correction of malocclusion may involve surgical repositioning of teeth and the provision of dental prostheses.⁶⁷ Surgical procedures are usually uneventful in CCD but atlanto-axial subluxation with consequent damage to the spinal cord has been documented.⁶⁸ This potential hazard during anesthesia warrants preoperative assessment of the status of the odontoid process by radiological or other appropriate imaging techniques and careful control of the neck movements during operative procedures. Finally, because of the long duration of some dental procedures, speech therapy is sometimes required.⁴⁸ In light of the foregoing, the dental management of persons with CCD can involve long-term care.

The dental management of CCD has undergone a metamorphosis from a “wait and observe” approach to more sophisticated and costly methods combining orthodontics and surgery.^{48,69-72}

The planning of dental treatment goals in CCD varies from individual to individual and primarily depends on the needs of the patient, the age at diagnosis, and social and economic circumstances. Nevertheless, the main objectives remain the restoration of craniofacial and

dental function together with esthetics.⁴⁹ Although there are numerous options, there is a general consensus that the best results are obtained if the condition is diagnosed and treated at an early age.

The most popular orthodontic-surgical regimes are the Toronto-Melbourne, Belfast-Hamburg, and Jerusalem approaches (Table II). The Toronto-Melbourne approach is based on timed, serial extraction of deciduous teeth and depends on the extent to which the roots of the permanent teeth have developed. During each procedure, which is performed under general anesthesia, supernumerary teeth are also removed together with the bone covering the underlying permanent teeth. The rationale is to facilitate the spontaneous eruption of the unerupted permanent teeth.^{69,70}

The Belfast-Hamburg approach advocates a single surgical procedure under general anesthesia to extract all retained deciduous and supernumerary teeth. In addition, all unerupted permanent teeth are exposed and the surgical sites are allowed to heal. After healing is complete, orthodontic appliances are placed on fully erupted teeth with traction bands attached to partially erupted teeth so as to promote further eruption of the latter.^{50,73} The advantage of this procedure is that the patient is exposed to only a single surgical operation under general anesthesia.

The Jerusalem approach is based on at least 2 surgical interventions, the timing of which is dependent on the root development of the permanent dentition. During the first procedure, the anterior deciduous teeth and supernumerary teeth are extracted and the permanent anterior teeth are exposed. At the same time, orthodontic brackets and traction elastics are applied and surgical flaps are closed. During the second component of the Jerusalem approach, which takes place at approximately 13 years of age, the residual primary teeth are extracted, unerupted canines and premolars are exposed, and the necessary orthodontic and surgical processes are completed.

Table II. Cleidocranial dysplasia: management approaches

<i>Approach</i>	<i>Procedure</i>	<i>Reference</i>
Toronto-Melbourne		69,70
Several procedures		
Age: 5-6	Anterior primary teeth are extracted	
Age: 6-7	Primary incisors are exposed and healing is allowed Orthodontic brackets are placed on permanent incisors	
Age: 9-10	Posterior primary teeth are extracted Permanent bicuspid teeth are exposed	
Age: 9-12	Surgical removal of supernumerary teeth and healing allowed Placement of orthodontic brackets on permanent canines and bicuspid teeth	
Jerusalem		47,48
Age: 10-12	Phase 1: Anterior primary teeth are extracted All supernumerary teeth are extracted Permanent incisors are exposed Orthodontic attachments are placed on permanent incisors Surgical flaps are closed completely	
Age: 13 and older	Phase 2: Posterior primary teeth are extracted Unerupted permanent canines and premolars are exposed Orthodontic attachments are bonded Surgical flaps are closed completely	
Belfast-Hamburg		73,74
Single procedure	All primary and supernumerary teeth are removed All impacted teeth are surgically exposed	
Age: not specified	Surgical packs are placed to prevent healing of bone and soft tissue over teeth Healing by secondary intention Orthodontic attachments are placed Orthodontic appliances placed on fully erupted teeth Elastic thread is placed between brackets on unerupted teeth and the arch wires	
Bronx		74
Two at most 3 Procedures	Phase 1: All primary and supernumerary teeth are removed Surgical flaps are closed	
Age: not specified	Phase 2: Unerupted permanent teeth are exposed Orthodontic brackets are placed Surgical flaps are closed and overdenture is placed Conventional orthodontic appliances are placed	
	Phase 3: Leforte osteotomy-orthognathic surgery Dental implants are placed	

The Bronx approach uses 2, and at most 3, surgical interventions.⁵⁸ As in the Toronto-Melbourne and Jerusalem techniques, deciduous teeth and underlying supernumerary teeth are removed under general anesthesia and surgical flaps are closed. Unlike the previously documented techniques, this approach uses the placement of a removable partial overdenture for esthetic and functional purposes. As with the Toronto-Melbourne and Jerusalem techniques, the age at which the management commences depends on the stage of root development of the underlying permanent teeth. If necessary, an intermediate operation is undertaken so as to expose unerupted teeth and place orthodontic brackets over fully erupted molars. A transpalatal arch appliance is welded to the brackets and these are used in conjunction as a base for an artificial dentition. After the natural eruption of the permanent teeth with suffi-

cient posterior support, orthodontic appliances are used to bring the teeth into occlusion. Finally, a Leforte I osteotomy-orthognathic procedure is performed and dental implants are placed.

These procedures are all undertaken over a long period. It is relevant that patient compliance is essential to a favorable outcome for any of these modalities. In addition, they each have individual benefits and shortcomings.

In South Africa, the dental and orthodontic approach to CCD has several constraints. Extensive medical expertise is available, but access is limited and costly. Initially, most persons with dental problems visit primary health care facilities, which are often understaffed and overcrowded. Medical and dental professionals at these institutions may not have adequate experience to diagnose conditions such as CCD. Once diagnosed,

however, patients are referred to specialized facilities that are located in the major cities and often overbooked, making early intervention challenging. Surgical, orthodontic, and prosthodontic procedures are expensive and, when presented with any of the management strategies and the projected cost of treatment, many patients decide not to proceed. In these instances, alternative, more cost-effective strategies can be offered to the patient with CCD. These options may include removal of non-functional deciduous teeth, erupted supernumerary teeth that are not in occlusion, or teeth that may eventually cause complications. Edentulous areas can be managed with removable prostheses. Dentures could be adjusted and/or replaced as the individual grows or as supernumerary teeth erupt.

The high prevalence of substance abuse in the general population of South Africa, including individuals affected with CCD, has an influence on dental management at different levels. For example, a young male patient with classic features of CCD was recently referred to the Faculty of Dentistry, University of Western Cape, for dental management. In addition to the orofacial manifestations of CCD, he also had poor oral hygiene and multiple carious teeth. He was initially regarded as having mild intellectual disability but on further clinical investigation, it emerged that he was a regular user of methamphetamine (or “tik” as it is termed in South Africa). Individuals who are regular users frequently have defective oral hygiene and multiple carious teeth. His poor oral health status and diminished mental capacity was probably a reflection of drug abuse and poor socioeconomic status. After extensive dental management planning, the young man avoided further treatment. This situation often arises in South Africa and compounds difficulties in the management of complicated orofacial disorders. In addition to poverty, lack of education, and drug abuse, HIV infection is another negative factor. Moreover, the cost of private dental treatment is unaffordable by the average person. These problems reflect the situation in other developing countries, and in these circumstances, it is evident that the provision of sophisticated facilities needs to be balanced against the dental needs of the general population.

We are grateful to Greta for her efficient preparation and processing of the manuscript.

REFERENCES

- Mundlos S. Cleidocranial dysplasia: clinical and molecular genetics. *J Med Genet* 1999;36:177-82.
- Cooper SC, Flaitz CM, Johnston DA, Lee B, Hecht JT. A natural history of cleidocranial dysplasia. *Am J Med Genet* 2001; 104:1-6.
- Jackson WP. Osteo-dental dysplasia (cleido-cranial dysostosis): the “Arnold head”. *Acta Med Scand* 1951;139:292-303.
- Greig DM. A neanderthaloid skull presenting features of cleidocranial dysostosis and other peculiarities. *Edinb Med J* 1933;40:497-557.
- Bartsocas CS. Cleidocranial dysostosis in Homer. *Archeia Ellin Pediátr Etair* 1973;36:107.
- Bartsocas CS. Stature of Greeks of the Pylos area during the second millennium BC. *Hippocrates (Athens)* 1977;2:157.
- Paultauf R. Demonstration eines Skelettes von ein Falle von dysostosis cleidocranialis. *Verh Dtsch Pathol Ges* 1912:337-53.
- Beighton P, Sujansky E, Patzak B, Portele KA. Genetic skeletal dysplasias in the Museum of Pathological Anatomy, Vienna. *Am J Med Genet* 1993;47:843-7.
- Meckel JF. Cited by Siggers CD. Cleidocranial dysostosis. *Dev Med Child Neurol* 1975;17:522-4.
- Martin. Sur déplacement de la clavicule. *J Med Chir Pharmacol* 1765;23:456-460. Cited by Gorlin RJ, Cohen MM, Hennekam RCM. *Syndromes of the head and neck*. Oxford, UK: Oxford University Press, 2001. p. 310.
- Scheuthauer G. Kombination rudimentärer Schlüsselbeine mit Anomalien des Schädels beim Erwachsenen Menschen. *Allg Wein Med Ztg* 1871;16:293-295.
- Marie P, Sainton P. Observation d’hydrocéphalie héréditaire (père et fils) par vice de développement du crane et du cerveau. *Bull Soc Med Hop Paris* 1897;14:706-12.
- Marie P, Sainton P. On hereditary cleidocranial dysostosis. *Rev Neurol* 1898;6:835.
- Hultkranz JW. Über dysostosis cleidocranialis. *Z Morphol Anthropol* 1908;11:385-528.
- Jensen BL. Somatic development in cleidocranial dysplasia. *Am J Med Genet* 1990;35:69-74.
- Mundlos S, Mulliken JB, Abramson DL, Warman ML, Knoll JH, Olsen BR. Genetic mapping of cleidocranial dysplasia and evidence of a microdeletion. *Dental abnormalities in cleidocranial dysplasia in one family*. *Hum Mol Genet* 1995;4:71-5.
- Mundlos S, Otto F, Mundlos C, Mulliken JB, Aylsworth AS, Albright S, et al. Mutations involving the transcription factor CBFA1 cause cleidocranial dysplasia. *Cell* 1997;89:773-9.
- Li Y, Pan W, Xu W, He N, Chen X, Liu H, et al. RUNX2 mutations in Chinese patients with cleidocranial dysplasia. *Mutagenesis* 2009;24:425-31.
- Staz J. Proceedings of the 21st International Congress of the SA. Division of IADR – Abstract. *J Dent Res* 1987;67:778.
- Staz J. Cleidocranial dysplasia in the south western Cape: preliminary report. *J Dent Assoc S Afr* 1988;43:547-51.
- Ramesar RS, Greenberg J, Martin R, Goliath R, Bardien S, Mundlos S, Beighton P. Mapping of the gene for cleidocranial dysplasia in the historical Cape Town (Arnold) kindred and evidence for locus homogeneity. *J Med Genet* 1996;33:511-4.
- Dawjee SM, Nkhumeleni F. Cleidocranial dysplasia—a case report. *SADJ* 2002;57:187-90.
- Brooks JK, Nikitakis NG. Multiple unerupted teeth. *Cleidocranial dysplasia*. *Gen Dent* 2008;56:395-6.
- Garg RK, Agrawal P. Clinical spectrum of cleidocranial dysplasia: a case report. *Cases J* 2008;1:377.
- Segal N, Puterman M. Cleidocranial dysplasia—review with an emphasis on otological and audiological manifestations. *Int J Pediatr Otorhinolaryngol* 2007;71:523-6.
- Golan I, Baumert U, Hrala BP, Müssig D. Early craniofacial signs of cleidocranial dysplasia. *Int J Paediatr Dent* 2004; 14:49-53.
- Gorlin RJ, Cohen MM Jr, Hennekam RCM. *Syndromes of the head and neck*. 4th ed. Oxford, UK: Oxford University Press; 2001. p. 306-10.

28. Rushton MA. An anomaly of cementum in cleidocranial dysostosis. *Br Dent J* 1956;100:81-3.
29. Manjunath K, Kavitha B, Saraswathi TR, Sivapathasundharam B, Manikandhan R. Cementum analysis in cleidocranial dysostosis. *Indian J Dent Res* 2008;19:253-6.
30. Golan I, Baumert U, Hrala BP, Müssig D. Dentomaxillofacial variability of cleidocranial dysplasia: clinicoradiological presentation and systematic review. *Dentomaxillofac Radiol* 2003;32:347-54.
31. McNamara CM, O'Riordan BC, Blake M, Sandy JR. Cleidocranial dysplasia: radiological appearances on dental panoramic radiography. *Dentomaxillofac Radiol* 1999;28:89-97.
32. Corona-Rivera JR, Romo-Huerta CO, López-Marure E, Ramos FJ, Estrada-Padilla SA, Zepeda-Romero LC. New ocular findings in two sisters with Yunis-Varon syndrome and literature review. *Eur J Med Genet* 2011;54:76-81.
33. Díaz A, Orozco J, Fonseca M. Multiple hyperodontia: report of a case with 17 supernumerary teeth with nonsyndromic association. *Med Oral Patol Oral Cir Bucal* 2009;14:E229-231.
34. Lukinmaa PL, Jensen BL, Thesleff I, Andreasen JO, Kreiborg S. Histological observations of teeth and peridental tissues in cleidocranial dysplasia imply increased activity of odontogenic epithelium and abnormal bone remodeling. *J Craniofac Genet Dev Biol* 1995;15:212-21.
35. Åberg T, Cavender A, Gaikwad JS, Bronckers AL, Wang X, Waltimo-Sirén J, Thesleff I, et al. Phenotypic changes in dentition of RUNX2 homozygote-null mutant mice. *J Histochem Cytochem* 2004;52:131-9.
36. D'Souza RN, Åberg T, Gaikwad J, Cavender A, Owen M, Karsenty G, Thesleff I. Cbfa1 is required for epithelial-mesenchymal interactions regulating tooth development in mice. *Development* 1999;126:2911-20.
37. Kreiborg S, Jensen BL, Larsen P, Schleidt DT, Darvann T. Anomalies of craniofacial skeleton and teeth in cleidocranial dysplasia. *J Craniofac Genet Dev Biol* 1999;19:75-9.
38. Yoda S, Suda N, Kitahara Y, Komori T, Ohyama K. Delayed tooth eruption and suppressed osteoclast number in the eruption pathway of heterozygous RUNX2/Cbfa1 knockout mice. *Arch Oral Biol* 2004;49:35-42.
39. Lossdörfer S, Abou Jamra B, Rath-Deschner B, Götz W, Abou Jamra R, Braumann B, Jäger A. The role of periodontal ligament cells in delayed tooth eruption in patients with cleidocranial dysostosis. *J Orofac Orthop*. 2009;70:495-510.
40. Zhang CY, Zheng SG, Wang YX, Zhu JX, Zhu X, Zhao YM, Ge LH. Novel RUNX2 mutations in Chinese individuals with cleidocranial dysplasia. *J Dent Res* 2009;88:861-6.
41. Ryoo HM, Kang HY, Lee SK, Lee KE, Kim JW. RUNX2 mutations in cleidocranial dysplasia patients. *Oral Dis* 2009;16:55-60.
42. Zhou G, Chen Y, Zhou L, Thirunavukkarasu K, Hecht J, Chitayat D, et al. CBFA1 mutation analysis and functional correlation with phenotypic variability in cleidocranial dysplasia. *Hum Mol Genet* 1999;8:2311-6.
43. Quack I, Vonderstrass B, Stock M, Aylsworth AS, Becker A, Brueton L, et al. Mutation analysis of core binding factor A1 in patients with cleidocranial dysplasia. *Am J Hum Genet* 1999;65:1268-78.
44. Yoshida T, Kanegane H, Osato M, Yanagida M, Miyawaki T, Ito Y, Shigesada K. Functional analysis of RUNX2 mutations in Japanese patients with cleidocranial dysplasia demonstrates novel genotype-phenotype correlations. *Am J Hum Genet* 2002;71:724-38.
45. Suda N, Hamada T, Hattori M, Torii C, Kosaki K, Moriyama K. Diversity of supernumerary tooth formation in siblings with cleidocranial dysplasia having identical mutation in RUNX2: possible involvement of non-genetic or epigenetic regulation. *Orthod Craniofac Res* 2007;10:222-5.
46. Suda N, Hattori M, Kosaki K, Banshodani A, Kozai K, Tanimoto K, Moriyama K. Correlation between genotype and supernumerary tooth formation in cleidocranial dysplasia. *Orthod Craniofac Res* 2010;13:197-202.
47. Becker A, Lustman J, Shteyer A. Cleidocranial dysplasia: part 1—General principles of the orthodontic and surgical treatment modality. *Am J Orthod Dentofacial Orthop* 1997;111:28-33.
48. Becker A, Shteyer A, Bimstein E, Lustmann J. Cleidocranial dysplasia: part 2—treatment protocol for the orthodontic and surgical modality. *Am J Orthod Dentofacial Orthop* 1997;111:178-83.
49. D'Alessandro G, Tagariello T, Piana G. Craniofacial changes and treatment of the stomatognathic system in subjects with cleidocranial dysplasia. *Eur J Paediatr Dent* 2010;11:39-43.
50. Richardson A, Swinson T. Combined orthodontic and surgical approach to cleidocranial dysostosis. *Trans Eur Orthod Soc* 1987;63:23.
51. Angle AD, Rebellato J. Dental team management for a patient with cleidocranial dysostosis. *Am J Orthod Dentofacial Orthop* 2005;128:110-1.
52. Becker A. Cleidocranial dysplasia. In: Becker A, editor. *The orthodontic treatment of impacted teeth*. St Louis: Mosby; 1998. p. 199-229.
53. Becktor KB, Becktor JP, Keller EE. Growth analysis of a patient with ectodermal dysplasia treated with endosseous implants: a case report. *Int J Oral Maxillofac Implants* 2001;16:864-74.
54. Fardy MJ. Cleidocranial dysostosis: some problems in the dental management of occlusion. *Dent Update* 1984;11:363-8.
55. Hitchin AD, Fairley JM. Dental management in cleido-cranial dysostosis. *Br J Oral Surg* 1974;12:46-55.
56. Hemalatha R, Balasubramaniam MR. Cleidocranial dysplasia: a case report. *J Indian Soc Pedod Prevent Dent*. 2008;26:40-43.
57. Jensen BL, Kreiborg S. Dental treatment strategies in cleidocranial dysplasia. *Br Dent J* 1992;172:243-7.
58. Kelly E, Nakamoto RY. Cleidocranial dysostosis—a prosthodontic problem. *J Prosthet Dent* 1974;31:518-26.
59. Lombardas P, Toothaker RW. Bone grafting and osseointegrated implants in the treatment of cleidocranial dysplasia. *Compend Contin Educ Dent* 1997;18:509-14.
60. Magnus WW, Sands NR. Cleidocranial dysostosis—report of a case. *Am J Orthod* 1974;65:638-43.
61. Maw RB. Cleidocranial dysostosis: report of case. *J Am Dent Assoc* 1978;96:306-9.
62. Nordenram A. Autotransplantation of teeth in cleidocranial dysostosis. *Odontol Revy* 1971;22:363-70.
63. Pröbster L, Bachmann R, Weber H. Custom-made resin-bonded attachments supporting a removable partial denture using the spark erosion technique: a case report. *Quintessence Int* 1991;22:349-54.
64. Suba Z, Balaton G, Gyulai-Gaal S, Balaton P, Barabas J, Tarjan I. Cleidocranial dysplasia: diagnostic criteria and combined treatment. *J Craniofac Surg* 2005;6:1122-6.
65. Trimble LD, West RA, McNeill RW. Cleidocranial dysplasia: comprehensive treatment of the dentofacial abnormalities. *J Am Dent Assoc* 1982;105:661-6.
66. Winter GR. Dental conditions in cleidocranial dysostosis. *Am J Orthod* 1943;29:61-89.
67. Kuroda S, Yanagita T, Kyung HM, Takano-Yamamoto T. Titanium screw anchorage for traction of many impacted teeth in a patient with cleidocranial dysplasia. *Am J Orthod Dentofacial Orthop* 2007;131:666-9.
68. Kobayashi S, Uchida K, Baba H, Takeno K, Yayama T, Nakajima H, et al. Atlantoaxial subluxation-induced myelopathy in

- cleidocranial dysplasia. Case report. *J Neurosurg Spine* 2007; 7:243-247.
69. Smylski PT, Woodside DG, Harnett BE. Surgical and orthodontic treatment of cleidocranial dysostosis. *Int J Oral Surg* 1974;3:380-85.
70. Hall RK, Hyland AL. Combined surgical and orthodontic management of the oral abnormalities in children with cleidocranial dysplasia. *Int J Oral Surg* 1978;7:267-73.
71. Daskalogiannakis J, Piedade L, Lindholm TC, Sándor GK, Carmichael RP. Cleidocranial dysplasia: 2 generations of management. *J Can Dent Assoc* 2006;72:337-42.
72. Farronato G, Maspero C, Farronato D, Gioventù S. Orthodontic treatment in a patient with cleidocranial dysostosis. *Angle Orthod* 2009;79:178-85.
73. Behlfelt K. Cleidocranial dysplasia: diagnosis and treatment concept. *Trans Eur Orthod Soc* 1987;63:25.
74. Berg RW, Kurtz KS, Watanabe I, Lambrakos I. Interim prosthetic phase of multidisciplinary management of cleidocranial dysplasia: "the Bronx approach." *J Prosthodont* 2011;20:S20-5.

Reprint requests:

Peter Beighton, MD, PhD, FRCP
Division of Human Genetics
Faculty of Health Sciences University of Cape Town
Observatory 7925
Cape Town, South Africa
peter.beighton@uct.ac.za