CLINICOPATHOLOGIC CONFERENCE

A rapidly growing gingival mass

HyukIl Kwon, BS,[a] Nam Hee Kim, PhD,[b] Yonghoon Cha, DDS, MSD,[b] Hyung Jun Kim, PhD,[c] Ho-Gul Jung, DDS, PhD,[d] Ja Seung Koo, MD, PhD,[e] Jong In Yook, DDS, PhD,[b] and Hyun Sil Kim, DDS, PhD,[b] Gwangju and Seoul, Korea
CHONNAM NATIONAL UNIVERSITY AND YONSEI UNIVERSITY
(Oral Surg Oral Med Oral Pathol Oral Radiol 2013;115:2-8)

CLINICAL PRESENTATION

A 71-year-old Korean woman was referred to the Department of Oral and Maxillofacial Surgery with a 10-day history of a rapidly growing mass occupying the oral cavity, which was associated with pain and spontaneous bleeding. Clinical examination revealed a soft or slightly firm pedunculated mass approximately 4 × 5 × 5 cm in size on the anterior aspect of the lower gingiva. The mass extended to the buccal and lingual vestibule, floor of mouth, and abutted the tongue. The mass was not lobulated and was well vascularized, showed a reddish purple color, and had a smooth, shiny surface with no ulceration. The patient showed neither paresthesia of the lips or chin, nor palpable cervical lymph nodes. Her medical history included controlled hypertension and diabetes mellitus. She had also been diagnosed with asthma and had suffered a cerebrovascular accident, but has completely recovered. There was no history of alcohol intake or smoking.

To trace the etiology of the rapidly growing gingival mass and to evaluate the operability, all the laboratory tests and diagnostic workup were performed after she was admitted. Routine complete blood count and blood chemistry tests were within normal limits. There were no other noticeable findings with coagulation blood tests and the urinalysis.

Dental panoramic radiography demonstrated slight bone destruction with an irregular border, which was confined to the lower anterior alveolar bone. There was neither diffuse basal bone destruction, nor periosteal reaction (Figure 1). To minimize the interval between biopsy and surgical operation, and the possibility of spreading cancer cells during the surgical intervention, the radiological evaluations were performed before the biopsy. On computed tomography (CT) examination, the gingival mass extended anteriorly and displaced the buccinator muscle outward. The mass also extended posteriorly and approximated the tongue (Figure 2, *A* and *B*). Magnetic resonance imaging (MRI) revealed a mass approximately 5 cm in size on the anterior gingiva showing low signal intensity on T1- or T2-weighted images (Figure 3, *A* and *B*). On T1-weighted images with gadolinium (GD) enhancement, however, the mass showed high signal intensity with focal heterogeneity (Figure 3, *C*). The mass eroded alveolar bone and extended to the buccal and lingual vestibule, floor of mouth, and abutted the tongue on sagittal T1 with GD contrast images (Figure 3, *D*). Enlarged cervical lymph nodes were identified on neither CT nor MRI scans (Figures 2 and 3). Based on clinical examination and radiologic imaging, the initial impression was that of a primary well-vascularized soft tissue tumor, such as a malignant vascular tumor, or a metastatic cancer.

Initial biopsy was performed from the lower anterior gingiva by an oral and maxillofacial surgeon. The specimen was sent for histopathological evaluations to an oral pathologist.

DIFFERENTIAL DIAGNOSIS

The gingival tumor presented an admixture of small cells with scant cytoplasm and hyperchromatic round to oval nuclei, and large cells with abundant cytoplasm and peripheral large nuclei (Figure 4, *A*). The tumor was well vascularized, but there was no histologic evidence of malignant vascular tumor. Based on the light microscopic findings, differential diagnosis was

This study was supported by a grant from the National R&D Program for Cancer Control, Ministry for Health, Welfare and Family Affairs, Republic of Korea (1020110), and a grant from the National Research Foundation of Korea (2010-0029703).
[a]2nd stage of Brain Korea 21 for School of Dentistry, Dental Science Research Institute, Chonnam National University, Gwangju, Korea.
[b]Department of Oral Pathology, Oral Cancer Research Institute, Yonsei University College of Dentistry, Seoul, Korea.
[c]Department of Oral and Maxillofacial Surgery, Yonsei University College of Dentistry, Seoul, Korea.
[d]Department of Oral and Maxillofacial Radiology, Yonsei University College of Dentistry, Seoul, Korea.
[e]Department of Pathology, Yonsei University College of Medicine, Seoul, Korea.
Received for publication Mar 17, 2011; returned for revision Oct 31, 2011; accepted for publication Dec 5, 2011.
© 2013 Elsevier Inc. All rights reserved.
2212-4403/$ - see front matter
doi:10.1016/j.oooo.2011.12.006

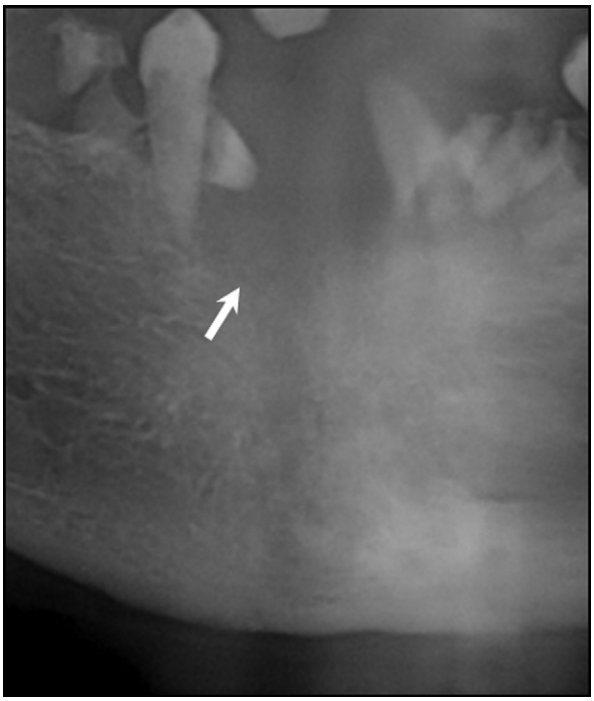

Fig. 1. Panoramic view demonstrates multiple root tips of the teeth and a destructive bone lesion (*arrow*) with an irregular border on the lower anterior alveolar bone. Periosteal reaction is not found.

needed for Ewing sarcoma (ES)/primitive neuroectodermal tumor (PNET), primary Merkel cell carcinoma (MCC), lymphoma, and combined small cell carcinoma (SCLC), which could be metastatic. Among them, ES/PNET was discounted, as it occurs most frequently in teenagers, and the probability of its occurring in our elderly patient was low. Besides, the present lesion showed no "onion skin"–type periosteal reaction in radiologic findings, often associated with ES/PNET.

Primary MCC is a type of neuroendocrine tumor of the head and neck, as is SCLC. Primary MCC, lymphoma, and metastatic SCLC could not be discriminated only by microscopic findings, because they show similar histologic features. Thyroid transcription factor 1 (TTF-1) was used as a helpful marker to verify that the gingival lesion was the primary MCC or metastatic SCLC. Lymphoma could be ruled out simultaneously if the tumor cells could show the positivity for TTF-1.

SCLCs are thought to originate from neuroendocrine cells in the bronchus. Hence, the diagnosis of SCLC is increasingly supported by a variety of neuroendocrine markers, such as chromogranin A, CD57, synaptophysin, neuron-specific enolase, and most recently CD56. Among the neuroendocrine markers, CD56 is widely used because of its high sensitivity compared with other antibodies.[1] For the diagnosis of the present case, CD56 could be used as a significant tool in revealing the neuroendocrine origin of the gingival mass.

Metastatic tumor was suspected initially. The estimation was based on the following clinical evidence. First, the present gingival mass grew extremely rapidly, beyond comparison with the common malignant tumors of oral cavity origin. Second, the jawbone destruction by the tumor was confined to the alveolar bone, which implies that the oral cavity lesion was not a central lesion.

Still some conflict remained: the gingiva is not a frequent site of metastatic tumors. Most metastatic tumors to the oral cavity are to the jawbones. The posterior areas of the mandible are the most frequent sites of cancer metastasis, because they contain hematopoietically active marrow; however, the abundant capillary network of chronically inflamed gingiva can entrap cancer cells, and can also become sites of metastatic cancer.[2] Metastatic tumors to the oral region account for approximately 1.0% to 1.5% of all malignant oral tumors.[3] Moreover, metastatic tumors to the oral mucosa are more rarely reported than those in the jawbones by a ratio of 1.0:2.5.[2] The most common primary sites of metastatic oral cancers are the lungs, breasts, kidneys, bone, and colorectum, respectively. The breasts are the most common primary site for tumors that metastasize to the jawbones, whereas the lungs are the most common source for cancers that metastasize to the oral soft tissues.[2]

The patent merely displayed alveolar bone erosion without mandibular bone marrow infiltration by the tumor. Therefore, we could hypothesize that lung cancer had metastasized to the inflamed gingival tissue first and then infiltrated well-vascularized periodontal ligament spaces; however, our patient showed no symptoms associated with a lung lesion.

Lung cancers are classified according to histologic type. This classification has important implications for clinical management and prognosis of the disease. The histologic subtypes of lung cancer are classified into 2 main categories: SCLC and non–small cell lung carcinoma (NSCLC), which include adenocarcinoma, squamous cell carcinoma, and large cell carcinoma. NSCLCs are usually detected before metastasis or local spread occurs. On the other hand, SCLCs have invariably spread when they are first detected, even if the primary tumor appears small and localized. Our patient showed no previous pulmonary symptoms when the oral cavity tumor was first found, which may support the possibility of the metastatic SCLC.

Taking the clinico-histopathologic evaluation of the patient and epidemiologic references into consideration, the preliminary diagnoses for the initial gingival

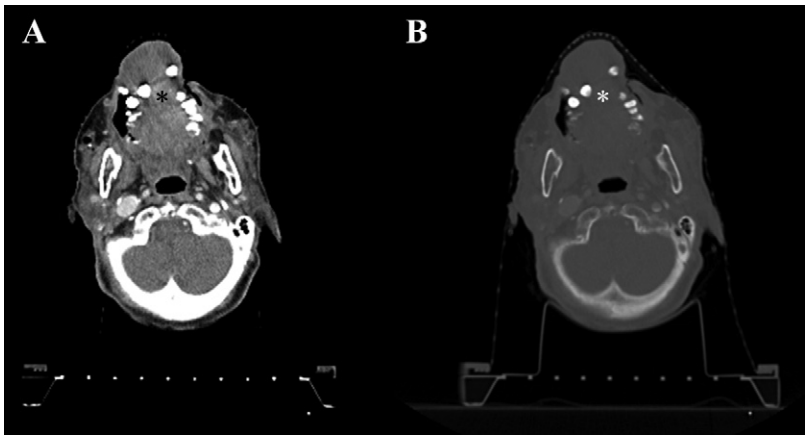

Fig. 2. Computed tomography imaging. **A,** Axial soft tissue window setting. At the level of roots of the lower anterior teeth, axial CT image demonstrates a soft tissue mass (*asterisk*) approximately 4 × 5 × 5 cm on the lower anterior gingiva. **B,** Axial bone window setting. The mass (*asterisk*) causes irregular alveolar bone destruction and extends anterioposteriorly.

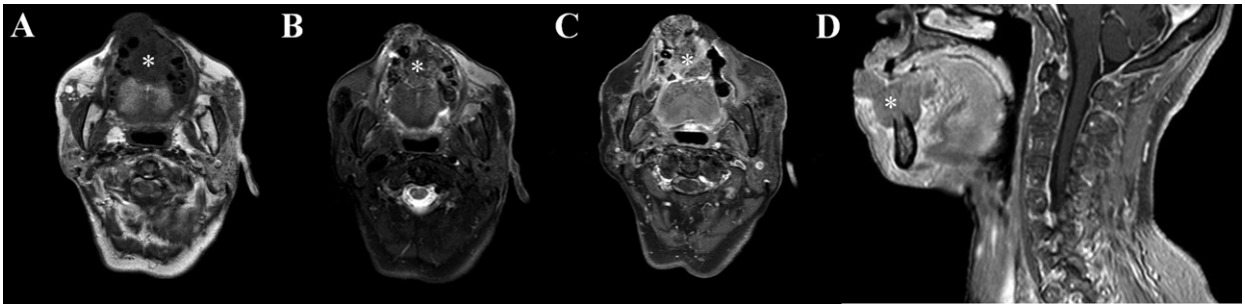

Fig. 3. Magnetic resonance imaging. **A,** Axial T1-weighted image. **B,** Axial T2-weighted image. **C,** Axial T1 with gadolinium (GD) contrast. There is evidence of contrast enhancement of the mass, clearly defining a discrete mass (*asterisk*), which could not be seen distinctly on noncontrast-enhanced T1- or T2-weighted images. **D,** Sagittal T1 with GD contrast images demonstrate that the gingival mass slightly erodes alveolar bone only. The basal bone portion under the alveolus is intact. The tumor extends to the buccal and lingual vestibule, floor of mouth, and abuts the tongue (*asterisk*).

lesions were summarized as primary MCC, lymphoma, and probably metastatic SCLC.

ADDITIONAL INFORMATION AND DIAGNOSIS

To determine whether the oral lesion was primary or metastatic, immunohistochemical staining for the gingival specimen was performed and, simultaneously, positron emission tomography-computed tomography (PET-CT) images for the patent were taken.

For the immunohistochemical staining, the anti-TTF-1 (Dako, M3575, Glostrup, Denmark) and anti-CD56 (Dako, M7304, Glostrup, Denmark) antibodies were used. TTF-1 is exclusively expressed in the epithelium of the lung and thyroid gland; therefore, it can be a highly selective marker for tumors arising in these organs. The gingival tumor cells exhibited focal positivity for TTF-1, confirming their pulmonary origin (Figure 5, *A*). Therefore, lymphoma could be ruled out. The tumor cells also showed strong positivity for CD56, the marker for neuroendocrine differentiation (Figure 6, *A*). Both MCC and metastatic SCLC show the common neuroendocrine differentiation, which could not be discriminated by CD56 immunohistochemistry. The possibility of primary MCC could also be excluded by TTF-1 positivity of the tumor. Despite similar histopathologic features to SCLC, MCC presents the opposite reactivity for TTF-1 immunohistochemistry. Cheuk et al. reported that 82.7% of pulmonary SCLCs were positive for TTF-1, whereas 42% of extrapulmonary SCLCs were positive, but extrapulmonary neuroendocrine tumor of MCC showed negativity for TTF-1 without exception.[3,4]

PET-CT scanning of the whole body revealed not only the oral cavity mass but also an infiltrative mass in the left upper lobe of the lung with contiguous invasion of mediastinal pleura and several seeding nodules. Enlarged lymph nodes with 18-fluorodeoxyglucose uptake were also noted in the left hilar, pretracheal, and axillary fossa, but bilateral cervical lymph nodes were

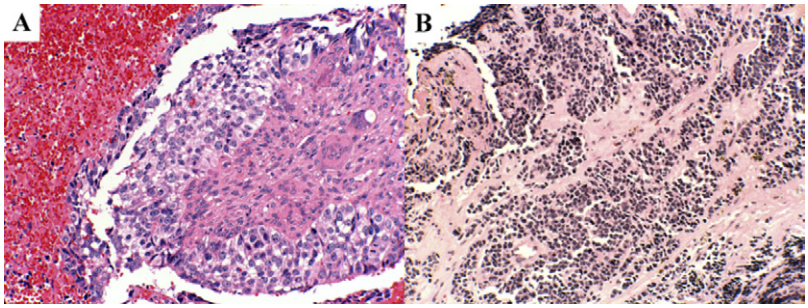

Fig. 4. Histopathologic findings. **A,** The gingival tumor shows an admixture of small cells and large cells with frequent mitoses. **B,** A tumor from the axilla shows nests of small cells (hematoxylin and eosin stain; original magnification ×200).

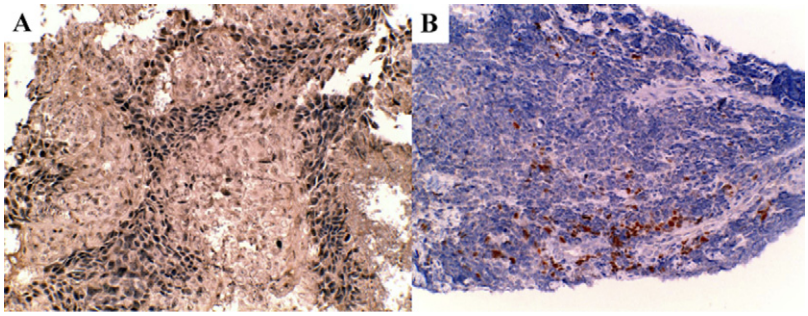

Fig. 5. Immunohistochemical staining with TTF-1. Both the specimen from the gingiva (**A**) and axilla (**B**) show focal positivity within the nuclei of the tumor cells (original magnification ×200).

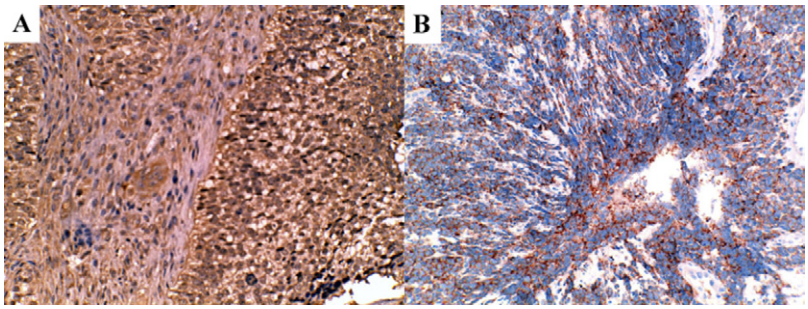

Fig. 6. Immunohistochemical staining with CD56. Both the specimen from the gingiva (**A**) and axilla (**B**) show strong positivity in the membrane of the tumor cells (original magnification ×200).

intact (Figure 7). Both the gingival and lung masses were interpreted as malignant tumors, because they infiltrated adjacent normal tissues. If one was a metastatic lesion from the other distant site, which was the primary? In which direction did the metastasis occur? Metastasis from the lung to the gingiva was more probable than vice versa in the present case, judging from clinical evidence of a lack of metastatic cervical lymph nodes.

Additional biopsy was performed on the left axilla. Based on its anatomic location, the axillary mass was considered a regional lymph node around the lungs, and was radiologically diagnosed as metastatic lung cancer. Therefore, a more dangerous bronchoscopic lung biopsy, in comparison with an axillary lymph node biopsy, was deemed unnecessary. The specimen was obtained through a sonogram-guided gun biopsy by a radiologist and sent for histopathological evaluations to a pathologist.

Histologically, the tumor from the axillary lesion presented typical features of small cell carcinoma. The tumor cells had scant cytoplasm and hyperchromatic round to oval nuclei (Figure 4, *B*). Immunohistochemical staining was performed for the axillary mass and compared with the results of the gingival mass. The same antibodies were used for the immunohistochemical staining. The tumor cells of both locations showed similar expression patterns of TTF-1 and CD56. They

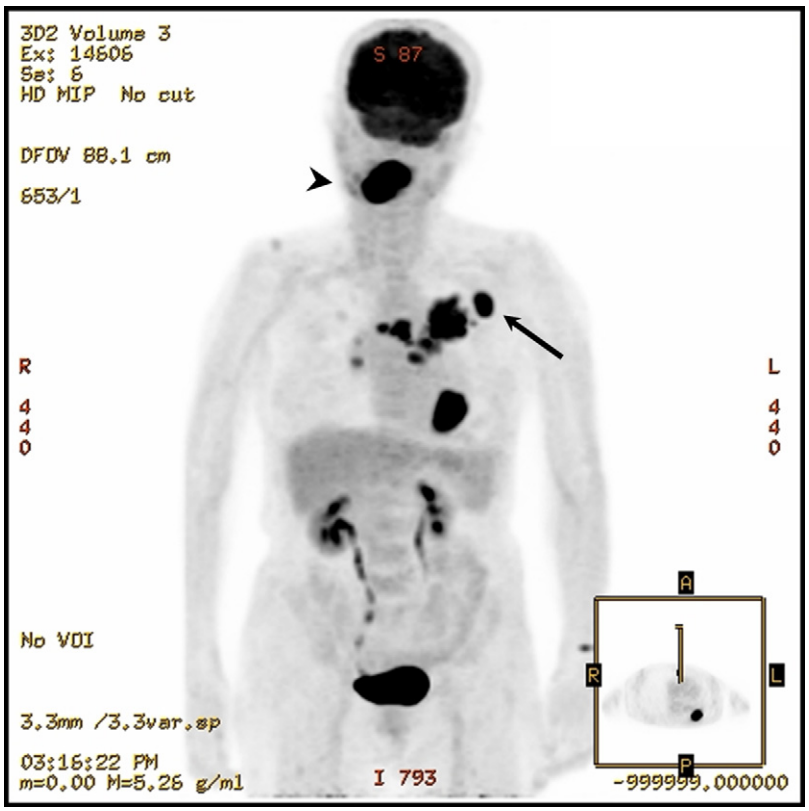

Fig. 7. PET-CT shows a mass in the lungs with several seeding nodules near the left mediastinum, as well as the mass in the oral cavity (*arrowhead*). Enlarged lymph nodes were also noted in hilar, pretracheal, and axillary fossa on the left (*arrow*), but bilateral cervical lymph nodes were intact.

exhibited focal positivity for TTF-1 (Figure 5, *A* and *B*), and a strong positivity for CD56 (Figure 6, *A* and *B*).

Results of immunohistochemical staining with TTF-1 offered the critical evidence to verify whether the gingival and lung masses were synchronous double primary tumors or the gingival and axillary masses were all metastatic lung cancer. Intriguingly, the gingival lesions showed different microscopic features from the axillary lesions. The gingival tumor presented an admixture of small cells and large cells (Figure 6, *A*), with peripheral large nuclei, prominent nucleoli, and abundant cytoplasm with well-defined cell borders. Large cells aggregated in a nodular pattern with interspersed components of small cells, and contained numerous clear cell-like portions. To determine the characterization for the cytoplasmic granules of the large cells observed in the gingival SCLC specimen, Periodic acid-Schiff (PAS) staining was performed. The large clear cells were positive for PAS staining (Figure 8, *A*) and were digested by diastase (Figure 8, *B*). These results revealed that the tumors showing clear cell changes contained abundant glycogen in the cytoplasm.

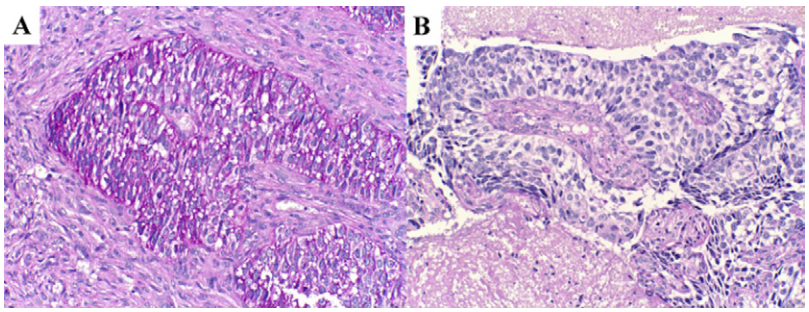

Fig. 8. PAS stain of gingival tumor. The tumor cells of the gingival SCLC shows positivity for PAS staining (**A**), which were digested by diastase (**B**) (original magnification ×200).

Based on the clinico-pathologic analyses, the final pathologic diagnosis for both the axillary and gingival masses was metastatic SCLC. Histopathologically, the axillary mass was composed of small cell carcinoma, and the gingival mass was composed of combined small cell carcinoma.

After the diagnosis was made, the patient refused treatment and passed away about 2 months later.

DISCUSSION

SCLC is a highly malignant neoplasm accounting for approximately 20% to 25% of all bronchial carcinomas and leads to a poor prognosis for patients, with high recurrence and a tendency to develop metastases widely throughout the body at an early stage in its clinical course.[5-7] According to the recent World Health Organization classification, when at least 10% of the tumor bulk of SCLC is made of non–small cell components—large cells, squamous cell carcinoma, or adenocarcinoma—it is defined as combined-SCLC (c-SCLC).[8]

c-SCLC is relatively rare, accounting for 2% to 14% of all cases of SCLC. Barnard[9] first described SCLC as "oat cell carcinoma," because of the flat cell shape and scant cytoplasm. Barnard[9] also described that there is cytologic heterogeneity within SCLC, describing "in all these tumors, cells other than small 'oat' cells could be found." Abeloff et al.[10] reported morphologic and biochemical changes of small cell carcinoma. According to this report, 5 of the 40 patients presented squamous cell carcinoma,[10] adenocarcinoma,[1] and large cell carcinoma,[1] which developed concurrently with or after their diagnosis of SCLC.[11]

An in vitro study showed that SCLC containing a large cell component was less sensitive to radiation therapy and chemotherapy than pure SCLC, and several clinical studies suggested that patients with SCLC containing a large cell component showed a significantly poorer response to treatment and shorter survival time than those with pure SCLC.[12-14] Thus, making an accurate pathologic distinction between pure SCLC and c-SCLC is important for therapeutic implications.

In the present case, because the gingival mass was found before the lung mass, which accompanied no pulmonary symptoms, the diagnosis of metastatic SCLC of the gingiva was more of a challenge for pathologists. Worse still, the 2 biopsy specimens, from the gingival and axilla, showed different histomorphologic features, which made diagnosis even more difficult. To determine the reason for the difference in histomorphologic features between the 2 lesions, 2 hypotheses could be made: the possibility of dual primary cancers or transformation during metastasis. Because the gingival tumor partly contained small cell portions, which were also observed in the axillary mass, the second hypothesis may be more reasonable than the former.

Compared with the axillary tumor mass, the gingival tumor intriguingly contained large clear cells. From the result of PAS stain with digestion of diastase, it was determined that the clear cytoplasm contained carbohydrates, such as glycogen, glycoprotein, and proteoglycans. This excluded adenocarcinoma, which contains mucin, from the differential diagnosis. Recent studies show that glycogen may be used by carcinoma cells as a source for energy because of the limited supply of nutrients and oxygen in a rapidly growing carcinoma.[15] Metastases are complicated processes in which the tumor cells have to detach from the primary tumor, and then must spread in the tissue, invade the lymphovascular system, survive the journey in the circulation, and settle down at the metastatic site. The histomorphologically altered metastatic lesion associated with glycogen accumulation suggests that the tumor underwent the alteration of glucose metabolism during the strained metastatic process.

In summary, metastatic SCLC with different subtypes is extremely rare, although metastases of small cell carcinoma occur frequently throughout the body. The present case shows different histopathological features in the metastatic lesions, which makes diagnosis more difficult. To reveal the primary site, careful clinico-pathologic examinations and proper immunohistochemical studies were required. Although there are no established informed data on the prognosis of c-SCLC associated with metastases, it would likely be poorer than that of common SCLC, according to our case.

REFERENCES

1. Kontogianni K, Nicholson AG, Butcher D, Sheppard MN. CD56: a useful tool for the diagnosis of small cell lung carcinomas on biopsies with extensive crush artefact. J Clin Pathol 2005;58:978-80.
2. Hirshberg A, Shnaiderman-Shapiro A, Kaplan I, Berger R. Metastatic tumours to the oral cavity—pathogenesis and analysis of 673 cases. Oral Oncol 2008;44:743-52.
3. Neville B, Damm D, Allen C, Oral BJ. Oral and maxillofacial pathology. Philadelphia: W. B. Saunders; 2002.
4. Cheuk W, Kwan M, Suster S, Chan J. Immunostaining for thyroid transcription factor 1 and cytokeratin 20 aids the distinction of small cell carcinoma from Merkel cell carcinoma, but not pulmonary from extrapulmonary small cell carcinomas. Arch Pathol Lab Med 2001;125:228-31.
5. Cooper S, Spiro SG. Small cell lung cancer: treatment review. Respirology 2006;11:241-8.
6. Le Pechoux C, Dhermain F, Bretel J, Laplanche A, Dunant A, Tarayre M, et al. Modalities of radiotherapy in small cell lung cancer: thoracic radiotherapy and prophylactic cerebral irradiation. Rev Pneumol Clin 2004;60;3S91.
7. Kumar V, Abbas A, Fausto N. Robbins and Cotran pathologic basis of disease. Philadelphia: Elsevier Saunders; 2005.
8. Travis W, Colby T, Corrin B, Shimosato Y, Brambilla E. World

Health Organization international histological classification of tumors: histological typing of lung and pleural tumors. Berlin: Springer-Verlag; 1999.
9. Barnard W. The nature of the "oat-celled sarcoma" of the mediastinum. J Pathol Bacteriol 1926;29:241-4.
10. Abeloff M, Eggleston J, Mendelsohn G, Ettinger D, Baylin S. Changes in morphologic and biochemical characteristics of small cell carcinoma of the lung: a clinicopathologic study. Am J Med 1979;66(5):757-64.
11. van der Waal RI, Buter J, van der Waal I. Oral metastases: report of 24 cases. Br J Oral Maxillofac Surg 2003;41:3-6.
12. Fushimi H, Kukui M, Morino H, Hosono Y, Fukuoka M, Kusunoki Y, et al. Detection of large cell component in small cell lung carcinoma by combined cytologic and histologic examinations and its clinical implication. Cancer 1992; 70:599-605.
13. Hirsch FR, Osterlind K, Hansen HH. The prognostic significance of histopathologic subtyping of small cell carcinoma of the lung according to the classification of the World Health Organization. A study of 375 consecutive patients. Cancer 1983;52:2144-50.
14. Mangum MD, Greco FA, Hainsworth JD, Hande KR, Johnson DH. Combined small-cell and non-small-cell lung cancer. J Clin Oncol 1989;7:607-12.
15. Kang JG, Park SY, Ji S, Jang I, Park S, Kim HS, et al. O-GlcNAc protein modification in cancer cells increases in response to glucose deprivation through glycogen degradation. J Biol Chem 2009;284:34777-84.

Reprint requests:

Hyun Sil Kim, DDS, PhD
Department of Oral Pathology
Oral Cancer Research Institute
Yonsei University College of Dentistry
250, Seongsanno, Seodaemun-gu
Seoul 120-752, South Korea
khs@yuhs.ac