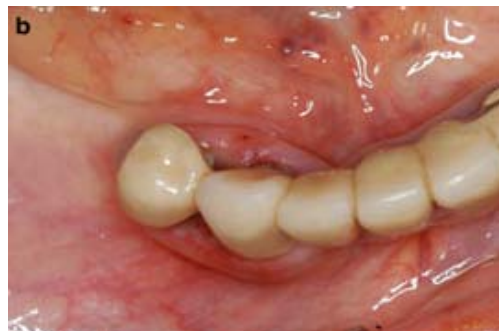
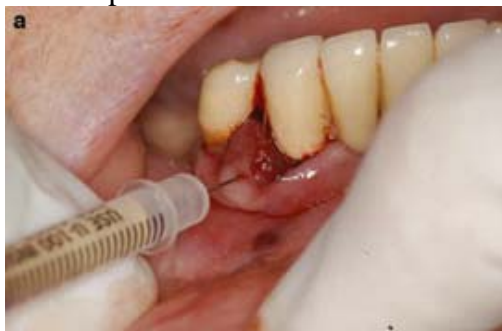
原文題目(出處)：	Oral vascular malformation in a patient with hereditary hemorrhagic telangiectasia: a case report. Spec Care Dentist 2012;32:11-4
原文作者姓名：	Renato Nicolás Hopp, Douglas Cardoso de Siqueira, Marcondes Sena-Filho, Jacks Jorge
通訊作者學校：	Piracicaba Dental School, Sao Paulo, Brazil
報告者姓名(組別)：	梁鋸潔 (Intern A 組)
報告日期：	2012/9/10

內文：

- Hereditary hemorrhagic telangiectasia (HHT), also called **Osler-Weber-Rendu syndrome**, is an inherited mucocutaneous disease produced by **mutation on endoglin and ALK genes**. This disease can present in five types, the most prevalent being type I, produced by mutation on the endoglin gene (9q34.1), and type II, caused by a mutation in activin A Receptor type II-like 1 on chromosome 12 which encodes ALK1 (12q11-q14). Proteins produced by these genes are important for endothelial wall integrity, modulating different cell processes including migration, proliferation, adhesiveness, composition, and organization.
- HHT is characterized by:
 - Telangiectatic lesions of 1 mm to 2 mm located in the oral mucosa, lips, and fingers
 - May have a **family history** of disease
 - Episodes of recurrent spontaneous epistaxis
 - Arteriovenous malformations in the lungs, gastrointestinal tract, liver, brain, and spinal cord

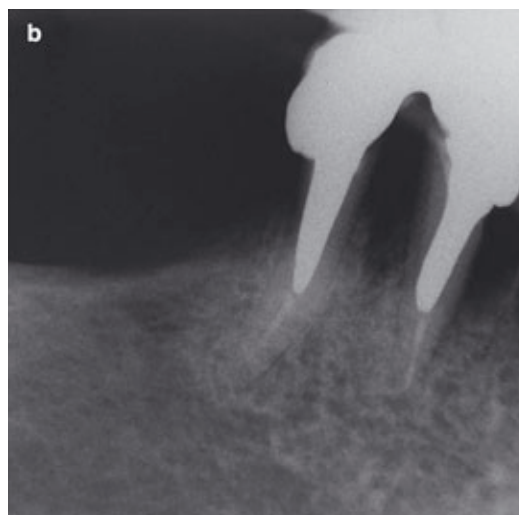
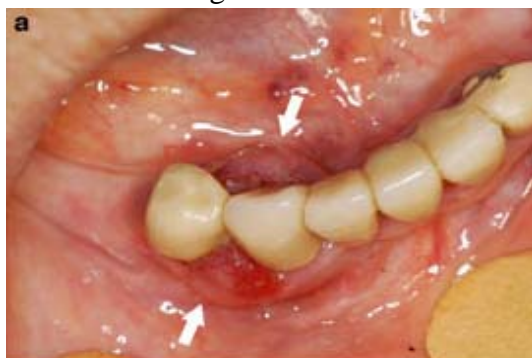Diagnosis of HHT is “definite” if a patient presents three of those characteristics, “suspect” if two are present, and “unlikely” if only one characteristic is present.
- Disease manifestations are caused by vascular abnormalities of arterioles, capillaries, and venules, which have diminished smooth muscle walls and practically **no elastic fibers**. As the lesion develops, blood vessels become dilated and filled with blood, lose contractile function, are more prone to disruption, and have increased risk of hemorrhage.
- Patients may have repeated episodes of nasal bleeding that may lead to anemia.
 - Patients who have HHT may also experience intense bleeding from tooth brushing, a result of the diminished vascular wall thickness associated with inflammation caused by poor oral health and gingival disease.
 - Hemorrhagic ulcers and vesicles on the gingival and oral mucosa may also be present.
- Although the prognosis for HHT is good, patients who are not aware of their condition can have significant morbidity. In such cases, mortality ranges between **1% for patients with epistaxis**, to **10% for patients with cerebral abscesses**.
- Case report:



a. A 64-year-old Caucasian woman presented to the Piracicaba Dental School's Oral Diagnosis Clinic with the chief complaint of a **bleeding gingival lesion** between the **left mandibular canine and first premolar**; the lesion had been treated unsuccessfully with periodontal scaling and antibiotics for about 10 years. She had previously been diagnosed with HHT, but was not under medical follow up for this condition and failed to report this information during the initial visit with the authors. Her medical history included **iron deficiency anemia and recurrent episodes of epistaxis**. The patient reported a history of **hemorrhage after dental extractions**, the last having occurred 1 month before the initial appointment. An extra-oral examination revealed the presence of **telangiectatic lesions on the face, typical of HHT**. The intra-oral examination revealed a red gingival nodule (1.5 cm x 1 cm x 0 cm) between the left mandibular canine and first premolar, involving the buccal and lingual surfaces of the gingival papilla. The lesion caused the patient significant discomfort, as it would bleed when touched, when the patient ate, and while she brushed her teeth. Analysis of the radiographic examination revealed preserved cortical and medullar bone, suggesting a peripheral lesion. The initial differential diagnosis included pyogenic granuloma or a peripheral giant cell lesion. Blood tests were within physiological limits (Blood count 4.22 million/mm³; Leukocytes 5,800/mm³; Bleeding time (Duke) 1 minute; INR 1.23; Prothrombin time 15 seconds).

b. An excisional biopsy was scheduled for her next appointment based on the clinical diagnosis. However, the patient reported pulsation of the lesion, a feature that she had not reported at the first appointment. Palpation of the lesion revealed a more vascular characteristic for the lesion, with a thickened mucosa that pulsed similar to an arteriovenous shunt. Aspiration of the lesion with a 27-gauge needle attached to a 10-ml syringe yielded an abundant amount of blood. The biopsy was canceled and a clinical diagnosis was established of an arteriovenous malformation. The contents of the aspiration were sent for histological analysis, and the report stated that there were a normal proportion of blood cells, thus eliminating the diagnosis of giant cell lesion or pyogenic granuloma. The diagnosis was established as an arteriovenous malformation.

c. It was determined that sclerotherapy was the treatment of choice and 1 ml of Ethamolin® (Ethanolamine Oleate, FQM, Brazil) was injected directly into the lesion. There was complete remission of the lesion after 14 days. Periodontal scaling followed to remove the significant amount of dental calculus that accumulated due to inadequate oral home care. At a recall appointment 1 year later, there were no signs of recurrence. A mandibular removable prosthesis was used to complete the patient's oral rehabilitation.



7. Discussion:

- a. Patients with HHT can be recognized in the dental clinic. If a lesion is seen, dental professionals must alert patients about the probable diagnosis, the disease manifestations, and the risks it poses. It is important to understand the diagnostic criteria which include (1)telangiectatic lesions on oral mucosa, facial skin, hands, and feet; (2)recurrent episodes of epistaxis; (3)a familial history of the disease; and (d)soft tissue arteriovenous malformations. Once the dentist makes probable diagnosis, the patient must be referred to a physician for further diagnosis and follow up.
- b. When a patient with HHT is identified in the dental office, dentists should be aware of the risks associated with the disease. In the literature, these risks have been reported as **intense epistaxis and vascular malformations in the pancreas, gastrointestinal tract, lungs, and brain.**
- c. Imaging tests can be helpful in identifying systemic arteriovenous malformations, especially the use of **computed tomography and magnetic resonance imaging (MRI)**. Therefore, the patient should be referred for evaluation by a physician to detect any malformations.
- d. The **number of affected sites increases with age** in both forms of the disease, therefore, it is especially important to explain to the patient why it necessary to refer them for diagnosis.
- e. Our patient was already aware of her condition, but was not currently under medical follow up. After referral and when a new series of examinations, including clinical examinations and MRIs of the lungs, gastrointestinal tract, and brain, did not find any lesions, the diagnosis of systemic arteriovenous malformations could be eliminated. Medical follow up of this patient has resumed, and the patient has been stable for the last 2 years.
- f. The clinical diagnosis of arteriovenous malformation took into consideration the guidelines proposed by Buckmiller *et al.*
- g. The lesion had a **thickened vascular mucosa** and was **pulsatile**, although discrete. Aspiration of the lesion was performed using a 27-gauge needle attached to a 10-ml syringe. The aspiration of blood helped to make the clinical diagnosis, and also—after histological analysis of the aspirate—to eliminate other lesions such as giant cell or pyogenic granulomas.
- h. Patients with HHT can be treated in the dental office; however, a few precautions should be taken into account to avoid potential complications, such as **maintaining the dental chair in the most vertical position possible** to reduce the risk of nasal and pulmonary bleeding, and **measuring the patient's blood pressure** both at the beginning and end of the appointment.
- i. Bleeding in patients with HHT occurs as a result of the **disruption of vascular malformations** due to **decreased wall thickness**, not by impairments in the coagulation cascade. There are very few reports of gingival arteriovenous malformations in patients with HHT described in the literature. It is important to recognize these malformations and include them in a differential diagnosis of reactive lesions.
- j. **Surgical treatment** for arteriovenous malformations can result in **hemorrhage** that is difficult to control, worsened by the hemorrhagic characteristics of HHT, potentially creating a medical emergency.
- k. Vascular malformations have been successfully treated with sclerotherapy in patients who were nonsyndromic by means of different sclerosing agents, especially Ethamolin. Although side effects such as **thrombosis**,

hepatotoxicity, acute renal failure, meningitis, pulmonary edema, spinal cord paralysis, and disseminated intravascular coagulation have previously been reported, these complications have a low prevalence and the treatment can be considered **relatively safe** when the drug is administered in **low doses**.

- l. In the dental office, careful attention must be paid to the procedure to reduce the risk of potential complications. The injection should **not introduce air** into the lesion as this could lead to an embolism and a potential stroke. When the procedure-associated risks and potential complications are taken into consideration, sclerotherapy is an acceptable treatment for patients with HHT, **eliminating the need for invasive surgical procedures** while reducing the possibility of secondary complications.
 - m. Our patient did not report any side effects after administration of the sclerosing drug and the lesion did not recur after 12-month follow up.
8. Conclusion:
- a. When treating patients with HHT, it is important to clarify and reinforce the potential local and especially the systemic complications that may occur due to these lesions, and to **refer the patient for medical evaluation**.
 - b. This patient presented a challenge in making the differential diagnosis of an apparently reactive lesion, with history of ineffective treatments that did not take into consideration clinical signs that could have suggested a correct diagnosis followed by appropriate treatment.
 - c. **Palpation of lesions** is important for the diagnosis of oral arteriovenous malformations as it can elicit the presence of **pulsation and its intensity, tissue consistency and compressibility**, as well as **changes in color under pressure**.
 - d. This case reports the successful treatment of a vascular lesion with sclerosing agents in a patient with HHT, which eliminated the necessity of using invasive surgical procedures, thereby reducing the possibility of secondary complications.

題號	題目
1	Which of the following is true? (A) Type 1 is caused by a mutation of ALK1 gene (B) Type 2 is caused by a mutation of endoglin gene (C) Prevalence at least 1 in 10,000 people (D) Does not increase in size and numbers with age
答案(C)	出處：Oral and Maxillofacial Pathology, 3 rd Edition
題號	題目
2	Which of the following is not criteria for diagnosis of HHT? (A) Recurrent spontaneous epistaxis (B) Telangiectasias of the mucosa and skin (C) Arteriovenous malformation involving lungs, liver, or CNS (D) No pulsation
答案(D)	出處：Oral and Maxillofacial Pathology, 3 rd Edition