Orofacial Tuberculosis—A 16-Year Experience With 46 Cases

Neelam N. Andrade, BDS, MDS, and*
Tejas S. Mhatre, BDS, MDS†

Purpose: The aim of this study was to evaluate clinical signs and symptoms of orofacial tuberculosis, with an emphasis on the importance of histologic diagnosis. Based on an evaluation of 46 patients, Andrade's classification is presented with a novel 10-point protocol for the management of orofacial tuberculosis.

Materials and Methods: Forty-six patients were evaluated for orofacial tuberculosis over 16 years (1996 through 2011). All 46 patients were managed with a 10-point protocol for the care of orofacial tuberculosis.

Results: Forty-six cases with a positive diagnosis of orofacial tuberculosis were confirmed by histopathologic and other investigations specified in the 10-point protocol for the management of orofacial tuberculosis. The male:female ratio was 0.917, with no gender predilection. Most cases were seen in the second and third decades of life. A large number of patients (n = 22) presented with a lesion in relation to the angle of the mandible.

Conclusions: In a tuberculosis-prevalent country such as India, it is very important to be aware of tubercular lesions involving the orofacial region. Andrade's classification of orofacial tuberculosis helped classify different forms of tubercular lesions that may involve the orofacial region. The 10-point protocol formulated and applied to all 46 cases proved successful in the management of these cases.
© 2012 American Association of Oral and Maxillofacial Surgeons
J Oral Maxillofac Surg 70:e12-e22, 2012

Tuberculosis is a chronic granulomatous disease that can affect various systems of the body. In humans, the disease can be caused by *Mycobacterium tuberculosis*, *Mycobacterium bovis*, and atypical mycobacteria. Although pulmonary tuberculosis is the most common form of the disease, it also can occur in other organ systems such as the lymph nodes and lymphatics, central nervous system, renal system, skeletal system, hepatic system, and gastrointestinal system, including the oral cavity. Pulmonary tuberculosis is often the primary lesion. It may heal by fibrosis or calcification, or it may remain dormant if the immunity is intact. Tuberculous infection can spread through local inoculation, lymphatics, or the hematogenous route, if the patient's immune response is poor.

Extrapulmonary tuberculosis is an uncommon form of chronic infection, which does not present with the typical signs and symptoms of pulmonary tuberculosis. Most extrapulmonary forms of tuberculosis affect organs with suboptimal conditions for bacillary growth. Therefore, extrapulmonary tuberculosis generally has an insidious presentation, a slow evolution, and paucibacillary lesions and/or fluids. Access to the lesions through secretions and body fluids is not always possible; therefore, invasive techniques may be necessary to obtain material for diagnostic investigation. Orofacial tuberculosis is an uncommon form and presents at different sites such as the mandible (alveolar and basal bone); head; face and neck lymph nodes; salivary glands; maxilla and maxillary antrum; and soft tissues such as the gingiva, tongue, muscles of mastication, and buccal mucosa. The diagnosis of extrapulmonary tuberculosis is often overlooked because it has no specific pathognomonic signs.

Received from the Department of Oral and Maxillofacial Surgery, Nair Hospital and Dental College, Mumbai, India.

*Professor and Head.

†Resident, Department of Oral and Maxillofacial Surgery, Nair Hospital and Dental College, Mumbai, India.

Address correspondence and reprint requests to Dr Andrade: Department of Oral and Maxillofacial Surgery, Nair Hospital and Dental College, A.L. Nair Road, 107/1st Floor, Mumbai 400008, India; e-mail: drnnandrade@yahoo.co.in
© 2012 American Association of Oral and Maxillofacial Surgeons
0278-2391/12/7001-0$36.00/0
doi:10.1016/j.joms.2011.07.020

Table 1. ANDRADE'S CLASSIFICATION FOR OROFACIAL TUBERCULOSIS

Type I	Lumpy jaw: patient presents with extraoral swelling without any intraoral or extraoral draining sinuses; the focus of infection involves the mandible or maxilla; in general, the patient's oral hygiene is good
Type II	Patients report a history of extraction and present with nonhealing extraction sockets with/without intraoral or extraoral draining sinus/sinuses
Type III	Patients report no history of extraction and present with intraoral or extraoral draining sinus/sinuses in the orofacial region and an osteomyelitic bony lesion
Type IV	Tuberculous lymphadenitis of the head face neck region without any features of type I, II, III, or V
Type V	Lesion of other sites in and around the oral cavity, eg, maxillary antrum, salivary glands, orofacial muscles gingiva, tongue, etc

Andrade and Mhatre. Orofacial TB: A 16 Year Experience of 46 Cases. J Oral Maxillofac Surg 2012.

The aim of this report is to present results from a retrospective study and clinical evaluation of the clinical characteristics of orofacial tuberculosis that were correlated histopathologically and with other investigations as noted in a 10-point protocol. A new classification system of orofacial tuberculosis in different forms and locations based on 46 cases is presented (Table 1). A sequential diagnostic and therapeutic protocol is also described with this 10-point protocol for the management of orofacial tuberculosis. This was followed for the treatment of all 46 patients described in the present report.

Materials and Methods

Forty-six patients tested positive for orofacial tuberculosis over 16 years, from 1996 through 2011. This study was carried out after approval by the ethics committee of the Nair Hospital and Dental College, Mumbai, India. All 46 patients were evaluated and successfully treated with the following 10-point protocol (Table 2).

1. A complete history was obtained from the patient to rule out active pulmonary tuberculosis or a family history of tuberculosis, and a clinical examination was performed to rule out odontogenic sources of infection.
2. Chest radiographs, orthopantomograms, and computed tomographic (CT) scans were obtained.
3. Full-body scintigraphy was performed to rule out other skeletal foci of infection in other parts of the body.
4. Purified protein derivative (ie, Mantoux test) and erythrocyte sedimentation rate were determined.
5. Polymerase chain reaction for immunoglobulin G and immunoglobulin M antibodies for *M tuberculosis* was performed.
6. Sputum samples (3 samples) were scrutinized for acid-fast bacilli (AFB).
7. For "lumpy jaw" (incision and drainage were not performed), aspiration was performed and the aspirate was assessed by histopathology (Ziehl-Neelsen stain) and culture using Bactec (Becton Dickinson Pvt Ltd, Haryana, India).
8. For extraoral or intraoral draining of sinuses and unhealed extraction sockets or deep-seated bony lesions, curettage or incisional biopsy was performed and assessed by histopathology (Ziehl-Neelsen stain) and culture with Bactec.
9. Only those patients with a diagnosis positive for tuberculosis by histopathology with or without positive culture studies were started on antituberculosis therapy under a directly observed treatment strategy (DOTS).
10. Long-term follow-up was mandatory.

Results

Forty-six cases were diagnosed positive for orofacial tuberculosis by histopathologic confirmation and

Table 2. INVESTIGATION DATA OF 46 PATIENTS

Investigations	No. of Patients With Positive Results
Chest radiograph, PA view	Calcifications on radiographs of 3 patients
PPD (Mantoux test)	Mild reaction, 25; moderate reaction, 19; severe reaction, 3
PCR	Significant in 25 patients
IgG	Positive in 38 patients
IgM	Positive in 12 patients
Sputum samples positive for AFB	Nil
Acid-fast staining of affected tissue samples	Positive for all 46 patients
Bactec	Positive for all 46 patients

Abbreviations: AFB, acid-fast bacilli; IgG, immunoglobulin G; IgM, immunoglobulin M; PA, posteroanterior; PCR, polymerase chain reaction; PPD, purified protein derivative.

Andrade and Mhatre. Orofacial TB: A 16 Year Experience of 46 Cases. J Oral Maxillofac Surg 2012.

Table 3. AGE DISTRIBUTION OF CASES POSITIVE FOR OROFACIAL TUBERCULOSIS

Age (yrs)	No. of Cases
1-10	4
11-20	14
21-30	14
31-40	8
41-50	3
51-60	1
61-70	1
71-80	1

Andrade and Mhatre. Orofacial TB: A 16 Year Experience of 46 Cases. J Oral Maxillofac Surg 2012.

other investigations specified in this 10-point protocol for the management of orofacial tuberculosis. The male:female ratio was 0.917, with no gender predilection. The age distribution was wide (1 year to 80 years old), with most cases in the second and third decades (Table 3).

Lesions of orofacial tuberculosis were seen to more commonly involve the mandibular angle and ramus, with or without intraoral and/or extraoral draining sinuses (Figs 1A, 2A, 3A). There were 11 patients who presented with lumpy jaw in the mandible and 1 in the maxilla. Six patients had a history of tooth/teeth extraction in the same region, and 5 of these patients presented with nonhealing extraction sockets and 1 patient with a nonhealing extraction socket and extraoral draining sinus. Fourteen patients presented with extraoral draining sinuses with no history of any tooth extraction, and 3 patients had only tuberculous lymphadenitis of the submandibular lymph nodes. Eight patients had tuberculous lesions in mandibular gingiva and presented with generalized gingival hyperplasia and gingivitis. One patient presented with tuberculosis of the zygoma with an extraoral draining

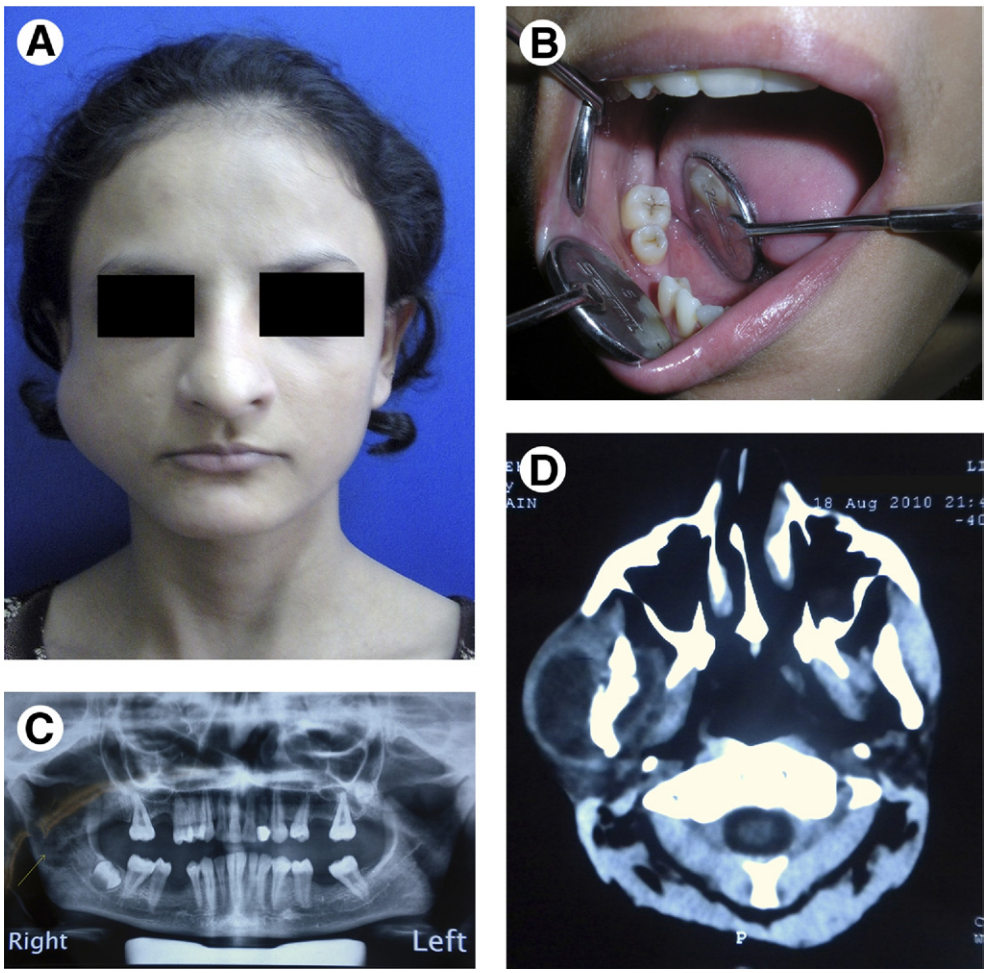

FIGURE 1. Type I. *A,* Lumpy jaw of the ramus on the right side. *B,* Healthy oral hygiene in a patient with lumpy jaw. *C,* Orthopantomogram shows rarefaction in the mandibular ramus on the right side. *D,* Axial computed tomographic view shows buccal cortical destruction in the right mandibular ramus.

Andrade and Mhatre. Orofacial TB: A 16 Year Experience of 46 Cases. J Oral Maxillofac Surg 2012.

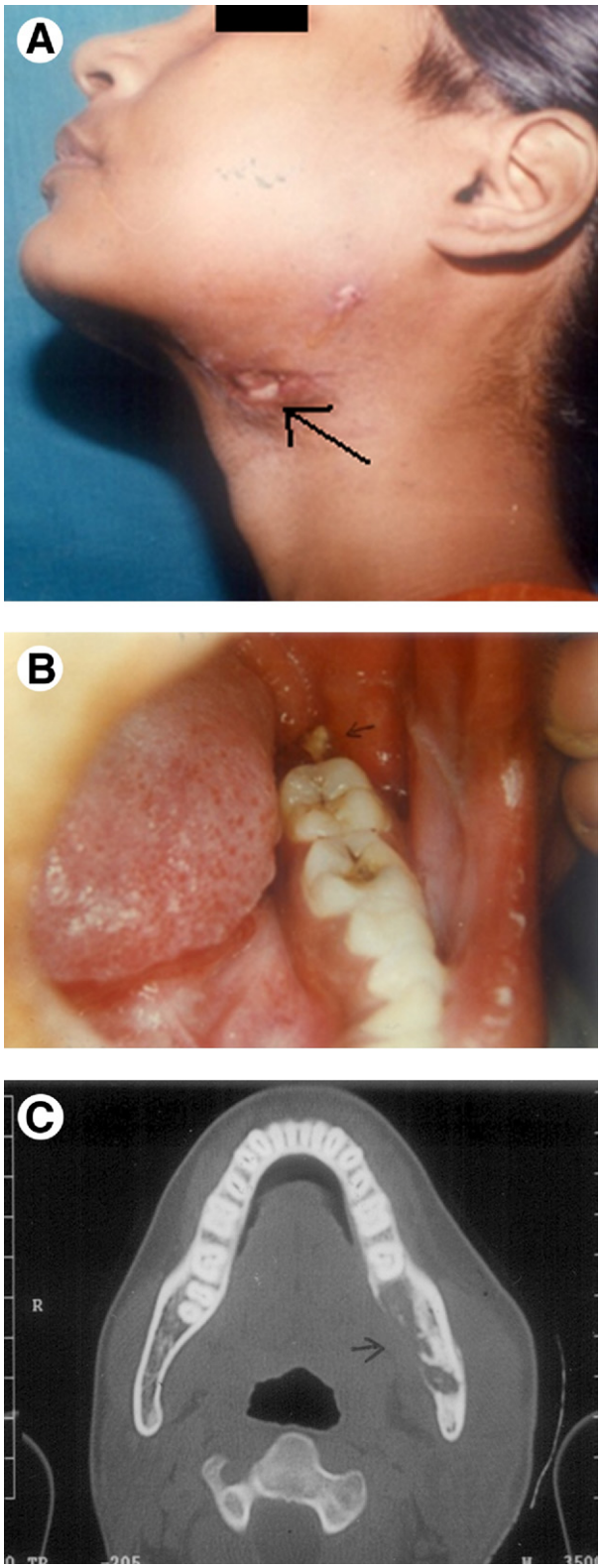

FIGURE 2. Type II. *A,* Nonhealing extraoral draining sinuses (*arrow*) on the left side. *B,* Nonhealing extraction socket (*arrow*) on the left side. *C,* Axial computed tomographic view shows destruction of the lingual cortex (*arrow*).

Andrade and Mhatre. Orofacial TB: A 16 Year Experience of 46 Cases. J Oral Maxillofac Surg 2012.

sinus, and 2 patients had exophytic soft tissue growths in the maxilla (Table 4). Based on these data, a classification system was devised according to the site and clinical presentation of the lesion (Table 1, Figs 1A, 2A, 3A, 4A, 5A).

Three patients also had radiographic evidence of tuberculous lesion in the lungs, so the primary focus of tuberculous infection was thought to be in the pulmonary system. The scintigraphic studies showed active sites of infection in other parts of the skeletal system in only these 3 patients. Interestingly, sputum samples for AFB showed no yield and did not show the presence of any *M tuberculosis* bacilli at microscopy, whereas the affected local tissue samples showed the presence of AFB at microscopy and the growth of *M tuberculosis* on Bactec culture. The other blood investigations, ie, polymerase chain reaction and immunoglobulin G and immunoglobulin M titers, showed variable results in different patients and added evidence for the diagnosis of tuberculous lesion (Table 2). Of 46 patients, 1 was diagnosed with multidrug-resistant tuberculosis and was started on chemotherapy (Table 5). On follow-up 2 years later, the patient presented with multiple draining sinuses on the face, neck sternum, supraclavicular region, and left ankle (Fig 6A, B). On inquiry it was shown that the patient had not been compliant with chemotherapy. Bone scanning was repeated and it showed multiple hot spots involving the ribs and the vertebral column. Discharge from draining sinuses was tested for drug sensitivity, AFB, and culture using Bactec, and the patient was diagnosed with multidrug-resistant tuberculosis. The patient was started on second-line chemotherapy for multidrug-resistant tuberculosis as presented in Table 5. When last followed, the patient was reported to have developed miliary tuberculosis and cerebral meningitis.

Three patients are undertaking antituberculosis therapy at a local DOTS center. All other 42 patients had a successful outcome with a short-course chemotherapy regimen that ranged from 6 to 9 months.

Discussion

Tuberculosis presents in many forms and is known to affect almost any part of the human body. Extrapulmonary sites, such as those involving the gastrointestinal system, central nervous system, skin, lymph nodes, or oral cavity, may also be involved as a primary or secondary lesion.[1,2] Of the present 46 cases, 3 patients had an old calcification in the lungs as the possible source of reactivation. Two other cases were considered to have primary lesion of the hilar lymph nodes from previous contact with tuberculosis, a theory that has been well supported by Pagel et al.[3] The

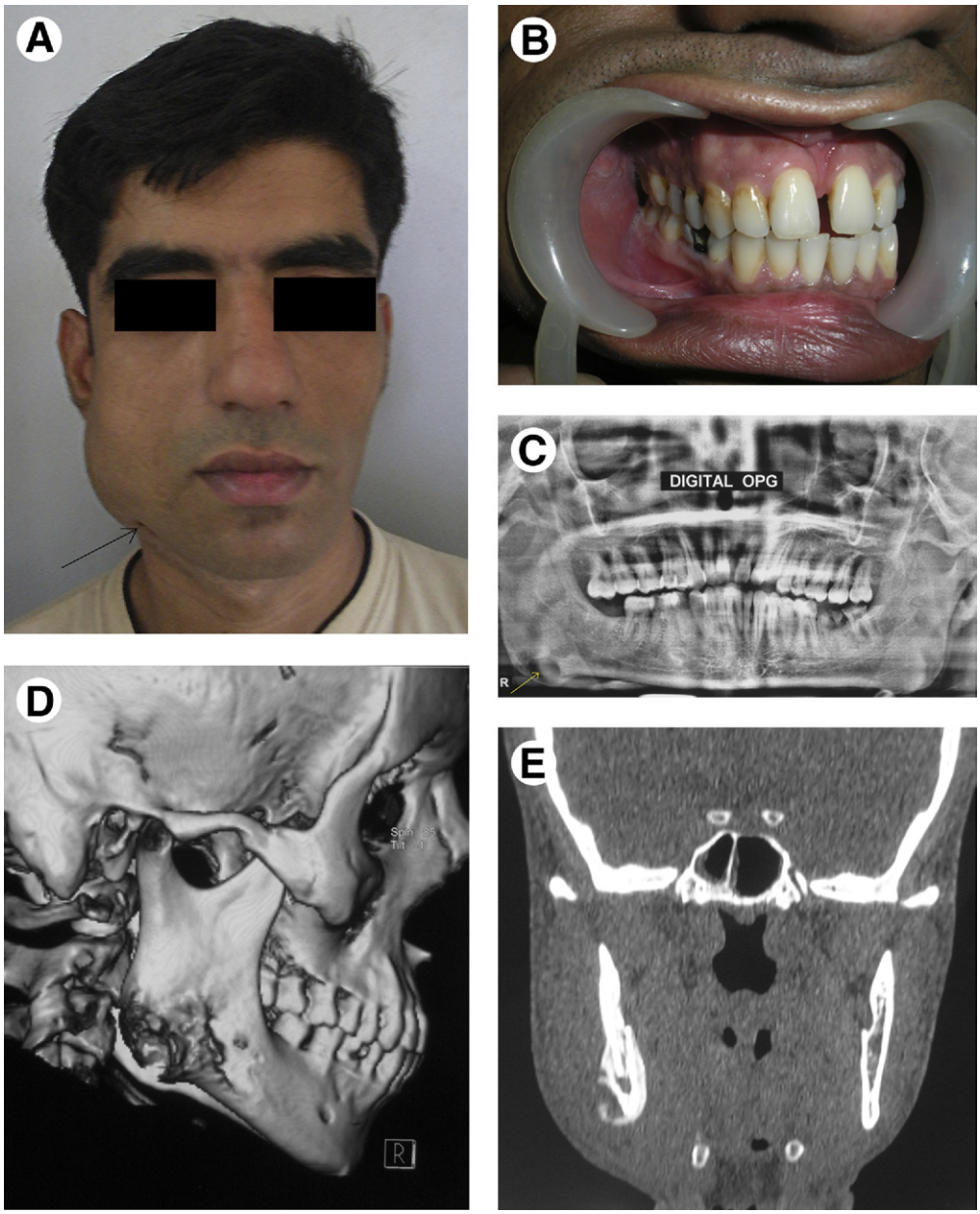

FIGURE 3. Type III. *A,* Patient with no recent history of extraction has swelling and an extraoral draining sinus on the right side of the mandible. *B,* This patient was found to have good oral hygiene. *C,* Rarefaction at the right angle of the mandible without any pathologic changes near the mandibular alveolus on the right side. *D,* Three-dimensional computed tomographic reconstruction shows destruction of the right angle of the mandible at the masseter muscle attachment. *E,* Destruction of the buccal cortex compared with the cancellous bone on the right side of the mandibular angle.

Andrade and Mhatre. Orofacial TB: A 16 Year Experience of 46 Cases. J Oral Maxillofac Surg 2012.

pulmonary tuberculous status of 8 patients with gingivitis and gingival enlargement was not known. The remaining 33 patients were negative for pulmonary tuberculosis.

Predisposing local and systemic factors exist for the occurrence of oral lesions[1]. These may be local factors such as poor oral hygiene, local trauma, preexisting lesions such as leukoplakia, periapical granuloma, cysts, and abscesses, and periodontitis.[1,4] A systemic predisposing factor, such as altered host resistance from immunosuppression or nutritional deficiencies, increases the susceptibility of a patient to a tuberculous infection. Common sites for oral tuberculous lesions to occur are the gingiva, the alveolus through an extraction socket, the tongue, and mucobuccal folds.[1,4-7] At the Nair Hospital and Dental College, tuberculous lesions were seen to involve the ramus and body of the mandible, submandibular lymph node, gingiva, maxilla, zygoma, and symphysis of the mandible (Figs 1 to 5).

Table 4. DISTRIBUTION OF CASES ACCORDING TO ANDRADE'S CLASSIFICATION OF OROFACIAL TUBERCULOSIS

Andrade's Classification of Orofacial Tuberculosis	No. of Cases
Type I	12
Type II	6
Type III	15
Type IV	3
Type V	10

Andrade and Mhatre. Orofacial TB: A 16 Year Experience of 46 Cases. J Oral Maxillofac Surg 2012.

The integrity of the oral epithelium and the inhibitory effect of saliva are considered the reasons for the relative resistance to infection by *M tuberculosis* bacilli.[5] However, any break in the continuity of the oral epithelium owing to an abrasion, ulceration, or an extraction socket facilitates inoculation of the bacilli present in the sputum, which is brought into intimate contact during coughing or speech. Inflammatory conditions of the oral mucosa are known to cause exposure of the underlying connective tissue. In contrast, other than the 8 patients who had gingivitis and gingival enlargement, no other patient had a breach in the continuity of the oral mucosa.

Six patients had a history of tooth/teeth extraction in the same region, and 5 of these presented with nonhealing extraction sockets and 1 with a nonhealing extraction socket and an extraoral draining sinus. On inquiry these 6 patients provided a history positive for an extraoral swelling before the extractions. Pre-extraction radiographs showed no pathology involving the teeth that had been extracted. These were the patients who likely presented with lumpy jaw and were misdiagnosed with an odontogenic infection. It was obvious that the tuberculous lesion progressed from lumpy jaw to nonhealing extraction sockets with and without draining sinuses.

There was no evidence of direct inoculation of AFB in 32 of the present patients. Hence, the spread to the jaw bones and cervical lymph node can be explained only by a hematogenous or lymphatic route in these patients. In this respect, it is important to consider the blood supply to the ramus of the mandible for the spread of tuberculosis to this region.[8-11] The ramus of the mandible and the attached musculature were seen to be affected more often, and the involvement of this region, in addition to its muscle attachments, may be due to a hematogenous spread from the arterial supply of the masseter and medial pterygoid muscles. The posterior mandible was more commonly involved, possibly the result of hematogenous spread.[12] This was further substantiated by the fact that the CT scans and the clinical presentation during surgery showed that the lesion was seen to involve the outer cortical plates, whereas the medullary bone was found to be unaffected (Fig 7A to D). Blood supply to this region is by 3 sources: *1)* blood vessels supplying the medial pterygoid and masseter muscles, *2)* the inferior alveolar artery, or *3)* a periosteal blood supply. Of these sources, spread through blood vessels supplying the medial pterygoid and masseter muscles was considered the most important in the involvement of the mandibular ramus and body by tuberculosis. Moreover, biopsy of the overlying masseter and medial pterygoid muscles and the adjacent bone from the mandibular ramus showed involvement of these tissues by tuberculosis as proved histopathologically by acid-fast staining.

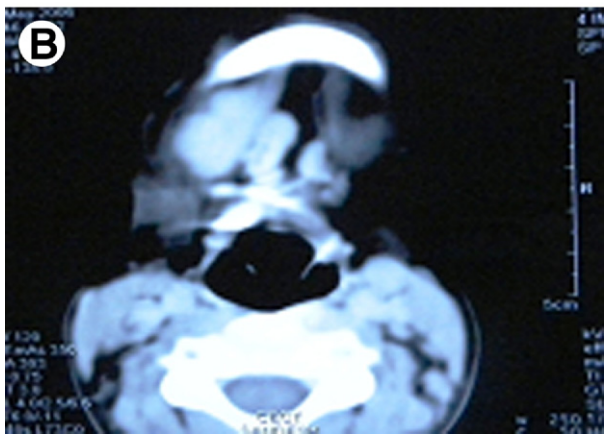

FIGURE 4. Type IV. *A,* Tuberculous lymphadenitis of the right submandibular lymph node. *B,* Axial computed tomographic view shows enlarged, matted, right submandibular lymph nodes.

Andrade and Mhatre. Orofacial TB: A 16 Year Experience of 46 Cases. J Oral Maxillofac Surg 2012.

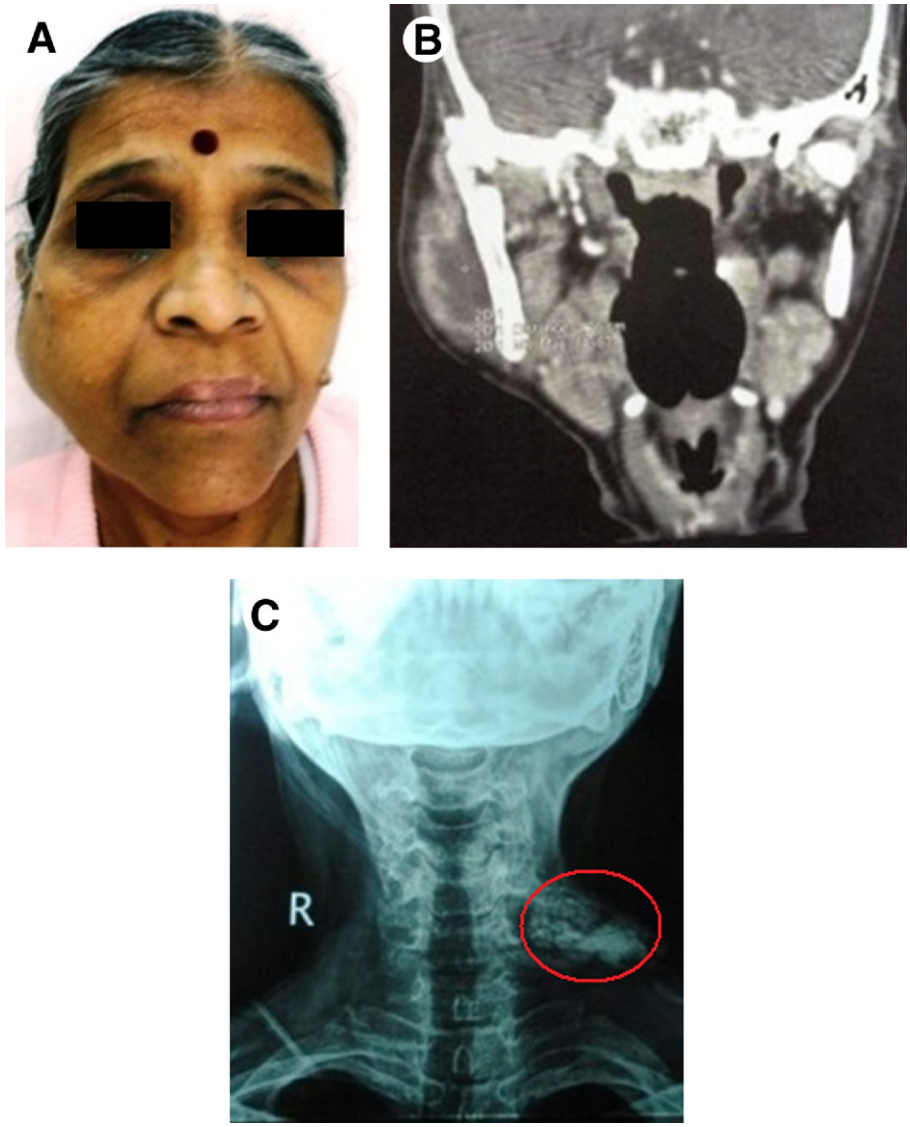

FIGURE 5. Type V. *A,* Tuberculous lesion of the right masseter muscle. *B,* Computed tomogram. *C,* Calcification in the supraclavicular lymph node with a tuberculous lesion in the masseter (*circled area*).

Andrade and Mhatre. Orofacial TB: A 16 Year Experience of 46 Cases. J Oral Maxillofac Surg 2012.

A similar involvement of the osteoarticular system and long bones is most commonly found in children and the elderly and is generally secondary to hematogenous seeding. The lesion is very commonly seen at the muscle attachments and at the metaphysis of long bones. The most frequent sites of bone involvement are the vertebrae (Pott disease) and the proximal extremities of the long bones.[13,14] The spread to cervical lymph nodes and then to the mandible from the hilar lymph nodes is explained by the lymphohematogenous route.[15]

These 32 patients had a healthy dentition with no odontogenic source of infection or any break in mucosal continuity. This substantiates a hematogenous or lymphatic spread of tuberculosis to the mandibular ramus. Initially, there was a difficulty in the diagnosis because no supportive clinical findings of swelling or sinuses could be linked to an odontogenic cause, cyst, or neoplasm. Establishing a diagnosis was also difficult because of the inability to detect the AFB with repeated sputum samples and cultures, which were negative. A tentative diagnosis of orofacial tuberculosis was established for them, and these patients were managed successfully with the present 10-point treatment protocol for the management of orofacial tuberculosis.

It is very important to document a patient's thorough history and clinical and radiologic examinations for a correct diagnosis. The final diagnosis is established only by a histopathologic confirmation and microbiological study of the tissue specimen for a definitive diagnosis of tuberculosis. Biopsy of the le-

Table 5. DRUG REGIMENS FOR TREATMENT CATEGORIES I TO IV

Category	Characteristic of a TB Case	Treatment Regimen*	
		Intensive Phase	Continuation Phase
I	New sputum smear: positive, seriously ill; negative, seriously ill, extrapulmonary	2 $(HRZE)_3$	4 $(HR)_3$
II	Relapse failure treatment after default others	2 $(SHRZE)_3$ followed by 1 $(HRZE)_3$	5 $(HRE)_3$
III	Sputum smear: negative not seriously ill, extrapulmonary	2 $(HRZ)_3$	4 $(HR)_3$
IV	For treatment of MDR-TB cases (and those with rifampicin resistance)	6 drugs: kanamycin, ofloxacin (levofloxacin), ethionamide, pyrazinamide, E, cycloserine during 6-9 mo of intensive phase	4 drugs: ofloxacin (levofloxacin), ethionamide, E, cycloserine during 18 mo of continuation phase

Note: Various definitions under the RNTCP may be found in annexure I.
Abbreviations: E, ethambutol; H, isoniazid; MDR-TB, multidrug-resistant tuberculosis; R, rifampicin; S, ??; Z, pyrazinamide.
*A number prefix denotes the number of months and subscript 3 indicates 3 times per week.

Andrade and Mhatre. Orofacial TB: A 16 Year Experience of 46 Cases. J Oral Maxillofac Surg 2012.

sion is confirmatory but at times may require repeat biopsies because of granulomatous changes that may not be evident in very early lesions.[1] DNA probes and polymerase chain reaction for tuberculosis are very sensitive to technique and, hence, not very reliable.[16] In 1994 Molinari and Coltone[17] reported the use of FNAC for vertebral tuberculosis. They also stated that if aspirated material shows the presence of granulomatous inflammation, the patient should be managed for tuberculosis because the AFB may not be found in the Ziehl-Neilson stain, particularly in countries where tuberculosis is prevalent. In areas with a high prevalence, it has been suggested that if cervical lymphadenitis is identified, tuberculosis lymphadenitis should be considered and biopsy performed for establishing the diagnosis.

Primary orofacial tuberculosis is observed more widely in children and young adults/adolescents.[18-20] Seventeen of the present 46 patients were younger than 20 years. They did not present with pulmonary tuberculosis, and orofacial tuberculosis was the primary lesion seen in these patients.

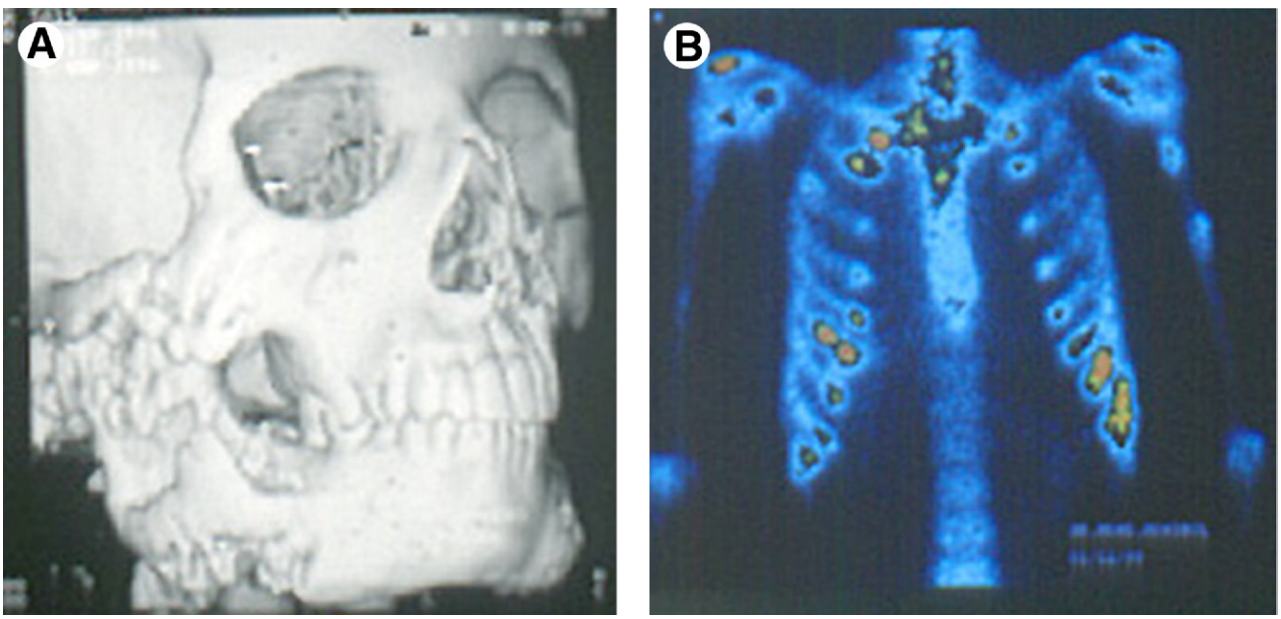

FIGURE 6. *A,* Computed tomogram of patient with multidrug-resistant tuberculosis. *B,* Bone scan of entire skeleton of a patient with multidrug-resistant tuberculosis.

Andrade and Mhatre. Orofacial TB: A 16 Year Experience of 46 Cases. J Oral Maxillofac Surg 2012.

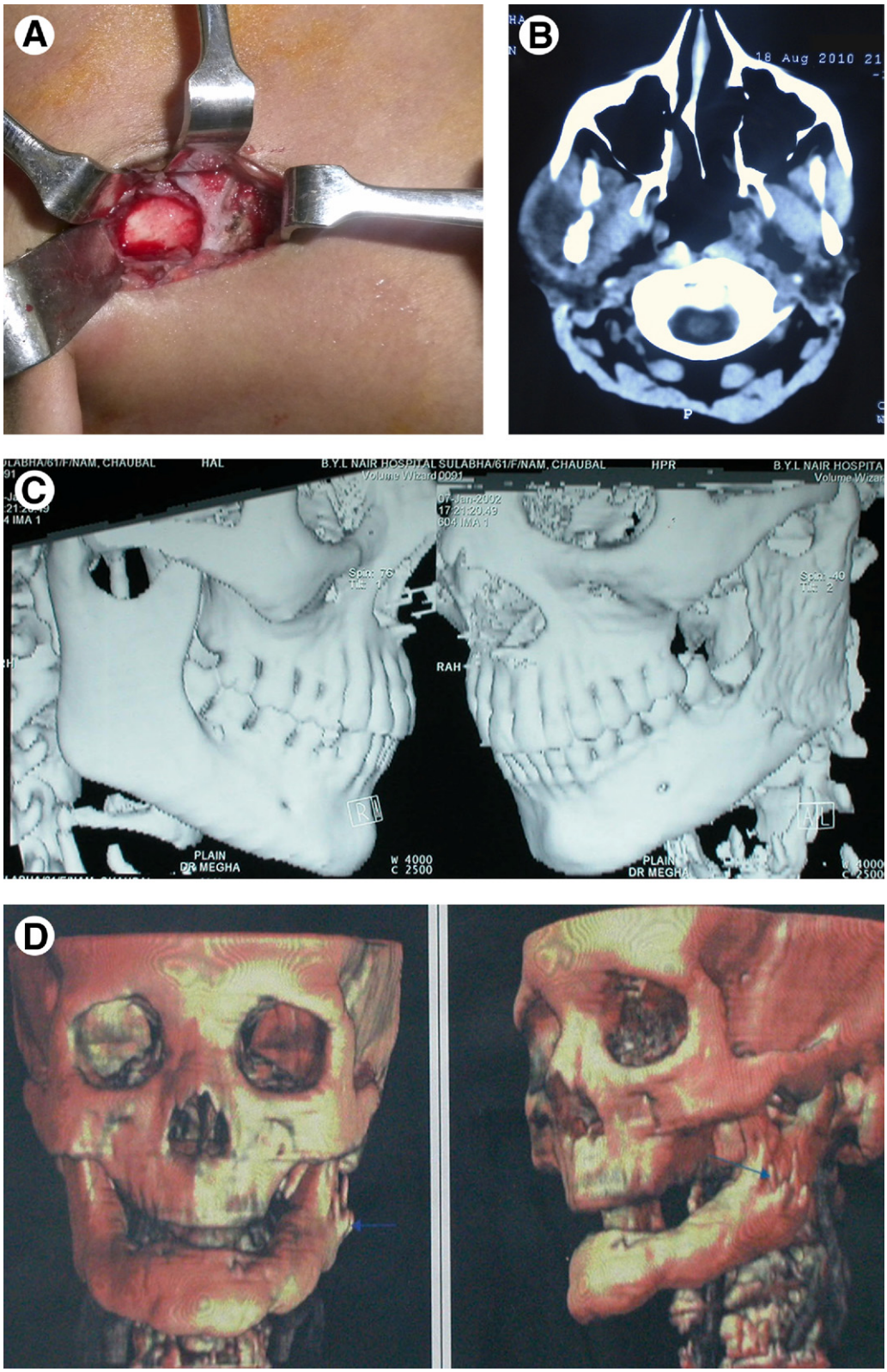

FIGURE 7. *A,* Buccal cortical destruction at the mandibular ramus with healthy underlying cancellous bone. *B,* Right buccal cortical destruction as seen on computed tomogram. *C,* Buccal cortical destruction of the right ramus of mandible as seen on computed tomogram. *D,* Buccal cortical destruction of the right mandibular ramus.

Andrade and Mhatre. Orofacial TB: A 16 Year Experience of 46 Cases. J Oral Maxillofac Surg 2012.

In patients negative for the human immunodeficiency virus (HIV), isolated cervical lymphadenitis is most often seen in about two-thirds of patients.[18-22] Bem[23] observed that in patients positive for HIV and those negative for HIV, cervical lymph nodes were most commonly affected, followed by axillary and inguinal lymph nodes. None of the present patients was positive for HIV.

The treatment of tuberculosis has undergone a vast change in the past century. For extrapulmonary tuberculosis, antituberculosis treatment remains the mainstay in their management. The RNTCP and other national tuberculosis programs worldwide follow the World Health Organization guidelines, ie, DOTS, which advocates short-course intermittent chemotherapy for patients with extrapulmonary tuberculosis.

According to DOTS guidelines,[24] patients with less severe forms of extrapulmonary tuberculosis are categorized under treatment category III, and those with a severe form of extrapulmonary tuberculosis are categorized under treatment category I. Antituberculous treatment regimens for these categories are listed in Table 3. Although the 6-month treatment may be sufficient for many patients, each patient has to be assessed individually and, where relevant, treatment duration be extended.[25] All the present patients were referred to a DOTS center close to their respective residences after establishing the diagnosis of tuberculosis. These patients were followed on a rigid regimen of short-course chemotherapy as advocated by the DOTS authority, ie, treatment category III (Table 5).

Although the rarity of orofacial tuberculosis is undisputable, it is imperative that a high index of suspicion be considered when dealing with lesions without a specific etiology. This is especially important in the present times, because the low incidence of orofacial tuberculosis (0.05% to 5% of all tuberculosis cases)[26,27] can increase rapidly, if the lesion remains undiagnosed. Not only can it cause an epidemic, but because of improper treatment, the complications of tuberculosis can be many fold, causing severe disfigurement, disability, and, at times, can prove to be life-threatening.

The authors' experience with orofacial tuberculosis has involved predominantly the mandibular angle and the ramus. Most of these patients had fair to healthy oral hygiene, and the involved region had no source of an odontogenic infection or breach in the continuity of oral mucosa, thus supporting the theory of spread of tuberculous infection by a hematogenous or lymphatic route. One source of blood supply to the angle of the mandible is by an arterial supply to the masseter and medial pterygoid muscles; and spread to this region by this route seems prudent because the destruction of bone seen on CT scans and in situ was from outside to inside in contrast to the normal pattern in osteomyelitis owing to odontogenic infection, ie, bone marrow first followed by the cortex. Involvement of the masseter and medial pterygoid muscles in addition to the adjacent bone proves that the infection progressed from the attached muscles to the angle of the mandible (Fig 7A to D). This typical pattern of destruction seen on CT scans of the present patients raises the suspicion of tuberculous infection, prompting an investigation for tuberculosis and management with the described 10-point protocol for orofacial tuberculosis.

In a tuberculosis-prevalent country such as India, it is important to be aware of tuberculous lesions involving the orofacial region. The tuberculous lesion may present at different sites of the orofacial region, in the hard tissues or soft tissues of the mandible, maxilla, lymph nodes, salivary glands, gingiva, tongue, etc, and in different forms such as a lumpy swelling, draining sinus or fistula, or even osteomyelitis presenting with sequestrum. This report presents Andrade's classification of orofacial tuberculosis based on the clinical presentation of these 46 patients. The 10-point protocol helps in diagnosing and differentiating it from other similarly occurring infectious conditions. Using this 10-point protocol for management and adhering to this protocol for patients with suspected and confirmed tuberculosis has proved most effective for the diagnosis and management of these patients with orofacial tuberculosis.

References

1. Prabhu SR, Sengupta SK: Bacterial infections due to mycobacteria, *in* Prabhu SR, Wilson DF, Daftary DK, et al (eds): Oral Diseases in Tropics (ed 1). Delhi, Oxford University Press, 1993, p 195
2. de Aguiar MC, Arrais MJ, Mato MJ, et al: Tuberculosis of the oral cavity: A case report. Quintessence 28:745, 1997
3. Pagel W, Simmonds FAH, MacDonalds N, et al: Textbook of Pulmonary Tuberculosis, Bacteriology, Pathology, Diagnosis, Management, Epidemiology and Prevention (ed 4). 1964, p 208
4. Rinaggio J: Tuberculosis. Dent Clin North Am 47:449, 2003
5. Eng HL, Lu SY, Yang CH, et al: Oral tuberculosis. Oral Surg Oral Med Oral Pathol Oral Radiol Endod 81:415, 1996
6. Iype EM, Ramdas K, Pandey M, et al: Primary tuberculosis of the tongue: Report of three cases. Br J Oral Maxillofac Surg 39:402, 2001
7. Bhat P, Mehndiratta A, D'Costa L, et al: Tuberculosis of tongue: A case report. Indian J Tub 44:31, 1997
8. Castelli W: Vascular architecture of the human adult mandible. J Dent Res 42:786, 1963
9. Clement CD: Atlas of Anatomy (ed 3). 1987
10. Lanigan DT, West RA: Aseptic necrosis of the mandible: Report of two cases. J Oral Maxillofac Surg 48:296, 1990
11. Lownie J, Cleaton TP: Avascular necrosis of mandibular ramus in the baboon following orthognathic surgery. Int J Oral Maxillofac Surg 9:206, 1980

12. Worsaac N, Reibel J: Tuberculous osteomyelitis of the mandible. Br J Oral Maxillofac Surg 22:93, 1984
13. Gunasekera TMR, Karunathilake DH, Wickramasinghe EMNW, et al: A rare presentation of tuberculous osteomyelitis in childhood: Sri Lanka. J Child Health 37:61, 2008
14. Tuli SM: General principles of osteoarticular tuberculosis. Clin Orthop Relat Res 398:11, 2002
15. Heney C, Baise T, Cohem MA: Tuberculosis of the mandible—A case report. Pediatr Infect Dis J 7, 1988
16. Williams GD: Jones T. Mycobacterium marches back. J Otolaryngol 109:5, 1995
17. Molinari JA, Coltone JA: Tuberculosis in 1990s. Current implications for dentistry. Compend Contin Educ Dent XIV, 1994
18. Thompson MM, Underwood MJ, Sayers RD, et al: Peripheral tuberculous lymphadenopathy: A review of 67 cases. Br J Surg 79:763, 1992
19. Dandapat MC, Mishra BM, Dash SP, et al: Peripheral lymph node tuberculosis: A review of 80 cases. Br J Surg 77:911, 1990
20. Subrahmanyam M: Role of surgery and chemotherapy for peripheral lymph node tuberculosis. Br J Surg 8:1547, 1993
21. Chen YM, Lee PY, Su WJ, et al: Lymph node tuberculosis: 7-Year experience in Veterans General Hospital, Taipei, Taiwan. Tuber Lung Dis 73:368, 1992
22. Fain O, Lortholary O, Djouab M, et al: Lymph node tuberculosis in the suburbs of Paris: 59 cases in adults not infected by the human immunodeficiency virus. Int J Tuberc Lung Dis 3:162, 1999
23. Bem C: Human immunodeficiency virus-positive tuberculous lymphadenitis in Central Africa: Clinical presentation of 157 cases. Int J Tuberc Lung Dis 1:215, 1997
24. Maher D, Chaulet P, Spinaci S, et al: Treatment of Tuberculosis: Guidelines for National Programmes. Geneva, World Health Organization, 1997
25. Blumberg HM, Burman WJ, Chaisson RE, et al: American Thoracic Society/Centers for Disease Control and Prevention/Infectious Diseases Society of America: Treatment of tuberculosis. Am J Respir Crit Care Med 167:603, 2003
26. Mignogna MD, Muzio LLO, Fvia G, et al. Oral tuberculosis: A clinical evaluation of 42 cases. Oral Dis 6:25, 2000
27. Yepes JF, Sullivan J, Pinto A: Tuberculosis: Medical management update. Oral Surg Oral Med Oral Pathol Oral Radiol Endod 98:267, 2004