J Oral Maxillofac Surg
70:e32-e38, 2012

Synovial Chondromatosis in the Inferior Compartment of the Temporomandibular Joint: Different Stages With Different Treatments

Min-jie Chen, DDS, MD, Chi Yang, DDS, MD,†*
Xie-yi Cai, DDS, MD,‡ Bin Jiang, DDS,§ Ya-ting Qiu, DDS, MD,‖
and Xiao-hu Zhang, DDS, MD¶

Purpose: To discuss a new classification and the treatment principles of synovial chondromatosis (SC) in the inferior compartment of the temporomandibular joint (TMJ).

Patients and Methods: Five cases of SC in the inferior compartment were treated in an open manner between January 2008 and May 2011. Each case had different clinical and radiologic aspects and was treated with different surgical therapies. SC in the inferior compartment of the TMJ is classified into 3 stages. All patients were evaluated by computed tomography, magnetic resonance imaging, and clinical manifestations preoperatively and postoperatively.

Results: There were 3 kinds of manifestation modes from radiologic findings. Case 1 was in stage 1, in which multiple loose bodies are noted without bony erosion. This patient was treated by removal of loose bodies and affected synovium. Case 2 was in stage 2, in which multiple calcified nodules were conglutinated to the condyle; the condyle was enlarged with pressure erosions. This patient was treated by condylectomy and reconstruction with costochondral graft. Case 3, case 4, and case 5 were all in stage 3, in which the condyle was destroyed as a result of pressure erosions or by direct bony invasion of the mass and the inferior surface of the disc was involved. These patients were treated by condylectomy together with discectomy, as well as reconstruction with costochondral graft and pedicled deep temporal fascial fat flap. No recurrence occurred. The height of the ramus and the occlusion were maintained in the same condition as preoperatively.

Conclusions: Our new classification of SC in the inferior compartment of the TMJ can better guide clinical treatment.
© 2012 American Association of Oral and Maxillofacial Surgeons
J Oral Maxillofac Surg 70:e32-e38, 2012

Synovial chondromatosis (SC) is a rare benign arthropathy characterized by cartilage formed in the synovial membrane, as well as secondary calcification and ossification. SC usually affects large synovial joints, such as the elbow and knee, and it is relatively uncommon in the temporomandibular joint (TMJ). To our knowledge, more than 200 cases of SC in the TMJ have been presented in the literature. This widespread finding is possibly attributable to improved imaging techniques, such as

Received from the Department of Oral & Maxillofacial Surgery, Ninth People's Hospital, Shanghai Jiao Tong University, School of Medicine, Shanghai Key Laboratory of Stomatology, Shanghai, China.

*Associate Professor.

†Professor.

‡Associate professor.

§Resident.

‖Attending Doctor.

¶Attending Doctor.

This work was supported by the Science and Technology Commission of Shanghai (08DZ2271100) and Program for Innovative Research Team of the Shanghai Municipal Education Commission.

Address correspondence and reprint requests to Dr Yang: Department of Oral & Maxillofacial Surgery, Ninth People's Hospital, Shanghai Jiao Tong University, School of Medicine, Shanghai Key Laboratory of Stomatology, No. 639 Zhi-zao-ju Road (200011), Shanghai, China; e-mail: yangchi63@hotmail.com
© 2012 American Association of Oral and Maxillofacial Surgeons
0278-2391/12/7001-0$36.00/0
doi:10.1016/j.joms.2011.07.014

Table 1. SUMMARY OF DATA FOR 5 PATIENTS WITH SC IN INFERIOR COMPARTMENT OF TMJ

Case	Age (yr)/ Gender	Location	Symptoms					Duration of Symptoms (mo)	Follow-Up (mo)
			PAS	Pain	Crepitus	LMO (mm)	Malocclusion		
1[17]	50/M	L	++	++	+	28	Left posterior open bite	10	18
2	29/M	R	+	+	+	20	Right posterior open bite	12	30
3	30/M	L	-	-	-	20	Mandibular midline shift of 7 mm to left	12	23
4	41/F	R	+++	+++	-	28	No	24	19
5	35/M	L	-	+	-	10	Mandibular midline shift of 5 mm to left	24	2

Abbreviations: PAS, preauricular swelling; LMO, limitation of mouth opening.

Chen et al. Synovial Chondromatosis in TMJ. J Oral Maxillofac Surg 2012.

plain radiography, computed tomography (CT), and magnetic resonance imaging (MRI).[1,2]

Most reports suggest that SC of the TMJ has a predilection for occurrence in the superior compartment.[3-5] We reviewed the SC literature in the TMJ and found that only 6 cases that originated in the inferior compartment were reported,[6-11] 1 case was found in both the superior and inferior compartments without perforation,[12] and 9 cases were found in both the superior and inferior compartments with perforation.[13-16] From January 2008 to May 2011, we found 5 cases of SC in the inferior compartment (including a previously reported case[17]). Each case had different clinical and radiologic aspects and was treated with different surgical therapies. The stages and the treatment principles of SC in the inferior compartment are discussed.

Patients and Methods

CRITERIA FOR CLASSIFYING SC ORIGINATING FROM INFERIOR COMPARTMENT

According to the different structures involved, we classified SC in the inferior compartment of the TMJ into 3 stages. Stage 1 involves multiple loose bodies that are noted with expansion of the inferior compartment; bony erosion is not found. Stage 2 involves multiple calcified nodules that are conglutinated to the condyle, the condyle is enlarged by pressure erosions, and the disc is intact. Stage 3 involves multiple calcified nodules conglutinated to the condyle, the condyle is destroyed as a result of pressure erosion or by direct bony invasion of the mass, the inferior surface of the disc is involved, and the lesion can not be detached from the disc. The classification was simply defined as follows: stage 1, synovium is involved; stage 2, synovium and condyle are involved; and stage 3, synovium, condyle, and disc are involved.

PATIENT DATA

Ethical approval was given by our university ethics committee. We have read the Declaration of Helsinki and have followed the guidelines in this investigation. A retrospective review of our patient files showed that there were 81 patients with SC of the TMJ treated at the TMJ clinic of the Ninth People's Hospital, Shanghai Jiao Tong University, Shanghai, China, from January 2000 to May 2011. Of the 81 patients, 70 (86.4%) had origins from the superior compartment, including 1 patient who had both SC and pigmented villonodular synovitis simultaneously[18]; 5 (6.2%) had origins from both the superior and inferior compartments with perforation; 1 (1.2%) had origins from both the superior and inferior compartments without perforation; and 5 (6.2%) were diagnosed with SC originating from the inferior compartment. Their demographics, location, duration of symptoms before hospitalization, clinical manifestations, and follow-up are given in Table 1. No patients had a history of trauma, septic arthritis, or rheumatoid arthritis. All surgical interventions were performed under general anesthesia through a preauricular and infratemporal approach to the joint.

Results

RADIOLOGIC FINDINGS

There were 3 types of manifestation modes from radiologic findings. The first mode was found in case 1: CT scans did not show calcifying lesions, and sagittal magnetic resonance images showed distinct nodules within an extremely expanded inferior joint compartment and an articular disc in the normal position (Fig 1A). The second mode was found in case 2, case 3, and case 4: the bony window on CT scans showed ossification lesions around the condyle, and the bone cortex was destroyed (Fig 2A); MRI showed some calcification around the head of the condyle, hyper-

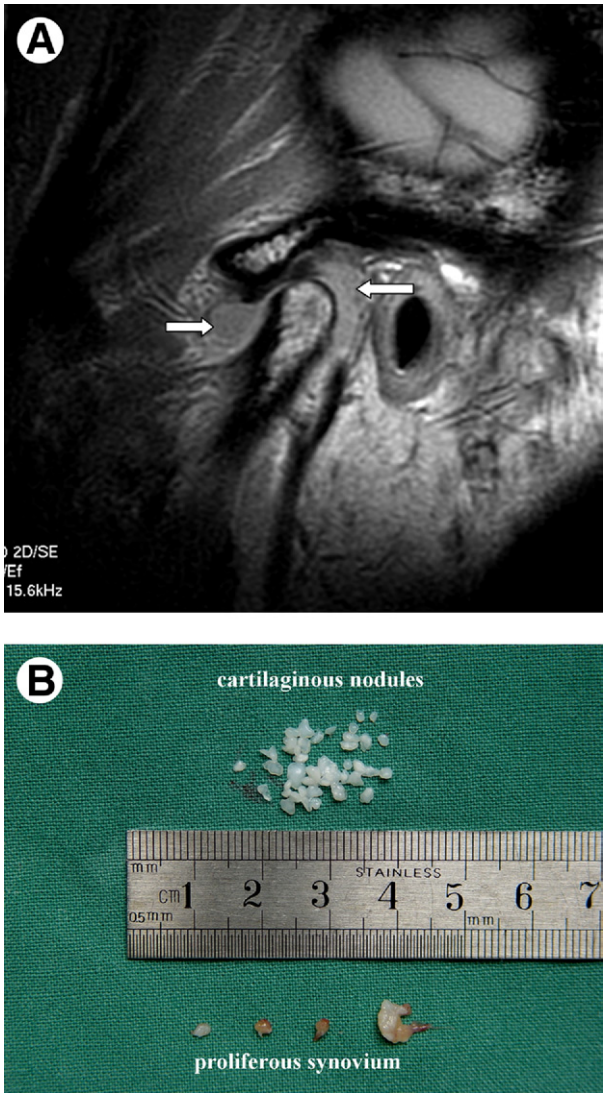

FIGURE 1. Clinical and radiologic findings of case 1.[17] *A*, Preoperative sagittal MRI showed the normal position of the disc, the normal contour of the condyle, and multiple loose bodies in the expanded inferior compartment. *B*, Loose bodies and synovium.

Chen et al. Synovial Chondromatosis in TMJ. J Oral Maxillofac Surg 2012.

trophy of the condyle, and normal position of the disc (Fig 2B). The third mode was found in case 5: CT scans and MRI showed sclerosis of the condyle with partial cupped absorption (Fig 3).

SURGICAL PROCEDURES AND SURGICAL FINDINGS

Before the operation, MRI showed a normal disc. Because the details of the disc would be disclosed during the operation only, the patients were told that the disc would be removed in case it was involved. During the operation, we found that all superior compartments were intact and the position of the discs was normal without perforation.

In case 1 many cartilaginous nodules of various sizes were floating in the inferior joint compartment. All loose bodies and grossly abnormal synovium were removed (Fig 1B). In case 2 condylectomy with the mass was performed. There was no invasion into the surrounding soft tissues including the attachment of the disc and the external pterygoid muscle. A costochondral graft (CCG) from the seventh contralateral rib was harvested and then fixed by use of an endoscope.[19] Numerous loose bodies with diameters ranging from 2 to 7 mm were conglutinated to the neck of the condyle (Fig 4). The cartilage surface of the condyle was destroyed. In case 3 and case 4, after the inferior joint space was opened, multiple calcified, small nodules were found between the disc and the condyle. Small nodules could not be detached from

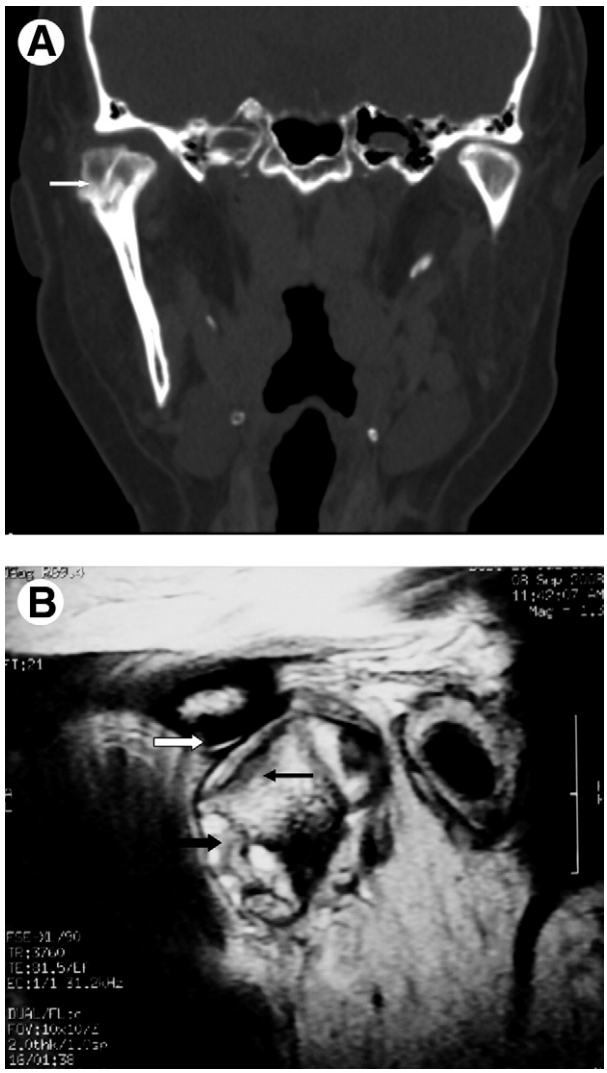

FIGURE 2. Preoperative radiologic examination of case 2 and case 3. *A*, Coronal CT scan showed several calcified bodies (*arrow*) at the lateral part of the right condyle. *B*, MRI showed the normal position of the disc (*white arrow*), severe osteoarthrosis of the condyle (*thin black arrow*), and some calcification (*thick black arrow*) in the expanded inferior compartment.

Chen et al. Synovial Chondromatosis in TMJ. J Oral Maxillofac Surg 2012.

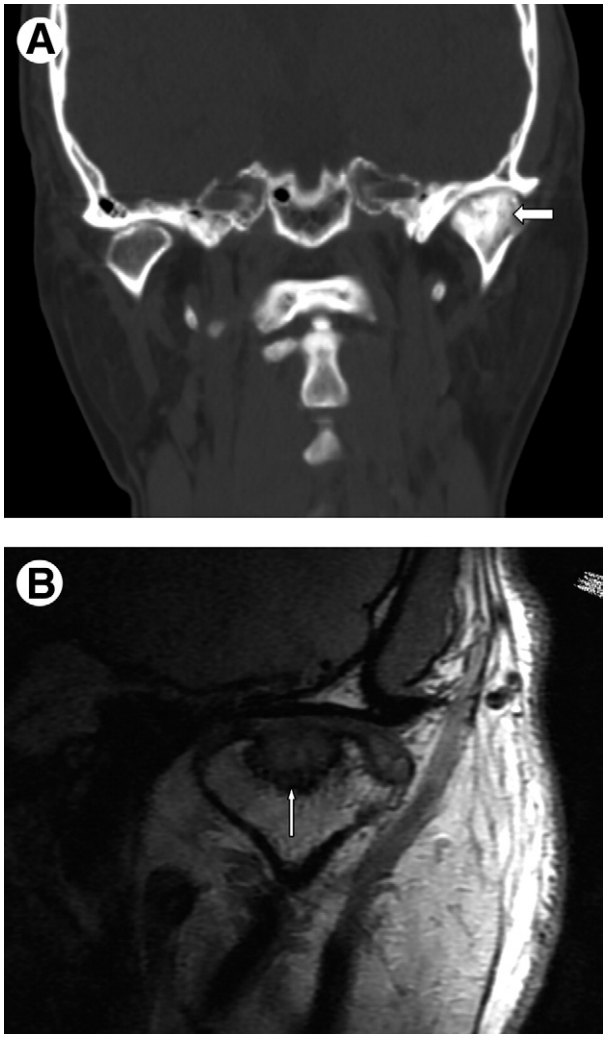

FIGURE 3. Preoperative radiologic examination of case 4. *A*, CT scan showed sclerosis of the left condyle (*arrow*). *B*, MRI showed partial sunk absorption (*arrow*) on the surface of the condyle.

Chen et al. Synovial Chondromatosis in TMJ. J Oral Maxillofac Surg 2012.

the inferior surface of the disc and the condyle (Figs 5A, 5B). There was bony erosion in the condylar head. As a result of our findings, both condylectomy and discectomy were performed. The pedicled deep temporal fascial fat flap (DTFFF) was transferred into the joint space to reconstruct the disc and CCG was harvested to reconstruct the condyle (Fig 5C). In case 5 a perforation was found at the superficial condyle. There were no loose bodies, but an irregular, semitransparent, jelly-like substance filled the inferior compartment and the cupped bony defect (Fig 6). The lesion was not confirmed by frozen sections. Condylectomy together with discectomy was performed. The pedicled DTFFF and CCG were harvested to reconstruct the joint. The diagnosis of SC was confirmed by histologic examination (Fig 7).

According to the radiologic and surgical findings, case 1 was in stage 1, case 2 was in stage 2, and case 3, case 4, and case 5 were all in stage 3.

FOLLOW-UP RESULTS

With 3 months of physical therapy, good outcomes occurred with respect to mandibular maximum interincisal opening (mean, 35.6 mm) without pain. CT and MRI scans were re-examined. Good positioning of the CCG and/or pedicled DTFFF was found. The disease had not recurred during the follow-up period.

Discussion

SC in the inferior compartment of the TMJ is extremely rare. MRI has been described as a helpful tool in defining the condition, based on the intactness of the disc. Six cases have previously been reported.[6-11] In these cases the signs and symptoms were pain, swelling, decreased mandibular range of motion, crepitus, and malocclusion, which were nonspecific. From radiographic findings, only 1 case displayed multiple loose bodies with expansion of the inferior compartment, and 5 cases that were easily misdiagnosed as malignant bony tumor displayed condylar erosion or extension. The treatment of SC in the inferior compartment of the TMJ is frequently problematic. The patient with multiple loose bodies was treated by loose body removal. In the other 5 cases with condylar erosion, 4 were treated by high condy-

FIGURE 4. Gross appearance of mass in case 2. Numerous loose bodies, ranging in diameter from 2 to 7 mm, were conglutinated to the neck of the condyle.

Chen et al. Synovial Chondromatosis in TMJ. J Oral Maxillofac Surg 2012.

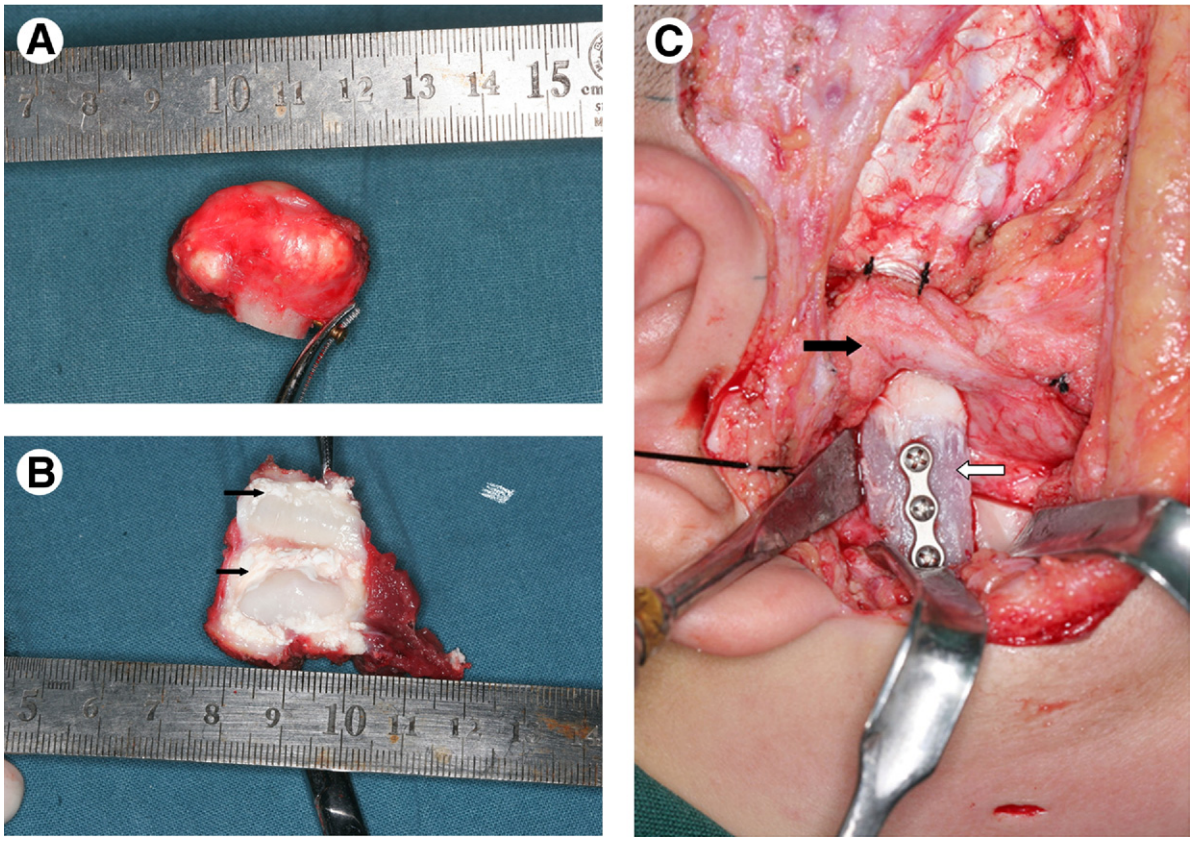

FIGURE 5. Gross appearance of mass and operative view in case 3. *A*, Condylectomy together with meniscectomy was performed. *B*, Small nodules could not be detached from the inferior surface of the disc and the condyle (black arrows). *C*, Pedicled DTFFF (black arrow) was transferred to reconstruct the disc, and CCG (white arrow) was fixed to reconstruct the condyle.

Chen et al. Synovial Chondromatosis in TMJ. J Oral Maxillofac Surg 2012.

lectomy and 1 underwent reconstruction with CCG. There are 5 cases described in our report. Thus, this is the largest series of SC in the inferior compartment found in the literature.

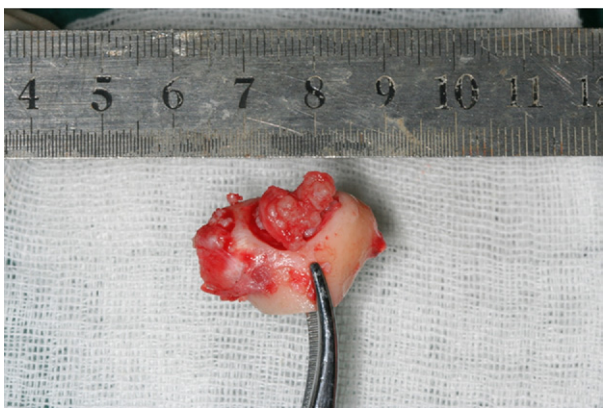

FIGURE 6. Gross appearance of mass in case 4. A perforation was found at the superficial condyle. No loose bodies were found, but an irregular, semitransparent, jelly-like substance filled the inferior compartment and the cupped bony defect.

Chen et al. Synovial Chondromatosis in TMJ. J Oral Maxillofac Surg 2012.

It is generally accepted that the recurrence of SC is likely if cartilaginous foci or hyperplastic synovium is left behind. The stage of the disease at the time of treatment is an important risk factor for recurrence. There are 2 histopathologic classifications of SC in the literature. One is the classification of Milgram,[20] which is based on the relationship between the cartilage foci and the synovium. He classified the disease into 3 developmental stages. Stage 1 shows active chondrogenic metaplasia with the foci of cartilage embedded within or protruding from the synovium, but without any detached particles. Stage 2 shows loose bodies containing active chondrocytes that maintain their growth potential. Stage 3 shows that only detached particles exist in the joint space; no intrasynovial disease is present. Some authors believe the treatment should be more aggressive in the first or second stage.[21,22] The other classification is that of Gerard et al,[23] which is based on the synovial activity of the disease without considering the loose bodies in the joint cavity. Stage 1 is characterized by the presence of cartilaginous or fibrocartilaginous nodules with plenty of ground substance in the synovium.

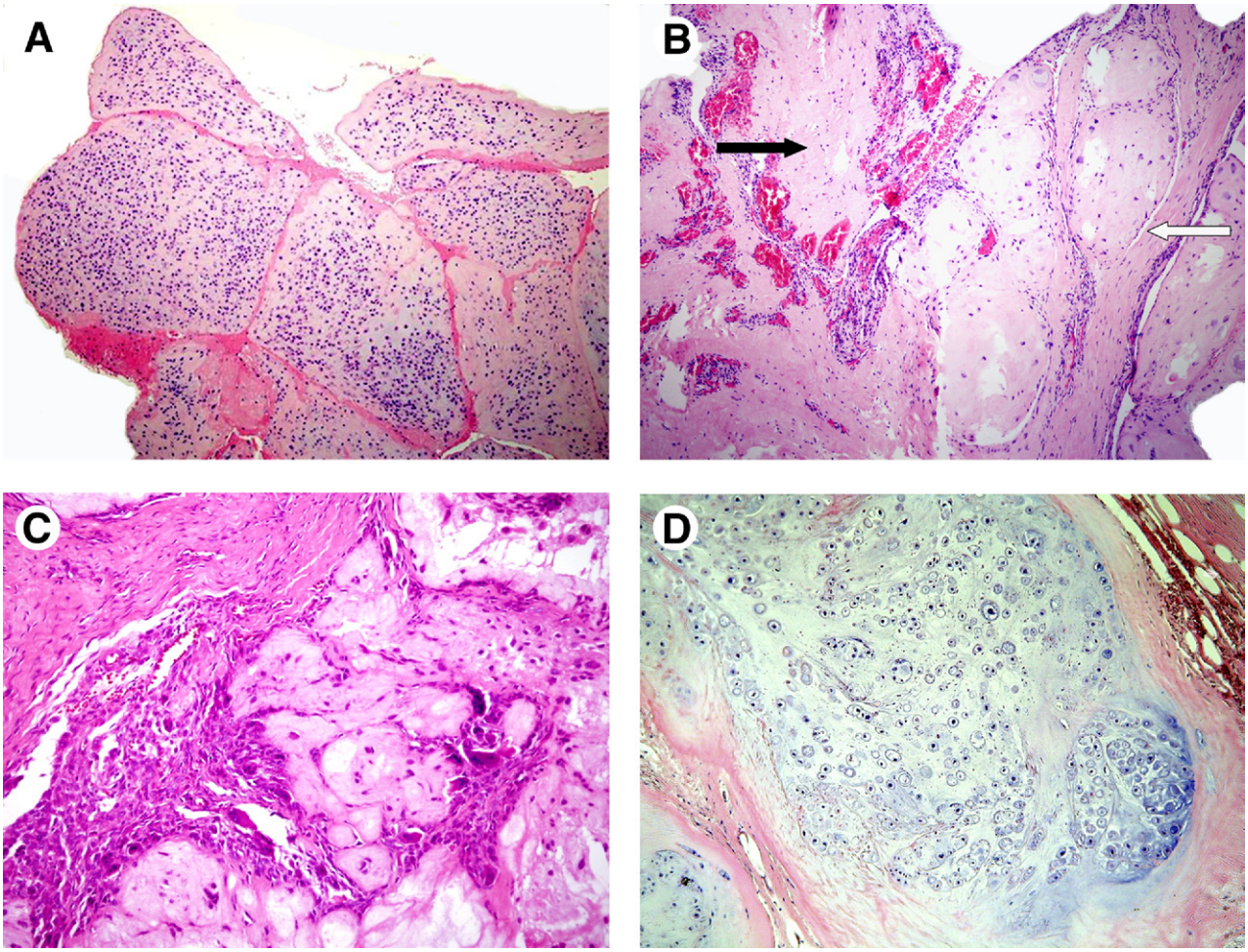

FIGURE 7. Histologic views of cases 1, 2, 4, and 5 (hematoxylin-eosin staining). *A*, Case 1 showed many cartilaginous immature nodules with a lining of synovium-like connective tissue (original magnification ×100).[17] *B*, Case 2 showed exophytic nodular growth of mature (*white arrow*) and immature (*black arrow*) hyaline cartilage (original magnification ×100). *C*, Case 4 showed a core of hyaline cartilage surrounded by a fibrous capsule with a synovial internal lining (original magnification ×200). *D*, Case 5 showed mature hyaline cartilage surrounded by a fibrous capsule (original magnification ×200).

Chen et al. Synovial Chondromatosis in TMJ. J Oral Maxillofac Surg 2012.

Stage 2 is the most active stage of synovial metaplasia, in which a very thick synovium with numerous small calcification or ossification cartilaginous nodules is present. In stage 3 active metaplasia is finished; the nodules are large and mostly ossified. In stage 4 the synovium is nearly normal or atrophic without any signs of metaplasia. Gerard et al concluded that surgical excision should be more aggressive in early-active stages.

Although histopathologic examination seems the only certain way of providing staging information, some clinical, radiographic, and operative data can be used to predict the stage of the disease. We thought that the extension of the lesion was more important in deciding on the surgical therapy used. We classified SC in the inferior compartment of the TMJ into 3 stages based on the extension of the lesion. Stage 1 means that the synovium is involved, stage 2 means that the synovium and condyle are involved, and stage 3 means that the synovium, condyle, and disc are involved. Interestingly, our 5 cases represented 3 stages of SC in the inferior compartment of the TMJ. Case 1 was in stage 1, case 2 was in stage 2, and case 3, case 4, and case 5 were in stage 3. Compared with the traditional classification, which is based on histopathologic examination, our classification is more useful to guide the treatment during the operation.

Different stages indicate that different structures are involved. Thus, we would also expect that different stages have different treatment principles.[5] In stage 1 only the synovium is involved. So, removal of loose bodies and affected synovium is generally enough. In stage 2 the synovium and condyle are involved, and thus condylectomy should be performed and CCG harvested to reconstruct the condyle. In stage 3 the synovium, condyle, and disc are all

involved. As a result, condylectomy together with discectomy should be performed. The pedicled DTFFF and CCG are harvested to reconstruct the joint. Compared with condylar recontouring or high condylectomy, CCG reconstruction could maintain the height of the ramus. We treated our 5 cases according to these principles. The procedures were well received, and no recurrence occurred. The height of the ramus and the occlusion were maintained in the same condition as preoperatively.

Given the low incidence of SC in the inferior compartment, there have been no large and controlled studies to support the benefits of different treatments. On the basis of our study, we conclude that our new classification of SC in the inferior compartment of the TMJ can better guide clinical treatment.

Acknowledgment

We express our thanks to Didi Zhang for her helpful revisions of our manuscript.

References

1. Yu Q, Yang J, Wang P, et al: CT features of synovial chondromatosis in the temporomandibular joint. Oral Surg Oral Med Oral Pathol Oral Radiol Endod 97:524, 2004
2. Ida M, Yoshitake H, Okoch K, et al: An investigation of magnetic resonance imaging features in 14 patients with synovial chondromatosis of the temporomandibular joint. Dentomaxillofac Radiol 37:213, 2008
3. Holmlund AB, Eriksson L, Reinholt FP: Synovial chondromatosis of the temporomandibular joint: Clinical, surgical and histological aspects. Int J Oral Maxillofac Surg 32:143, 2003
4. Fernández Sanromán J, Costas López A, Antón Badiola I, et al: Indications of arthroscopy in the treatment of synovial chondromatosis of the temporomandibular joint: Report of 5 new cases. J Oral Maxillofac Surg 66:1694, 2008
5. Ardekian L, Faquin W, Troulis MJ, et al: Synovial chondromatosis of the temporomandibular joint: Report and analysis of eleven cases. J Oral Maxillofac Surg 63:941, 2005
6. Forssell K, Happonen RP, Forssell H: Synovial chondromatosis of the temporomandibular joint. Report of a case and review of the literature. Int J Oral Maxillofac Surg 17:237, 1988
7. Dolan EA, Vogler JB, Angelillo JC: Synovial chondromatosis of the temporomandibular joint diagnosed by magnetic resonance imaging: Report of a case. J Oral Maxillofac Surg 47:411, 1989
8. Shibuya T, Kino K, Okada N, et al: Synovial chondromatosis of the left temporomandibular joint superficially resembling chondrosarcoma: A case report. Cranio 18:286, 2000
9. Kin HG, Park KH, Huh JK, et al: Magnetic resonance imaging characteristics of synovial chondromatosis of the temporomandibular joint. J Orofac Pain 16:148, 2002
10. Huh JK, Park JY, Lee S, et al: Synovial chondromatosis of the temporomandibular joint with condylar extension. Oral Surg Oral Med Oral Pathol Oral Radiol Endod 101:e83, 2006
11. Zha W, Zhao YF, Liu Y, et al: A case of synovial chondromatosis of the temporomandibular joint secondary to preauricular trauma. Int J Oral Maxillofac Surg 38:1212, 2009
12. Sato J, Notani KI, Goto J, et al: Synovial chondromatosis of the temporomandibular joint accompanied by loose bodies in both the superior and inferior joint compartments: Case report. Int J Oral Maxillofac Surg 39:86, 2010
13. Von Lindern JJ, Theuerkauf I, Niederhagen B, et al: Synovial chondromatosis of the temporomandibular joint: Clinical, diagnostic, and histomorphologic findings. Oral Surg Oral Med Oral Pathol Oral Radiol Endod 94:31, 2002
14. Sembronio S, Albiero AM, Toro C, et al: Arthroscopy with open surgery for treatment of synovial chondromatosis of the temporomandibular joint. Br J Oral Maxillofac Surg 46:582, 2008
15. Petito AR, Bennett J, Assael LA, et al: Synovial chondromatosis of the temporomandibular joint: Varying presentation in 4 cases. Oral Surg Oral Med Oral Pathol Oral Radiol Endod 90: 758, 2000
16. Koyama J, Ito J, Hayashi T, et al: Synovial chondromatosis in the temporomandibular joint complicated by displacement and calcification of the articular disk: Report of two cases. AJNR Am J Neuroradiol 22:1203, 2001
17. Chen MJ, Yang C, Zhang XH, et al. Synovial chondromatosis originally arising in the lower compartment of temporomandibular joint: A case report and literature review. J Craniomaxillofac Surg 39:459, 2011
18. Cai XY, Yang C, Chen MJ, et al: Simultaneous pigmented villonodular synovitis and synovial chondromatosis of the temporomandibular joint: Case report. Int J Oral Maxillofac Surg 38:1215, 2009
19. Qiu YT, Yang C, Chen MJ: Endoscopically assisted reconstruction of the mandibular condyle with a costochondral graft through a modified preauricular approach. Br J Oral Maxillofac Surg 48:443, 2010
20. Milgram JW: Synovial osteochondromatosis: A histopathological study of thirty cases. J Bone Joint Surg Am 59:792, 1977
21. Aydin MA, Kurtay A, Celebioglu S: A case of synovial chondromatosis of the TMJ: Treatment based on stage of the disease. J Craniofac Surg 13:670, 2002
22. Miyamoto H, Sakashita H, Wilson DF, et al: Synovial chondromatosis of the temporomandibular joint. Br J Oral Maxillofac Surg 38:205, 2000
23. Gerard Y, Shall A, Ameil M: Synovial osteochondromatosis. Therapeutic indications based on a histological classification. Chirurgie 119:190, 1993 (in French)