

原文題目(出處)：	Bisphosphonate-associated osteonecrosis of jaw: Are we dealing with a localized non-traditional calciphylaxis ? The Open Dent J 2012;6,5-7
原文作者姓名：	Meiller TF, Almubarak H, Weikel DS, Brahim J and Scheper MA
通訊作者學校：	University of Maryland, Baltimore, USA
報告者姓名(組別)：	徐浩訓 Intern J 組
報告日期：	101/6/22

內文：

### Introduction:

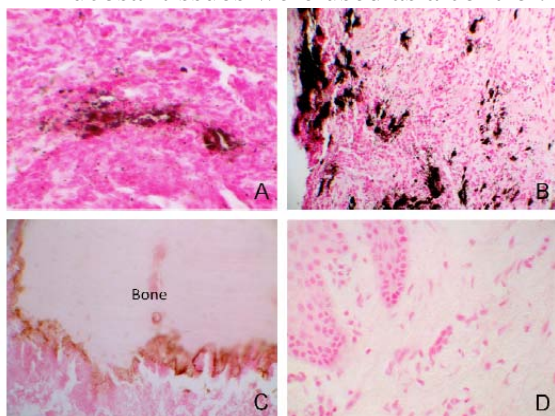
- ◆ ONJ lacks a defined pathophysiologic mechanism.
- ◆ Hypothesis, a potentially distinct and complementary mechanism of initiation and persistence of ONJ, secondary to a local non-traditional calciphylaxis through vascular and soft tissue calcium deposition

### Material and methods:

- ◆ found 10 cases of diagnosed ONJ which contained adjacent soft tissue. Paraffin embedded tissue sections from these 10 stage 3 (AAOMS) ONJs in cancer patients using zoledronic acid (bone and adjacent soft tissue), were first evaluated using hematoxylin and eosin stain for accurate diagnosis. Next, unstained sections were deparaffinized, immersed in ethanol 100% and 95%, washed with distilled H<sub>2</sub>O and incubated with 1% silver nitrate solution under UV light for 2 hours. The sections were then washed with distilled H<sub>2</sub>O and 5% sodium thiosulfate for 5 minutes. Next the sections were counterstained with nuclear fast red for 5 minutes. As a negative control, sections were treated with phosphate-buffered saline with omission of the von Kossa stain. Additionally, five normal archived oral mucosal tissues were used as a control. The von Kossa staining was reviewed by two independent, certified Oral Pathologists.

### Results:

- ◆ Using von Kossa staining, we demonstrated the presence of calcium in 8 of the 10 ONJ cases within the connective tissue and surrounding blood vessels. All of these cases demonstrated a significant delay in ONJ wound healing. The bone within these specimens also demonstrated the presence of calcium at their leading edge where BP would typically bind to calcium phosphate since they are considered analogs of pyrophosphate (Fig. 1C). Five normal archived oral mucosal tissues were used as a control. (Fig. 1D).



### Discussion

- ◆ Calciphylaxis is classically defined as a multifactorial renal phenomenon, whereby microcalcification of small blood vessels leads to soft tissue ischemia,

- necrosis and nonhealing lesions
- ◆ Calciphylaxis is frequently fatal and is seen most often at end-stage renal failure.
  - ◆ In certain hypercalcemic states, such as malignancy (Breast and Multiple Myeloma), hyperparathyroidism, cirrhosis, Crohns and collagen disease conditions, a nonuremic non-traditional calciphylaxis is shown to induce vascular and tissue deposition of calcium in the submucosal tissues . This complication must surpass a critical threshold of sensitizing conditions (e.g. hypercalcemia and inflammation of malignancy; and BP and corticosteroid use) and thrombogenic stimuli (e.g. dental trauma).
  - ◆ The mandible is a primary site for BP saturation and is commonly affected by trauma, infection and inflammation; an acidic microenvironment would release free BP from bone and secondarily release calcium from its BP bound state to induce oral mucosal apoptosis/necrosis
  - ◆ Clinically, ONJ is observed as a mucosal dehiscence leading to the formation of a superficial mucosal ulcer, which continues to extend with time and results in detectable bone exposure, necrosis and sequestration.
  - ◆ Like calciphylaxis, these lesions typically present as non-healing wounds treated empirically. Once a lesion occurs, there is tremendous difficulty in treating these lesions, which leads to delayed or refusal of dental treatment and discontinuation of necessary cancer therapy.
  - ◆ The only therapeutic regimen is antimicrobial therapy, with surgical interventions reserved only for severe cases. Therefore, a tetralogical cascade must exist, including a combination of effects on bone, vasculature, microbial biofilm and oral mucosal soft tissues, especially in wound healing.

**Conclusion**

- ◆ Part of the treatment regimen for calciphylaxis includes antibiotics and rebalancing calcium and phosphate, while avoiding local tissue trauma, similar to ONJ.
- ◆ the standard therapeutic regimen for ONJ, amoxicillin, is not affected by calcium and appears to have better success than tetracyclines which lose activity in the context of high calcium levels.
- ◆ balancing the calcium and phosphate levels, and creating a neutral pH, along with the standard of care therapy of eliminating the bacterial load, may become a translational model for investigating potential pathogenesis directed therapeutics.

題號	題目
1	What is the most prevalent site of BRONJ? (A) Mandible (B) Maxilla (C) Skull (D) Rib
答案(A)	出處：Oral & Maxillofacial pathology P.300
題號	題目
2	What is the contraindication of a patient with BRONJ? (A) Orthodontic treatment (B) OD (C) Prothodontic treatment (D) Orthognathic surgery
答案(D)	出處：Oral & Maxillofacial pathology P.302