ORAL SURGERY

Oral Surgery ISSN 1752-2471

CASE REPORT

Removal of ectopic mandibular third molar teeth: literature review and a report of three cases

N.M. Ahmed[1] & B. Speculand[1]

[1]Oral and Maxillofacial Surgery, University Hospital Birmingham NHS Trust, Birmingham, UK

Key words:
extraction, mandible, surgery, third molar

Correspondence to:
Miss NM Ahmed
STR Orthodontics
Leeds Dental Institute
Clarendon Way
Leeds LS2 9LU
UK
Tel.: +44 01133 431585
Fax: +44 01133 436282
email: nm.ahmed@yahoo.co.uk

Accepted: 21 October 2011

doi:10.1111/j.1752-248X.2011.01145.x

Abstract

This article reviews 23 published cases of ectopic mandibular third molar teeth. We report three further cases and discuss the surgical approaches which can be used for their removal.

Introduction

Unerupted impacted mandibular third molar teeth occur in 20–30% of the population, with a higher prevalence in women[1].

Mandibular third molars tend to occupy an abnormal position because of lack of space in the posterior mandible. The cause of their malposition is unclear although many theories have been put forward. During mandibular development as the ramus elongates and grows upward, it may take the tooth germ with it. The development of an associated cyst or tumour may push the tooth into an abnormal position as the cyst grows[2–7]. When the tooth is grossly displaced, for example up into the ramus or down below the level of the mandibular nerve, it may be referred to as ectopic. The majority of ectopic mandibular third molars are associated with cystic lesions. Other proposed causes include a lack of space between the second molar and ramus of the mandible[8], trauma and aberrant eruption[6].

Ectopic mandibular third molars are rare and the aetiology remains unclear. The normal position for a third molar is distal to the second molar, however ectopic positions include: condyle, ramus, coronoid process, sigmoid notch and lower border of the angle of the mandible.

These teeth are often an incidental finding on a routine radiograph and no treatment is required unless they are symptomatic or have associated pathology.

The purpose of this article is to review the literature on ectopic mandibular third molar teeth and to present three cases involving four ectopic lower third molars treated in our department which illustrate different surgical approaches for their removal.

Statement of clinical relevance: This article describes the techniques which can be used for removal of ectopic mandibular third molar teeth located low-down or high-up in the ramus of the mandible, including appropriate extra-oral approaches. We reviewed 23 cases from 21 papers and present an additional three patients with four ectopic lower third molars to illustrate why and how such ectopic teeth may be removed.

Literature review

We searched Pubmed via Medline using the following key search terms: 'ectopic third molar' and most non-English language papers were excluded. This initial

© 2011 John Wiley & Sons A/S

Table 1 Published cases of ectopic mandibular third molar teeth in chronological order

Author	Position tooth	Signs and symptoms	Management	Age patient	Sex patient
Szerlip 1978[7]	Subcondylar region	Trismus, pain, swelling	Intra-oral	50	F
Markowitz *et al*. 1979[9]	Bilateral: ramus	Facial pain right side	Intra-oral	23	F
Burton and Scheffer 1980[10]	Bilateral: Condyle and high ramus	Painful swelling left side	Left side- extra-oral Right side- intra-oral	57	F
Srivastava and Singh 1982[5]	Condylar neck	Discharging sinus left pre-auricular region	Sinus opened, ectopic tooth left in condyle, parotid gland dissected out	40	F
Muller 1983[11]	Coronoid process	Incidental finding	Intra-oral	38	M
Chongruk 1991[12]	Coronoid process	No gross disease	No treatment	27	F
Balan 1992[13]	Sigmoid notch	Pre-auricular pain	Not specified	30	F
Toranzo Fernandez and Terrones Meraz 1992[6]	Ramus	Swelling, pain, trismus	Not specified – 'excised surgically'	70	F
Bux and Lisco 1994[3]	Subcondyle	Painful swelling with draining sinus, trismus, fever, difficulty in mastication	Extra-oral submandibular access	66	F
Adams and Walton 1996[2]	Angle/ posterior body	Discomfort and unpleasant tasting discharge	Follow up long term	45	F
Medici *et al*. 2001[4]	Condylar process	Right TMJ pain, difficulty in mastication/ mouth opening, pre-auricular swelling	Intra-oral with removal coronoid process	41	F
Turner *et al*. 2002[14]	Subcondyle	Recurrent right-sided swelling	Extra-oral pre-auricular	47	M
Suarez-Cunquiero *et al*. 2003[15]	Condylar neck	Pain, swelling	Endoscopic intra-oral	45	M
Wassouf *et al*. 2003[16]	Condylar neck	Painful swelling left massetricomandibular area, tenderness to palpation left angle of mandible	Extra-oral pre auricular	47	M
Jones *et al*. 2004[17]	Angle?	Chronic infection/ discharging sinus, facial swelling, trismus	SSO	48	M
Wang *et al*. 2008[1]	Ascending ramus	Right-sided facial swelling	Intra-oral	31	F
Salmeron *et al*. 2008[18]	Condylar neck	Pre-auricular pain and swelling	Endaural approach	53	F
Salmeron *et al*. 2008[18]	Condylar neck	Pre-auricular swelling	Extra-oral (pre-auricular)	41	M
Naaj *et al*. 2010[19]	Angle/ posterior body	Pain, swelling, discharging fistula	Extra-oral	43	M
Bortoluzzi and Manfro 2010[20]	Subcondyle	Pain, swelling, purulent discharge right side of face	Intra-oral	64	F
Gadre and Waknis 2010[21]	Condyle	Pre-auricular pain, swelling on right side	Intra-oral	30	F
Gadre and Waknis 2010[21]	Condyle	Left sided facial swelling, pain	Intra-oral	40	M
Pace *et al*. 2010[22]	Subcondylar region	Erythematous skin swelling/ discharging sinus	Extra-oral (retromandibular)	53	M

literature review yielded a review paper[1] which helped to identify some further papers.

We found 23 cases reported in 21 papers from 1976 to 2010, the majority of these were single (Table 1). Of the 23 cases, the mean age for presentation was 44.7 years (range 23–70 years).

With regard to site, eight of the ectopic mandibular third molars were located in the condyle, five were described as subcondylar, three in the angle, three in the ramus (one of which was bilateral) two in the coronoid process, one at the sigmoid notch, and one bilateral case was described as being in the condyle and ramus.

The common presentation was found to be that of pain and swelling, and others included in decreasing frequency trismus, a sinus, difficulty in mastication, discharge, fever, TMJ pain and a discharging fistula.

Of the 23 cases, 18 had removal of the ectopic mandibular third molars, two did not have any treatment, one did not specify the treatment, one was excised surgically and no further details were given, and one specified the tooth was left in the condyle and the parotid gland was dissected out. The common approaches for removal in decreasing frequency were the conventional intra-oral approach (including one endoscopic) an extra-oral approach

© 2011 John Wiley & Sons A/S

(pre-auricular or submandibular) and sagittal split osteotomy.

Cases

We present three cases seen in our department which illustrate different surgical approaches for the removal of these teeth.

Case 1

A 38-year-old female who was medically fit and well was referred from Birmingham Dental Hospital to the Oral and Maxillofacial Unit at Queen Elizabeth Hospital, Birmingham.

She presented with recurrent pain, bad taste and left-sided facial swelling for which several courses of antibiotics had been prescribed.

On extra-oral examination, a swelling was noted at the angle of the mandible with a discharging sinus adjacent to the lower third molar intra-orally.

An orthopantomogram (OPT) was taken which showed an ectopic mandibular third molar at the posterior border of the left angle of the mandible, with an associated coronal radiolucency (Fig. 1).

The tooth was removed surgically under general anaesthetic via an extra-oral approach (the Risdon neck approach) (Fig. 2). This approach involves incising through skin and superficial fascia and platysma and exposing the superficial surface of the masseter muscle. After checking for the position of the branches of the facial nerve, the muscle is incised horizontally to expose the mandible. The ectopic tooth is exposed and removed and the wound is then closed in layers.

Figure 1 Left side of orthopantomogram radiograph, case 1, showing ectopic mandibular third molar at the posterior border of the left angle of the mandible.

The histological specimen sent was reported as a dentigerous cyst. The patient was discharged from the clinic after a single post-operative visit.

Case 2

A 52-year-old female was also referred from Birmingham Dental Hospital to the Oral and Maxillofacial Unit at Queen Elizabeth Hospital, Birmingham. She was medically fit and well.

She presented with pain, trismus and a recurrent right-sided facial swelling which failed to resolve following five courses of antibiotics. This was initially thought to be due to a parotid infection.

Extra-oral examination revealed a discharging sinus at the right angle of mandible and a radiograph (Fig. 3) revealed an impacted lower-right third molar in the sigmoid notch/high ramus region of the mandible.

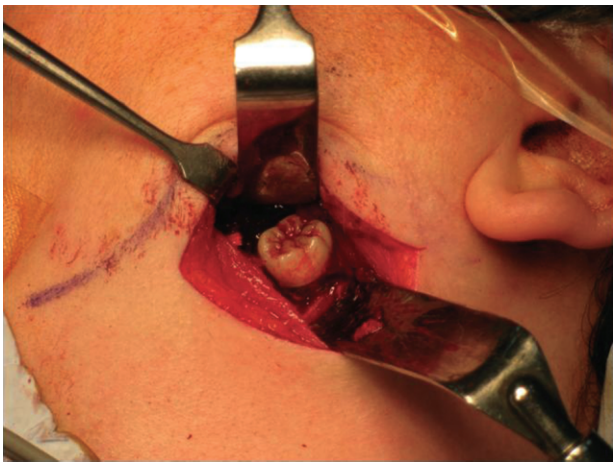

Figure 2 Extra-oral approach, case 1.

Figure 3 Right side of orthopantomogram radiograph, case 2, showing ectopic mandibular third molar at sigmoid notch/high ramus region of right mandible.

© 2011 John Wiley & Sons A/S

Figure 4 Extra-oral approach, case 2.

The tooth was removed under a general anaesthetic also via an extra-oral Risdon neck approach. Dissection through masseter muscle revealed a buccal perforation of the mandibular ramus (Fig. 4). The tooth was removed surgically and the associated cyst was enucleated. An extra-oral drain was placed.

The patient made good post-operative recovery although she had mild buccal branch weakness which recovered after a few weeks. Four-monthly review indicated good bony infill. Complete healing could be seen at 18 months on the OPT. The pathology was reported as a radicular cyst.

Case 3

A 36-year-old female with mild asthma presented with pain and recurrent intra-oral infection which had not resolved after several courses of oral broad spectrum antibiotics.

Extra-oral examination was unremarkable, although inflammation was noted in the retro-molar trigone area bilaterally. A computed tomography (CT) scan (Fig. 5) and OPT showed impacted lower third molars in the ramus of the mandible bilaterally.

The patient opted to have these teeth extracted and the procedure was carried out under a general anaesthetic via an extended lower third molar intra-oral incision bilaterally, extending up the ramus of the mandible.

Both teeth were removed surgically and the associated cysts were enucleated. Both inferior dental nerves (IDNs) were visualised and protected. The patient made a good post-operative recovery.

At the 1-month review the patient had moderate paraesthesia of both IDNs. The histopathology was reported as dentigerous cyst for both.

Figure 5 Axial CT slice, case 3, showing bilateral ectopic third molar teeth in right and left ramus of the mandible.

Discussion

Management of ectopic mandibular third molars is dependent on several key factors such as signs, symptoms and associated pathology, which are listed as indications for extraction of third molars in the National Institute of Health and Clinical Excellence guidelines. Pathology in the mandibular ramus and condyle can lead to serious complications such as condylar resorption, osteolysis and even condylar fracture[4,7]. Once a decision has been made to extract the ectopic tooth, access can be achieved either intra- or extra-orally.

An OPT or postero-anterior (PA) mandible radiographs allow initial assessment but a more detailed investigation such as a CT scan is often carried out to determine the position of the ectopic tooth accurately, especially if it lies in the ramus of the mandible. This allows the clinician to assess the depth of the impaction, the relationship with the neurovascular bundle, and helps in surgical planning.

With increasing availability of small volume Cone Beam CT, this modality may be used more commonly in the future to locate the position of an ectopic lower third molar with better resolution and less radiation exposure than conventional CT scans.

The mean age of affected patients from our literature review was 44.7 years (range 23–70 years) compared with a mean age of 42 years in our reported cases (range 36–52 years).

© 2011 John Wiley & Sons A/S

All but two of the reviewed cases of ectopic mandibular third molars were symptomatic and presented with pain and repeated mandibular swelling, and several with a draining sinus extra-orally or intra-orally. The anatomic position of the ectopic third molar may irritate the temporalis muscle fibres and cause pain during mastication[23]. All three of our cases had repeated infections treated with several courses of antibiotics. One of our cases had an external sinus draining at the angle of the mandible.

All of our cases were associated with cyst formation. In adults, a dentigerous cyst is the most common benign lesion associated with an impacted mandibular third molar[2]. The treatment of choice is enucleation and removal of the impacted tooth. Spontaneous resolution of the cyst is unlikely. In addition to displacement of the tooth, cystic involvement of an impacted or unerupted third molar may result in expansion of bone causing facial asymmetry, resorption of roots of adjacent teeth and loss of bone in the ramus, extending as far as the coronoid process and condyle[10].

Two of our reported cases were managed by extra-oral removal and one by intra-oral removal.

There are four surgical approaches which have been reported:

Sagittal split osteotomy (one case)[17]

This is useful where extensive removal of alveolar bone would be required[17]. This approach allows direct visualisation of the tooth and good exposure of the surgical site. There is a 22–78% incidence of post-operative immediate IDN damage, falling to 5–26% after 6 months[24].

Intra-oral approach (eight cases)[1,4,7,9–11,20,21]

This is not possible if there is a limited surgical field or poor visualisation in an inaccessible region such as the lower border of the mandible[19]. The intra-oral approach is a more cosmetic approach with no skin scar. However there is a high risk of damage to the IDN significant alveolar bone loss and risk of damage to adjacent teeth[19]. In some cases, removal of the coronoid process may help[4,16].

Extra-oral approach (eight cases)[3,10,14,16,18,19,22]

This is usually either submandibular or pre-auricular. Teeth high in the ramus, condyle or at the lower border of the mandible may require an extra-oral approach. Two of our three cases were removed extra-orally. This approach allows good exposure of the surgical site, more control over the surgical plane, less bone removal and a lower chance of pathological fracture. However there will be a skin scar and there is a risk of damage to the marginal mandibular branch of the facial nerve[19].

If the ectopic tooth is located below the level of the IDN then an extra-oral approach may be preferable.

Endoscopic approach (one case)[15]

The use of fibre optic technology and minimal access surgery has allowed some cases to be treated with endoscopy. The advantages of this more conservative approach are said to include access to a surgical site which would otherwise be difficult to reach via an intra-oral approach, good illumination and magnification of the surgical area, a smaller scar and decreased risk of damage to the facial nerve[15]. This technique may not be indicated in all cases.

Conclusion

Ectopic mandibular third molar teeth are uncommon and may not be detected unless symptoms occur. Whilst some can be removed by an intra-oral approach, both the literature and our own experience have shown that an extra-oral approach to the lower border, ramus or condylar regions of the mandible may be required.

Acknowledgement

We would like to thank Mr Rhodri Williams, Consultant Oral and Maxillofacial Surgeon at University Hospitals Birmingham, for allowing us to include Case 3 in this article.

Conflict of interest

Funding: None.
Competing interests: None declared.
Ethical approval: None declared.

References

1. Wang C, Kok S, Hou L, Yang P, Lee J, Cheng S *et al*. Ectopic mandibular third molar in the ramus region: report of a case and literature review. Oral Surg Oral Med Oral Pathol Oral Radiol Endod 2008;105:155–61.
2. Adams AM, Walton AG. Case report. Spontaneous regression of a radiolucency associated with an ectopic mandibular third molar. Dentomaxillofac Radiol 1996;25:162–4.

© 2011 John Wiley & Sons A/S

3. Bux P, Lisco V. Ectopic third molar associated with a dentigerous cyst in the subcondylar region: report of case. J Oral Maxillofac Surg 1994;52:630–2.
4. Medici A, Raho MT, Anghinomi M. Ectopic third molar in the condylar process: case report. Acta Biomed Ateneo Parmense 2001;72:115–8.
5. Srivastava RP, Singh G. An unusual impacted inverted molar in mandibular condyle with preauricular sinus (a case report). J Indian Dent Assoc 1982;54:67–9.
6. Toranzo Fernandez M, Terrones Meraz MA. Infected cyst in the coronoid process. Oral Surg Oral Med Oral Pathol Oral Radiol Endod 1992;73:768.
7. Szerlip L. Displaced third molar with dentigerous cyst- an unusual case. J Oral Surg 1978;36:551–2.
8. Capelli JJ. Mandibular growth and third molar impaction in extraction cases. Angle Orthod 1991;61:223–9.
9. Markowitz NR, Wolford DG, Harrington WS, Monaco F. Bilateral vertical impacted third molars of the mid ramus. Oral Surg Oral Med Oral Pathol Oral Radiol Endod 1979;47:107.
10. Burton DJ, Scheffer RB. Serratia infection in a patient with bilateral subcondylar impacted third molars and associated dentigerous cysts: report of a case. J Oral Surg 1980;38:135–8.
11. Muller EJ. Tooth in coronoid process. Oral Surg Oral Med Oral Pathol Oral Radiol Endod 1983;55:327.
12. Chongruk C. Asymptomatic ectopic impacted mandibular third molar. Oral Surg Oral Med Oral Pathol Oral Radiol Endod 1991;71:520.
13. Balan N. Tooth in the sigmoid notch. Oral Surg Oral Med Oral Pathol Oral Radiol Endod 1992;73:767.
14. Turner C, Eset AE, Atabek A. Ectopic impacted mandibular third molar in the subcondylar region associated with a dentigerous cyst: a case report. Quintessence Int 2002;33:231–3.
15. Suarez-Cunquiero MM, Schoen A, Schramm A, Gellrich NC, Schmelzeisen R. Endoscopic approach to removal of an ectopic mandibular third molar. Br J Oral Maxillofac Surg 2003;41:340–2.
16. Wassouf A, Eyrich G, Lebeda R, Gratz KW. Surgical removal of a dislocated lower third molar from the condyle region: case report. Schweiz Monatsschr Zahnmed 2003;113:416–20.
17. Jones T, Monaghan A, Garg T. Removal of a deeply impacted mandibular third molar through a sagittal split ramus osteotomy approach. Br J Oral Maxillofac Surg 2004;42:365–8.
18. Salmeron JI, Del Amo J, Plasencia R, Pujol R, Vila CN. Ectopic third molar in condylar region. Int J Oral Maxillofac Surg 2008;37:398–400.
19. Naaj IA, Braun R, Leiser Y, Peled M. Surgical approach to impacted mandibular third molars- operative classification. J Oral Maxillofac Surg 2010;68: 628–33.
20. Bortoluzzi MC, Manfro R. Treatment for ectopic third molar in the subcondylar region planned with cone beam computed tomography: a case report. J Oral Maxillofac Surg 2010;68:870–2.
21. Gadre KS, Waknis P. Intra-oral removal of ectopic third molar in the mandibular condyle. Int J Oral Maxillofac Surg 2010;39:294–6.
22. Pace C, Holt D, Payne M. An unusual presentation of an ectopic third molar in the condylar region. Aust Dent J 2010;55:325–7.
23. Anagnostopoulou S. Ectopic third molar. Oral Surg Oral Med Oral Pathol Oral Radiol Endod 1991;71:522–3.
24. Yip L, Korczak P. Clinical audit on the incidence of inferior alveolar nerve dysfunction following mandibular sagittal split osteotomies at the Derby Royal Infirmary, England. Int J Adult Orthodon Orthognath Surg 2001;16:266–71.

© 2011 John Wiley & Sons A/S