ORAL SURGERY

Oral Surgery ISSN 1752-2471

CASE REPORT

Multiple myeloma with primary manifestation in mandibular area

P.S. da Silva Santos[1], M.F.G. Klingbeil[2], A.C. Abrahão[3], M. Gallottini[2] & S.C.O.M. de Sousa[2]

[1]Department of Stomatology, Bauru School of Dentistry, University of São Paulo, Bauru, Brazil
[2]School of Dentistry, University of São Paulo, Oral Pathology, São Paulo, Brazil
[3]School of Dentistry, Federal University of Rio de Janeiro, Oral Pathology, Rio de Janeiro, Brazil

Key words:
bone, diagnosis, mandible, pathology

Correspondence to:
Dr. Paulo Sérgio da Silva Santos
Bauru School of Dentistry
University of São Paulo
Department of Stomatology
Al. Dr. Octavio Pinheiro Brisolla, 9-75, Bauru – SP
Brazil
Tel.: +55 14 32358000
Fax: +55 14 32358254
email: paulosss@fob.usp.br

Accepted: 3 October 2011

doi:10.1111/j.1752-248X.2011.01141.x

Abstract

Multiple myeloma (MM) is a haematological disease characterised by the multicentric proliferation of plasma cells in the bone marrow. This relatively rare disease develops mainly in men (mean age, 60 years). The occurrence of the disease in jaws is uncommon as a primary manifestation. A 73-year-old man was first seen with a chief complaint of a painful mandibular enlargement persisting for 1 month with an increase in the volume of the gingiva, which bled during oral hygiene. The Xray revealed a 'punched-out' lesion with ill-defined margins in the mandibular ramus and body. A computed tomography scan showed a mandibular osteolytic lesion extending to the surrounding soft tissue. The incisional biopsy revealed a monotonous proliferation of plasmacytoid cells strongly immunoreactive to Kappa IgG, which confirmed the diagnosis of MM. After the biopsy, the patient spontaneously fractured his ribs, and the Bence Jones protein test was positive. Conformal radiotherapy followed by bortezomib with melphalan and prednisone was the elected treatment. The patient stopped treatment after two cycles, and progression to death followed after 6 months. This case report reinforces the data on the importance of early diagnosis of MM in the jaw and illustrates the contribution that oral assessment can provide for the diagnosis of this disease.

Multiple myeloma (MM) is a relatively rare, malignant haematological disease characterised by the multicentric proliferation of plasma cells in the bone marrow. It develops mainly in men aged 50–80 years, with a mean age of 60 years[1]. Its occurrence in the jaws is common; however, oral lesions rarely appear as the primary manifestation of the disease. The more common clinical manifestations are persistent pain in the bone, especially in the affected areas, a history of recurrent infection, fever, fatigue, haematological alterations, nephropathy and temporal arteritis[2]. More than 30% of patients with MM develop osteolytic lesions in the jaw[3]. Jaws lesions are usually more frequent in the posterior region of the mandible (molars and premolars), and pain may be the initial symptom of the disease. Manifestations such as gingival haemorrhage, odontalgia, paraesthesias, dental mobility, ulcerations and increased volume may also be present[4].

In 1992, Scutellari and Orzincolo reviewed 237 cases of MM, and the diagnosis was based on the following criteria: (1) an increased number of abnormal, atypical or immature plasma cells in the bone marrow; (2) the presence of a monoclonal protein in the serum or urine; and (3) bone lesions consistent with those of myeloma. Symptoms include pain and swelling of the oral cavity, tooth mobility and loss, numbness along the inferior dental nerve and paraesthesia of the lower lip. The typical radiographic appearance is a well-defined 'punched-out' lytic defect, which may be solitary or multiple. In some cases, the defect enlarges and appears 'bubbly' or septated. Permeative lytic areas with blurred outlines are a rare pattern and are radiologically indistinguishable from skeletal metastases[5].

The involvement of the oral cavity and jaw in MM has been frequently reported in the literature[3–6];

© 2011 John Wiley & Sons A/S

however, the initial manifestation of the disease in the jaw is rare, and there are few reports in the literature.

Case report

A 73-year-old man was first seen with a chief complaint of a painful mandibular enlargement persisting for 1 month with an increase in the volume of the gingiva, which bled during oral hygiene. An intraoral examination showed a purple mass in the mandibular alveolar ridge measuring 1.5 cm in length (Fig. 1A). Radiographic examination revealed a characteristic rounded, 'punched-out' lesion and a well-defined radiolucent image extending into the mandibular ramus and body (Fig. 1B). A CT scan showed a mandibular osteolytic lesion extending into the surrounding soft tissue (Fig. 1C). Other standard skeleton radiography (Xray) showed no other bone lesions besides the jaws. An incisional biopsy was performed, and a histopathological study revealed monotonous proliferation of plasmacytoid cells with round, eccentric nuclei with fine granular chromatin and evident nucleoli (Fig. 1D). The cells were strongly immunoreactive to Kappa IgG (Fig. 1E) and were not positive to a Lambda light chain. The histopathological diagnosis was plasmacytoma. At the time of diagnosis, the patient suffered from pathological bone fractures in his ribs, and a urine test was positive for Bence Jones protein. The CRAB criteria (calcium, renal, anaemia and bone lesions) were examined, and only anaemia was observed; additionally, the laboratory routine test showed moderate pancytopenia, and electrophoresis

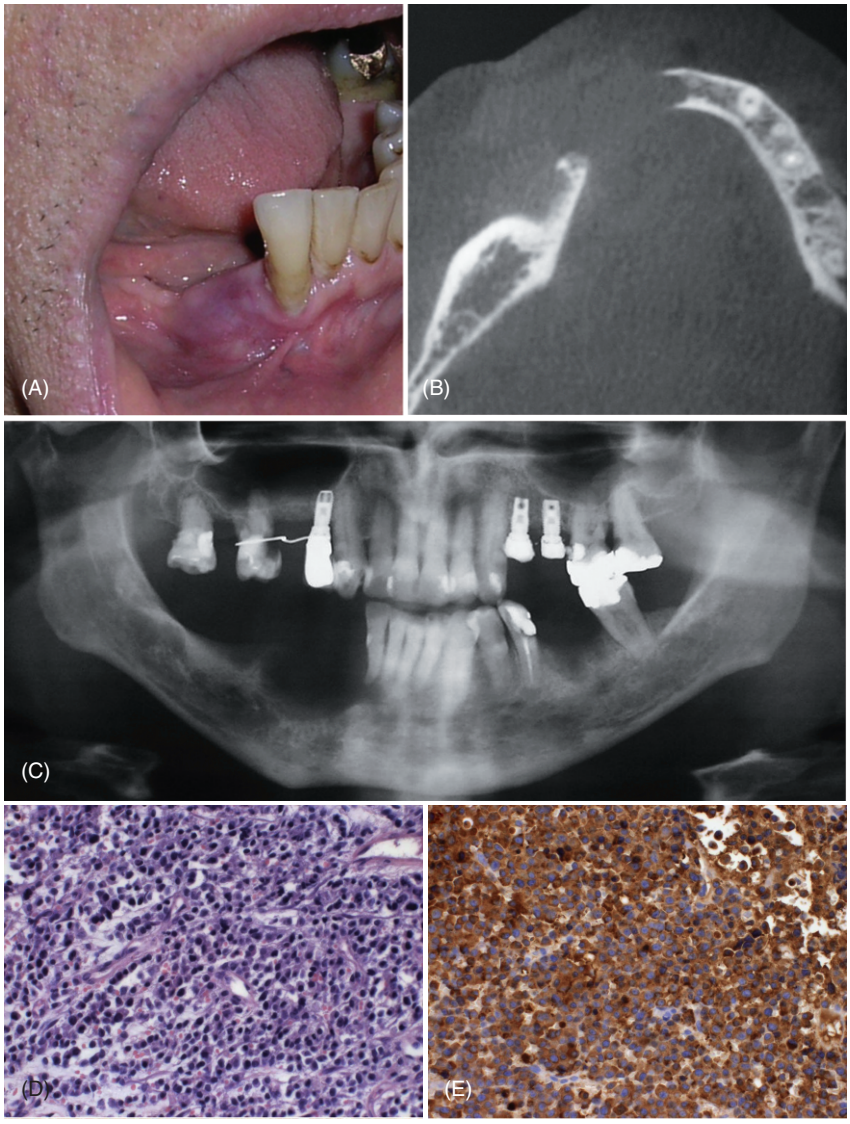

Figure 1 (A) purple mass in the mandibular alveolar ridge, (B) rounded 'punched out' lesion defined radiolucent image extending into mandibular ramus and body, (C) computed tomography scan showed a mandibular osteolytic lesion extending to the surrounding soft tissue, (D) histopathological features revealed monotonous proliferation of plasmacytoid cells, with round, eccentric nuclei with fine granular chromatin and evident nucleolus, (E) the cells were strongly immunoreactive to the Kappa IgG.

© 2011 John Wiley & Sons A/S

Table 1 Casuistic of jaws first manifestation of multiple myeloma

Author	Number of cases with oral primary manifestation of multiple myeloma	Clinical and radiographic characteristics
Baykul *et al*. (2004)[7]	01	Mandible: numbness and osteolytic manifestations
Ho *et al*. (1999)[8]	01	Mandible: swelling of masticatory muscles, osteolytic lesions
Pisano *et al*. (1997)[1]	06	01 Maxilla: gingival lesion 05 Mandible: soft tissue and osteolytic lesions
Huang *et al*. (1997)[9]	01	Mandible: gingival swelling
Witt *et al*. (1997)[10]	10	Mandible: osteolytic lesions
Lee *et al*. (1996)[11]	02	Mandible: gingival/alveolar mass with hypermobility of the teeth, osteolytic lesions
Scutellari and Orzincolo (1992)[5]	03	Mandible: osteolytic lesions
Monje *et al*. (1989)[12]	01	Mandible: osteolytic lesion
Yoshimura *et al*. (1976)[13]	01	Mandible: swelling and osteolytic lesion

confirmed IgG-positive monoclonal gammopathy. These additional clinical and laboratory features supported the final diagnosis of MM. The patient was submitted to conformal radiotherapy (3600 cGy), followed by bortezomib chemotherapy (1.3 mg per square meter of body surface area) with melphalan (9 mg per square meter of body surface area) and prednisone. After two cycles, the treatment was stopped because of intolerance, and maintenance therapy with dexamethasone was prescribed; however, progression to death inexorably followed after 6 months.

Discussion

MM may involve the jaws, which occurs in 10–30% of cases, and mainly affects the mandibular molar region, ramus and angle of the mandible because these areas exhibit intense haematopoietic activity. The oral manifestations of MM, although rare, may present as a first sign of disease[6]. There are few reports in the literature describing the initial manifestation of MM orally in the jaws. A survey was conducted through PubMed/MEDLINE, and we found only nine articles reporting the relationship of the initial manifestation of MM in the mouth using the following search descriptors: 'mouth' and 'first manifestation' and 'multiple myeloma' (Tables 1 and 2).

For the differential diagnosis for malignancy of plasma cells involving the jaws (solitary plasmacytoma of the bone, soft tissue solitary plasmacytoma and systemic MM), we should consider the clinical, radiographic and laboratory criteria described in Table 3.

In this case report, the patient had no other injuries besides the osteolytic lesion of the jaws and the rib fracture before the patient underwent intensive chemotherapy. This clinical condition coupled with the absence of bone pain symptoms lead the medical team delay to begin bisphosphonates treatment. Unfortunately, the patient died, which explains why the use

Table 2 Total numbers of papers about casuistic of jaws first manifestation of Multiple Myeloma in Pbmed/MEDLINE (1974–2010)

Database	Search strategy	Results
Pubmed/ MEDLINE	'mouth' and 'first manifestation' and 'Multiple Myeloma'	Six case reports showed seven cases with oral primary manifestation of Multiple Myeloma Three retrospective studies showed 19 cases with oral primary manifestation of Multiple Myeloma No reviews of the literature

Table 3 Plasma cell neoplasias – differential diagnosis

Characteristics and differential diagnosis
Systemic multiple myeloma
• Change of M protein in serum and/or urine
• Plasma cell infiltrates in bone marrow
• With systemic changes
Solitary plasmacytoma of the bone
• Single bone lesion
• Normal bone marrow
• Radiography of the skeleton is normal
• Without M protein
• Without systemic changes
Extramedullary plasmacytoma
• Extramedullary plasmacell tumour
• Normal bone marrow
• Radiography of the skeleton is normal
• Without M protein
• Without systemic changes

© 2011 John Wiley & Sons A/S

of bisphosphonates was not applied earlier to prevent bone loss and fractures.

Despite the relative frequency of MM in the jaws, the disease only rarely originates in the jaw. The described condition suggests that routine tests (oral and Xray) should be performed to diagnose MM. Male patients >55 years are more susceptible to the onset of this disease. This study may contribute to a better overall outcome of the treatment of these patients. This case report supports the data on the prevalence of MM in the jaws and illustrates the contribution that oral assessment can provide for the diagnosis of this disease.

References

1. Pisano JJ, Coupland R, Chen SY, Miller AS. Plasmacytoma of the oral cavity and jaws: a clinicopathologic study of 13 cases. Oral Surg Oral Med Oral Pathol Oral Radiol Endod 1997;83:265–71.
2. Keung YK, Yung C, Wong JW, Shah F, Cobos E. Association of temporal arteritis, retinal vasculitis, and xanthomatosis with multiple myeloma: case report and literature review. Mayo Clin Proc 1998;73:657–60.
3. Epstein JB, Voss NJ, Stevenson-Moore P. Maxillofacial manifestations of multiple myeloma. An unusual case and review of the literature. Oral Surg Oral Med Oral Pathol 1984;57:267–71.
4. Lambertenghi-Deliliers G, Bruno E, Cortelezzi A, Fumagalli L, Morosini A. Incidence of jaw lesions in 193 patients with multiple myeloma. Oral Surg Oral Med Oral Pathol 1988;65:533–7.
5. Scutellari PN, Orzincolo C. Mandibular lesions in multiple myeloma. Radiol Med 1992;83:219–23.
6. Lae ME, Vencio EF, Inwards CY, Unni KK, Nascimento AG. Myeloma of the jaw bones: a clinicopathologic study of 33 cases. Head Neck 2003;25:373–81.
7. Baykul T, Aydin U, O Carroll MK. Unusual combination of presenting features in multiple myeloma. Dentomaxillofac Radiol 2004;33:413–19.
8. Ho CL, Chen YC, Yiang YT, Kao WY, Chao TY. Mandibular mass as the presenting manifestation of IgM myeloma in a 22-year-old man. Ann Hematol 1999;78:93–5.
9. Huang JS, Ho YP, Ho KY, Wu YM, Chen CC, Wang CC *et al*. Multiple myeloma with oral manifestations – report of two cases. Kaohsiung J Med Sci 1997;13: 388–94.
10. Witt C, Borges AC, Klein K, Neumann HJ. Radiographic manifestations of multiple myeloma in the mandible: a retrospective study of 77 patients. J Oral Maxillofac Surg 1997;55:450–5.
11. Lee SH, Huang JJ, Pan WL, Chan CP. Gingival mass as the primary manifestation of multiple myeloma: report of two cases. Oral Surg Oral Med Oral Pathol Oral Radiol Endod 1996;82:75–9.
12. Monje F, Gil-Diez JL, Campano FJ, Alonso del Hoyo JR. Mandibular lesion as the first evidence of multiple myeloma. Case report. J Craniomaxillofac Surg 1989;17:315–17.
13. Yoshimura Y, Takada K, Kawai N, Hasegawa K, Ishikawa T. Two cases of plasmacytoma in the oral cavity. Int J Oral Surg 1976;5:82–91.

© 2011 John Wiley & Sons A/S