ORAL SURGERY

Oral Surgery ISSN 1752-2471

CASE REPORT

The peripheral adenomatoid odontogenic tumour: a case report

L.M. Bowers[1], D.M. Cohen[1,2], A. Fetner[2] & I. Bhattacharyya[1]

[1]Department of Oral and Maxillofacial Diagnostic Sciences, Division of Oral Pathology, University of Florida College of Dentistry, Gainesville, FL, USA
[2]Department of Periodontology, University of Florida College of Dentistry, Gainesville, FL, USA

Key words:
adenomatoid tumour, gingival peripheral tumor, odontogenic tumour, pathology

Correspondence to:
I Bhattacharyya
Department of Oral and Maxillofacial Diagnostic Sciences
Division of Oral Pathology
University of Florida College of Dentistry
1600 SW Archer Road
PO Box 100414
Gainesville FL 32610
USA
Tel.: +1 352 273 6689
Fax: +1 352 392 2507
email: ibhattacharyya@dental.ufl.edu

Accepted: 23 November 2011

doi:10.1111/j.1752-248X.2011.01146.x

Abstract

An 11-year-old male presented with a localised erythematous gingival enlargement of the anterior maxillary gingiva and an associated deep facial pocket. Biopsy specimens were obtained. Histopathological examination of the submitted tissue showed a cystic lining consisting of proliferating odontogenic epithelium with spindle-shaped cells forming small ductules and well-formed duct-like structures lined by pseudo-stratified columnar epithelium. A diagnosis of peripheral adenomatoid odontogenic tumour (PAOT) was rendered. The PAOT is a rare entity that can present as an erythematous gingival swelling, similar to an epulis or fibroma. Dentists should be aware that unusual pathological entities can have a variety of presentations and that definitive diagnosis may require submission of tissue for histopathological examination.

Introduction

The adenomatoid odontogenic tumour (AOT) is a benign lesion of odontogenic origin. The AOT appears in three clinical variants: a follicular type, an extra-follicular type and a peripheral type[1,2]. Peripheral odontogenic tumours are defined as tumours that demonstrate the histological characteristics of their intraosseous counterparts but occur exclusively in the soft tissue[2]. We report a rare case of peripheral adenomatoid odontogenic tumour (PAOT) occurring in the anterior maxillary gingiva of an 11-year-old male who presented with an erythematous gingival swelling of 1 year's duration. We briefly review the literature regarding the prevalence, histopathological features and treatment of this unusual entity.

Case report

An 11-year-old male presented (to AF) for evaluation of a 'red marginal lesion' of 1 year's duration. Six months prior to the evaluation, the lesion was determined to be not plaque-related and was removed by a paediatric dentist using electrosurgery (no specimen was obtained). The lesion returned 6 months later, and the patient was referred for further evaluation to AF.

Upon examination, a firm erythematous, raised lesion was noted on the facial gingiva associated with the permanent maxillary left central incisor (Fig. 1). A normal radiographic presentation was noted. On the basis of the clinical and radiographic findings, the differential diagnosis included an epulis and a pyogenic granuloma. A surgical flap was raised, and the tissue along with the associated gingiva was removed. It was noted that the lesion was attached to the facial flap and was not associated directly with the tooth. Facial bone expansion was observed relative to the adjacent teeth. No bony perforation was noted, but there was 7 mm of root exposed from the mesiofacial to the distofacial line angles of the permanent maxillary left central incisor. The specimen was placed in a 10% formalin solution and sent for microscopic examination.

Histological examination of the soft-tissue specimen revealed an encapsulated lesion containing

© 2011 John Wiley & Sons A/S

Figure 1 Preoperative appearance of erythematous gingival lesion associated with the permanent maxillary left central incisor.

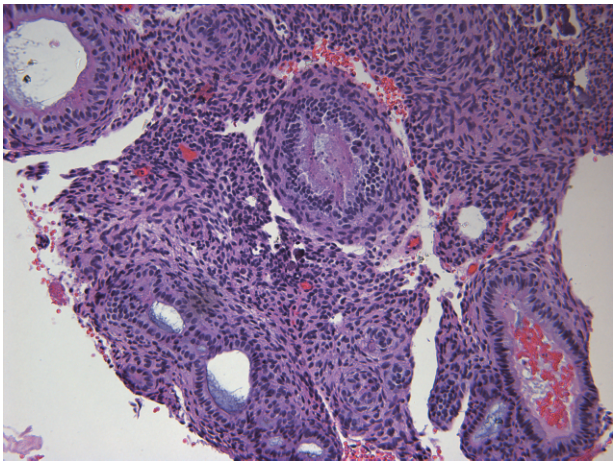

Figure 2 Proliferating cystic odontogenic epithelium with well-formed ductal structures (haematoxylin and eosin; original magnification × 200).

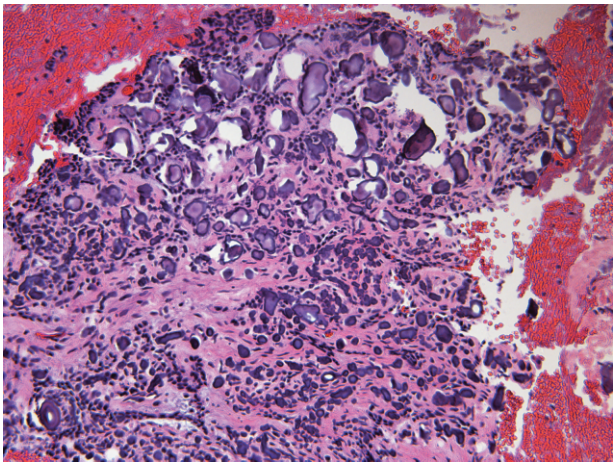

Figure 3 Calcospheritic masses distributed in the connective tissue stroma (haematoxylin and eosin; original magnification × 200).

Figure 4 Six weeks post-operatively, showing no recurrent lesion and return of clinically normal probing depths.

proliferating cystic odontogenic epithelium, well-formed ductal structures (Fig. 2) and scattered small calcospheritic masses (Fig. 3). In the specimen taken from between the teeth and the bony defect, additional cystic odontogenic epithelium of a similar appearance was seen. The histological findings were consistent with a well-encapsulated PAOT.

The patient was seen for follow-up at 1 week and 6 weeks after biopsy. Healing was uneventful. Post-operative radiographs of the area did not show any associated pathology. The tissue appeared completely healed at 6 weeks, and the probing depths had returned to clinically normal readings (Fig. 4). No further recurrence has been reported to date.

Discussion

The AOT was proposed as a distinct entity by Stafne in 1948 when he described three cases in which the epithelial components formed duct-like structures. The World Health Organization (WHO) in 1971 adopted the term proposed by Philipsen and Birn as 'adenomatoid odontogenic tumour' and defined the lesion as, 'A tumour of odontogenic epithelium with duct-like structures and with varying degrees of inductive change in the connective tissue'[3]. In 2005, the WHO redefined the AOT as 'composed of odontogenic epithelium in a variety of histoarchitechtural patterns, embedded in a mature connective tissue stroma characterized by slow but progressive growth'[4].

The peripheral variant comprises between 2.3% and 4.5% of all cases of AOT[5–7]; the lowest frequency of the three AOT types[6]. Similarly to all variants of AOT, the PAOT shows a distinct male: female ratio ranging from 1:2 to 1:14[5,7,8]. The peak incidence of the PAOT is in the second decade, with a reported mean age at presenta-

© 2011 John Wiley & Sons A/S

tion ranging from 11.9 to 14 years[5,7]; the lowest mean age for any AOT variant[6]. The peripheral lesions are most commonly seen in the anterior maxilla, most frequently in the incisor or canine region, but have also been reported in the anterior mandible[2]. The PAOT is the only peripheral odontogenic tumour that shares the age, gender and site predilections of its central counterpart[5,9]. A review of 48 well-documented cases of peripheral epithelial odontogenic tumours showed that the PAOT accounted for 12.5% of the cases[2]. In 2006, a review of 45 cases of peripheral odontogenic tumours collected over a 20 year period from a large biopsy service revealed no cases of PAOT[10].

The clinical appearance of the PAOT is that of a painless, slow-growing gingival swelling. One reported case produced protrusion of the associated teeth[2,11]. The duration of the lesion may vary from months to years[2]. Preoperative differential diagnoses may include fibroma, gingival hyperplasia or epulis[2], pyogenic granuloma, peripheral ossifying fibroma, peripheral giant cell fibroma or other peripheral odontogenic tumour. As in this case, a bony defect may be associated with the lesion. Radiographic appearance may vary from normal to demonstrating evidence of superficial erosion of the underlying bone[2,8,12,13].

The histological features of the AOT involve cuboidal or columnar cells of odontogenic epithelium forming nests or rosette-like structures with minimal intervening fibrous connective tissue stroma. Within the rosette-like structures, eosinophilic amorphous material is often seen. Tubular or duct-like structures are typically present within the cellular areas. These structures are lined by simple columnar epithelial cells with the nuclei polarised away from the luminal space. The lumen may contain an eosinophilic material, cellular debris or may be without contents. In addition to forming the duct-like structures, the cuboidal to columnar cells may form convoluted cords in complicated patterns that often show invaginations. The connective tissue stroma of the AOT is loosely arranged and contains dilated, thin-walled congested vessels[4].

Dystrophic calcification, believed to be dentinoid or cementum in nature[14], of varying amounts and patterns, is often seen within the lumina of the duct-like structures, scattered among the epithelial components or in the stroma of the AOT[8,12,13]. The number, size and degree of calcifications present will influence the radiographic appearance of the lesion[15].

The histology of the tumour does not differ widely; the histological appearance of all variants (follicular, extra-follicular and peripheral) is identical and shows remarkable consistency[16,17]. The PAOT, like the intraosseous lesion, is usually solid, however, in this case, the lesion had a cystic component. Unlike the intraosseous lesion, PAOTs are generally unencapsulated, although these lesions have also been reported as surrounded by a relatively thick capsule[2], as was observed in this case.

The PAOT has been proposed to be an erupted AOT; as normal eruption progresses, the tooth pushes an intraosseous or gingival hamartomatous growth peripherally[2]. There are reports of cases in which an unerupted tooth associated with an AOT was orthodontically guided into the arch prior to excision. It was noted that the AOT accompanied the repositioned tooth to the gingiva[5]. This is in agreement with the lesion seen in this case, as it had both peripheral and central components.

The AOT, in general, is rarely detected radiographically, but there may be underlying erosion of the bony cortex[8,12,13]. The presence or absence of a moat-like osseous defect may depend on the initial position of AOT; namely, superficial small AOT of the follicular type may present as an entirely soft-tissue process post-eruption. The unique alveolar bone alterations are thought to most likely represent the remaining eruptive path of the AOT rather than the result of pressure fenestration by the PAOT[5].

Treatment of the PAOT involves conservative surgical excision and evaluation and appropriate treatment of an underlying bony defect if present. There have been no reports of recurrence of this lesion[2]. We speculate that incomplete excision of the original lesion occurred, resulting in its apparent recurrence in this case. Because of the obvious encapsulation of the lesion and histopathological and clinical evidence of complete excision in this case, recurrence is not expected.

Conclusion

In conclusion, we report a rare case of a PAOT in an 11-year-old male which presented as a recurrent erythematous gingival swelling with a deep periodontal pocket associated with the permanent maxillary left central incisor. The PAOT is the rare variant of the AOT which, histologically, is composed of cuboidal or columnar cells of odontogenic epithelium forming nests or rosette-like structures, duct-like structures and may have dystrophic calcifications. An underlying bony defect or saucerisation of the involved bone may be present. This case illustrates the necessity of submission of all specimens removed from the oral mucosa for histopathological examination. Treatment consists of conservative surgical excision with minimal likelihood of recurrence.

© 2011 John Wiley & Sons A/S

It is important for dentists and specialists to recognise that pathological entities can have a variety of clinical presentations. When an appropriate course of action may be in question regarding a pathological lesion, referral to a specialist and submission of tissue for microscopic examination may be necessary.

References

1. Mohamed A, Singh AS, Raubenheimer EJ, Bouckaert MMR. Adenomatoid odontogenic tumour: review of the literature and an analysis of 33 cases from South Africa. Int J Oral Maxillofac Surg 2010;39:843–6.
2. Buchner A, Sciubba JJ. Peripheral epithelial odontogenic tumors: a review. Oral Surg Oral Med Oral Pathol 1987;63:688–97.
3. Gadewar DR, Srikant N. Adenomatoid odontogenic tumour: tumour or a cyst, a histopathological support for the controversy. Int J Pediatr Otorhinolaryngol 2010;74:333–7.
4. Philipsen HP, Nikai H. Adenomatoid odontogenic tumor. In: Barnes L, Eveson JW, Reichart P, Sidransky D, editors: Pathology and Genetics of Head and Neck Tumors. Lyon: IARC Press, 2005:304–5.
5. Ide F, Mishima K, Saito I, Kusama K. Rare peripheral odontogenic tumors: report of 5 cases and comprehensive review of the literature. Oral Surg Oral Med Oral Pathol Oral Radiol Endod 2008;106:e22–8.
6. Philipsen HP, Reichart PA, Siar CH, Ng KH, Lau SH, Zhang X *et al*. An updated clinical and epidemiological profile of the adenomatoid odontogenic tumour: a collaborative retrospective study. J Oral Pathol Med 2007;36:383–93.
7. Leon JE, Mata GM, Fregnani ER, Carlos-Bregni R, de Almeida OP, Mosqueda-Taylor A *et al*. Clinicopathological and immunohistochemical study of 39 cases of adenomatoid odontogenic tumour: a multicentric study. Oral Oncol 2005;41:835–42.
8. Philipsen HP, Reichart PA. Adenomatoid odontogenic tumour: facts and figures. Oral Oncol 1998;35: 125–31.
9. Philipsen HP, Reichart PA, Siar CH *et al*. An updated clinical and epidemiological profile of the adenomatoid odontogenic tumour: a collaborative retrospective study. J Oral Pathol Med 2007;36:383–93.
10. Buchner A, Merrell PW, Carpenter WM. Relative frequency of peripheral odontogenic tumors: a study of 45 new cases and comparison with studies from the literature. J Oral Pathol Med 2006;35:385–91.
11. Yazdi I, Nowparast B. Extraosseous adenomatoid odontogenic tumor with special reference to the probability of the basal cell layer of the oral epithelium as a potential source of origin. Oral Surg Oral Med Oral Pathol 1974;37:249–56.
12. Rick GM. Adenomatoid odontogenic tumor. Oral Maxillofac Surg Clin North Am 2004;16:333–54.
13. Garg D, Palaskar S, Shetty VP, Bhushan A. Adenomatoid odontogenic tumor-hamartoma or true neoplasm: a case report. J Oral Sci 2009;51:155–9.
14. Neville B, Damm D, Allen C, Bouquot J. Oral & Maxillofacial Pathology, 3rd edition. Philadelphia: Saunders, 2009:713–715.
15. Regezi JA, Sciubba JJ, Jordan RCK. Odontogenic tumors. In: Regezi JA, Sciubba JJ, Jordan RCK, editors: Oral Pathology: Clinical Pathologic Correlations, 5th edition. St. Louis, MO: Saunders, 2008:269–71.
16. Philipsen HP, Reichart PA, Nikai H. The adenomatoid odontogenic tumor (AOT): an update. J Oral Pathol Med 1997;2:55–60.
17. Shivakumar GC, Sahana S. Adenomatoid odontogenic tumor (follicular type) of the mandible: a case report and review of the literature. Int J Oral-Med Sci 2010;9:57–61.

© 2011 John Wiley & Sons A/S