

原文題目(出處)：	Reiter's syndrome (reactive arthritis)with trismus after intravesical BCG immunotherapy : a case report. Asian J Oral & Maxillofac Surg. 2011;23:25-7.
原文作者姓名：	Noriko Hatano,Hisako Hikiji,Minoru Matsubara,Hideto Saijo,Daichi Chikazu,Katsumi Ohashi,Yoshiyuki Mori,Takafumi Susami, Tetsuya Yoda,Tsuyoshi Takato
通訊作者學校：	Oral and maxillofacial surgery ,The university of Tokyo,Bunkyo-ku,Tokyo,Japan
報告者姓名(組別)：	王紹光 Intern B 組
報告日期：	100/10/14

內文：

A. Introduction:

- Intravesical(膀胱內的) Bacillus Calmette-Guerin (BCG)(卡介苗) immunotherapy is considered useful for some patients with primary superficial bladder carcinoma
- 60% of patients undergoing this therapy develop several side effects such as pneumonitis(肺炎), sepsis(敗血),multiple organ failure, and severe granulomatous inflammation(嚴重肉芽腫發炎)
- Reiter's syndrome (reactive arthritis) is one of the major side effects caused by urinary tract infection (UTI) (尿道感染) triggered by BCG
- Reactive arthritis is considered to be derived from infection by microorganisms via membranes of the digestive(消化道), urogenital(泌尿生殖道), or respiratory systems
- This is the first report of Reiter's syndrome with reactive temporomandibular arthritis caused by BCG immunotherapy.

B. Case report

- A 48-year-old male underwent transurethral resection(經尿道的切除術)of a bladder tumor(膀胱腫瘤)under a diagnosis of bladder carcinoma in the Department of Urology at the University of Tokyo Hospital on August 17, 2004.
- After bladder carcinoma resection, a total of eight intravesical BCG immunotherapy treatments using an immunobladder were planned and started from September 10.
- However, after the fifth treatment, the patient developed a fever and reactive arthritis on October 14, and so the treatment was discontinued.
- The symptoms included trismus(牙關緊閉), whereby he could not even put one finger into his mouth, eating disorder, limited ambulation(有限的步行)due to painful swelling of the bilateral knee joints, a fever of 39 °C, blepharedema(臉浮腫), and blepharoconjunctivitis(臉結膜炎)
- The patient was diagnosed with Reiter's syndrome since he had the triad of arthritis(關節炎), urethritis(尿道炎), and conjunctivitis(結膜炎).
- Sharp pain of the bilateral temporomandibular area was more marked than at any other joint.
- The laboratory data on October 18 are shown in Tables 1 and 2.

Table 1

The time-course of blood counts of the patient.

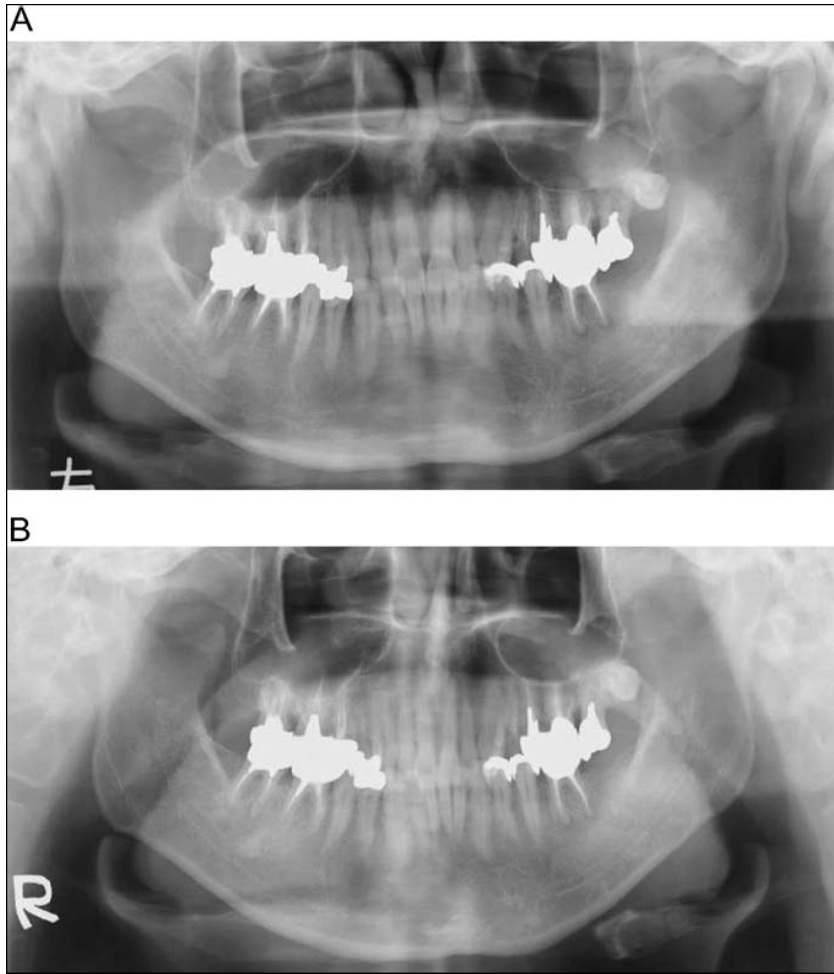
	9/24/2004	10/18/2004	1/7/2005	2/25/2005
WBC (/ μ l)	6400	10,700	6300	5000
RBC ($\times 10^4$ / μ l)	480	458	489	492
HB (g/dl)	15.1	14.7	15.3	15.5
HCT (%)	47	44.5	47.2	48
PLT ($\times 10^4$ / μ l)	37	43.9	36.6	33.4

Table 2

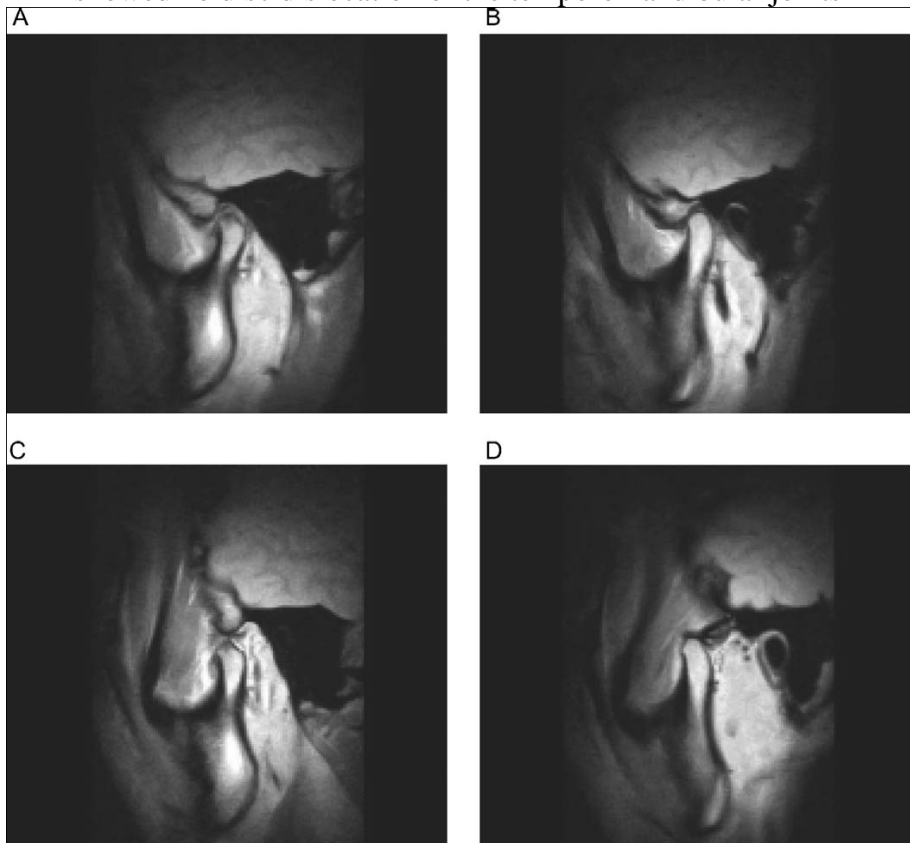
The time-course of blood biochemical parameters of the patient.

	9/24/2004	10/18/2004	1/7/2005	2/25/2005
GOT (IU/l)	22	60	39	25
GPT (IU/l)	15	45	41	22
γ -GPT (IU/l)	28	103	60	39
ALP (IU/l)	187	241	234	198
T.B. (mg/dl)	0.5	0.6	0.6	0.4
CRP (mg/dl)	0.11	7.89	0.32	0.04

- These results indicated possible tuberculosis infection.
- He was then administered rifampicin at 450mg and isoniazid at 200mg per day, and the anti-inflammatory drug diclofenac sodium (voltarenR) several days after.
- By the end of October, he gradually became able to walk with physiotherapy.
- The swelling of the knee joints fully resolved by January 2005, and he could walk normally.
- The mouth-opening distance increased, although the sharp pain of the left temporomandibular joint persisted.
- HLA antigen presence, one of the potent indices of Reiter's syndrome, was investigated on November 5, 2004. No positive indices [HLA-A31(19),HLA-B61(40), B48, or HLA-B27] were detected. Urinalysis for the acid fast bacillus on November 5, 2004, and January 7, 2005, revealed negative results.
- The severe pain of the temporomandibular joint persisted and, therefore, the attending urologist referred him to our maxillofacial surgery department on April 1, 2005.
- It had been 5 months since the reactive arthritis was first noted.
- The maximum mouth opening distance was 38mm at the first visit.
- The left side of the temporomandibular joint showed poor motility.
- Neither the left nor right TMJ showed articular crepitus(關節軋軋音) or clicking.
- Although we could not find deterioration of the head of mandibular condyles or associated osseous tissues in panoramic radiography, magnetic resonance imaging (MRI, proton density image), left TMJ MR image at mouth opening reveals effusions of both upper and lower compartments and a low signal density area on the top of the condyle that is also depicted on the mouth closing position image with a diffused irregular contour of the condylar cortical bone



- MRI showed no disc dislocation of the temporomandibular joints



- He was instructed to undergo physiotherapy for mouth opening for 2 weeks with the aid of diclofenac sodium.
- Physiotherapy treatments
 - To position the mandible slowly to the left and right sides, and then forwards and backwards 10 times, respectively.
 - To open the mouth as wide as possible 10 times, with the fingers in the mouth.
 - To do three sets of these exercises daily according to instructions given in written form.
- He continued the exercise for 3 months without medication, and the pain reduced.
- The more he exercised, the more smoothly he was able to move and open his mouth.
- He became able to open his mouth without inconvenience after 7 months of this treatment.
- Panoramic radiography showed no change of the temporomandibular joint after 1 year of this therapy.
- At present, he can open his mouth total distance of 48mm with neither pain nor difficulty.

C. Discussion

- We have reported a case of Reiter's syndrome with reactive temporomandibular arthritis caused by BCG immunotherapy.
- There are a few reports concerning Reiter's syndrome (reactive arthritis) caused by intravesical BCG immunotherapy.
- However, these did not comment on temporomandibular arthritis.
- Reviewing the literature, this is the first report of Reiter's syndrome of the temporomandibular joint following intravesical BCG immunotherapy.
- Furthermore, this case is rare because the temporomandibular area pain was severe and lasted for a prolonged period.
- Intravesical Bacillus Calmette-Guérin (BCG) immunotherapy is useful for antitumor therapy for some patients with primary superficial bladder carcinoma, or, particularly, superficial carcinoma.
- However, for intravesical BCG immunotherapy, there have been many reports of side effects such as pneumonitis, sepsis, multiple organ failure, and severe granulomatous inflammation.
- Nevertheless, after urinary tract infection (UTI) of BCG, dermatitis(皮膚炎)and blepharoconjunctivitis occur secondarily.
- HLA-B27, one of the indices of Reiter's syndrome, was negative in this case.
- However, a diagnosis of Reiter's syndrome is more likely, because about 44% of patients with Reiter's syndrome are HLA-B27-negative .Lyme disease is another candidate.
- Lyme disease is caused by Ixodesdammini or related ixodid ticks(壁虱類) showing regional specificity.
- Arthritis develops in many patients at stage 3, which is several weeks to years later from tick biting.
- We cannot deny the possibility of Lyme disease, because DR2 and IgG antibody against the Lyme spirochete were not investigated.
- However, Reiter's syndrome seems more appropriate for this case.
- The first reason is that the patient showed no clinical history of symptoms of stage 1 Lyme disease, characterized by skin lesions erythema chronicum

- migrans(特殊的遊走性紅斑), accompanied by meningitis or flu-like symptoms.
- The second reason is that he had a history of intravesical BCG immunotherapy treatments which may cause Reiter’s syndrome.
 - Considering the fact that the present patient showed the triad of arthritis, urethritis, and conjunctivitis, he was diagnosed with Reiter’s syndrome.
 - The pain of the temporomandibular area persisted for a prolonged period.
 - Sharp pain of the temporomandibular area was more marked than that of other areas such as the knee joints.
 - The inflammatory level might have been higher in the temporomandibular area than in the other joints at the time he developed this disease.
 - The patient seemed to have recovered from the primary stage of acute inflammation on the first visit to our department, although the pain of the temporomandibular area still persisted.
 - The reason why only the left temporomandibular pain persisted with less pain in the right temporomandibular joint was unclear.
 - The irregular contour of the left condylar corical bone may affect this pain.
 - Mouth-opening exercise with the use of anti-inflammatory drugs relieved the pain of the temporomandibular joint.
 - These results suggest that controlled rehabilitation is effective to recover the function of the temporomandibular joint.

題號	題目
1	以下關於 Reiter’s syndrome(reactive arthritis)何者為非? (A) 是免疫中介引起的 (B) 有三種表徵: 關節炎、非淋菌性尿道炎及結膜炎 (C) Reiter 是第一個發現這個病的人 (D) HIV 病人常發生 reactive arthritis
答案(C)	出處: Oral and maxillofacial pathology-3 rd edition p.781~782
題號	題目
2	以下關於 Reiter’s syndrome(reactive arthritis)何者為非? (A) 常發生在老年人身上, 男女比為 6:1 (B) 20% 以下的病人會發生於口腔中, 且會出現無痛的紅斑丘疹 (erythematous papules)於頰黏膜和顎 (C) 組織學上類似 psoriasis, 因有微膿腫產生於上皮的淺層, 及過度角化(hyperkeratosis) (D) 可用 NSAID 治療
答案(A)	出處: Oral and maxillofacial pathology-3 rd edition p.781~782