

原文題目(出處)：	Herpes zoster, odontalgia and nephropathy: a case report and review. Oral Surg 2011;4:35-8
原文作者姓名：	Pattni N, Hudson P, Yates JM
通訊作者學校：	Charles Clifford Dental Hospital and School of Clinical Dentistry, Claremont Crescent, Sheffield, UK
報告者姓名(組別)：	Intern I 組
報告日期：	100/04/11

內文：

#### Abstract

Herpes zoster is an acute viral infection caused by reactivation of varicella-zoster virus. Presented is a case of herpes zoster involving the trigeminal nerve masquerading as odontalgia. The difficulties in diagnosis and management are discussed.

#### Introduction

Herpes zoster (HZ) is an acute viral infection caused by varicella-zoster virus (VZV). Following primary varicella infection (chickenpox), typically in childhood, VZV establishes latency in dorsal root or cranial nerve ganglia.

Reactivation of VZV, although uncommon, results in its spread from the ganglion to the corresponding dermatome(s), producing neurocutaneous signs and symptoms – HZ or shingles.

HZ affecting the oral and maxillofacial region may pose a significant diagnostic challenge and should be considered in the differential diagnosis of those presenting with atypical odontalgia.

Other diagnoses in the early stages of symptoms may include irreversible pulpitis, acute periapical periodontitis or even acute sinusitis.

Prompt management is required, especially in immunocompromised individuals, to prevent complications, which may cause significant morbidity.

We report a case of HZ affecting the trigeminal nerve presenting as odontalgia in a patient with renal immunosuppression and review the relevant literature.

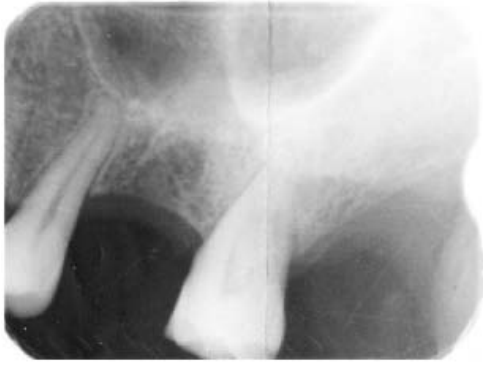#### Case report

A 44-year-old male attended his dental practitioner complaining of recent onset pain relating to an upper left molar tooth.

His medical history was significant for bilateral complete nephrectomy (due to renal carcinoma), for which the patient was receiving haemodialysis three times a week and pharmacological therapy (including folic acid, hydrocortisone, aspirin, paracetamol, penicillin, lansoprazole and lanthanum carbonate).

On examination, the dental practitioner noted nil of significance.

Further investigation revealed the upper left second molar was unresponsive to vitality testing and tender to percussion.



**Figure 1** Periapical radiograph demonstrating the upper left quadrant with no signs of odontogenic pathology related to the second permanent molar.

A periapical radiograph was taken (Fig. 1)

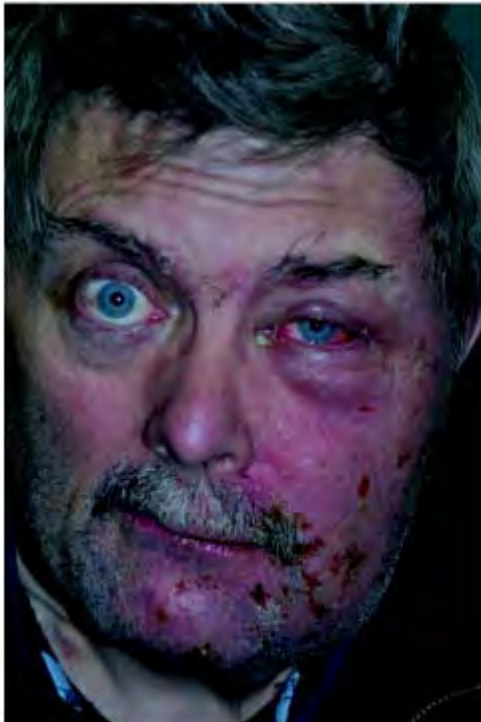Which revealed no obvious signs of odontogenic pathology.

However, there was subtle evidence of periodontal widening and as the patient identified this tooth as the source of the discomfort a diagnosis of periapical periodontitis of the upper left 7 was made.

Subsequently, the tooth was extracted under local anaesthesia without incident.

The patient reattended his dental practitioner 4 days later complaining of a 3-day history of painful swelling affecting the left side of his face and was urgently referred to the Oral and Maxillofacial Department.

Upon presentation, the patient reported a gradual onset swelling which was associated with a painful-tingling sensation and malaise. No dysphagia or odynophagia was reported. The patient denied a history of similar signs and symptoms.

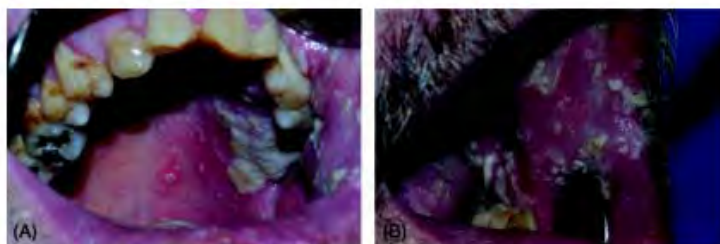


**Figure 2** Clinical photograph demonstrating facial swelling with erythema and crusting over the distribution of the left maxillary and mandibular branches of the trigeminal nerve.

Examination revealed a non-tender, diffuse oedematous swelling with widespread erythema and crusting distributed over the left maxillary and mandibular divisions of the trigeminal nerve (Fig. 2).

No cranial nerve neuropathies were noted with all other nerves being grossly intact. The left conjunctiva was inflamed, but acuity and pupillary reflexes were normal.

**Figure 3** Intra-oral clinical photographs showing unilateral vesicles, ulceration, erythema, scaling and crusting affecting the hard palate (A) and buccal mucosa (B).



Intra-orally vesicular eruptions, erythema and areas of ulcerations were noted unilaterally over the distribution of the maxillary and mandibular nerves, including the hard palate and buccal mucosa (Fig. 3).

Upon questioning, the patient reported having chickenpox (varicella) as a child.

A diagnosis of HZ of the left maxillary and mandibular branches of the trigeminal nerve was made.

Ophthalmological and renal opinion was sought to exclude corneal ulceration and plan antiviral pharmacological therapy respectively.

The latter was sought due to the potential toxic effects of the antiviral drugs secondary to the bilateral nephrectomy.

The patient was given a modified course of acyclovir, but failed to attend follow-up. However, discussions with the renal dialysis team suggested the patient made a slow but complete recovery.

#### Discussion

The majority of HZ infections involve the thoracic and lumbar dermatomes; however, approximately 13% of patients present with infections involving any of the three branches of the trigeminal nerve.

The ophthalmic branch is most commonly affected; however, in our case only the maxillary and mandibular branches were involved; this is rare (1.7% of cases).

Reactivation of VZV may occur spontaneously or when host defenses are compromised. Increased age, physical trauma (including dental manipulation), psychological stress, malignancy, radiation therapy and immunocompromised states including transplant recipients, immunomodulatory therapy and HIV infection are predisposing factors for VZV reactivation.

Our patient, as well as others with compromised renal function, exhibits an impaired host immune response which may contribute to development of HZ.

Sato et al. demonstrated an increased prevalence of HZ in patients with end-stage renal disease requiring renal replacement therapy.

Patients with HZ may progress through three stages: prodromal stage, active stage (also called acute stage) and chronic stage.

The prodromal stage presents as sensations (described as burning, tingling, itching, boring, prickly) occurring in cutaneous distribution of the dermatome and is believed to represent viral degeneration of nerve fibrils.

During this period, if branches of the trigeminal nerve are affected, odontalgia and pulpal necrosis may occur.

For the latter, it is proposed that the reactivated virus may travel the length of the nerve, infect the pulp vasculature lead to infarction and necrosis.

Furthermore, these symptoms may present up to 1 month before the acute mucocutaneous lesion, and pose significant diagnostic difficulties.

The active stage is characterised by the emergence of the rash which is nearly always

accompanied by systemic upset.

The characteristic skin rash progresses from erythematous papules and oedema to vesicles and finally to pustules within 1 to 7 days which dry and crust and are exfoliated over 2 to 3 weeks leaving erythematous macular lesions that may scar.

Surprisingly, pain is reported to subside when the rash is most active; however, it returns during the crusting and scale phase until the rash clears.

It is during the active or 'eruptive' phase that HZ is at its most contagious and could pose a significant cross infection risk.

In this particular case, the risk of infection to other patients within the dialysis unit may be significant and the consequences potentially severe.

On further questioning, no further outbreaks were reported.

The chronic stage is only seen in approximately 10% of all patients with HZ, and is termed post-herpetic neuralgia.

It is described as a brief recurrent shooting or shocking allodynia, with a constant, usually deep pain, lasting beyond the period of healing of the active skin lesions. It may persist for years and is a significant cause of morbidity.

Although post-herpetic neuralgia is the most common complication of HZ, other complications include neurological disorders, ophthalmologic, cutaneous and visceral complications; immunocompromised individuals with HZ exhibit a significantly higher rate of complications .

Periapical lesions, root resorption, tooth exfoliation and alveolar osteonecrosis have also been reported in association with HZ infection.

Although HZ is a self-limiting condition and resolution is usually complete, treatment is indicated in some cases to reduce the acute symptoms of pain and malaise, to limit the spread and duration of the skin lesions and to prevent complications.

The pharmacological approach is based on symptomatic relief and antiviral therapy.

For many years, aciclovir (ACV) has been the antiviral drug of choice for the treatment of VZV infections.

Recently, other antiviral agents such as valaciclovir and famciclovir have been developed to overcome the low oral bioavailability of ACV and its limited and less predictable effect in preventing the development of post-herpetic neuralgia, as well as to provide a more favourable dosage regime.

In a recent review of VZV management, Mustafa et al. recommends administration of ACV as an infusion for treatment of HZ in immunocompromised individuals.

However, ACV and other antiviral drugs are primarily excreted/eliminated via the kidneys and thus, in this patient, consideration was given to the most appropriate administration and dosage, given that he had previously had a bilateral nephrectomy for renal carcinoma.

Therefore, dosage modification of ACV is required in patients with abnormal creatinine clearance and evidence of acute and chronic renal failure.

In this particular case, advice was sought from a kidney specialist who recommended a reduced dose of 400-800 mg orally twice daily and for the patient to continue his dialysis . The patient was reviewed during his dialysis and made a full recovery.

Conclusion

A case of HZ affecting the trigeminal nerve is reported.

This case highlights the importance of a thorough dental history and examination in patients with odontalgia.

In those presenting with atypical odontalgia, HZ should be considered in the differential diagnosis.

Furthermore, special consideration must be given to patients who have a history of

chronic or dialysis dependant kidney failure as excessive dosages can lead to neurological and systemic upset along with a deterioration of what may already be limited kidney function.

題號	題目
1	Which disease is not associated with viral infection ? (A) Herpes zoster (B) Measles (C) Hand-foot and mouth disease (D) Actinomycosis
答案(D)	出處：ORAL PATHOLOGY second edition P. 177~125
題號	題目
2	Which statement about Herpes-zoster is not correct ? (A) The pathogens is varicella-zoster virus (B) The pain usually along the course of the involved bilateral trigeminal sensory nerve (C) If the infection involved the geniculate ganglion ,called James Ramsay Hunt Syndrome – facial paralysis , pain of the external auditory meatus and pinna of the ear (D) The majority of HZ infections involve the thoracic and lumbar dermatomes
答案(B)	出處：ORAL PATHOLOGY second edition P. 177~125