

原文題目(出處)：	Anterior lingual mandibular bone cavity as a diagnostic challenge: Two case reports. J Oral Maxillofac Surg 2010;68:201-4
原文作者姓名：	Voss P, Marc Metzger C, Schulze D, Loeffelbein DJ, Pautke C, Hohlweg-Majert B
通訊作者學校：	University Hospital Freiburg, Freiburg, Germany. Technische Universität München, Munich, Germany
報告者姓名(組別)：	許璧仔(Intern D組)
報告日期：	99/01/04

內文：

Introduction

Stafne bone cyst

1. Well-demarcated radiolucency in the posterior mandibular angle.
2. Also known as static bone cyst, latent bone cyst, lingual mandibular bone cavity, mandibular embryonic defect, idiopathic bone concavity of the mandible, developmental submandibular gland defect of the mandible.
3. Innocuous convexities in the lingual cortex of the mandible.
4. Regular salivary gland tissue was the most histologic finding. Muscle, fibrous connective tissue, blood vessels, fat, or lymphoid tissue were also found in the lesion occasionally.
5. One theory suggested that part of the submandibular gland was entrapped in the lingual mandibular cortex.
6. The incidence ranges from 0.1% to 1.3%.
7. Richard and Ziskind in 1957 first found the Stafne bone cavity in the premolar region. The sublingual gland or aberrant salivary gland tissue has also been associated with this bony cavity in the anterior mandible.
8. The diagnosis of Stafne bone cavity is difficult on plain radiographs; and endodontic treatment, bone trephining and bone exploration may result from and incorrect diagnosis.

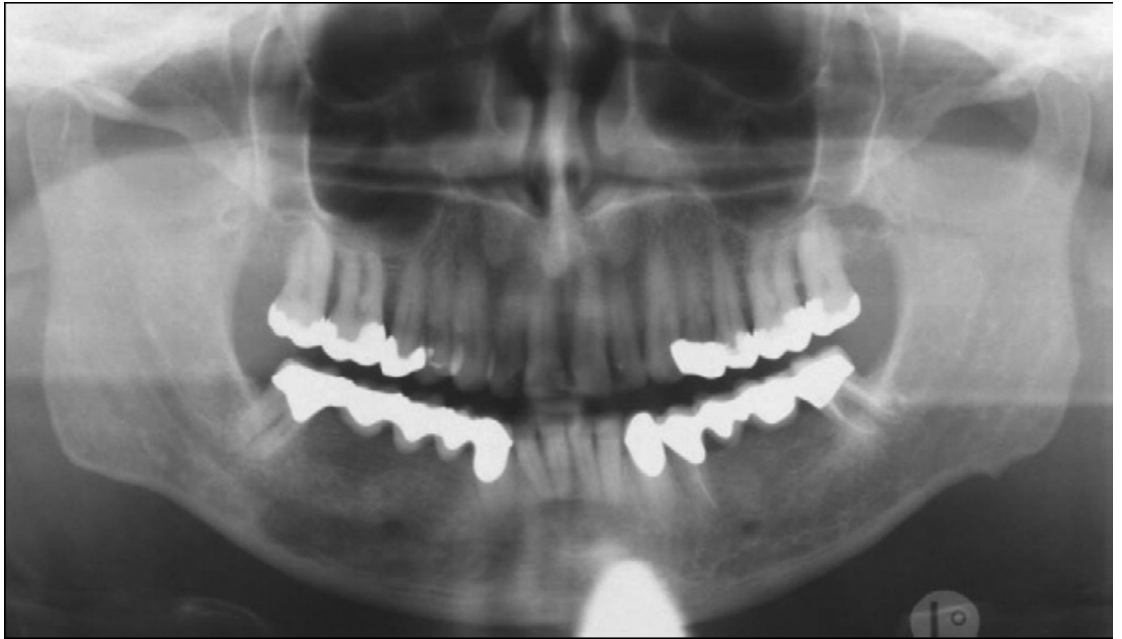Object

To describe 2 new cases of Stafne bone cavity in the anterior mandible and to discuss the differential diagnosis process. Here introduces cone-beam computed tomography as a suitable noninvasive diagnostic and follow-up modality for these cases.

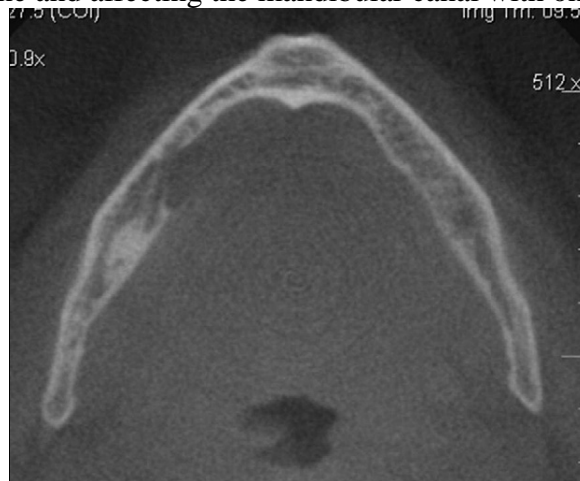
Case report

Case 1:

- 58-year old male was noticed a sharply bordered unilateral radiolucency in the mandible by his dentist
- No significant history and symptom
- Lesion was located in the edentulous region between the lower right canine and the first molar and appeared to have no relation to the adjacent teeth
- This 1.5 x 3 cm lesion seemed to be associated with the mandibular canal



- Cone-beam computed tomography showed a lingual osteolysis, interrupting the lingual compact bone and affecting the mandibular canal with only

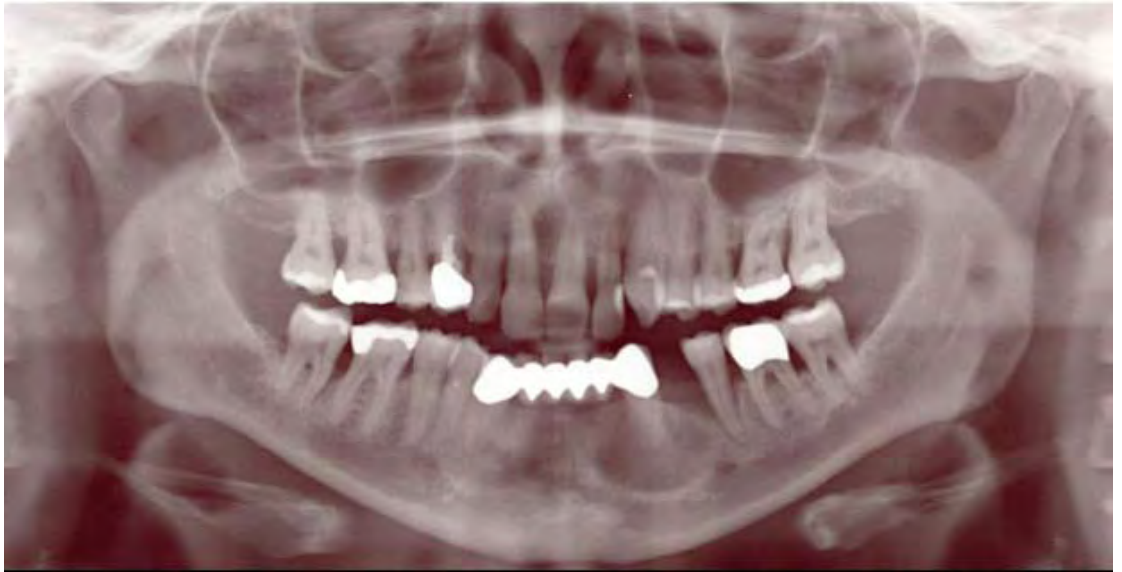

poorly-defined margin

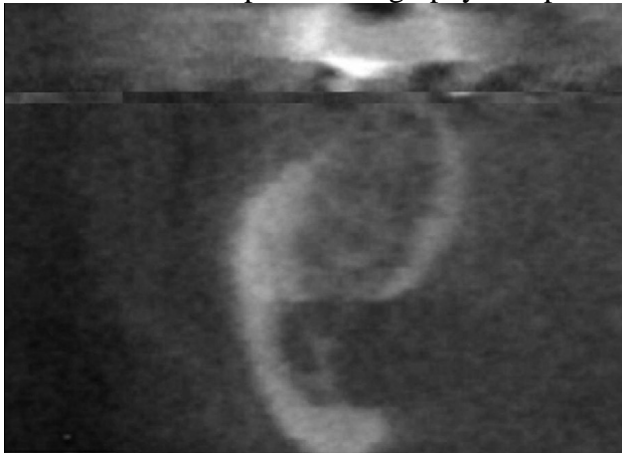- Histologic examinations shows a mixed salivary gland tissue with a slightly chronic infection in the area of the ducts and periductal fibrosis

Case 2

- 50-year-old female
- No special dental or medical history
- A 20 x 15 mm radiolucency was found in the anterior mandible appearing to relate to adjacent teeth on a panoramic radiograph and periapical radiograph during routine dental examination



- No abnormal findings and all teeth in the region responded within normal limits to the temperature pulp test
- Differential diagnosis were osteoporotic focal defect of the marrow, apical granuloma, residual cyst or latent bone cyst
- An occlusal radiograph and ultrasound did not provide further information, so cone-beam computed tomography was performed



- A 20-mm-wide and 15-mm-long bony impression on the lingual side of the anterior mandible, which did not have any relation to an adjacent tooth
- A follow-up radiograph taken 5 months later did not show any alteration of the radiolucency. Therefore, no invasive therapy was performed on this patient.

Discussion

1. Ectopic salivary gland tissue: the lateral and posterior neck, tongue, middle ear, thyroid, pituitary gland, and mandible.
2. The inclusion of salivary gland tissue in the mandible is a rare phenomenon, which is most commonly seen in the posterior region and more unusually in the anterior mandible (0.009% to 0.3%).
3. Male patients seem to be more often affected (approximately 80%), with a peak in their fifth and sixth decades.
4. Hypotheses put forward suggest that the defect is congenital or develops through pressure resorption. The first theory suggests that part of the

- salivary gland becomes entrapped during the development and ossification of the mandible.
5. Asymptomatic, non-progressive, and rarely palpated
 6. Not all bone cavities will be well-demarcated impressions with a sclerotic border. Because a relation to the dental roots on plain radiographs is frequent in the anterior mandible, the differential diagnosis includes a periapical granuloma or radicular cyst; equally a keratocyst, an odontogenic tumor, or an idiopathic bone cavity may be unusual but possible considerations
 7. Although sialography is helpful in doubtful posterior cases, it is impracticable and rarely effective in anterior cases due to the presence of many accessory Bartholin ducts adjoining the sublingual gland in the anterior mouth floor so that it gives little information on the submandibular gland
 8. Several investigators have described the use of computed tomography or magnetic resonance imaging to specify the diagnosis, especially in the anterior case
 9. This article recommend cone-beam computed tomography—a rapidly developing radiographic 3-dimensional imaging technique—to confirm the diagnosis.
 10. In most cases, no histopathology should be required and no treatment is indicated if 3-dimensional radiologic screening shows a Stafne cavity. Nevertheless, regular follow-ups are recommended to identify any changes.

題號	題目
1	Which description about Stafne bone cyst is incorrect? (A) It is also named mandibular embryonic defect. (B) It is common that patient go for help when a radiolucency in a radiograph was found at a routine dental examination because in most cases Stafne bone cyst is asymptomatic. (C) Stafne bone cyst shows male predilection and is most seen in posterior mandibular area. (D) Stafne bone cyst is distinguishable about the relationship with mandibular canal in a plain radiograph.
答案(D)	出處：Anterior Lingual Mandibular Bone Cavity as a Diagnostic Challenge: Two Case Reports (J Oral Maxillofac Surg 68:201-204 2010)
題號	題目
2	Which radiographic examination can be used to help to diagnosis Stafne bone cyst? (A) Panoramic radiograph (B) Sialography (C) MRI (D) Cone-beam computed tomography
答案 (ABCD)	出處：Oral and maxillofacial pathology p.23-p.24