

原文題目(出處)：	Castleman's disease presenting within the cheek of a child. Oral Surgery 2008;1:216-9
原文作者姓名：	Katti S, Bussell MA, Najran P, ElRasheed A, Prescott RJ, Smith JG
通訊作者學校：	Department of Histopathology, Royal Lancaster Infirmary, Lancaster, UK
報告者姓名(組別)：	袁麗芸 Intern L組
報告日期：	2009/09/11

內文：

Abstract

A case is presented of an 11-year-old male with an eventual diagnosis of extranodal Castleman's disease (hyaline vascular type). This was difficult to diagnose as attempts were made to remove what was believed to be a haematoma, and then a reactive lymph node within the left cheek. Subsequent histopathology revealed the true nature of this swelling.

Introduction

- *Castleman's disease was first described in 1954 (by Castleman and Towne).
- *Further development has suggested that Castleman's disease is a lymphoproliferative disorder.
- *The disease can present in lymph nodes or as an extranodal mass.
- * The aetiology of the disease remains unknown
- *Clinically, the lesion typically presents as a solitary mass, which is benign, painless and without specific signs or symptoms.
- * It can also present as multicentric masses.
- *The disease tends to be seen in young adults and there is no sexual predilection.
- * Most common site of presentation is in the mediastinum (in 86% of cases)-followed by the neck (in 6% of cases).
- *Less commonly, cases have been reported in the head and neck region, including the parotid gland⁸, submandibular gland⁹ and within a lymph node in the buccal mucosa.
- *Histopathologically, two main variants of Castleman's disease have been identified; 1) Hyaline vascular type (80–90%), is characterised histologically by lymphoid follicular hyperplasia with abnormal, regressive germinal centres. This variant is usually asymptomatic, unless the lesion causes indirect symptoms by compression of adjacent structures.
- 2) Plasma cell type (10–20%), which shows an increase in the number of plasma cells in the interfollicular region. This variant often has associated systemic symptoms, such as fever, night sweats, anaemia. This form of the disease is more aggressive and has a relatively poor prognosis. It has been associated with the human herpes virus 8 (HHV8) infection.

Case presentation

An 8-year-old Caucasian male presented with a 2-week history of swelling within the substance of the left cheek. The lump was first noticed following an injury to the left cheek while playing rugby. Failure of the lesion to reduce in size resulted in a referral to oral and maxillofacial surgery by his general medical practitioner. Upon examination, the patient was systemically well with no cervical lymphadenopathy. A 1.5 cm diameter, non-tender, fluctuant, smooth mass was found within the left cheek, overlying the zygomatic bone. A full blood count and erythrocyte sedimentation rate were within normal limits and facial radiographs were unremarkable. The provisional diagnosis of an organizing haematoma was made. The patient was then reviewed over

a 4-month period, during which time there was no significant change.

As the lesion had not resolved, an exploration of the left cheek and excisional biopsy was performed under general anaesthetic. The lesion was approached from an intraoral incision; the mass was found within subcutaneous tissue and muscle, deep within the left cheek. The lesion was solid in nature and there was no definitive plane between the lesion and surrounding tissue. Histopathological analysis revealed reactive lymphoid hyperplasia with no malignancy.

After 7 months, the lesion reoccurred in the same location and further removal was performed under general anaesthetic. Histopathological examination of this sample was reported as showing soft tissue with a reactive lymphoid infiltrate composed of reactive lymphoid follicles with regressive germinal centres.

The latter showed vascular proliferation and focal hyalinisation. The mantle zone appeared expanded and showed the classical 'onion skin' concentric layering of lymphocytes at the periphery of the follicles (Figs. 1 & 2). No lymph node capsule or sinuses were evident. A diagnosis of extranodal, soft tissue, hyaline vascular type Castleman's disease was made. The lesion was felt to be completely excised and the patient now remains symptom-free, although continuing under regular review.

Discussion

Castleman's disease is a rare lymphoproliferative disorder, which has the potential to progress to malignancy.

Most frequently, it presents in the mediastinum of young adults. Although rare, the disease has been reported in children.

This reported case is believed to be a unique example of extranodal, hyaline vascular Castleman's disease, which presented intraorally, within the substance of the cheek of a child, following a history of trauma.

Diagnosis of the disease is a challenge to the clinician and can be readily misdiagnosed. The aforementioned case highlights this difficulty, as initially, the lesion was diagnosed clinically as a haematoma. The first histopathological investigation reported the lesion as reactive

lymphoid hyperplasia. Only after the recurrence and second excision was a histopathological diagnosis of Castleman's disease made.

A haematoma is not routinely included in the differential diagnosis of Castleman's disease. However, because of marked 'vascular infiltration', and therefore the vascular nature of this lesion, it may clinically mimic a haematoma.

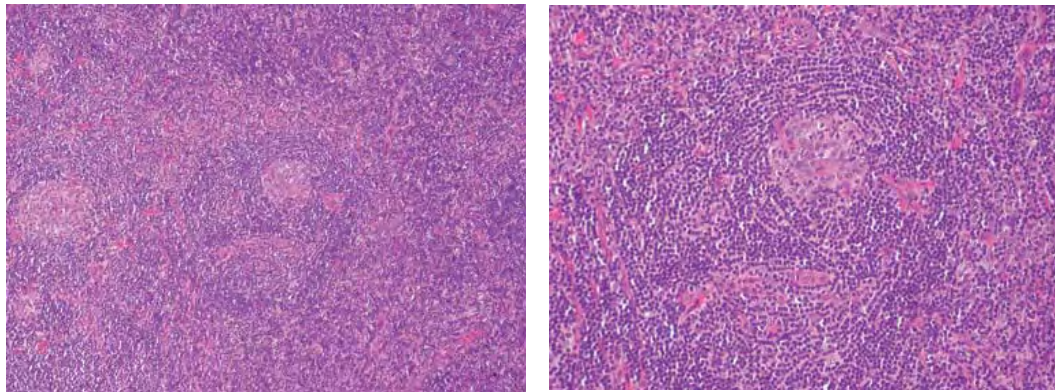
It is postulated that increased IL-6 production by the mantle zone B-lymphocytes secondary to stimulation by HHV-8 or by an unidentified exogenous or endogenous agent, is the initial step in the development of Castleman's disease. IL-6, in turn, stimulates release of vascular endothelial growth factor, resulting in the characteristic lymphoid follicular and vascular proliferation. The aforementioned case manifested subsequent to a traumatic event. It remains to be seen if trauma can induce localised IL-6 production and subsequent

Castleman's disease-like changes, or whether trauma can cause an already existing vascular Castleman's lesion to bleed and form what mimics an organized haematoma. Following complete surgical excision, clinical resolution of the disease usually occurs. In this case, the recurrence is most likely to have arisen within the residual tissue, suggesting an incomplete initial excision.

Ten months following the second procedure, the patient has remained symptom-free.

In summary, this distinctive case reports a localised, extranodal, soft tissue, hyaline vascular Castleman's disease, occurring in the cheek of a child following trauma. It is an unusual example of an extremely rare pathological condition to occur intraorally

and within the paediatric population. It has presented a diagnostic challenge to both clinician and pathologist.



題號	題目
1	下列哪一種不是Castleman's disease 的種類? (A) 透明血管型 (B) 單細胞型 (C) 漿細胞型 (D) 多中心型
答案(B)	出處：Oral surgery 2008 p 216
題號	題目
2	何者非Castleman disease? (A) 血管慮泡性淋巴結增生 (B) 淋巴錯構瘤 (C) 巨淋巴結增生 (D) 反應性淋巴結增生
答案(D)	出處：Oral surgery 2008 p 216,217