

Review

Osteonecrosis of the jaw – Who gets it, and why? ☆

Ian R. Reid \*

Faculty of Medical and Health Sciences, University of Auckland, Private Bag 92019, Auckland, New Zealand

ARTICLE INFO

Article history:

Received 15 August 2008  
 Revised 16 September 2008  
 Accepted 16 September 2008  
 Available online 7 October 2008

Edited by: T. Jack Martin

Keywords:

Bisphosphonate  
 Cancer  
 Osteoporosis

ABSTRACT

Osteonecrosis of the jaw (ONJ) is now defined by the presence of exposed bone in the mouth, which fails to heal after appropriate intervention over a period of six or eight weeks. It is commonly precipitated by a tooth extraction in patients treated with zoledronate, pamidronate or a combination of these agents, for the management of myeloma, breast cancer or prostate cancer. In patients with these malignancies who are treated with bisphosphonates, the overall prevalence is about 5%. There is a need to clearly delineate the incidence of ONJ in osteoporosis patients treated with bisphosphonates, and in appropriate control populations. Based on current evidence, the risk of ONJ in osteoporosis appears to be comparable to that in the general population.

It is likely that ONJ results from direct toxicity to cells of bone and soft tissue from high potency bisphosphonates, probably acting through their effects on the mevalonate pathway. The bone in ONJ lesions does not appear to be ‘frozen’, rather there is very active resorption present, probably stimulated by local infection. This is likely to result in the local release at high concentrations of bisphosphonates. Management focuses on prevention, treatment of infection and cessation of bisphosphonates. The role of surgery is unclear.

© 2008 Elsevier Inc. All rights reserved.

Contents

Introduction . . . . .	4
Epidemiology . . . . .	5
Cancer . . . . .	5
Osteoporosis . . . . .	5
Etiology . . . . .	6
Ischemia . . . . .	6
Low bone turnover . . . . .	6
Bisphosphonate toxicity to bone . . . . .	7
Infection . . . . .	8
Bisphosphonate toxicity to soft tissue . . . . .	8
Management . . . . .	9
Conclusions . . . . .	9
Competing interests . . . . .	9
References . . . . .	9

Introduction

When a new clinical entity is described, there is often a period of uncertainty during which some clinicians question whether the condition really exists, and then a further time during which the

defining characteristics of the syndrome and its nomenclature are debated. Osteonecrosis of the jaw (ONJ) is progressing through this evolution. The reality of the condition in oncology patients is beyond doubt, though in benign bone diseases the debate continues. There are now at least two authoritative consensus statements regarding its definition – the syndrome is now defined by the presence of exposed bone in the mouth which fails to heal after appropriate intervention over a period of six or eight weeks [1,2]. Authors have used a variety of terms to refer to this condition, some of which make inappropriate

☆ Funded by the Health Research Council of New Zealand.  
 \* Fax: +64 9 308 2308.  
 E-mail address: [i.reid@auckland.ac.nz](mailto:i.reid@auckland.ac.nz).

assumptions regarding etiology, such as 'avascular necrosis of the jaw'. Generally, the syndrome is now referred to as either 'osteonecrosis of the jaw' or 'bisphosphonate-related osteonecrosis of the jaw'.

Not all cases in the literature meet the now agreed definition and it is the anecdotal experience of many, that some dental practitioners apply this label to a much wider range of conditions. The term has been applied to the presence of persistent inflammation in the mouth, osteomyelitis, delayed healing of extraction sockets, the development of sequestra, or the presence of fistulae from the mouth to the skin or to the nose or sinuses. These conditions should only be labeled as ONJ when the criterion of exposed bone for more than six to eight weeks is met. The variability in the use of this definition and the need for case adjudication, should be borne in mind when epidemiological studies in this area are evaluated. It should also be borne in mind that exposed bone in the mouth can occur in individuals who have never been exposed to bisphosphonates [3], so a causative role for a bisphosphonate a patient happens to be taking, should not always be assumed.

### Epidemiology

It has taken several years for a coherent picture of the epidemiology of ONJ to emerge from the disparate case reports and case series which have been published. The literature was recently reviewed by Abu-Id [4], and this is summarized in Table 1. The majority of ONJ patients have been treated with zoledronate, pamidronate or a combination of these agents, most commonly for treatment of myeloma or breast cancer. In 5% of patients with ONJ, the treated condition is said to be osteoporosis. These figures are very similar to those from the German National Registry [5]. Common precipitating events are tooth extractions (reported in more than one half of cases in most series), mandibular exostoses, periodontal disease and local trauma from ill-fitting dentures. Dental implants have also been suggested to be common precipitating factors, though recent series have cast doubt on that, particularly in those receiving oral bisphosphonates [6–9]. Co-existent use of cytotoxic drugs and glucocorticoids is very common in the patients that develop this condition. A case–control study has recently implicated smoking and obesity as independent risk factors [10], and others have suggested that diabetes is a common concomitant condition [11].

**Table 1**  
Bisphosphonate exposure, underlying conditions, and affected sites in 626 published cases of osteonecrosis of the jaw

Epidemiology of ONJ	
<i>Drugs</i>	
Zoledronate	43%
Pamidronate	27%
Zoledronate + pamidronate	23%
Ibandronate intravenous	2%
Alendronate	4%
Ibandronate oral	0.5%
Risedronate	0.5%
Clodronate	0.2%
<i>Conditions</i>	
Myeloma	48%
Breast	36%
Prostate	7%
Other malignancy	3%
Osteoporosis	5%
<i>Sites</i>	
Mandible	67%
Maxilla	26%
Both	8%
N=626	

Based on data in Abu-Id et al., J Cran Max Surg 36:95, 2008.

### Cancer

A number of authors have now studied the prevalence of ONJ in cohorts of patients with a variety of malignancies. Hoff et al. carried out a chart review on 4000 cancer patients treated with bisphosphonates at the MD Anderson Cancer Centre [12]. Half of these patients had either breast cancer or multiple myeloma, of which 1.2% and 2.8%, respectively, developed ONJ. However in the half of the cohort suffering from other malignancies, there were only two cases of ONJ, giving a prevalence of 0.09% in that group. It is unclear whether this substantial difference between breast cancer and multiple myeloma on the one hand, and other malignancies, is attributable to different patterns of use of bisphosphonates, or whether it is an effect of the underlying disease conditions. Abu-Id has recently reviewed seven case series comprising 7500 patients, and found ONJ to occur in 2–11% of myeloma patients, 1–7% of breast cancer patients and 6–15% of those with prostate cancer. These figures suggest that these three malignancies do not differ in their risk of ONJ, and suggest that the overall prevalence is about 5%. These case series also demonstrate that ONJ can occur less than 6 months after initiation of bisphosphonate treatment for malignancy, or up to 60 months later. It is probable with longer follow-up, that the mean time to onset and ONJ prevalence will increase, since Durie has shown an approximately linear relationship between prevalence and duration of therapy [13], and risk increases with the number of bisphosphonate infusions administered [14].

Another way of confirming that bisphosphonate use is associated with an increased incidence of ONJ is to use medical claims databases. The difficulty with this approach is that most such databases have not contained a specific category for ONJ, but it is possible to search for inflammatory conditions of the jaw or operations on the jaw, on the basis that these are the categories that are likely to contain cases of ONJ. Wilkinson has done this using a database of >40,000 cancer patients, and found a 0.2% prevalence of these categories in those not treated with bisphosphonates, compared with 5.5% at 72 months in those treated with bisphosphonates [15]. Cartos et al. performed similar analyses on data from 250,000 cancer patients, and showed odds ratios for jaw problems in the range of 4.5–6.8 [16]. A case–control study has also been used to characterize the epidemiology of ONJ in cancer patients. Wessel et al. identified 30 cancer patients and matched five control subjects for age, gender, cancer type and date of diagnosis to each case [10]. This allowed development of a logistic regression model which produced an odds ratio of 32 for use of zoledronate ( $P=0.02$ ), and an odds ratio of 1.11 per zoledronate infusion ( $P=0.01$ ). They also found that smoking (odds ratio 7), obesity (odds ratio 17) and metastasis (odds ratio 27) were significant predictors of the development of ONJ. Smoking has been associated with other oral pathologies so its emergence here is not a surprise.

### Osteoporosis

While the epidemiology of ONJ in cancer patients treated with bisphosphonates is becoming clearer, this is certainly not the case with respect to patients with osteoporosis. In the literature survey carried out as part of the recent American Society for Bone and Mineral Research report [1], 57 individuals were identified, though other case series have been published since then [17]. In the risedronate and alendronate clinical trials (each program involving 16,000–17,000 patients) no cases of ONJ were noted. Post-marketing surveys to mid-2007 indicated an incidence of <1.2 per 100,000 patient-years for risedronate, and of <0.5–2.5 per 100,000 patient-years for alendronate. In the recent zoledronate phase III program, an expert group prospectively surveyed the adverse event reports for anything that might represent ONJ, and then adjudicated possible cases while blinded to treatment allocation. In the first of these studies, one case was found in the placebo group and one in the

zoledronate group, from a total study cohort of more than 7700 women [18,19]. In the 2000 men and women involved in the second zoledronate trial [20], no cases were reported and none have been seen in the other smaller studies in this program. With the likely prevalence sitting at approximately 1 per 100,000 patient-years, it is quite unclear that this is any different from that in the general population, since these problems can certainly occur in the absence of bisphosphonate use, as noted above. In our own osteoporosis clinic, we have had two patients develop ONJ who had not used bisphosphonates.

The Cartsos [16] medical claims database study also surveyed 260,000 subjects with osteoporosis, and found an odds ratios for inflammatory necrosis of the jaw to be 0.65 in oral bisphosphonate users, and that for surgery for a necrotic process to be 0.86. Both these values are consistent with the other data suggesting that bisphosphonate use does not increase ONJ risk in osteoporosis patients. These findings are very similar to those from a case-control study using a claims database, which found that receiving at least one oral bisphosphonate prescription was associated with an odds ratio for jaw surgery of 0.91 [21]. For osteoporosis patients treated with intravenous bisphosphonates in the Cartsos database, there did appear to be increases in the risk of both categories of claim. However, this is likely to be attributable to co-existent cancer, since it appears that 10% of the cancer patients also had a diagnosis of osteoporosis, and because use of intravenous bisphosphonate for osteoporosis in the United States was extremely uncommon during the period that this database was compiled. Other benign bone diseases show very low risks of ONJ, including Paget's disease treated with intravenous zoledronate [22] and osteogenesis imperfecta treated with monthly infusions of pamidronate [23].

One study presents a very different picture of the risk of ONJ in benign disease. Mavrokokki et al. [24] sent questionnaires to oral surgeons in Australia soliciting cases of ONJ. They identified 114 cases nationwide, including 25 prospectively identified cases in South Australia alone. In the former group, 28% of patients had benign disease and in the latter group, 56%. These proportions are 5–10-fold greater than in any other series. The cases were not adjudicated which may mean that a number of non-qualifying cases were included, and the failure to definitively identify patients means that undetected duplicates cannot be ruled out. Considering that these unadjudicated data are inconsistent with all other published studies, including those from the prospectively adjudicated German national registry, the conclusions regarding the incidence of ONJ in benign disease should be treated with caution.

## Etiology

The mechanism by which bisphosphonates cause ONJ is uncertain, and a number of assumptions have crept into the literature. Several possible pathogenic mechanisms need to be considered, as follows.

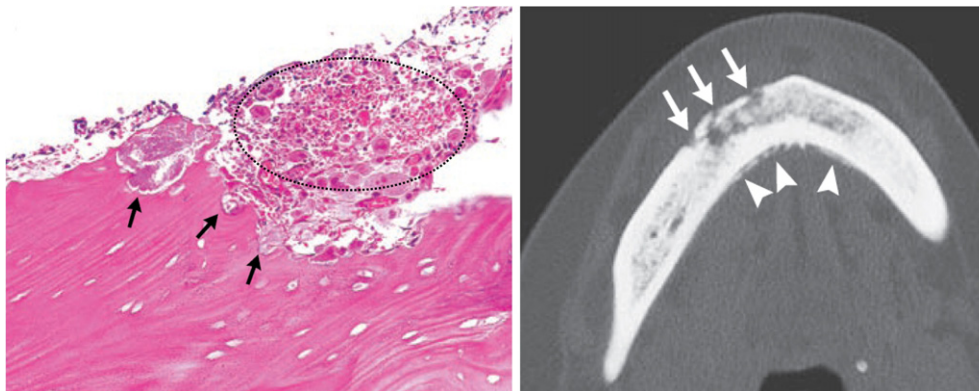
### Ischemia

Early reports of this condition referred to it as 'avascular necrosis'. It is quite unclear why this etiology was assumed, since ONJ tissue is reported to bleed at the time of surgery, and Hansen has noted patent vessels in seven out of eight ONJ cases studied histologically [25]. If ONJ were simply an avascular necrosis of bone, then it would be expected to present in the same way as that condition does in the hip or knee, and it is not clear why it would have a predilection for the jaws. Having said this, there is evidence that bisphosphonates can interfere with the proliferation of endothelial cells [26], though micromolar solutions of bisphosphonates will inhibit the proliferation of most cell types (see section on soft tissue effects, below).

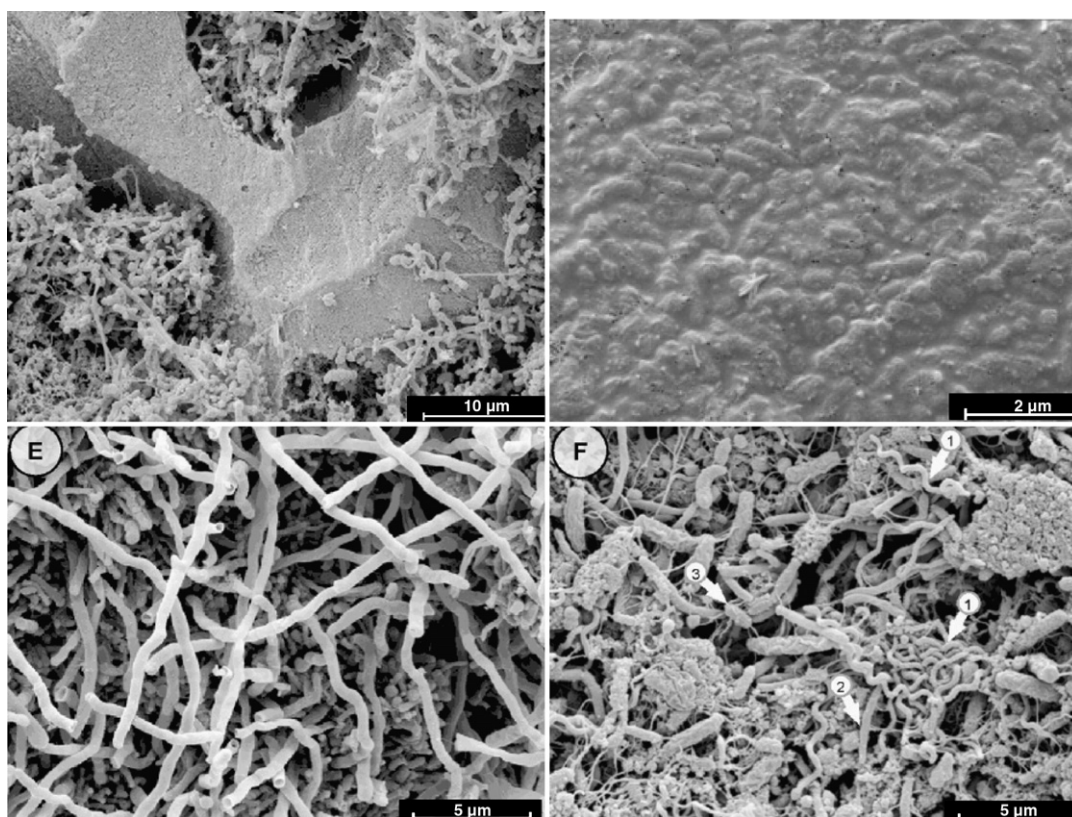
### Low bone turnover

This has been assumed by some authors to be the cause of ONJ, because the therapeutic action of these drugs is to reduce turnover. There is certainly slowed remodeling of bone, and failure of remodeling of bony extraction sockets has been noted [4] even in subjects in whom mucosal healing has occurred. However, there are other conditions associated with chronically reduced bone turnover, such as hypoparathyroidism, in which ONJ-like lesions do not occur. An exception is osteopetrosis, in which exposed bone has been reported, probably because the osteopetrotic mandible is so dense that the development of normal vascular channels is impaired.

However, there is compelling evidence that bone turnover is *not* reduced within ONJ lesions. Deep osteoclastic pits have been demonstrated in a number of reports (Figs. 1 and 2) [25,27,28]. Hansen has now formally compared osteoclast numbers in patients with ONJ, those with radionecrosis, and in control subjects, and shown them to be highest in ONJ subjects, four-fold greater than control [29]. The presence of active bone resorption is self-evident from the frequent reports of radiographic lytic lesions in affected bone (Fig. 1) [30–32]. Bone scintigraphy also suggests that turnover is not suppressed at sites of ONJ, but in fact is above normal. Abu-Id found large zones of increased tracer uptake surrounding areas of necrotic bone in 15 of 16 subjects [4] and that has also been our own



**Fig. 1.** Bone resorption is usually increased in ONJ lesions, both microscopically and radiologically. These images are taken from a 65 year old woman with multiple myeloma who received intravenous bisphosphonates over a 6-year period, subsequently developing ONJ. The left panel shows surface resorption of necrotic bone by osteoclasts, creating a scalloped appearance (arrows). There are neighboring inflammatory cells (dark nuclei) and *Actinomyces* (both are within the dotted ellipse). The right hand panel is a CT scan obtained without contrast medium in the same patient, showing demineralization of the buccal cortex (arrows). There is also increased periosteal reaction along the lingual face of the mandible (arrowheads) and diffusely increased density of the mandibular medullary cavity. From Dodson et al. (2008) *New England Journal of Medicine* 358(12): 1283–1291. Copyright 2008, Massachusetts Medical Society, used with permission.



**Fig. 2.** Images of microbial biofilms within ONJ lesions. The top left panel shows a biofilm filling resorption lacunae on a bone surface. The lower two panels demonstrate biofilms at higher magnification, the left panel being predominately *Actinomyces*, the right panel showing a mixture of bacteria. The top right panel is a higher power view demonstrating classic biofilm architecture, with bacteria embedded in such a dense exopolymeric substance that they are barely visible below the dense slime layer. From Sedghizadeh et al, Journal of Maxillofacial Surgery 66:767, 2008, Copyright American Association of Oral and Maxillofacial Surgery, used with permission.

experience [33]. Chiandussi [30] reported that a Tc-99(m)-MDP three-phase bone scan was the most sensitive tool to detect ONJ in a series of 11 patients who also had CT and MRI scans. It is likely that this paradoxical situation arises from the effects of bacterial infection in the lesions, which drives bone resorption. The reported association between low bone resorption markers and the development of ONJ [34] is not necessarily causal, the low marker levels probably just reflecting recent use of bisphosphonate.

The role of low bone turnover in itself in the development of ONJ is now being rigorously tested in Amgen's clinical trial program for denosumab. This monoclonal antibody against RANKL is being directly compared with zoledronate in trials assessing their comparative efficacy in the management of metastatic prostate cancer, metastatic breast cancer and multiple myeloma. The scale of these trials is such that cases of ONJ will certainly occur in the zoledronate groups. The relative frequency in the denosumab-treated patients will definitively address the question as to whether this is simply a function of low bone turnover or whether it is a more specific toxicity related to the presence of bisphosphonate in bone.

#### *Bisphosphonate toxicity to bone*

It is possible that ONJ is contributed to by direct toxicity of bisphosphonates to bone cells. Bisphosphonates block a key enzyme (farnesyl pyrophosphate synthase) in the mevalonate pathway, which leads to the synthesis of cholesterol and to the production of carbon chains which are important for binding regulatory enzymes to the cytoskeleton. This is the mechanism by which high intracellular concentrations of bisphosphonates are able to cause apoptosis in any cell to which they gain entry. Usually, osteoclasts are the only cell internalizing toxic amounts of bisphosphonate, but in the presence of

high bone concentrations of bisphosphonate or with frequent intravenous dosing, toxicity to other bone cells might occur.

Approximately half of an intravenous dose of bisphosphonate is taken up by the skeleton, where it is retained indefinitely [35,36]. Human [37] and rat [38] studies show that skeletal uptake of bisphosphonate is sustained with long-term administration. The cortical bone of the mandible has much higher turnover than appendicular sites [39], and this is particularly true for the alveolar bone [40]. Therefore, bisphosphonates will be selectively concentrated into the jaw, and we have previously estimated that 4 years use of zoledronate at a dose of 4 mg/month would result in an average skeletal content of 70 nmol/g of bone [41], and probably two to three times this level in alveolar bone. Cell toxicity occurs in solutions with zoledronate concentrations of 1 nmol/mL, though this may be less evident when the bisphosphonate is bound to bone [42]. Cells other than osteoclasts take up bisphosphonate by fluid-phase endocytosis, a unidirectional process that leads to the progressive intracellular accumulation of drug, since there is no known mechanism for its re-release or metabolism [43]. Frequent intravenous dosing over long periods will maximize intracellular bisphosphonate concentrations in non-osteoclast cells.

There is evidence that bisphosphonates cause necrosis in the mandible, even when ONJ is not clinically apparent. For instance, matrix necrosis has been observed in 25–33% of beagle dogs treated with alendronate in doses comparable to those used in osteoporosis and Paget's disease for 3 years [44]. These necrotic regions occur predominantly in the alveolar bone and show absence of patent canaliculi. No such abnormalities were evident in vehicle-treated animals.

In addition to the lytic changes on radiographs, mentioned above, sclerosis is also frequently observed [45,46] and is likely to represent

the presence of necrotic bone. However, assessment of osteocyte viability in bone affected by ONJ indicates that it is not uniformly necrotic, though some osteocytic lacunae are empty [25]. The finding that ONJ is most common with the agents which are the most potent inhibitors of the target enzyme would be consistent with bone toxicity. However, generalized bone toxicity does not occur with high-dose bisphosphonate therapy, since this is not manifested at other sites and since there is no evidence of impairment of fracture healing in bisphosphonate-treated subjects [20].

### Infection

As reports of histological assessments of this condition become more numerous, the consistent finding of infection is striking, and this is commonly associated with complaints of pain [34]. A variety of species have been implicated, but *Actinomyces* is a common, if not universal, finding [4,25,31,32] (Fig. 1). The isolation and identification of *Actinomyces* species by conventional methods remains problematic, so clinical cases may be under-reported or mis-identified [47]. The presence of infection might account for the frequent finding of soft tissue inflammatory changes and lymphadenopathy in imaging studies [30,31].

Very recently, Sedghizadeh [27] carried out scanning electron microscopy in four patients with ONJ, and reported the presence of microbial biofilms in all four (Fig. 2). Biofilms consist of a dense layer of mixed micro-organisms embedded in a polysaccharide matrix secreted by the microbes [48]. Biofilms are fixed to the underlying surface, and are resistant to both host defences (antibodies and phagocytes) and to antibacterial agents. Frequently, surgical removal of the biofilms is required to effect a cure. This resistance to intrinsic and external defences is probably attributable to reduced access of agents and host cells to the inside of the biofilm, and to reduced growth rates of bacteria once they are incorporated into such a structure. The conditions within these films favor growth of anaerobic organisms, but biofilms contain channels in which nutrients can circulate, so aerobic microbes are also commonly present. Biofilms occur frequently in a variety of chronic infections, including dental sepsis, osteomyelitis, osteoradionecrosis, cystic fibrosis, and infections on prostheses and catheters. Light microscopy and simple swabs for bacterial cultures often fail to identify the presence of bacteria in biofilms, so their prevalence is under-appreciated. It is likely that the development of biofilms in ONJ lesions is a result of the local environment and the chronicity of the lesions, though it is possible

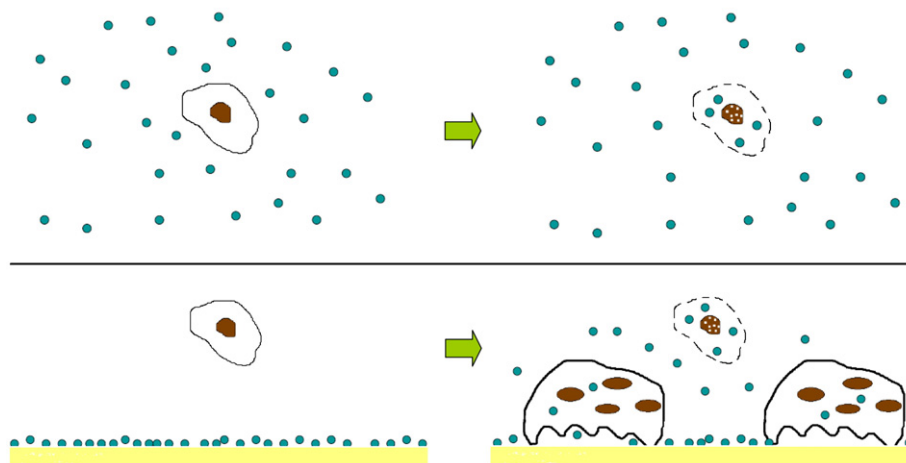
that the presence of bisphosphonates on the bone surface facilitates their development.

The presence of infection may be important in producing one of the unexpected but consistent features of this condition – increased bone resorption despite the presence of bisphosphonate in bone. Many bacteria have been shown to stimulate bone resorption, and some to inhibit bone formation. The best characterized mediators of bacterial osteolysis are the lipopolysaccharides from gram-negative bacteria, which probably act by stimulating local cytokine production [49]. However, there are numerous other factors from bacteria which have similar effects through a variety of mechanisms. For instance, proteins from *Porphyromonas gingivalis* directly regulate production of RANKL and osteoprotegerin in human periodontal ligament cells and gingival fibroblasts, increasing stimulation of osteoclastogenesis [50]. The close link between bacterial infection and bone resorption is suggested by the upper left panel of Fig. 2, which shows microbial biofilms sitting inside resorption lacunae on the surface of an ONJ lesion.

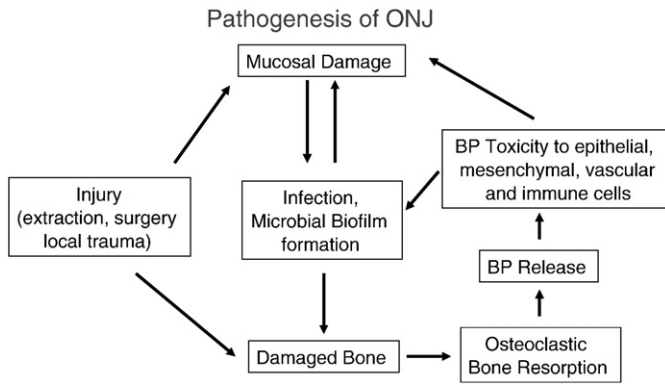
### Bisphosphonate toxicity to soft tissue

We have proposed that soft tissue toxicity from bisphosphonates might be involved in the pathogenesis of ONJ [41]. Exposure to micromolar concentrations of these compounds *in solution* produces toxic effects in many cells, including monocytes [51,52], macrophages, periodontal ligament fibroblasts [53], endothelial cells [26,54–56], a variety of tumor cells, osteoblasts, and epithelial cells [57–59]. However, it has not been clear to what extent bisphosphonates on bone surfaces are toxic to adjacent cells. This issue has recently been explored in detail by Coxon et al. [42]. They confirmed the toxicity of bisphosphonate solutions to several cell types but showed that this was greatly reduced in the presence of bone, because the bisphosphonate was taken up onto the bone surface. They also showed that bisphosphonate-labeled bone caused only minimal toxicity to cultured cells. However, when osteoclasts were added to these cultures, bisphosphonate was mobilized from bone and transferred to adjacent cells. Thus, bisphosphonate toxicity to non-osteoclast cells is facilitated by the presence of osteoclasts, as occurs at an infected bone surface. This scenario is shown in schematic form in Fig. 3.

It is likely that this is the scenario that obtains in ONJ, where bone is heavily labeled with bisphosphonate but very active bone resorption still takes place, driven by bacterial infection and/or dissolution of necrotic bone. This leads to release of high



**Fig. 3.** Mechanisms for bisphosphonate toxicity on non-osteoclast cells, based on the findings of Coxon et al [42]. In the absence of a bone surface, bisphosphonate in solution is taken up by cells, resulting in toxicity mediated through its inhibition of the mevalonate pathway (upper panel). In the presence of a bone surface (lower panel), the bisphosphonate becomes tightly bound to hydroxyapatite and is not available to act on non-bone cells. However, in the presence of osteoclasts, bone resorption takes place (lower right panel) and bisphosphonate mobilized from the bone surface is able to pass to other cells. If the number of osteoclasts is sufficient and the concentration of bisphosphonate on the bone's surface is high enough, then soft tissue toxicity is likely to result. Copyright IR Reid 2008, used with permission.



**Fig. 4.** Possible scenario for the interactions of factors contributing to the development of osteonecrosis of the jaw. Copyright IR Reid 2008, used with permission.

concentrations of bisphosphonate into the immediate environment, and its uptake into regenerating epithelial, vascular, mesenchymal and immune cells (Fig. 4). Thus, a vicious cycle is established in which the bone and soft tissue lesion originally caused by a tooth extraction is unable to heal because of persisting infection, resulting in sustained bone resorption and the release of cytotoxic bisphosphonates. Sometimes the initiating trauma is less dramatic, such as that from dentures, from chewing food, or from local infection such as periodontitis. This pathogenic cascade suggests that management should target prevention and treatment of infection, and cessation of further bisphosphonate administration, as immediate therapeutic priorities.

## Management

Management strategies need to consider both prevention and treatment of this condition. For patients with malignancy, pre-treatment dental examinations are important. Ripamonti has shown in a retrospective survey of patients treated with zoledronate, that the performance of a dental examination and the application of preventive measures led to a sustained reduction in ONJ occurrence from 7.8% to 1.7% ( $P=0.016$ ) [60]. Reducing bisphosphonate dose is a promising line of prevention in the context of oncology practice, and early results suggest that three-monthly administration of intravenous bisphosphonate is safer than monthly administration [61]. Avoidance of invasive dental procedures is also an important preventive strategy.

In the management of established disease, case reports have suggested that aggressive surgical intervention is counterproductive, though two recent case series showed an 86% [4] and 83% [62] positive response to such initiatives. Other reports support a role for limited surgical intervention [63,64]. There is also broad endorsement for the use of antibiotics, mouthwashes and discontinuation of bisphosphonates [65]. Possibly direct physical measures to disrupt and remove the biofilms from infected bone surfaces might help.

For patients with osteoporosis, in the absence of clear evidence that ONJ is any more common than in the general population, specific preventative measures do not seem to be warranted. Many dentists have failed to appreciate the difference in bisphosphonate doses between oncology and osteoporosis patients and the attendant difference in ONJ prevalence. This has led to unnecessary concern for many such patients.

## Conclusions

It is likely that ONJ results from direct toxicity to cells of bone and soft tissue from high potency bisphosphonates, probably acting through their effects on the mevalonate pathway. The bone in ONJ

lesions does not appear to be 'frozen' but rather there is very active resorption present, which is likely to be responsible for the local release at high concentrations of bisphosphonates. Infection probably plays a pivotal role in the pathogenesis of this condition, so its active management is of key importance. There is a need to clearly delineate the incidence of ONJ in osteoporosis patients treated with bisphosphonates, and in appropriate control populations. Based on current evidence, the risk of ONJ in osteoporosis appears to be comparable to that in the general population.

## Competing interests

IRR has received research support from and acted as a consultant for Merck, Novartis, Amgen and Procter & Gamble.

## References

- [1] Khosla S, Burr D, Cauley J, Dempster DW, Ebeling PR, Felsenberg D, et al. Bisphosphonate-associated osteonecrosis of the jaw: report of a task force of the American Society for Bone and Mineral Research. *J Bone Mineral Res* 2007;22:1479–91.
- [2] American Association of Oral and Maxillofacial Surgeons. American Association of Oral and Maxillofacial Surgeons position paper on bisphosphonate-related osteonecrosis of the jaws. *J Oral Maxillofac Surg* 2007;65:369–76.
- [3] Khosla S, Burr D, Cauley J, Dempster DW, Ebeling PR, Felsenberg D, et al. American Society for Bone and Mineral R. Bisphosphonate-associated osteonecrosis of the jaw: report of a task force of the American Society for Bone and Mineral Research. *J Bone Mineral Res* 2007;22:1479–91.
- [4] Abu-Id MH, Warnke PH, Gottschalk J, Springer I, Wiltfang J, Acil Y, et al. Bis-phosphy jaws" – high and low risk factors for bisphosphonate-induced osteonecrosis of the jaw. *J Cranio-Maxillofac Surg* 2008;36:95–103.
- [5] Felsenberg D, Hoffmeister B, Amling M. Kiefernekrosen nach hoch dosierter Bisphosphonattherapie. *Dtsch Arztebl* 2006;103:3078–81.
- [6] Fugazzotto PA, Lightfoot WS, Jaffin R, Kumar A. Implant placement with or without simultaneous tooth extraction in patients taking oral bisphosphonates: post-operative healing, early follow-up, and the incidence of complications in two private practices. *J Periodontol* 2007;78:1664–9.
- [7] Bell BM, Bell RE. Oral bisphosphonates and dental implants: a retrospective study. *J Oral Maxillofac Surg* 2008;66:1022–4.
- [8] Grant BT, Amenedo C, Freeman K, Kraut RA. Outcomes of placing dental implants in patients taking oral bisphosphonates: a review of 115 cases. *J Oral Maxillofac Surg* 2008;66:223–30.
- [9] Jeffcoat MK. Safety of oral bisphosphonates: controlled studies on alveolar bone. *Int J Oral Maxillofac Implants* 2006;21:349–53.
- [10] Wessel JH, Dodson TB, Zavras AI. Zoledronate, smoking, and obesity are strong risk factors for osteonecrosis of the jaw: a case-control study. *J Oral Maxillofac Surg* 2008;66:625–31.
- [11] Khamaisi M, Regev E, Yarom N, Avni B, Leitersdorf E, Raz I, et al. Possible association between diabetes and bisphosphonate-related jaw osteonecrosis. *J Clin Endocrinol Metab* 2007;92:1172–5.
- [12] Hoff AO, Toth BB, Altundag K, Guarnieri V, Adamus A, Nooka AK, Sayegh GG, Johnson MM, Gagel RF, Hortobagyi GN. Osteonecrosis of the jaw in patients receiving intravenous bisphosphonate therapy. *J Clin Oncol* 2006;24(suppl):8528.
- [13] Durie BGM, Katz M, Crowley J. Osteonecrosis of the jaw and bisphosphonates. *N Engl J Med* 2005;353:99–100.
- [14] Cafo AM. Osteonecrosis of the jaw in patients with multiple myeloma treated with bisphosphonates: definition and management of the risk related to zoledronic acid. *Clin Lymphoma Myeloma* 2008;8:111–6.
- [15] Wilkinson GS, Kuo YF, Freeman JL, Goodwin JS. Intravenous bisphosphonate therapy and inflammatory conditions or surgery of the jaw: a population-based analysis. *J Natl Canc Inst* 2007;99:1016–24.
- [16] Cartos VM, Zhu S, Zavras AI. Bisphosphonate use and the risk of adverse jaw outcomes. *JADA* 2008;139:23–30.
- [17] Yarom N, Yahalom R, Shoshani Y, Hamed W, Regev E, Elad S. Osteonecrosis of the jaw induced by orally administered bisphosphonates: incidence, clinical features, predisposing factors and treatment outcome. *Osteoporos Int* 2007;18:1363–70.
- [18] Black DM, Delmas PD, Eastell R, Reid IR, Boonen S, Cauley JA, Cosman F, Lakatos P, Leung PC, Man Z, Mautalen C, Mesenbrink P, Hu HL, Caminis J, Tong K, Rosario-Jansen T, Krasnow J, Hue TF, Sellmeyer D, Eriksen EF, Cummings SR. Once-yearly zoledronic acid for treatment of postmenopausal osteoporosis. *N Engl J Med* 2007;356:1809–22.
- [19] Grbic JT, Landesberg R, Lin SQ, Mesenbrink P, Reid IR, Leung PC, et al. Incidence of osteonecrosis of the jaw in women with postmenopausal osteoporosis in the Health Outcomes and Reduced Incidence With Zoledronic Acid Once Yearly Pivotal Fracture Trial. *JADA* 2008;139:32–40.
- [20] Lyles KW, Colon-Emeric CS, Magaziner JS, Adachi JD, Pieper CF, Mautalen C, et al. Zoledronic acid and clinical fractures and mortality after hip fracture. *N Engl J Med* 2007;357:1799–809.
- [21] Pazianas M, Blumentals WA, Miller PD. Lack of association between oral bisphosphonates and osteonecrosis using jaw surgery as a surrogate marker. *Osteoporos Int* 2008;19:773–9.

- [22] Reid IR, Miller P, Lyles K, Fraser W, Brown JP, Saidi Y, et al. Comparison of a single infusion of zoledronic acid with risedronate for Paget's disease. *N Engl J Med* 2005; 353:898–908.
- [23] Malmgren B, Atrom E, Soderhall S. No osteonecrosis in jaws of young patients with osteogenesis imperfecta treated with bisphosphonates. *J Oral Pathol Med* 2008;37: 196–200.
- [24] Mavrokokki T, Cheng A, Stein B, Goss AAFNMT, Cheng A, Stein B, Goss A. Nature and frequency of bisphosphonate-associated osteonecrosis of the jaws in Australia. *J Oral Maxillofac Surg* 2007;65:415–23.
- [25] Hansen T, Kunkel M, Weber A, Kirkpatrick CJ. Osteonecrosis of the jaws in patients treated with bisphosphonates — histomorphologic analysis in comparison with infected osteoradionecrosis. *J Oral Pathol Med* 2006;35:155–60.
- [26] Fournier P, Boissier S, Filleur S, Guglielmi J, Cabon F, Colombel M, Clezardin P. Bisphosphonates inhibit angiogenesis in vitro and testosterone-stimulated vascular regrowth in the ventral prostate in castrated rats. *Cancer Res* 2002;62: 6538–44.
- [27] Sedghizadeh PP, Kumar SKS, Gorur A, Schaudinn C, Shuler CF, Costerton JW. Identification of microbial biofilms in osteonecrosis of the jaws secondary to bisphosphonate therapy. *J Oral Maxillofac Surg* 2008;66:767–75.
- [28] Dodson TB, Raje NS, Caruso PA, Rosenberg AE, Smullin SE, Harris NL. A woman with a nonhealing ulcer of the jaw — Gingival ulceration, inflammation, and acute osteomyelitis with actinomycetes, all associated with necrosis of bone (bisphosphonate-related osteonecrosis of bone). *N Engl J Med* 2008;358:1283–91.
- [29] Hansen T, Kirkpatrick CJ, Walter C, Kunkel M. Increased numbers of osteoclasts expressing cysteine proteinase cathepsin K in patients with infected osteoradionecrosis and bisphosphonate-associated osteonecrosis — a paradoxical observation? *Virchows Archiv* 2006;449:448–54.
- [30] Chiandussi S, Biasotto M, Dore F, Cavalli F, Cova MA, Di Lenarda R. Clinical and diagnostic imaging of bisphosphonate-associated osteonecrosis of the jaws. *Dentomaxillofac Radiol* 2006;35:236–43.
- [31] Bisdas S, Pinho NC, Smolarz A, Sader R, Vogl TJ, Mack MG. Bisphosphonate-induced osteonecrosis of the jaws: CT and MRI spectrum of findings in 32 patients. *Clin Radiol* 2008;63:71–7.
- [32] Biasotto M, Chiandussi S, Dore F, Rinaldi A, Rizzardi C, Cavalli F, et al. Clinical aspects and management of bisphosphonates-associated osteonecrosis of the jaws. *Acta Odontol Scand* 2006;64:348–54.
- [33] Reid IR, Cundy T. Osteonecrosis of the jaw. *Skelet Radiol* 2008 (in press).
- [34] Marx RE, Cillo JE, Ulloa JJ. Oral bisphosphonate-induced osteonecrosis: risk factors, prediction of risk using serum CTX testing, prevention, and treatment. *J Oral Maxillofac Surg* 2007;65:2397–410.
- [35] Reid IR, Brown JP, Burckhardt P, Horowitz Z, Richardson P, Trechsel U, et al. Intravenous zoledronic acid in postmenopausal women with low bone mineral density. *N Engl J Med* 2002;346:653–61.
- [36] Khan SA, Kanis JA, Vasikaran S, Kline WF, Matuszewski BK, McCloskey EV, et al. Elimination and biochemical responses to intravenous alendronate in postmenopausal osteoporosis. *J Bone Mineral Res* 1997;12:1700–7.
- [37] Skerjanec A, Berenson J, Hsu C, Major P, Miller Jr WH, Ravera C, et al. The pharmacokinetics and pharmacodynamics of zoledronic acid in cancer patients with varying degrees of renal function. *J Clin Pharmacol* 2003;43:154–62.
- [38] Lin JH, Chen IW, Duggan DE. Effects of dose, sex, and age on the disposition of alendronate, a potent antiosteolytic bisphosphonate, in rats. *Drug Metab Dispos* 1992;20:473–8.
- [39] Dixon RB, Tricker ND, Garetto LP. Bone turnover in elderly canine mandible and tibia. *J Dental Res* 1997;76:336.
- [40] Baron R, Saffar JL, Duflot-Vignery A. Alveolar bone remodelling in the rat: normal status and effects of PTX and PTH on the remodelling sequence and the osteoclastic pool. *Calcif Tissue Res* 1977;22(Suppl):502–4.
- [41] Reid IR, Bolland MJ, Grey AB. Is bisphosphonate-associated osteonecrosis of the jaw caused by soft tissue toxicity? *Bone* 2007;41:318–20.
- [42] Coxon FP, Thompson K, Roelofs AJ, Ebetino FH, Rogers MJ. Visualizing mineral binding and uptake of bisphosphonate by osteoclasts and non-resorbing cells. *Bone* 2008;42:848–60.
- [43] Thompson K, Rogers MJ, Coxon FP, Crockett JC. Cytosolic entry of bisphosphonate drugs requires acidification of vesicles after fluid-phase endocytosis. *Mol Pharmacol* 2006;69:1624–32.
- [44] Allen MR, Burr DB. Mandible matrix necrosis in beagle dogs after 3 years of daily oral bisphosphonate treatment. *J Oral Maxillofac Surg* 2008;66:987–94.
- [45] Wutzl A, Eisenmenger G, Hoffmann M, Czerny C, Moser D, Pietschmann P, et al. Osteonecrosis of the jaws and bisphosphonate treatment in cancer patients. *Wien Klin Wochenschr* 2006;118:473–8.
- [46] Bedogni A, Blandamura S, Lokmic Z, Palumbo C, Ragazzo M, Ferrari F, et al. Bisphosphonate-associated jawbone osteonecrosis: a correlation between imaging techniques and histopathology. *Oral Med Oral Pathol Oral Radiol Endodontology* 2008;105:358–64.
- [47] Hall V. Actinomycetes—gathering evidence of human colonization and infection. *Anaerobe* 2008;14:1–7.
- [48] Costerton JW, Stewart PS, Greenberg EP. Bacterial biofilms: a common cause of persistent infections. *Science* 1999;284:1318–22.
- [49] Nair SP, Meghji S, Wilson M, Reddi K, White P, Henderson B. Bacterially induced bone destruction: mechanisms and misconceptions. *Infect Immun* 1996;64: 2371–80.
- [50] Belibasakis GN, Bostanci N, Hashim A, Johansson A, Aduse-Opoku J, Curtis MA, et al. Regulation of RANKL and OPG gene expression in human gingival fibroblasts and periodontal ligament cells by *Porphyromonas gingivalis*: a putative role of the Arg-gingipains. *Microb Pathog* 2007;43:46–53.
- [51] Hewitt RE, Lissina A, Green AE, Slay ES, Price DA, Sewell AK. The bisphosphonate acute phase response: rapid and copious production of proinflammatory cytokines by peripheral blood gamma delta T cells in response to aminobisphosphonates is inhibited by statins. *Clin Exp Immunol* 2005;139:101–11.
- [52] Ishikawa C, Matsuda T, Okudaira T, Tomita M, Kawakami H, Tanaka Y, et al. Bisphosphonate incadronate inhibits growth of human T-cell leukaemia virus type I-infected T-cell lines and primary adult T-cell leukaemia cells by interfering with the mevalonate pathway. *Brit J Haematol* 2007;136:424–32.
- [53] Correia VDP, Caldeira CL, Marques MM. Cytotoxicity evaluation of sodium alendronate on cultured human periodontal ligament fibroblasts. *Dental Traumatol* 2006;22:312–7.
- [54] Hashimoto K, Morishige KI, Sawada K, Tahara M, Shimizu S, Ogata S, et al. Alendronate suppresses tumor angiogenesis by inhibiting Rho activation of endothelial cells. *Biochem Biophys Res Comm* 2007;354:478–84.
- [55] Moreira MS, Katayama E, Bombana AC, Marques MM. Cytotoxicity analysis of alendronate on cultured endothelial cells and subcutaneous tissue. A pilot study. *Dent Traumatol* 2005;21:329–35.
- [56] Ribatti D, Maruotti N, Nico B, Longo V, Mangierv D, Vacca A, et al. Clodronate inhibits angiogenesis in vitro and in vivo. *Oncol Rep* 2008;19: 1109–12.
- [57] Roelofs AJ, Thompson K, Gordon S, Rogers MJ. Molecular mechanisms of action of bisphosphonates: current status. *Clin Cancer Res* 2006;12:6222S–30S.
- [58] Reszka AA, Halasy-Nagy J, Rodan GA. Nitrogen-bisphosphonates block retinoblastoma phosphorylation and cell growth by inhibiting the cholesterol biosynthetic pathway in a keratinocyte model for esophageal irritation. *Mol Pharmacol* 2001;59:193–202.
- [59] Landesberg R, Cozin M, Cremers S, Woo V, Kousteni S, Sinha S, et al. Inhibition of oral mucosal cell wound healing by bisphosphonates. *J Oral Maxillofac Surg* 2008; 66:839–47.
- [60] Ripamonti CI, Maniezzo M, Campa T, Fagnoni E, Brunelli C, Saibene G, Bareggi C, Asciani L, Cislighi E. Decreased occurrence of osteonecrosis of the jaw after implementation of dental preventive measures in solid tumour patients with bone metastases treated with bisphosphonates. The experience of the National Cancer Institute of Milan. *Ann Oncol* 2008.
- [61] Corso A, Varettoni M, Zappasodi P, Klersy C, Mangiacavalli S, Pica G, et al. A different schedule of zoledronic acid can reduce the risk of the osteonecrosis of the jaw in patients with multiple myeloma. *Leukemia* 2007;21:1545–8.
- [62] Adornato MC, Morcos I, Rozanski J. The treatment of bisphosphonate-associated osteonecrosis of the jaws with bone resection and autologous platelet-derived growth factors. *JADA* 2007;138:971–7.
- [63] Kademani D, Koka S, Lacy MQ, Rajkumar SV. Primary surgical therapy for osteonecrosis of the jaw secondary to bisphosphonate therapy. *Mayo Clin Proc* 2006;81:1100–3.
- [64] Ibrahim T, Barbanti F, Giorgio-Marrano G, Mercatali L, Ronconi S, Vicini C, et al. Osteonecrosis of the jaw in patients with bone metastases treated with bisphosphonates: a retrospective study. *Oncologist* 2008;13:330–6.
- [65] Magopoulos C, Karakinaris G, Telioudis Z, Vahtsevanos K, Dimitrakopoulos I, Antoniadis K, et al. Osteonecrosis of the jaws due to bisphosphonate use. A review of 60 cases and treatment proposals. *Amer J Otolaryngol* 2007;28:158–63.