

OM Case Report



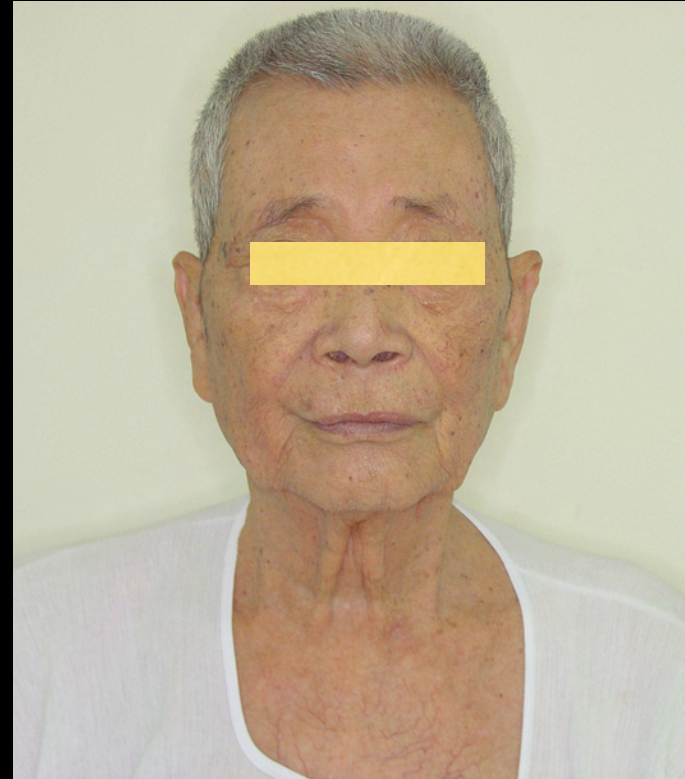報告者 : intern E組

指導醫師 : 口腔病理科全體醫師

報告日期 : 96/10/26

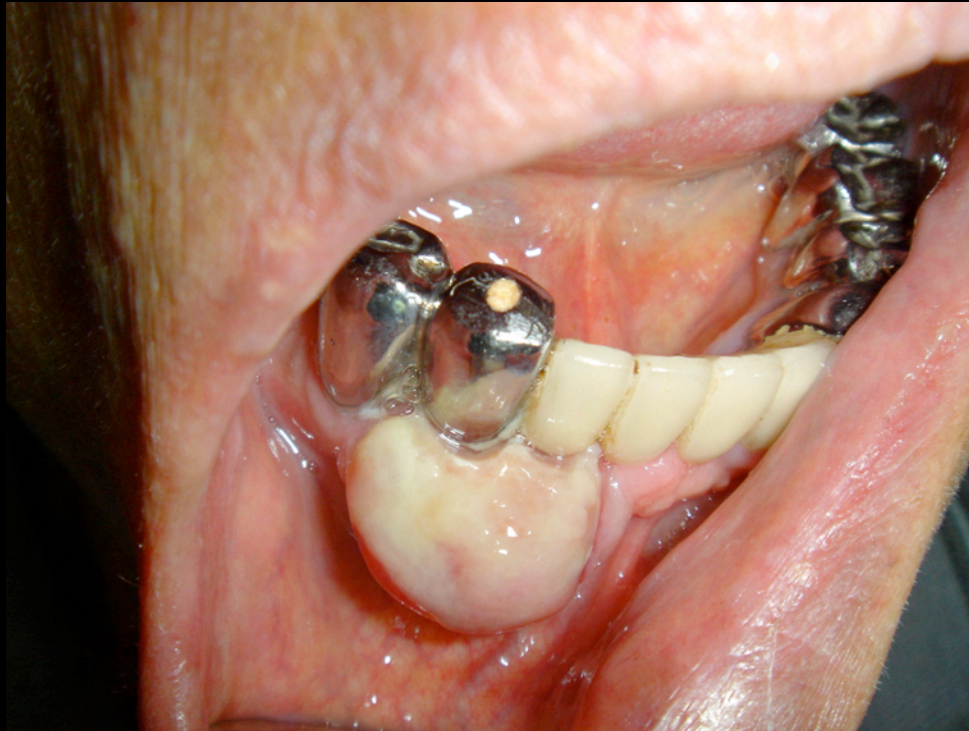General Data

- Name : 周霞峰
- Sex : 男
- Age : 79
- Native : 湖南
- Marital status : 已婚
- Attending VS :
王文岑醫師
- First visit : 96/09/26



Chief Complaint

- A mass over 42, 43 labial gingiva



Present Illness

- The 79 y/o male suffered from the above episode for a period of time. He came with a pathologic report diagnosed by省立屏東hospital dental department (96/09/17) and the report showed the high grade sarcoma was considered and the malignant lymphoma could not be ruled out(2.4x1.2x0.9cm, gingiva).
- 96/09/23 the patient noted the mass had recurred in a short time after biopsy in省立屏東hospital, and he was suggested to come to our OPD for further examination.
- 96/09/26 he came to our OPD and excisional biopsy was done.

Past History

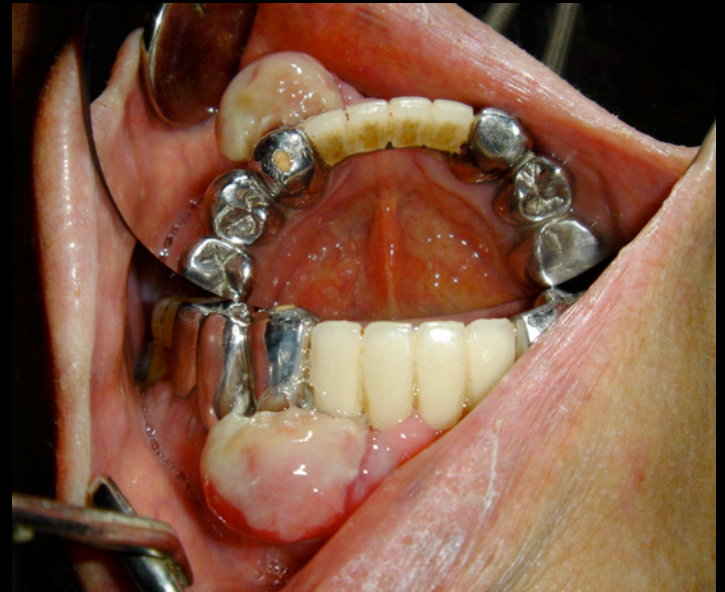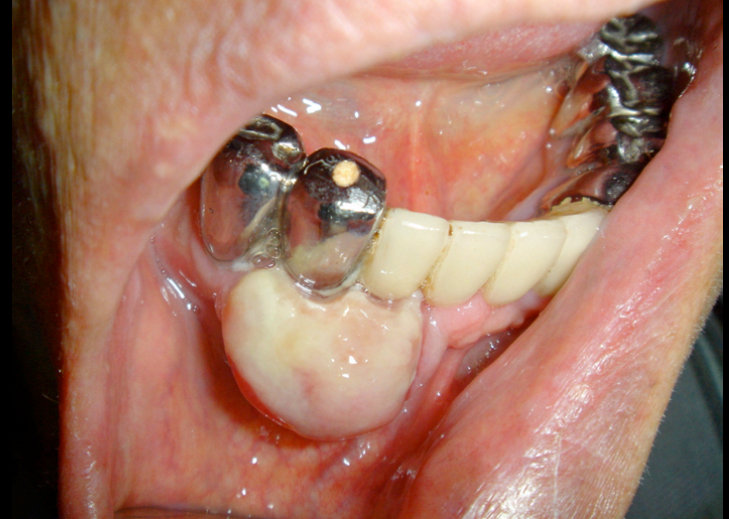- Past medical history
 - Denied any systemic diseases
 - Have been hospitalized for renal stone
 - Varicose vein
 - Denied drug or food allergy
- Past dental history
 - Endo
 - Prosthodontics
 - Extraction
 - Dental experience - cooperation

Personal Habits

- Cigarette : (+), 60年(quit recently)
- Alcohol : (-)
- Betel quid : (-)
- Other oral habits : Denied

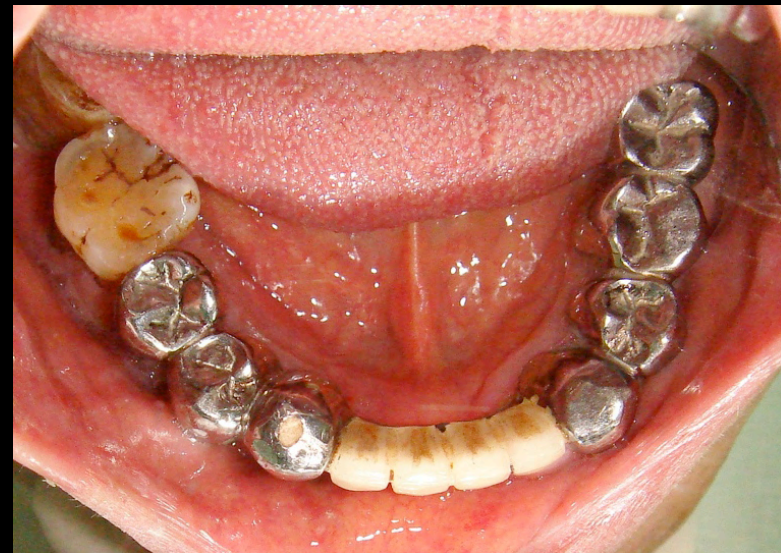
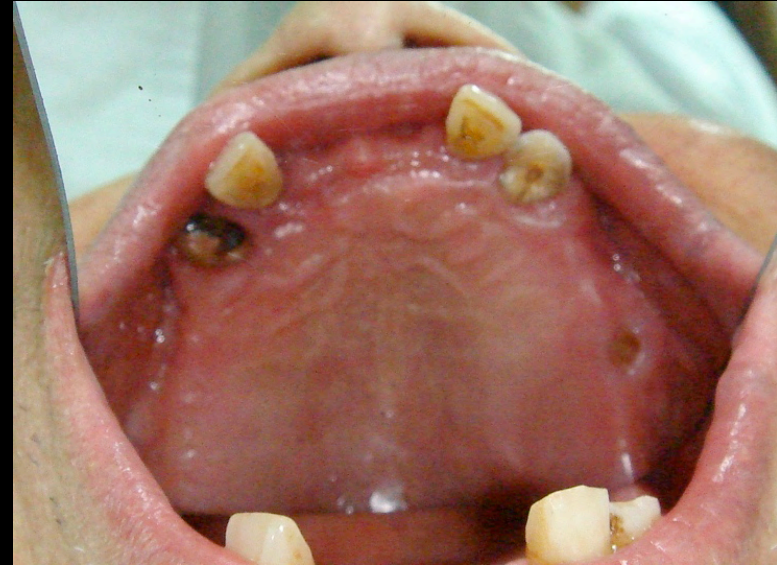Intraoral Examination on 9/26

- A dome-shaped well-defined painless swelling mass with smooth surface over the labial gingiva of tooth 42 & 43
- Ulceration at lower border of the mass
- Size : 2 x 2 cm in diameter
- Sessile base, white & red color with firm consistency
- Gingival recession of 46



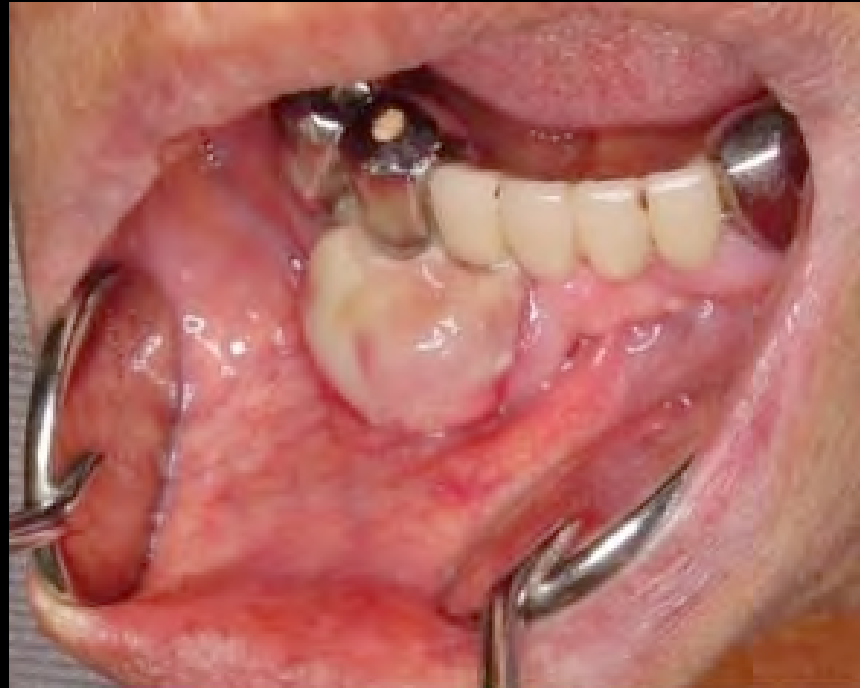Intraoral Examination on 9/26

- Generalized gingival swelling
- Open chamber of 43
- Long span C&B of 45 to 36
- Missing: 11, 14, 15, 16, 17, 18, 21, 24, 25, 27, 28, 31, 32, 36, 37, 38, 41, 42, 48
- Residual root: 13, 26

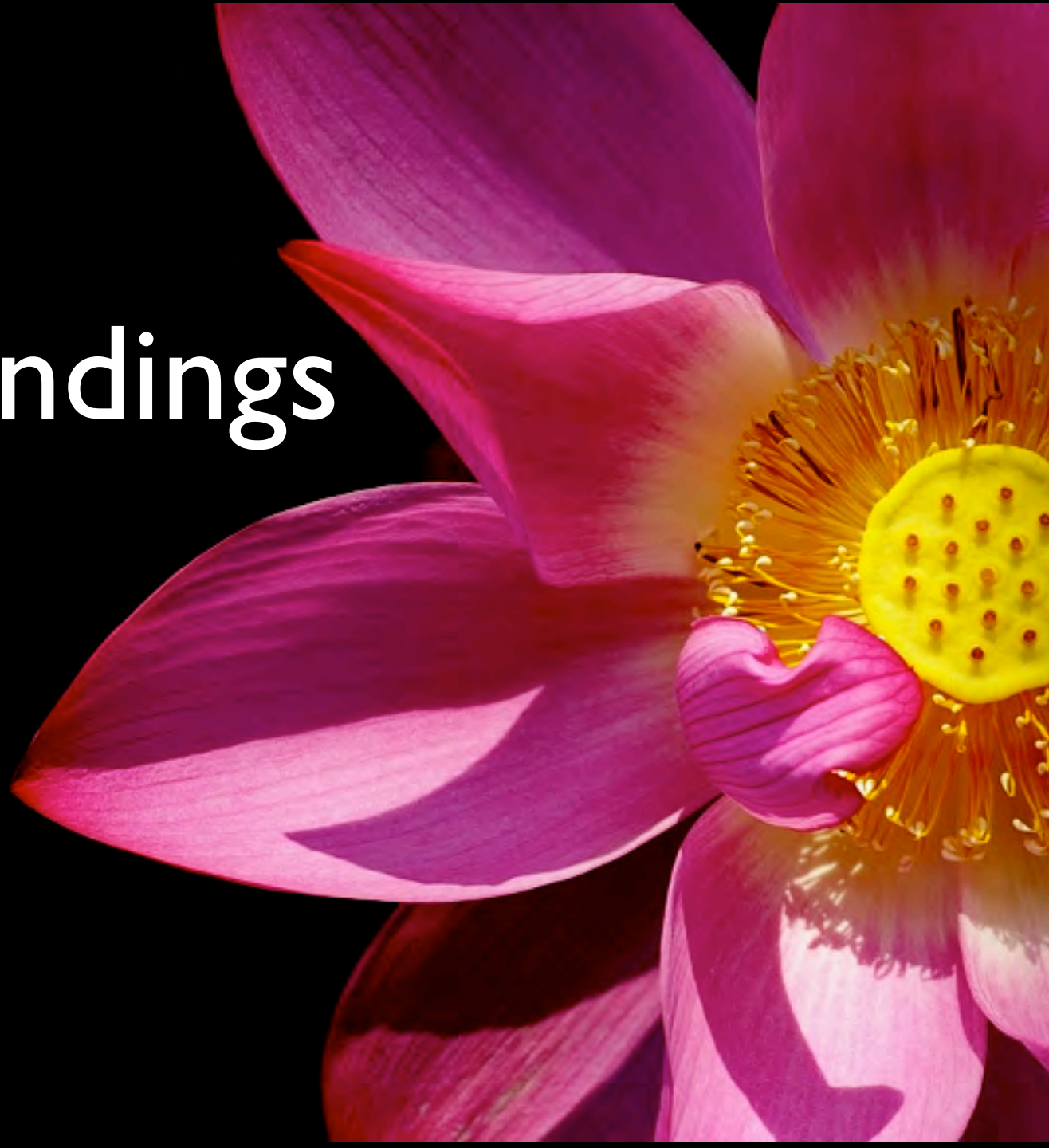

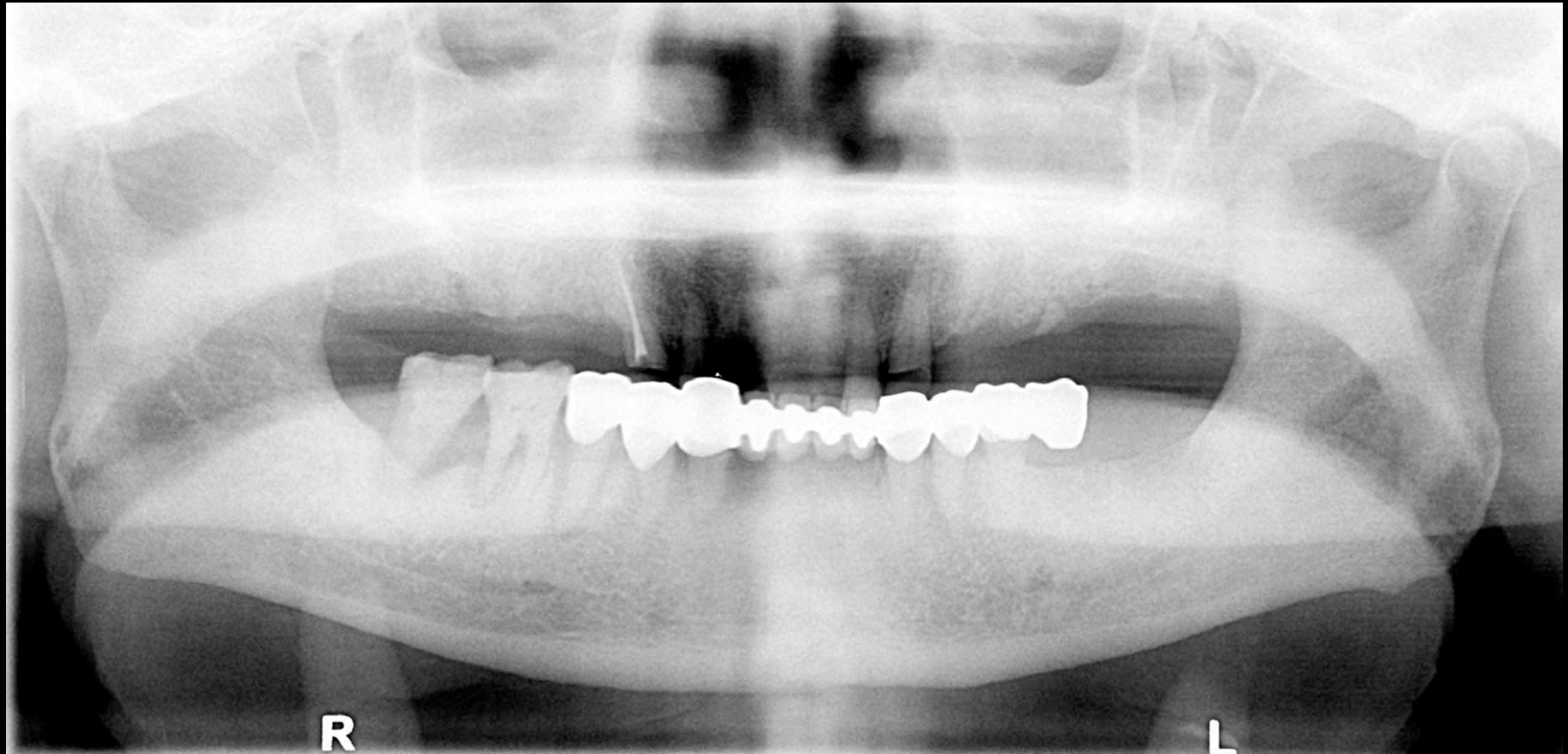
Oral & Maxillofacial Examination

- Duration - Rapid growth (96/09/17~96/09/23)
- (Pain (-))
- Firm(+)
- Well-defined
- Tenderness (-)
- Swelling (+)
- Ulceration (+)
- Fixed (+)
- Induration (+)
- Pus discharge (-)
- Local heat (-)
- Lymphadenopathy (-)

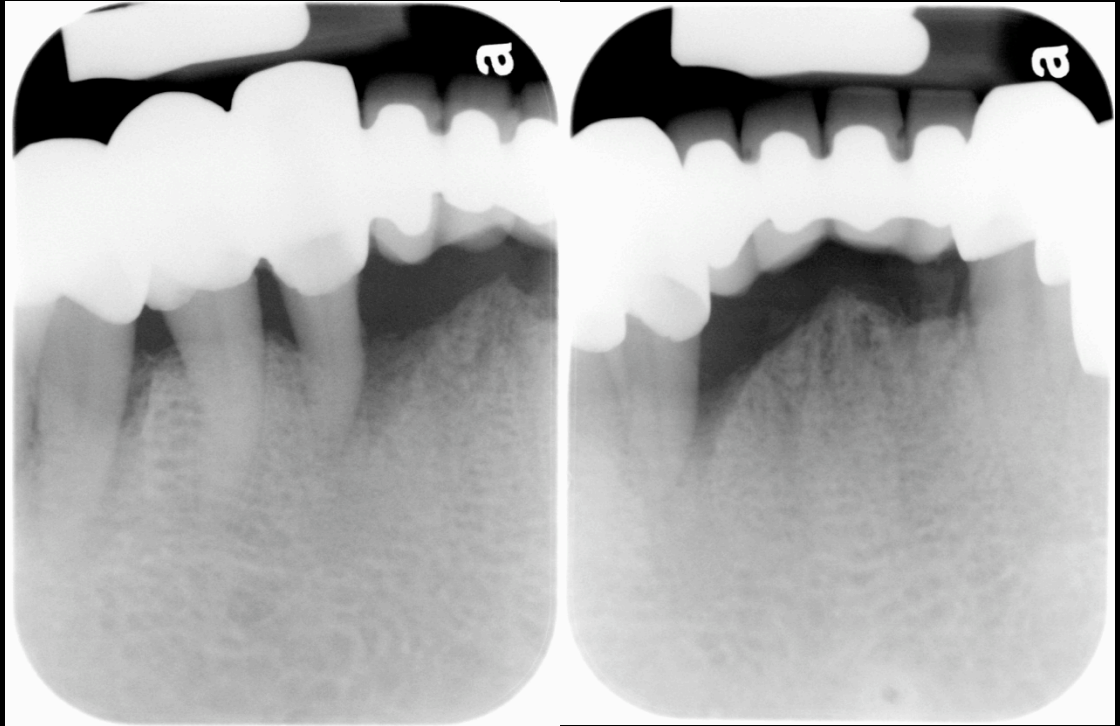
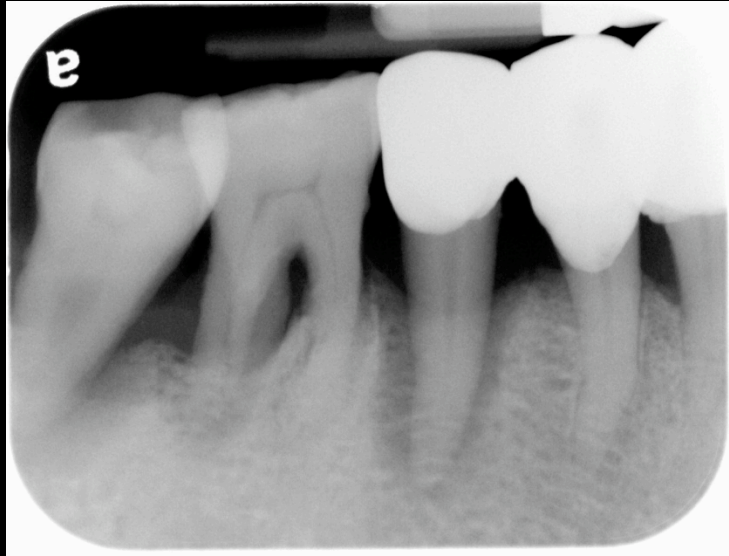

X-ray Findings



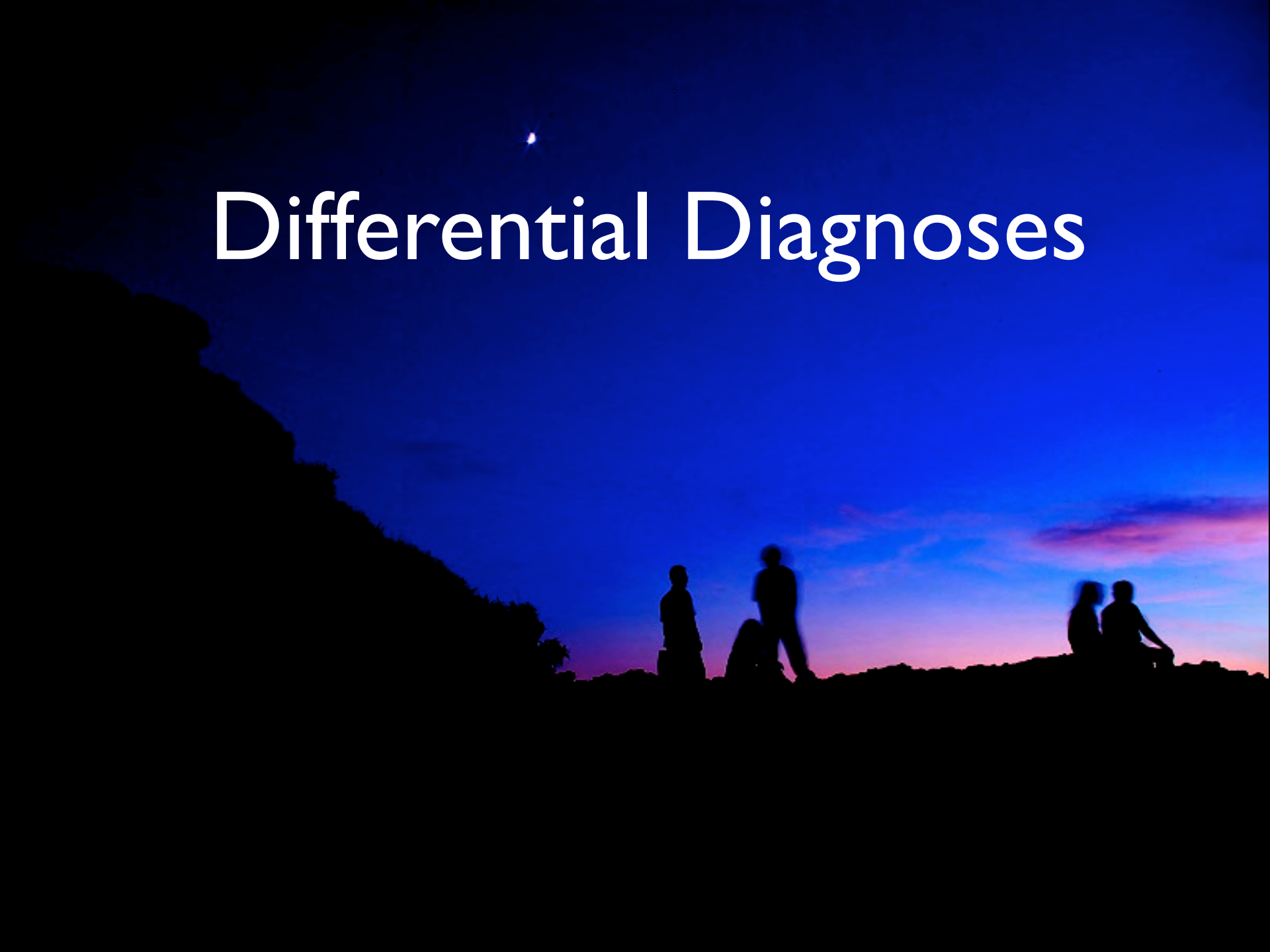

- Missing tooth : 11, 14, 15, 16, 17, 18, 21, 24, 25, 27, 28, 31, 32, 36, 37, 38, 41, 42, 48
- Endodontic condition : 13
- Residual root : 13, 26
- Long span prosthesis : 45.44.43XXXX33.34.35X
- Sinus : NP
- Condyle : NP



- Periodontal condition :
 - total bone loss : 45, 47, distal root of 46
 - angular bone loss : 43 mesial side
- Long span crown bridge 45-36

Differential Diagnoses



Inflammation or cyst or neoplasm

- Local heat(-)
- Pain(-)
- Firm(+)
- Induration(+)
- Fixed(+)
- Tenderness(-)
- Pus discharge(-)

neoplasm

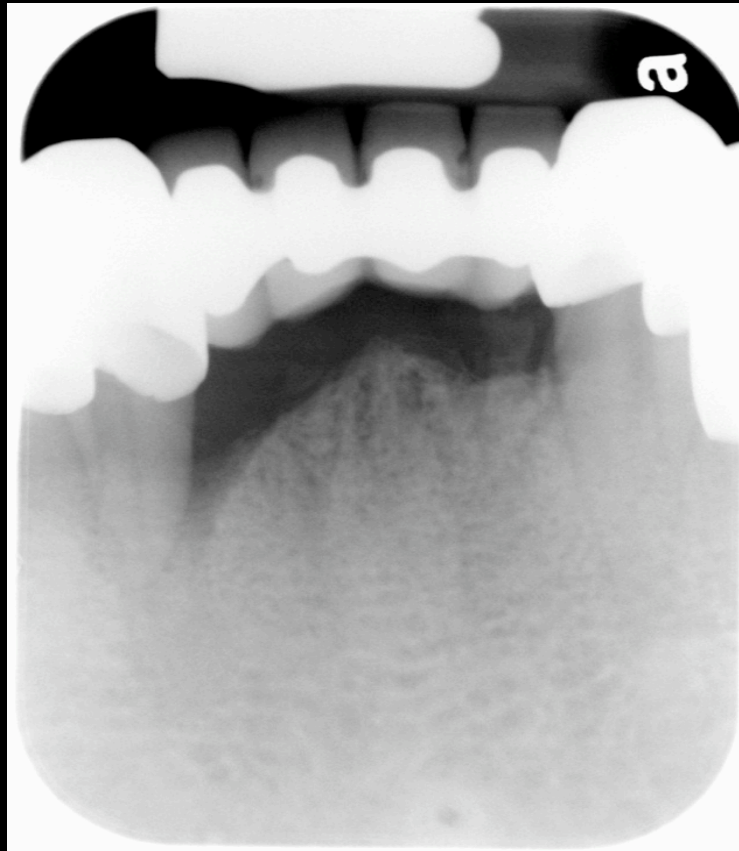Benign or malignant

- Duration-fast growing
- Fixed(+)
- Induration(+)
- Ulceration(+)
- Lymphadenopathy (-)
- Pain(-)

malignant

Intrabony or peripheral

★ Angular bone loss : 43 mesial side



peripheral

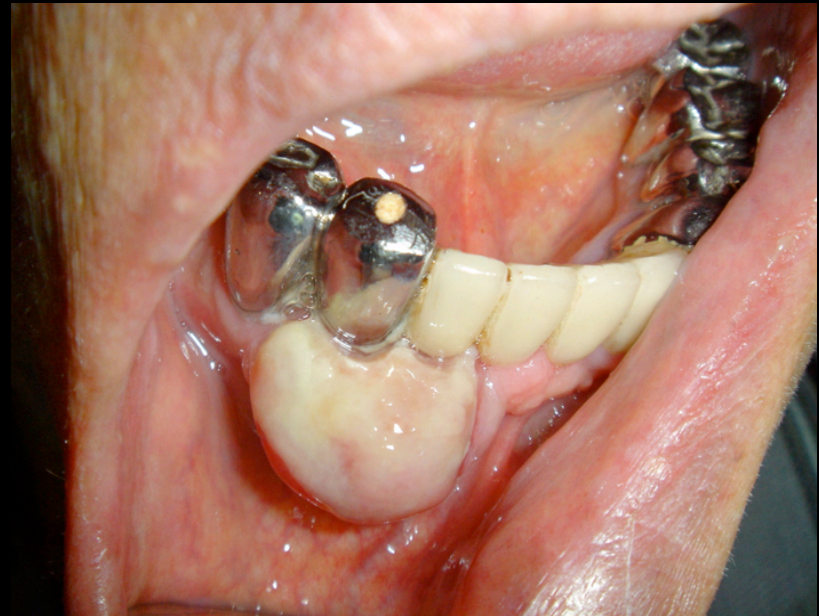Working diagnosis

neoplasm

malignant

peripheral

- Lymphoma
- Fibrosarcoma
- Leiomyosarcoma
- Squamous cell carcinoma
- Mucoepidermoid carcinoma
- Metastatic tumor



	Lymphoma	our case
Gender	no predilection	male
Age	Any age (are in the first decade)	79 y/o
Site	Buccal vestibule/posterior hard palate /gingiva	42.43 labial gingiva
Size	unspecific	2x2 cm
Color	Erythematous or purplish	white and red
Shape	Nodular	dome
Surface	smooth	smooth
Consistency	rubbery	firm
Pain	(-)	(-)
Ulcer	(+)sometimes	(+)
Induration	(+)	(+)
Tenderness	(-)	(-)
Mobility	fixed	fixed
Duration	fast growing	fast growing

	Fibrosarcoma	our case
Gender	no predilection	male
Age	any age	79 y/o
Site	extremities/head.neck	42.43 labial gingiva
Size	considerable size	2x2 cm
Color	red	white and red
Shape	unspecific	dome
Surface	unspecific	smooth
Consistency	firm	firm
Pain	(-)/(+) considerable size	(-)
Ulcer	(+/-)	(+)
Induration	(-)	(+)
Tenderness	(-)	(-)
Mobility	fixed	fixed
Duration	fast/slow growing	fast growing

Leiomyosarcoma

our case

Gender	male	male
Age	middle /older age	79 y/o
Site	tongue/gingiva/soft palate	42.43 labial gingiva
Size	unspecific	2x2 cm
Color	unspecific	white and red
Shape	unspecific	dome
Surface	unspecific	smooth
Consistency	firm	firm
Pain	(+)/(-)	(-)
Ulcer	(+)/(-)	(+)
Induration	(+)	(+)
Tenderness	(-)	(-)
Mobility	fixed	fixed
Duration	slow growing	fast growing

Squamous cell carcinoma(gingiva & edentulous)

our case

Gender	male	male
Age	>65y/o	79 y/o
Site	tongue/soft palate/gingiva/buccal mucosa	42.43 labial gingiva
Size	unspecific	2x2 cm
Color	white and red	white and red
Shape	irregular	dome
Surface	fungating/papillary/verruciform	smooth
Consistency	unspecific	firm
Pain	(-)gingiva/alveolar ridge	(-)
Ulcer	(+)	(+)
Induration	(+)	(+)
Tenderness	(+)	(-)
Mobility	fixed	fixed
Duration	fast growing	fast growing

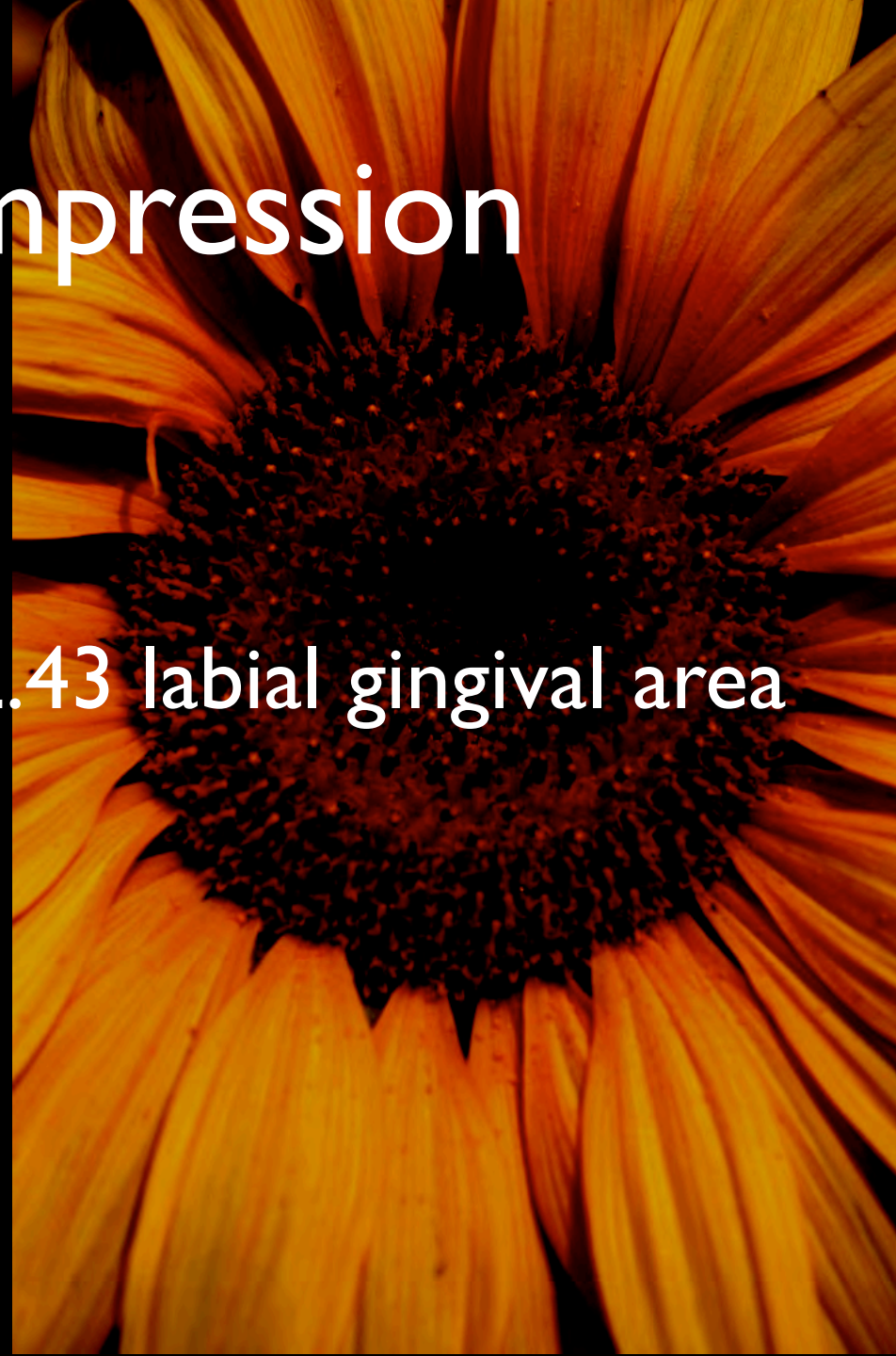	Mucoepidermoid carcinoma (minor salivary gland)	our case
--	--	----------

Gender	slight female predilection	male
Age	wide range	79 y/o
Site	lower lip / floor of mouth / tongue / retomolar pad	42.43 labial gingiva
Size	variable	2x2 cm
Color	blue/red	white and red
Shape	dome	dome
Surface	smooth	smooth
Margin	well-defined	well-defined
Consistency	soft to firm	firm
Pain	(-)	(-)
Ulcer	(-)	(+)
Induration	(-)	(+)
Tenderness	(-)	(-)
Mobility	fixed	fixed
Duration	slow-growing	fast growing

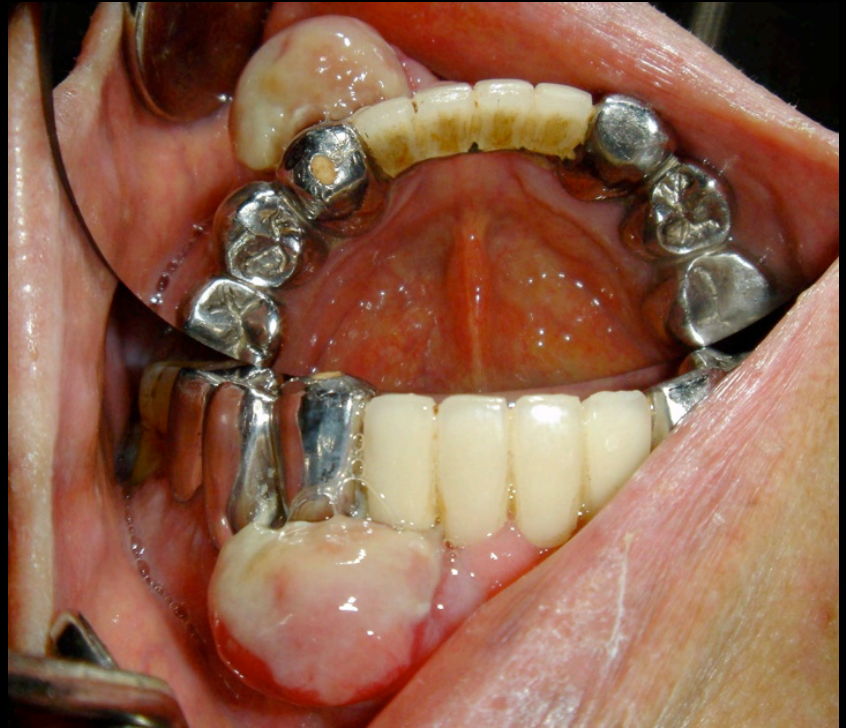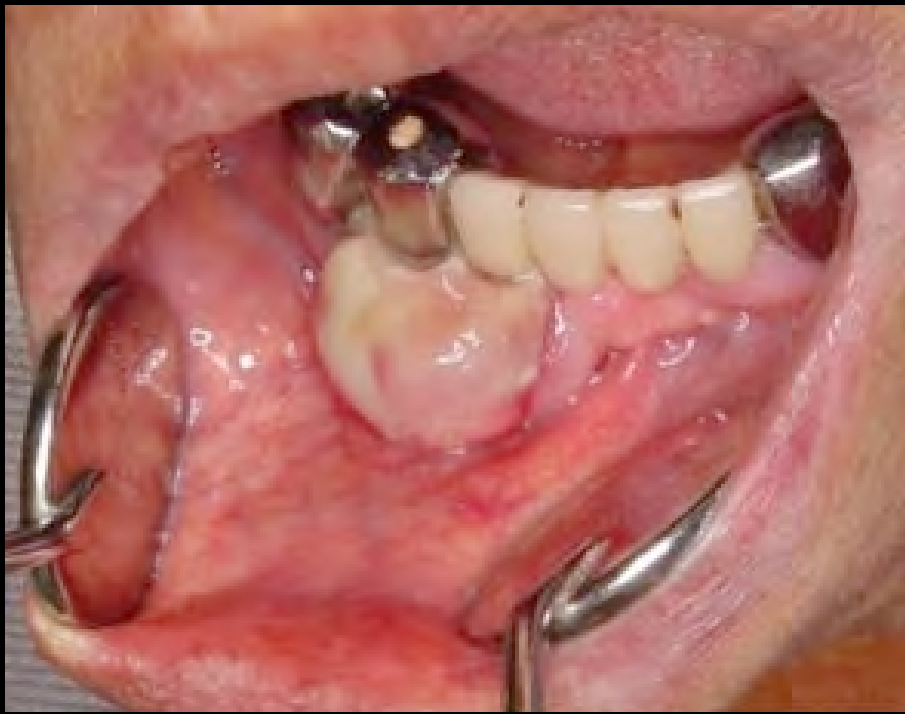	metastatic tumor	our case
Gender	male	male
Age	middle/older age(50-70)	79 y/o
Site	gingiva/alveolar mucosa/tongue	42.43 labial gingiva
Size	unspecific	2x2 cm
Color	white and red	white and red
Shape	polymorphous(dome)	dome
Surface	smooth	smooth
Consistency	firm	firm
Pain	(-)	(-)
Ulcer	(+)	(+)
Induration	(+)	(+)
Tenderness	unspecific	(-)
Mobility	fixed	fixed
Duration	fast growing	fast growing

Clinical impression

- Lymphoma over 42.43 labial gingival area

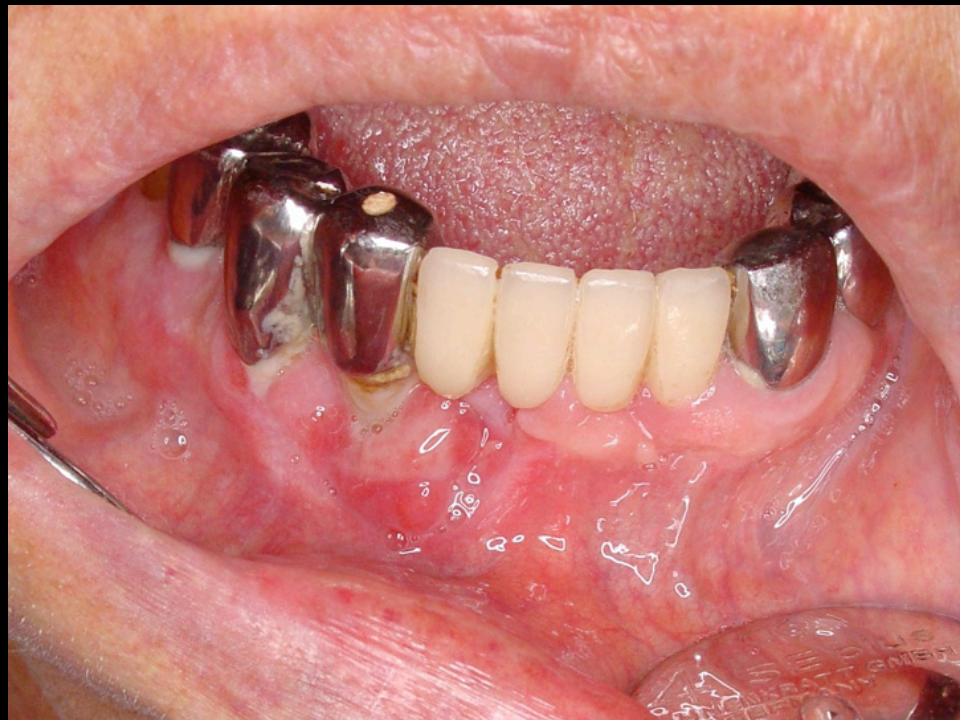

First visit in OM OPD

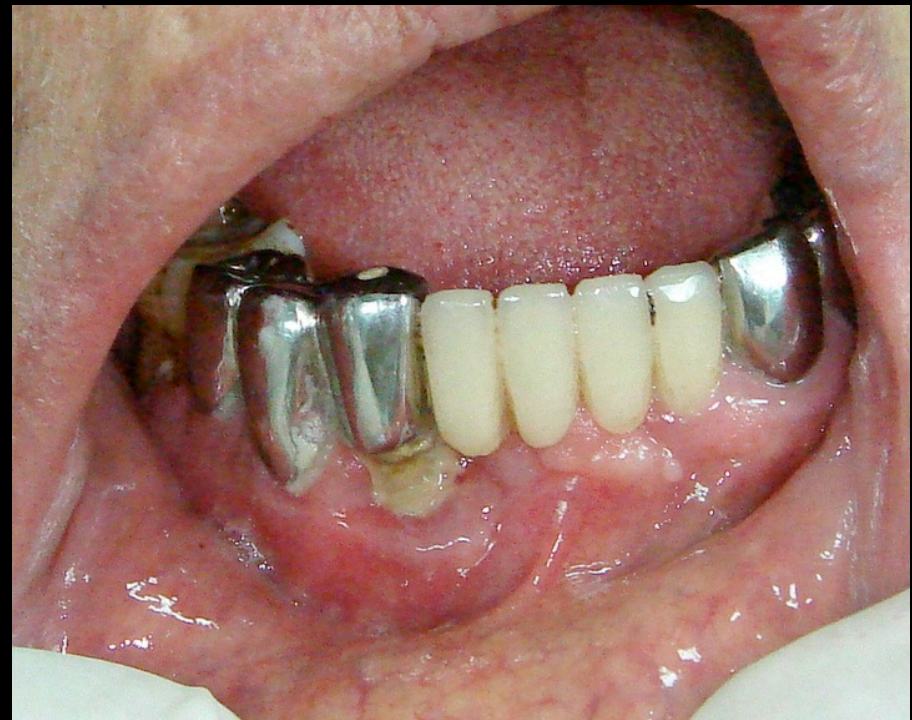

96.09.26

96.09.26 refer to OS for excisional biopsy

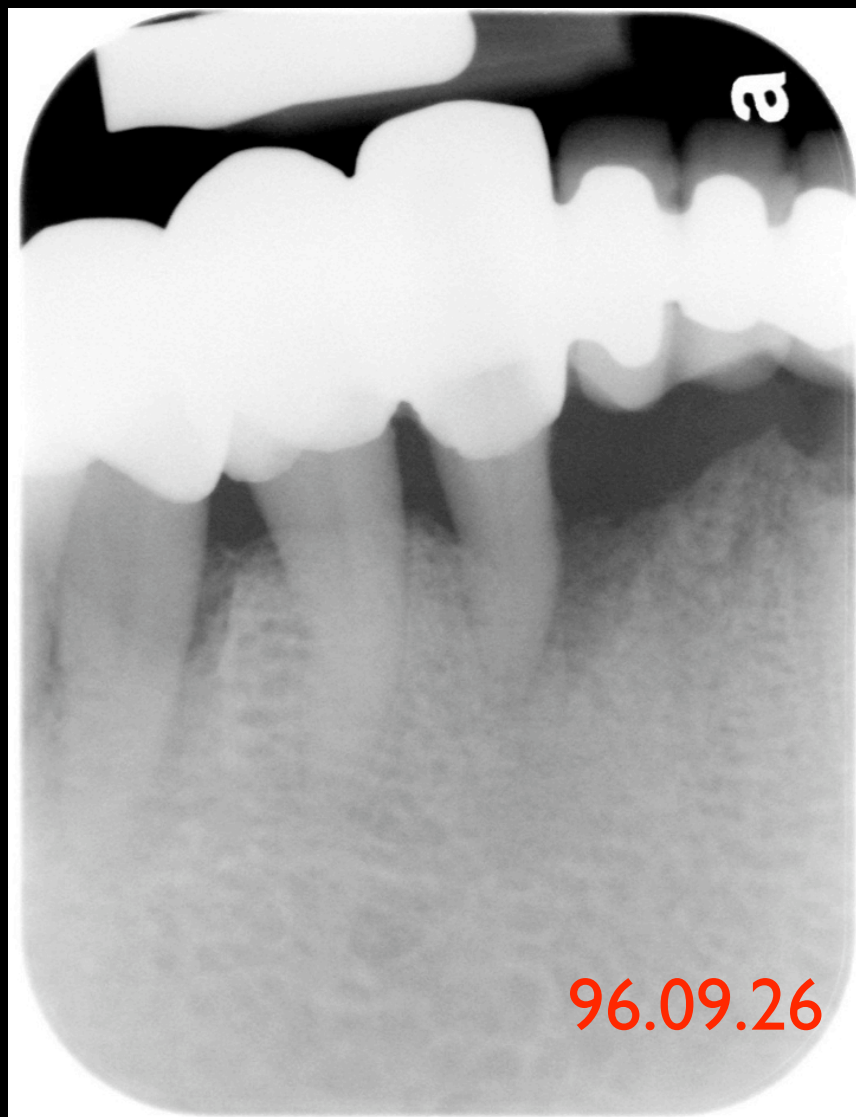


96.10.09

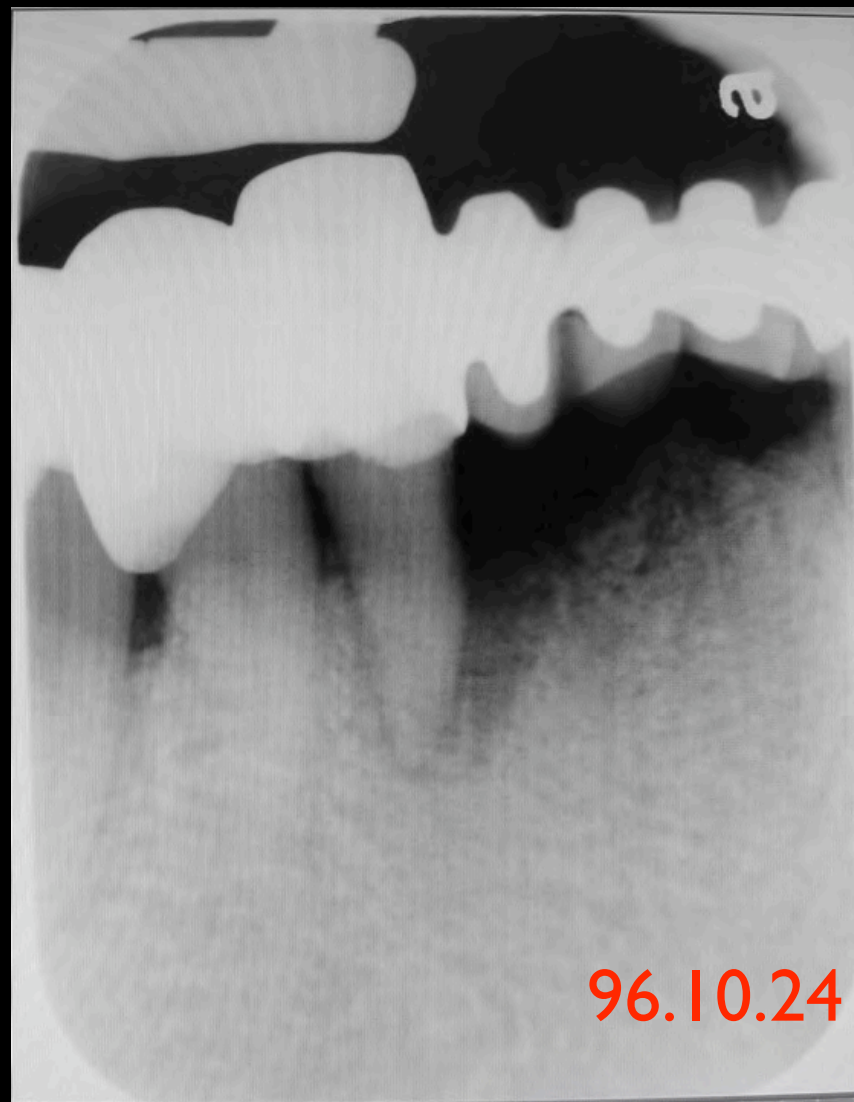

96.10.24

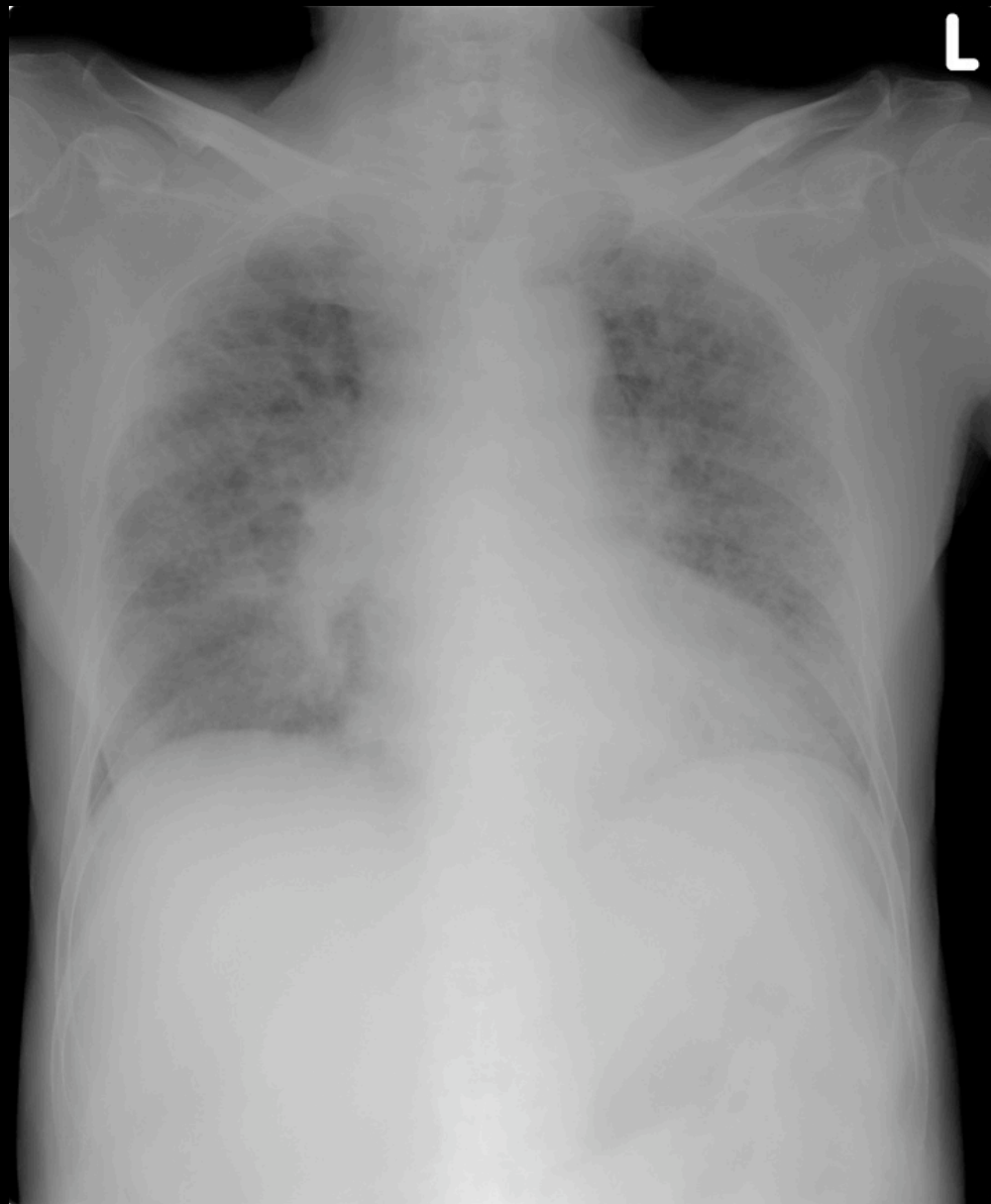Original



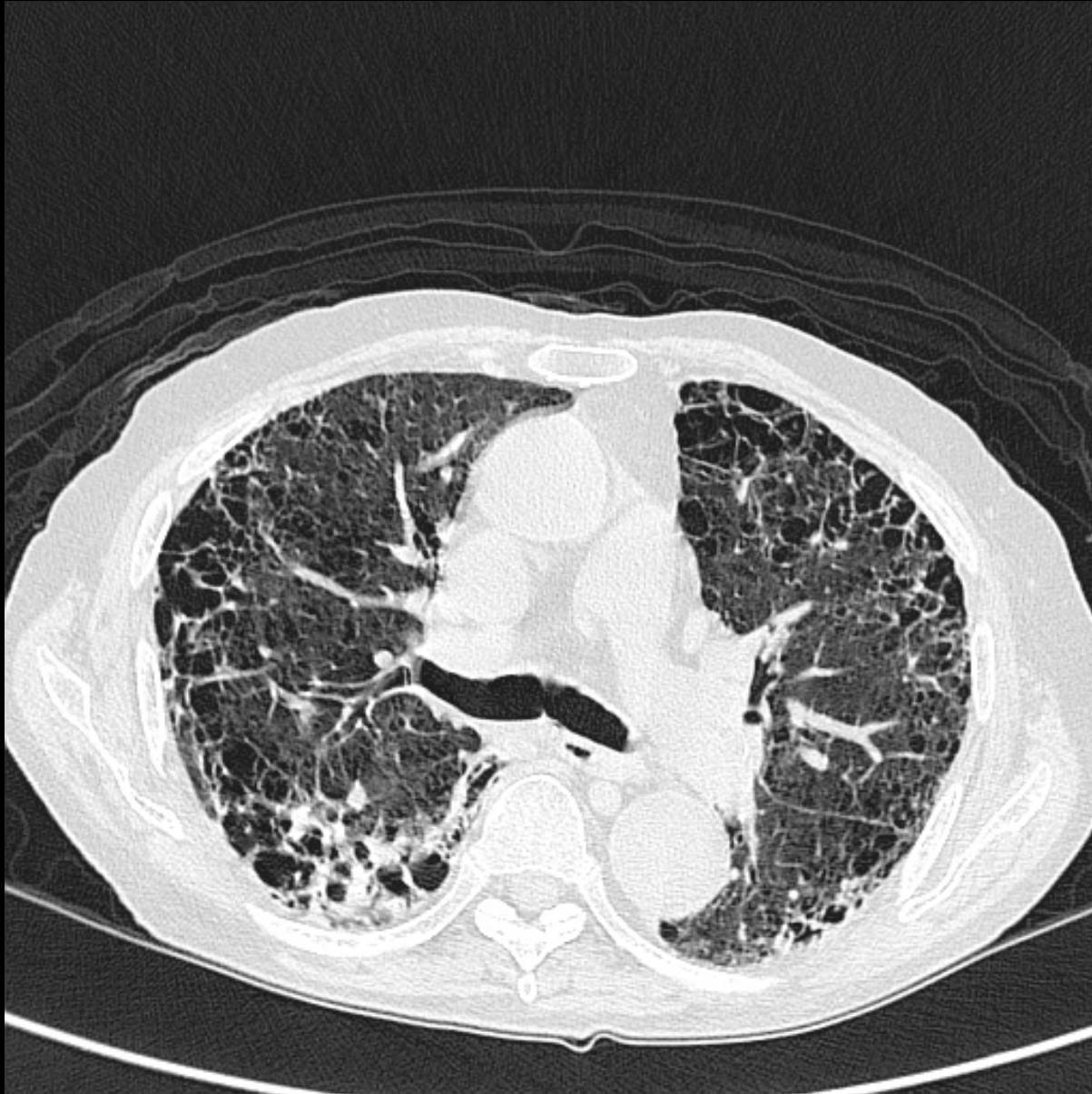
One month F/u

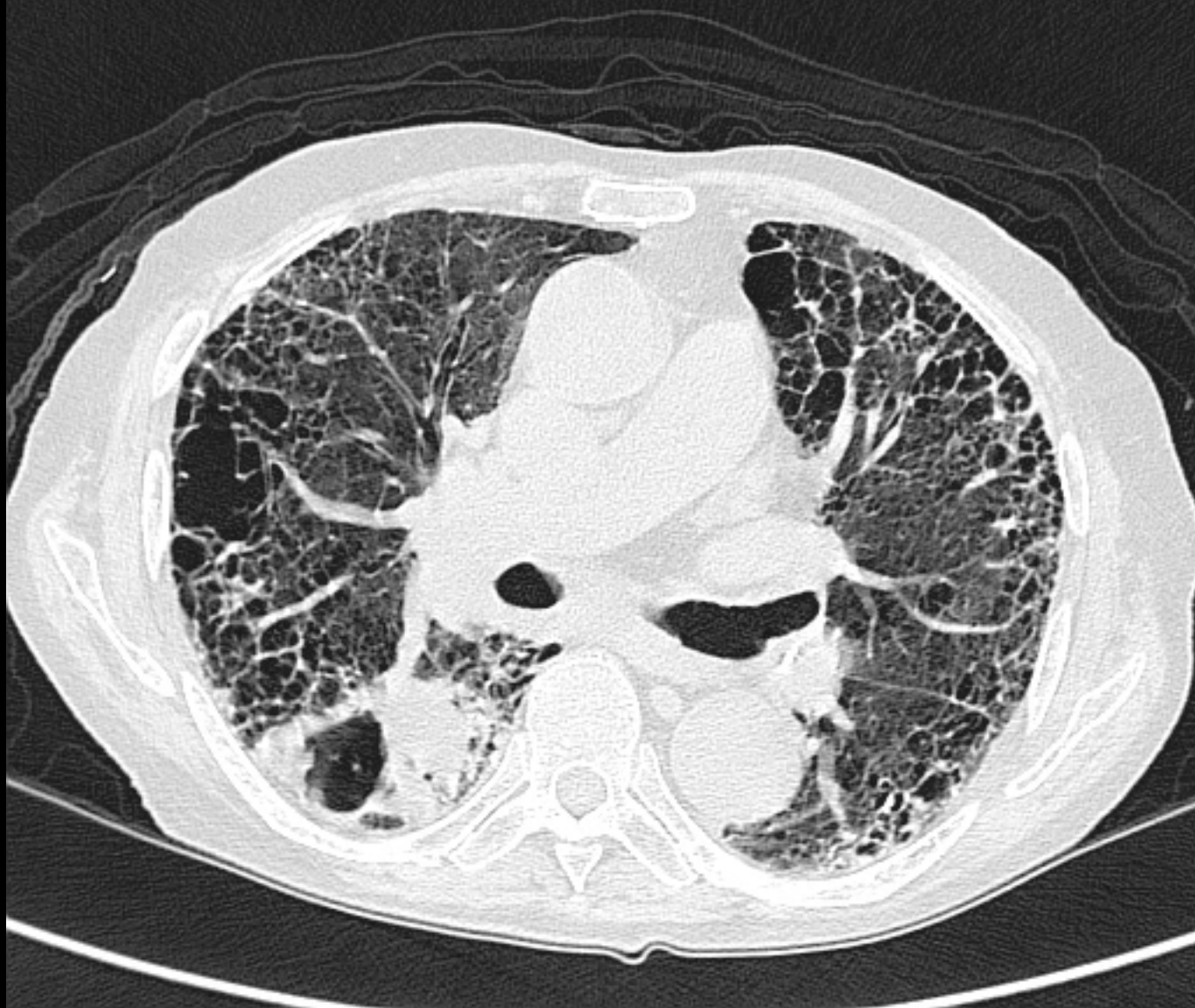


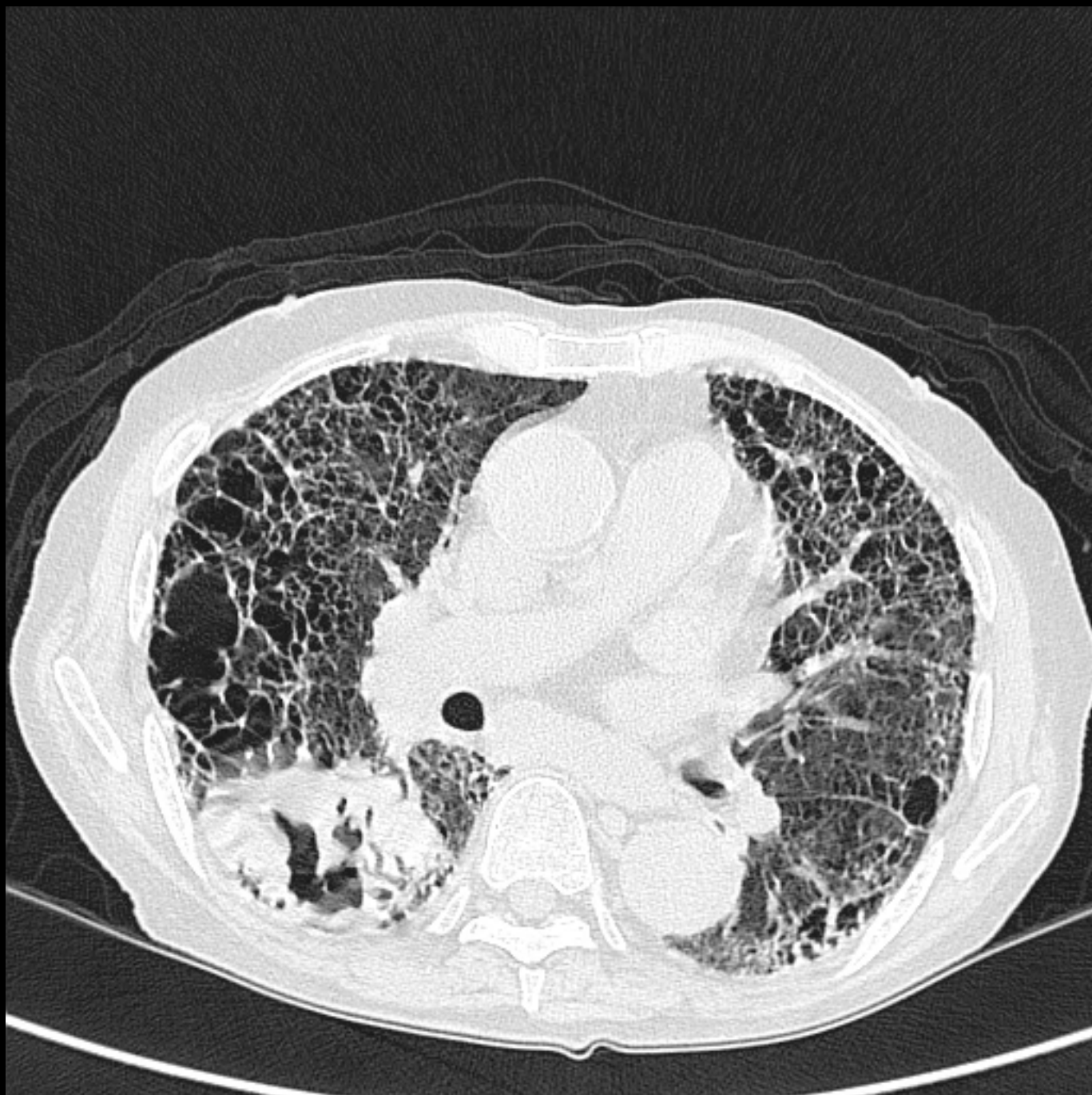
Chest X-ray 96.10.16

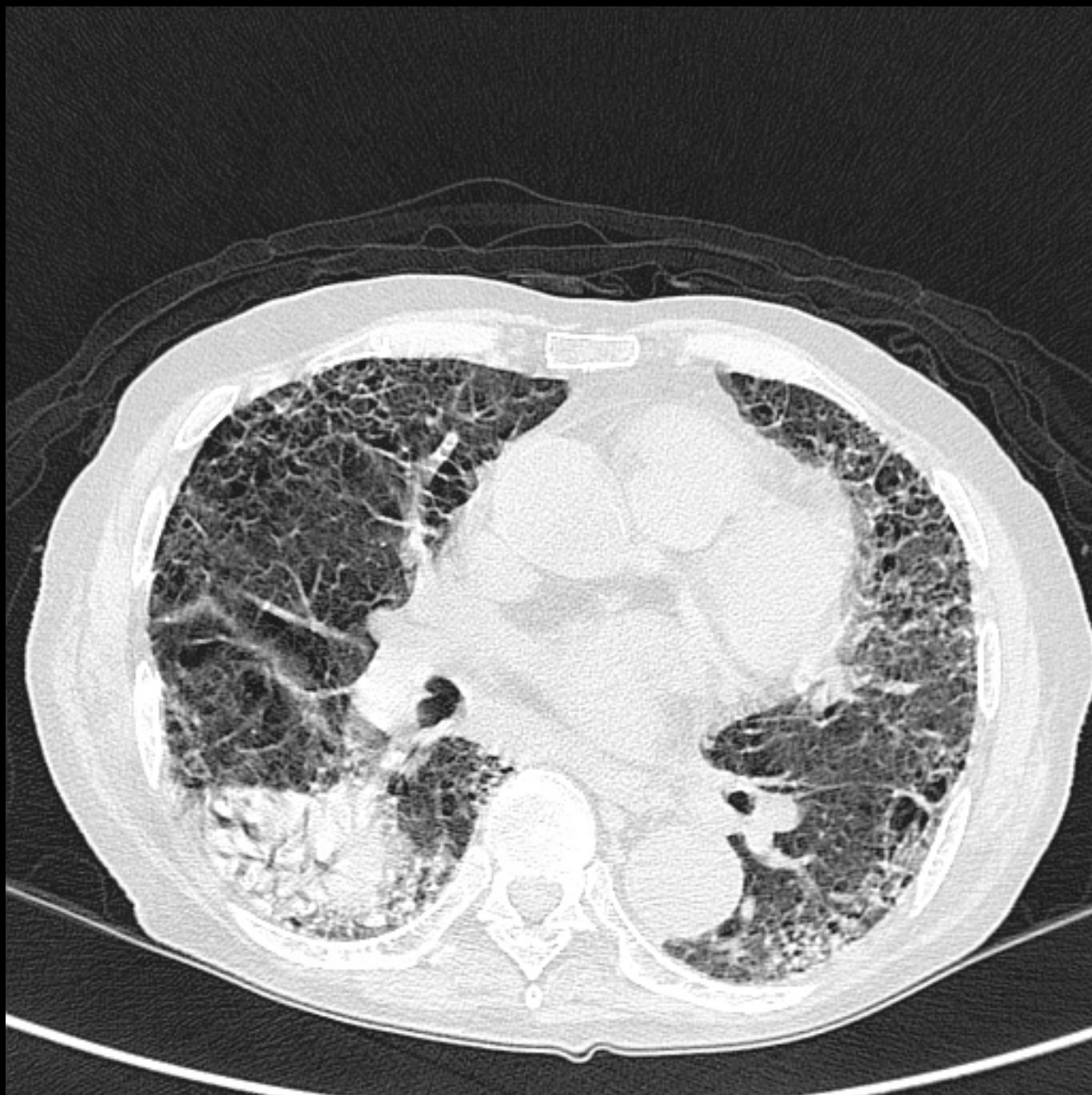


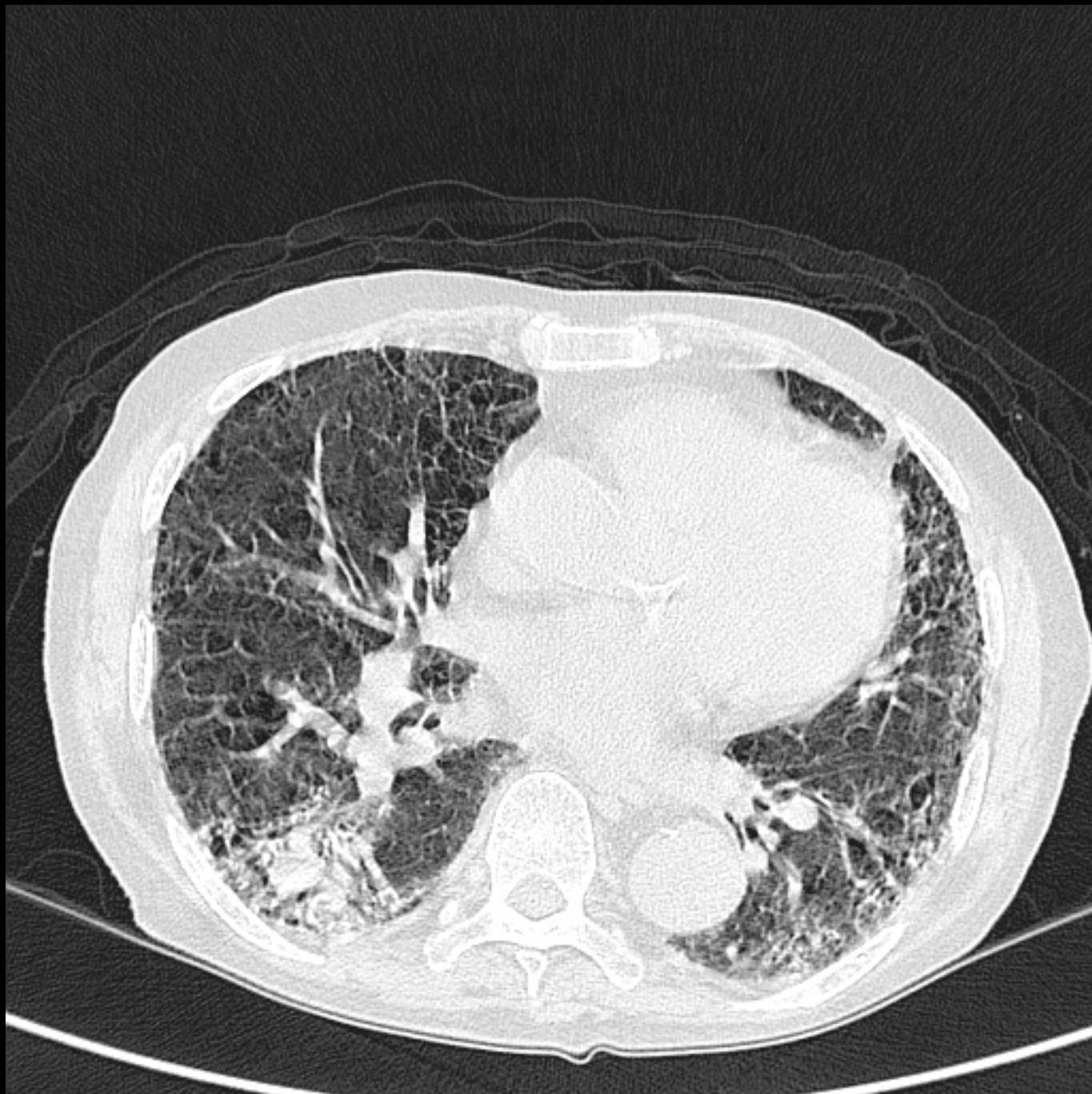
CT of chest 96.10.23

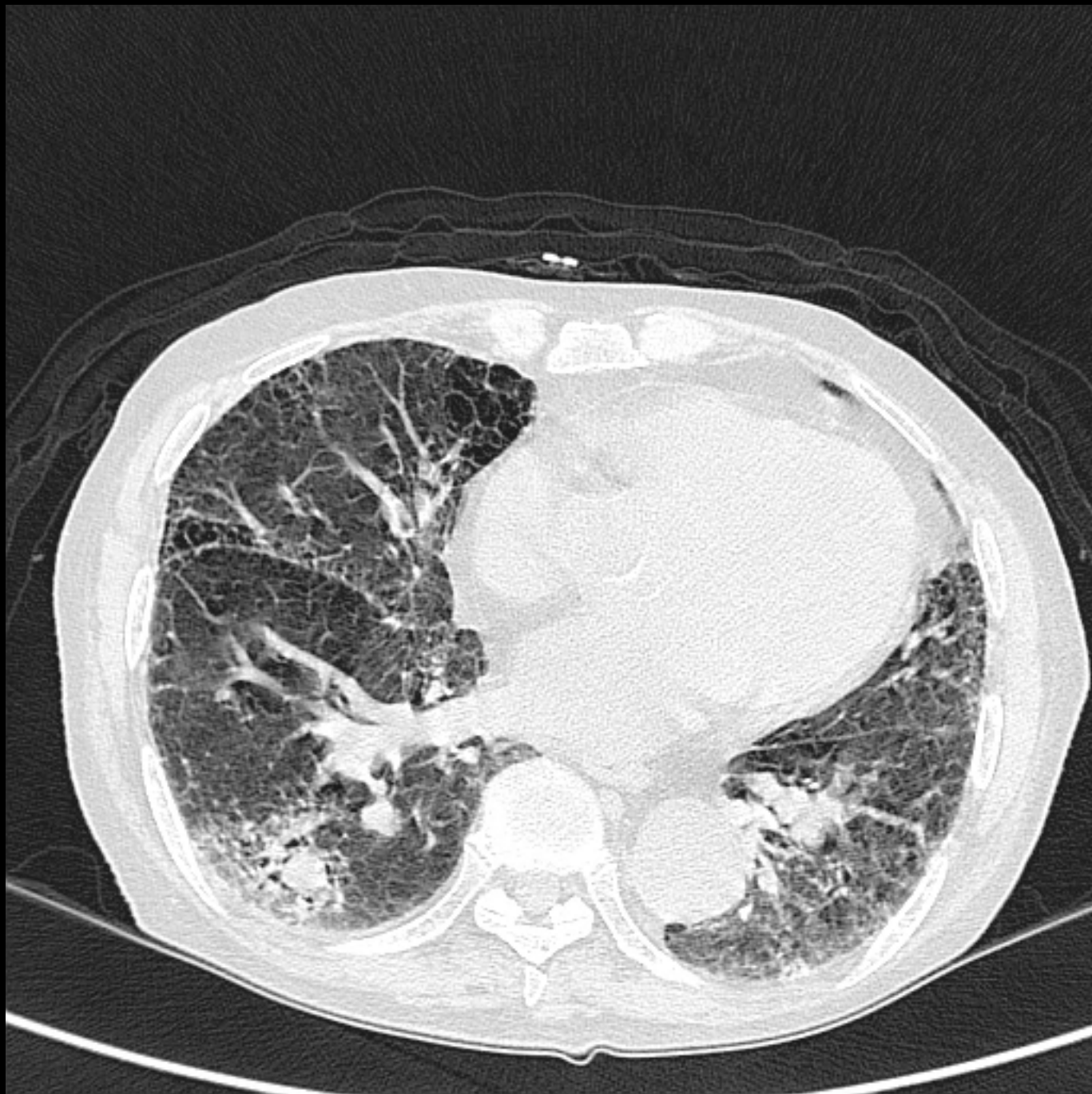












Thanks for your attention

