Case report

2009.12.28 INT C 陳其財 任心如 林雅敏 陳哲偉 詹明毅

GENERAL DATA

GENERAL DATA

- Personal data
  - Name : 黃XX
  - Gender : Male
  - Age : 32
  - Native : 屏東
  - Occupation : 工
  - First Visit : 98/05/13

GENERAL DATA

- Chief Complaint
  - refer from LDC for extraction 38

GENERAL DATA

- Present Illness
  - This 32 y/o patient felt discomfort over 38 area about 2 months ago.He came to LDC for help.The doctor referred him to our OPD for extraction of the 38 impaction.

GENERAL DATA

- Past medical history :
  - Hospitaliztation history (+)
  - Denied any food and drug allergy
  - Denied any systemic disease
- Past Dental History
  - General dental treatment
- Attitude to dental treatment :
  - Cooperative

GENERAL DATA

- Personal data
  - Risk factor related to malignancy
    - Alcohol : unknown
    - Betel nut : unknown
    - Cigarette : unknown
    - Other habit : unknown

X-ray findings

There is a well-defined unilocular ovoid shaped radiolucence with a corticated outline extending from CEJ of impacted tooth 38 to half of ramus and from 2cm under sigmoid notch to the furcation of impacted tooth 38,measuring approximately 3x2 cm.

Filling :18 17 13 12 11 21 24 37 38 46 47 **missing** :15 26 48
Restorarion :16x14 25x27 35 36 44 45 **impaction** :28 38

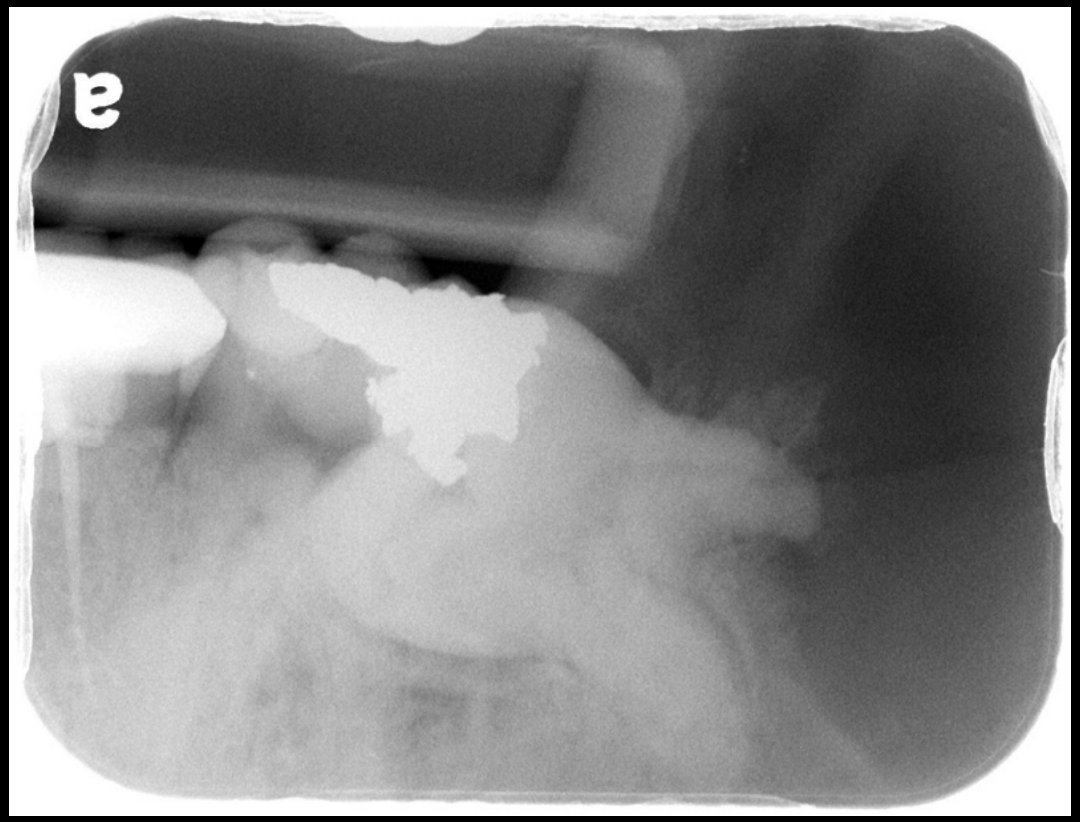

There is a well-defined radiolucence lesion over posterior and superior of impacted tooth 38. The distal root and crown of tooth38 is involved and the lamina dura of them was disappear.

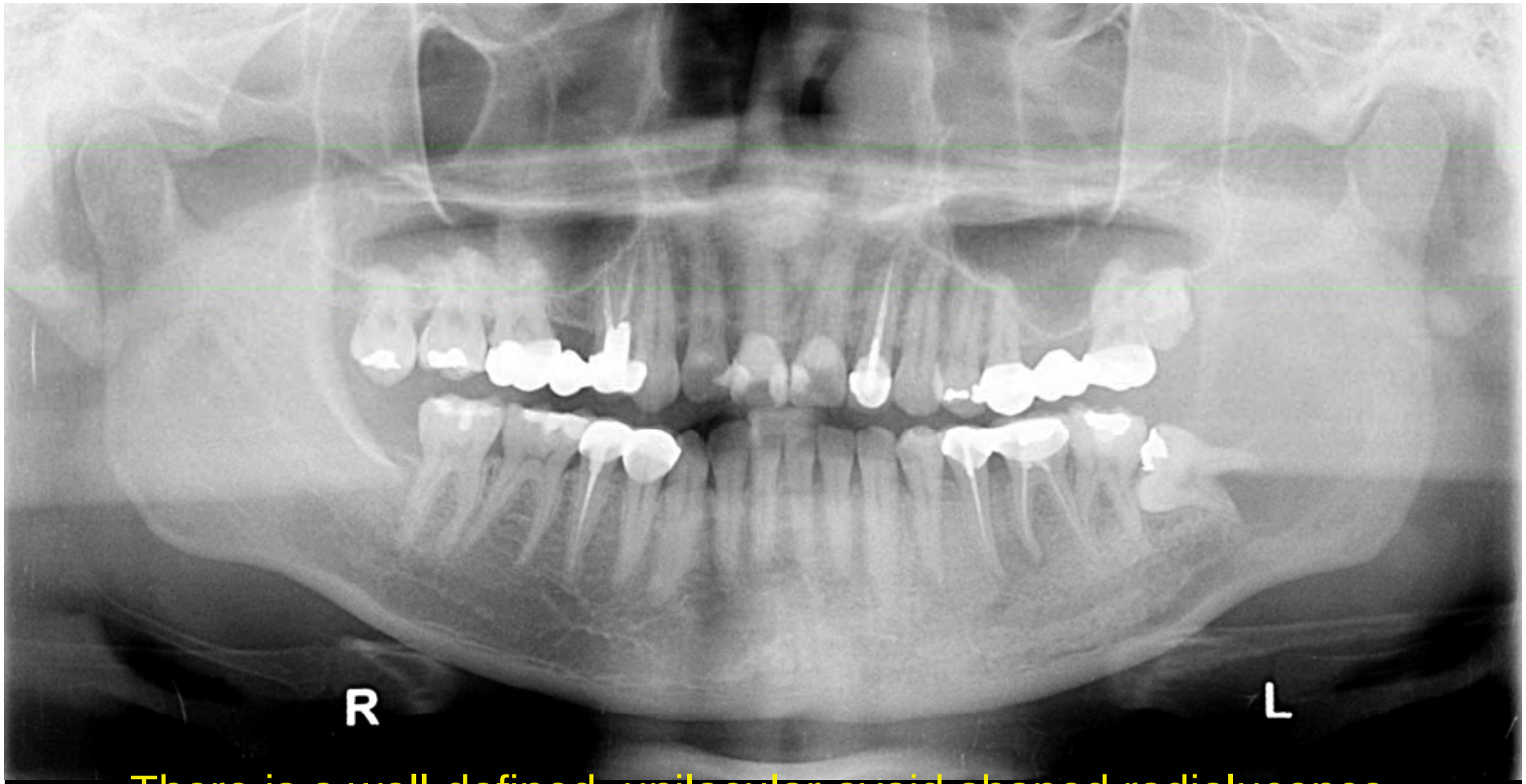

There is a well-defined unilocular ovoid shaped radiolucence with a corticated outline extending from CEJ of impacted tooth 38 to 3/4 of ramus and from 1cm under sigmoid notch to the mesial root of tooth 38,measuring approximately 4x2.5 cm. The inferior alveolar canal is involved. The root resorption is noted.

Computed Tomography

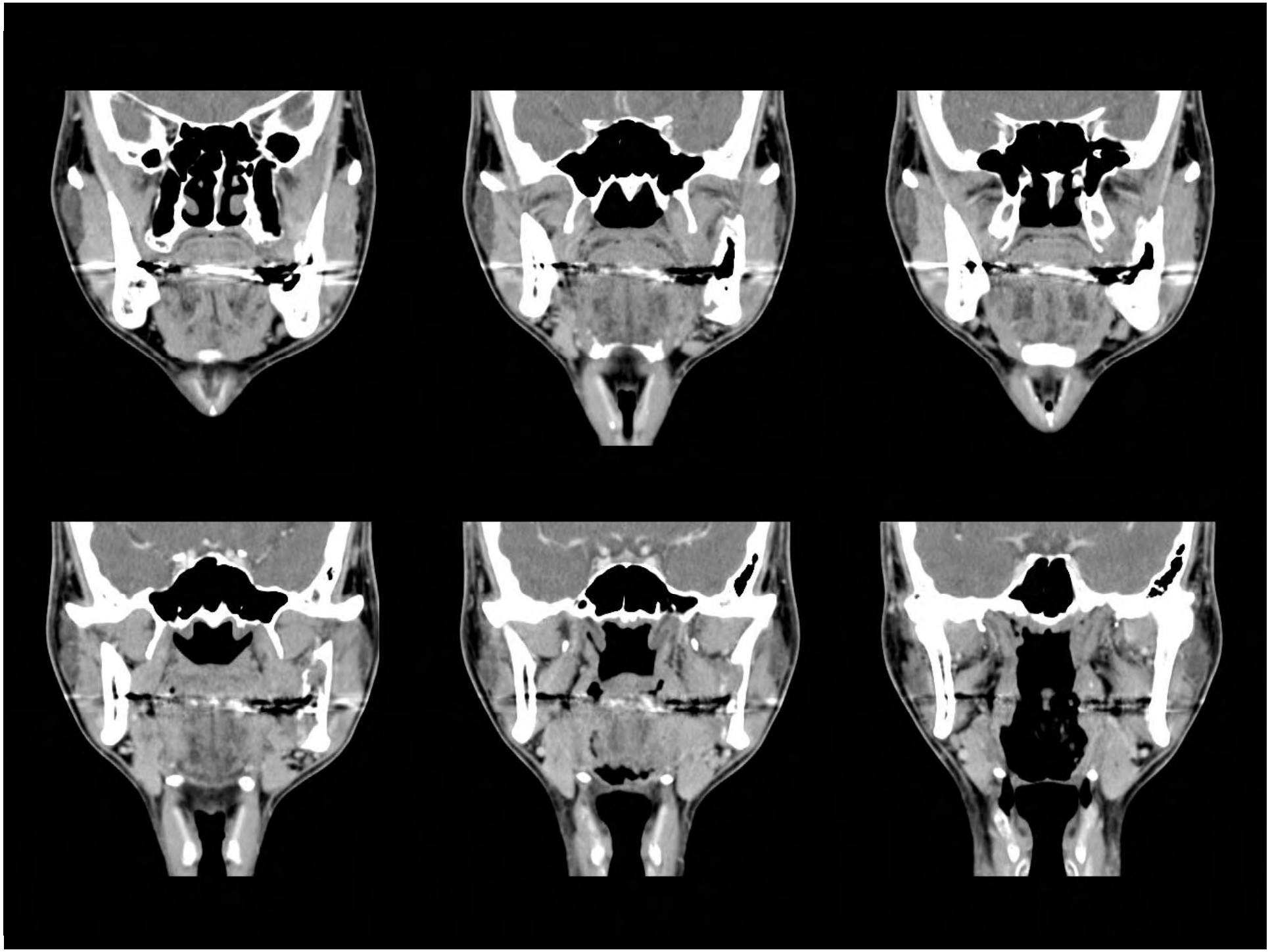

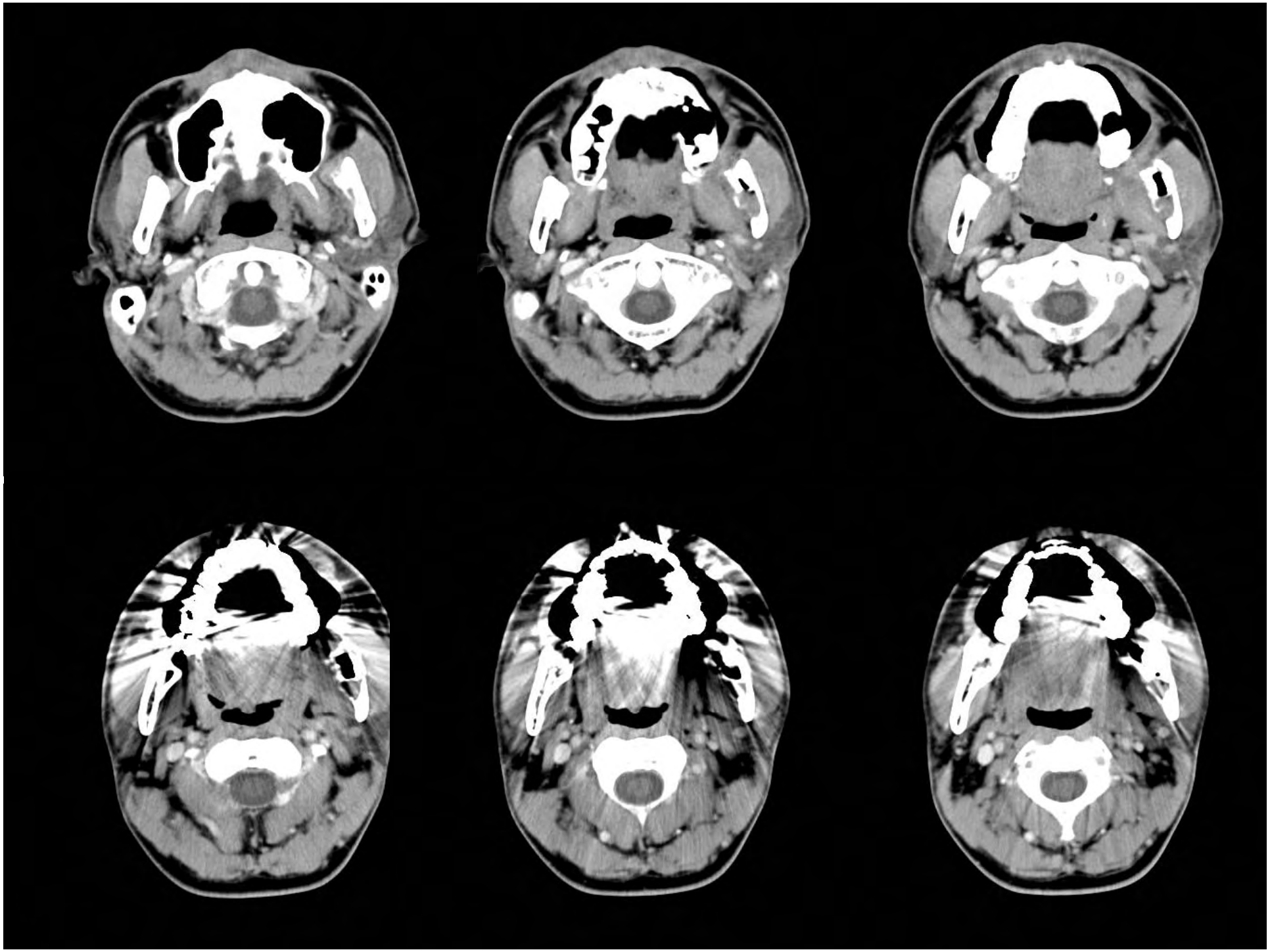

Positron Emission Tomography

PET

- 是異於傳統加馬照相機的新一代核子醫學儀 器，它利用正子同位素產生互毀反應後所射出的成對加馬輻射線來作爲成像的原理

- PET影像資料如配合動脈血中正子同位素藥物濃度資料以代謝模式加以運算，可求得單位組織代謝速率

- 正子攝影配合氟-18標記葡萄糖作爲放射藥劑，可進行體內器官組織的代謝評估，臨床上可用於腫瘤造影、心肌存活評估及癲癇病灶定位

PET

- 例如：使用FDG可測得每單位組織每分鐘代謝多少分子的葡萄糖， 使用150-水可測定每單位組織的血流、血量等

- 由於惡性腫瘤常表現出比正常或良性組織更高的代謝，所以可用氟-18葡萄糖正子攝影來偵測惡性腫瘤，運用的時機包括良惡性病灶的鑑別、治療前分期、治療中再分期、治療效果的評估及治療後復發的追蹤等。

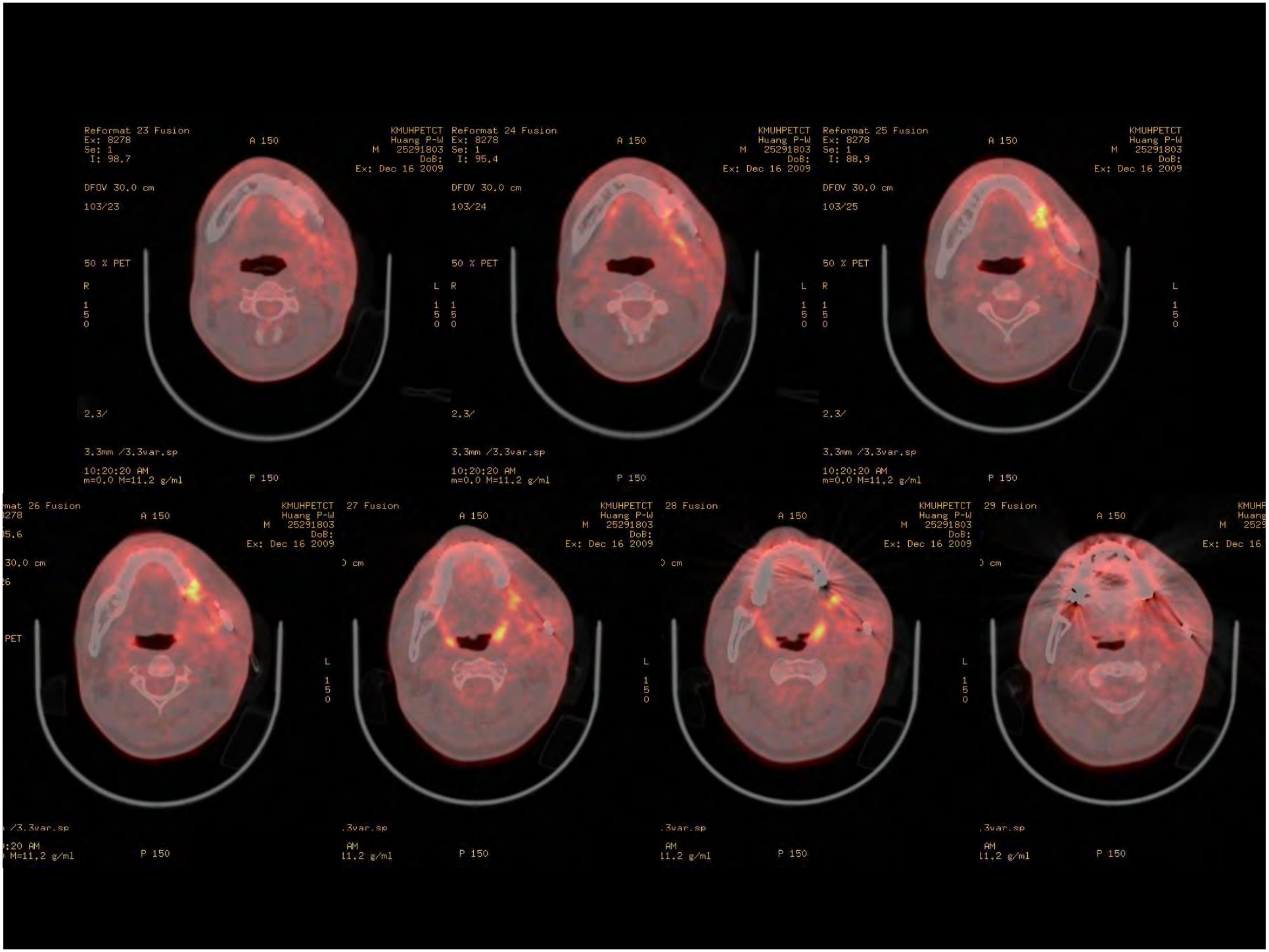
Reformat 23 Fusion
Ex: 8278
Se: 1
I: 98.7
A 150
KMUHPETCT
Huang P-W
M 25291803
DoB:
Ex: Dec 16 2009
DFOV 30.0 cm
103/23
50 % PET
R
L
1
5
0
2.3/
3.3mm /3.3var.sp
10:20:20 AM
m=0.0 M=11.2 g/ml
P 150
Reformat 24 Fusion
Ex: 8278
Se: 1
I: 95.4
DFOV 30.0 cm
103/24
Reformat 25 Fusion
Ex: 8278
Se: 1
I: 88.9
DFOV 30.0 cm
103/25
28 Fusion
29 Fusion

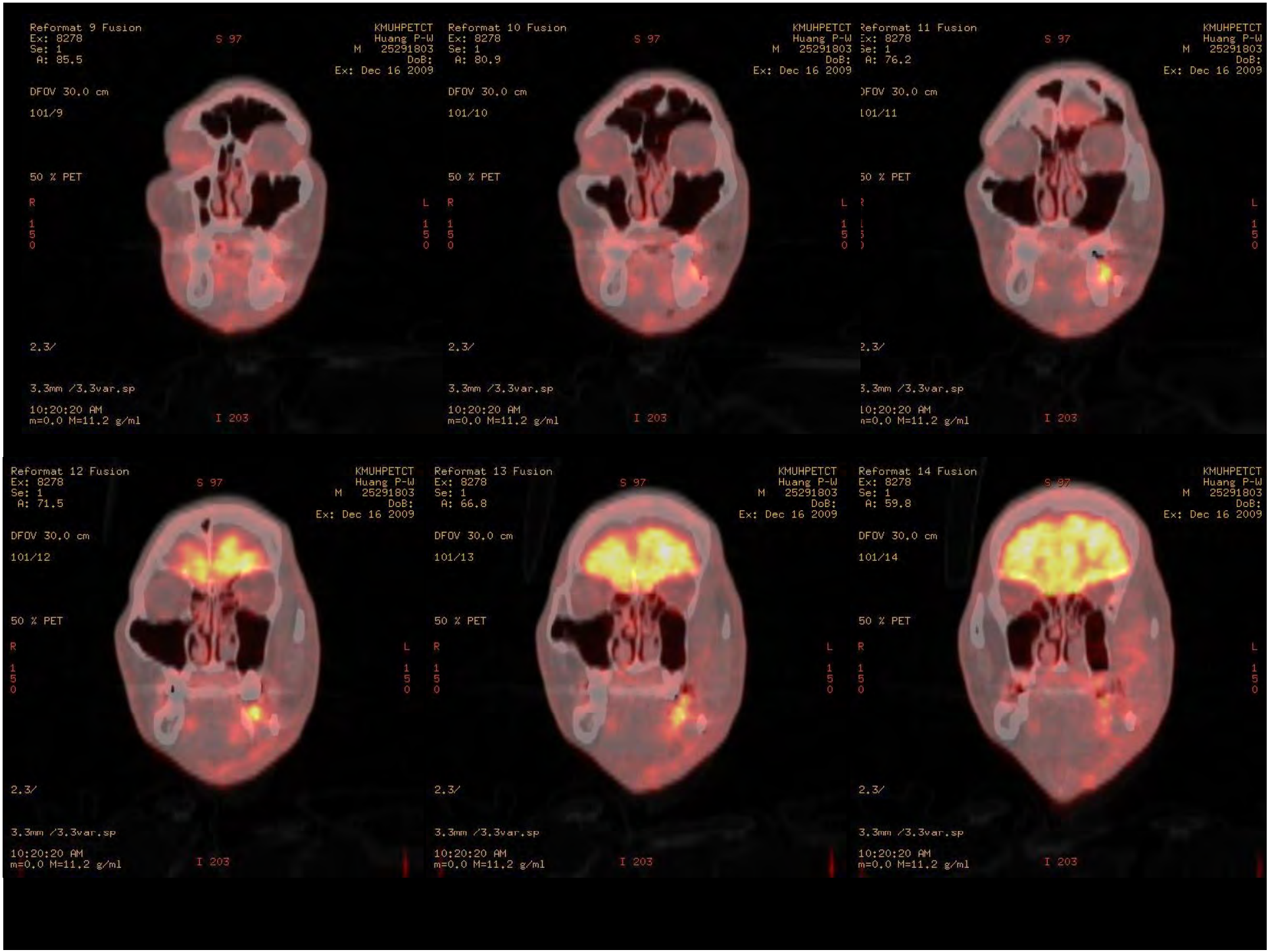
Reformat 9 Fusion
Ex: 8278
Se: 1
A: 85.5
S 97
KMUHPETCT
Huang P-W
M 25291803
DoB:
Ex: Dec 16 2009
DFOV 30.0 cm
101/9
50 % PET
R
L
2.3/
3.3mm /3.3var.sp
10:20:20 AM
m=0.0 M=11.2 g/ml
I 203
Reformat 10 Fusion
Ex: 8278
Se: 1
A: 80.9
S 97
KMUHPETCT
Huang P-W
M 25291803
DoB:
Ex: Dec 16 2009
DFOV 30.0 cm
101/10
50 % PET
R
L
2.3/
3.3mm /3.3var.sp
10:20:20 AM
m=0.0 M=11.2 g/ml
I 203
Reformat 11 Fusion
Ex: 8278
Se: 1
A: 76.2
S 97
KMUHPETCT
Huang P-W
M 25291803
DoB:
Ex: Dec 16 2009
DFOV 30.0 cm
101/11
50 % PET
L
2.3/
3.3mm /3.3var.sp
10:20:20 AM
m=0.0 M=11.2 g/ml
I 203
Reformat 12 Fusion
Ex: 8278
Se: 1
A: 71.5
S 97
KMUHPETCT
Huang P-W
M 25291803
DoB:
Ex: Dec 16 2009
DFOV 30.0 cm
101/12
50 % PET
R
L
2.3/
3.3mm /3.3var.sp
10:20:20 AM
m=0.0 M=11.2 g/ml
I 203
Reformat 13 Fusion
Ex: 8278
Se: 1
A: 66.8
S 97
KMUHPETCT
Huang P-W
M 25291803
DoB:
Ex: Dec 16 2009
DFOV 30.0 cm
101/13
50 % PET
R
L
2.3/
3.3mm /3.3var.sp
10:20:20 AM
m=0.0 M=11.2 g/ml
I 203
Reformat 14 Fusion
Ex: 8278
Se: 1
A: 59.8
S 97
KMUHPETCT
Huang P-W
M 25291803
DoB:
Ex: Dec 16 2009
DFOV 30.0 cm
101/14
50 % PET
R
L
2.3/
3.3mm /3.3var.sp
10:20:20 AM
m=0.0 M=11.2 g/ml
I 203

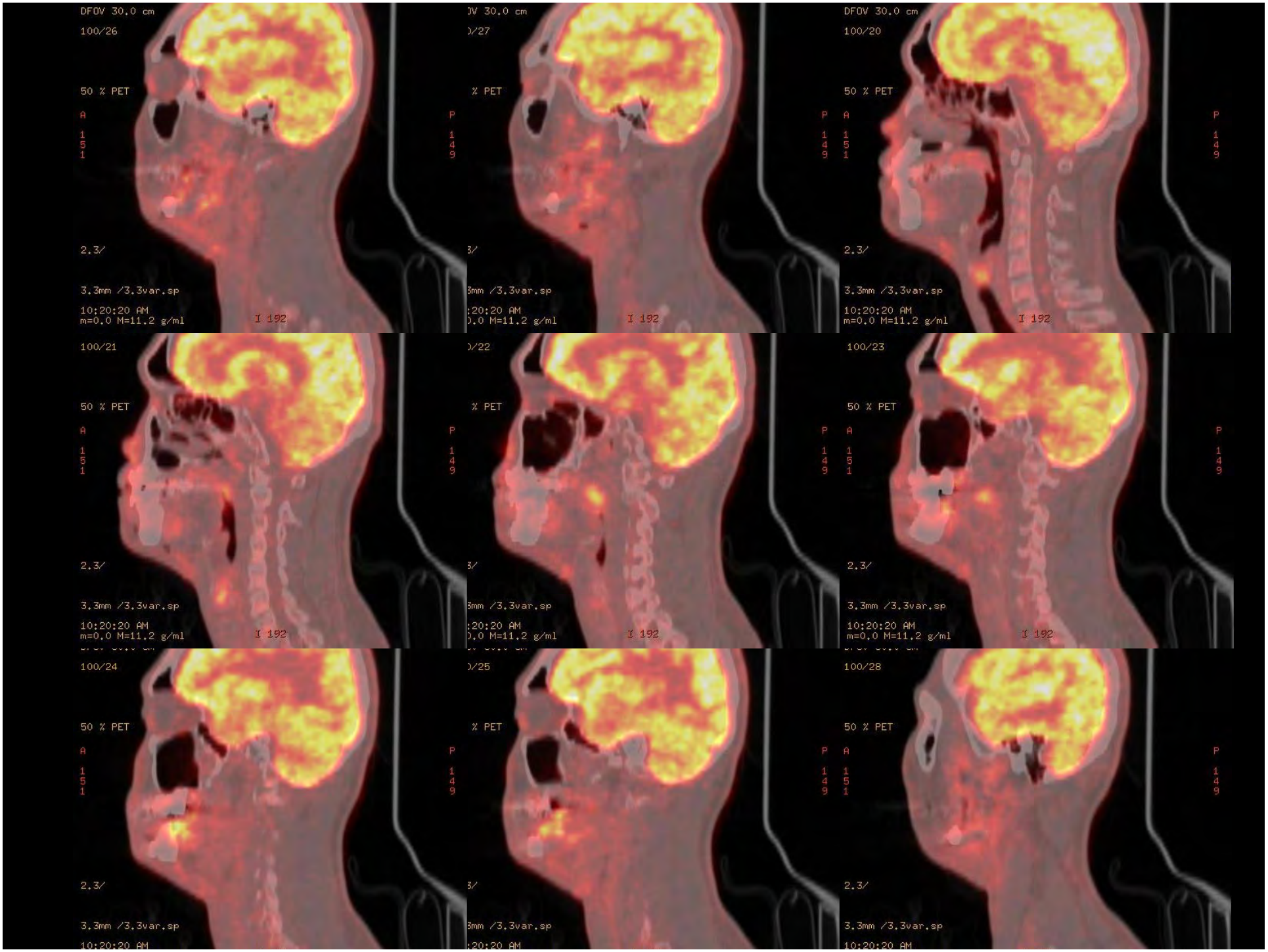
DFOV 30.0 cm
100/26
50 % PET
A
1
5
1
P
1
4
9
2.3/
3.3mm /3.3var.sp
10:20:20 AM
m=0.0 M=11.2 g/ml
I 192
100/27
100/20
100/21
100/22
100/23
100/24
100/25
100/28

Difference diagnosis

Difference diagnosis

- Intra-bony or peripheral
- Inflammation or cyst or neoplasm
- Benign or malignant

Intra-bony or peripheral origin?

① Mucosal lesion : (-)
② Induration : unknown
③ Bony destruction : (+)
④ Bony expansion : (-)

⇨ CENTRAL

(but can’t rule out peripheral origin)

Inflammation? Cyst? Neoplasm?

① Fever or local heat : unknown
② Pain : (+)
③ Lymphadenopathy : unknown
④ Pus discharge : (-)
⑤ Duration : 2 months

CYST
(but can’t rule out NEOPLASM)

(if Neoplasm) Benign or malignant

① Mobility : (-)
② Ulceration : (-)
③ Induration : (-)
④ Duration : 2 months
⑤ Pain : (+)
⑥ Numbness: (-)
⑦ Lymphadenopathy : unknown
⑧ Margin : well-defined

→ BENIGN

Working Diagnosis

WORKING DIAGNOSIS

<CYST>

Odontogenic Keratocyst

Periapical Cyst

<NEOPLASM>

Unicystic Ameloblastoma

Ameloblastic Fibroma

Odontogenic Fibroma

Odontogenic Keratocyst

	Odontogenic Keratocyst	Our Case	
Age, gender	10~40 y/o, slight male	32 y/o, male	☺
X-ray	Well-defined uni- or multilocular R-L	Well-defined unilocular R-L	☺
Jaw	60~80% in mandible, unerupted tooth	L't mandibular ramus	☺
Pain	Small: painless Large: pain	Pain	☺
Growth	Slowly growing	Slowly growing (6 months : 2x3 cm → 2.5x4 cm)	☺
Swelling	Bony expansion and thinning of cortical plates	No bony expansion	
Effects on tooth	Less root resorption	No root resorption	

Periapical Cyst

	Periapical cyst	Our case	
Site	unspecific	L't mandible body and ramus	
Gender	unspecific	Male	
Age	unspecific	32 y/o	
Size	Vary in size	About 2 x 3 cm	
Symptom / Sign	-No s/s, unless there is an acute inflammatory exacerbation. -Large size：swelling and mild sensitivity -Movement of adjacent teeth are possible	P't felt uncomfortable	
Pain	Often：(-) Inflammation：(+)	(+)	
Radiographic Features	- A round radiolucency encircles the affected tooth apex. - Loss of the lamina dura along the adjacent root - Root resorption is common	An ovoid RL involved distal root of tooth 38	☺

Unicystic Ameloblastoma

	Unicystic Ameloblastoma	Our case	
Site	More than 90% in Posterior Mandible	L't mandible body and ramus	☺
Gender	unspecific	Male	
Age	-Most common in younger p't -About 50% diagnosed during 10~20 y/o -Average age：23 y/o	32 y/o	
Size	Vary in size	About 2 x 3 cm	
Symptom / Sign	-Often asymptomatic -Large lesions may cause a painless swelling of the jaws	P't felt uncomfort	
Pain	(-)	(+)	
Radiographic Features	Circumscribed radiolucency Combine impacted tooth (often Md. 3rd molar)	An ovoid RL involved distal root of tooth 38	☺

Ameloblastic Fibroma

	Ameloblastic Fibroma	Our case	
Site	The most common in the posterior mandible(about 50%)	L't mandible body and ramus	☺
Gender	Male > female	Male	☺
Age	Most common in the 0~20 y/o	32 y/o	
Size	Vary in size	About 2 x 3 cm	
Symptom / Sign	Small→asymptomatic Large→swelling of the jaws	P't felt uncomfort	
Pain	(-)	(+)	
Radiographic Features	Well-defined unilocular or Multilocular RL Combined impacted teeth (about 75%)	An ovoid RL involved distal root of tooth 38	☺

Central odontogenic fibroma

	Central odontogenic fibroma	Our case	
Gender	female	Male	
Age	Mean age: 40 y/o	32 y/o	☺
Symptom	-	Uncomfortable	
Site	Mandible, post.	L't mandible body and ramus	☺
Size	-	About 4x2.5 cm	
Outline	Small lesion: unilocular Large lesion: mutilocular	unilocular	
border	Well-defined with a sclerotic border	Well-defined with corticated border	☺
shape		ovoid	
Effect on surrounding structure	Root resorption Root divergence Large lesion:bony expansion teeth lossening	Involved distal root of tooth 38	

Clinical impression

- Odontogenic keratocyst, left mandibular ramus

Discussion

Treatment course

- 98.05.13
  - First visit :asking for 38 extraction
  - X-ray finding : dentigerous cyst
  - Suggest OP
- 98.11.27
  - OP :enucleation+ 38 extraction+ bone graft
- 98.12.08
  - Specimen report: salivary duct carcinoma
- 98.12.11
  - OP: Wide excision (partial mandibulectomy)

Salivary duct carcinoma

- uncommon highly malignant tumor
- mean age : 56 years (older man)
- Site:
  - parotid gland
  - submandibular salivary gland
  - minor salivary glands in the maxilla

Salivary duct carcinoma

- 27% of the tumors
  - arose from pre-existing pleomorphic adenoma
- perineural and lymphatic invasion (common)
- Distant metastasis (most common cause of failure)

Thanks for your attention

請各位醫師comment!!!