


Case Report

Intern Group D

組員：蕭立彥
謝佩妤
陳科名
王建弦

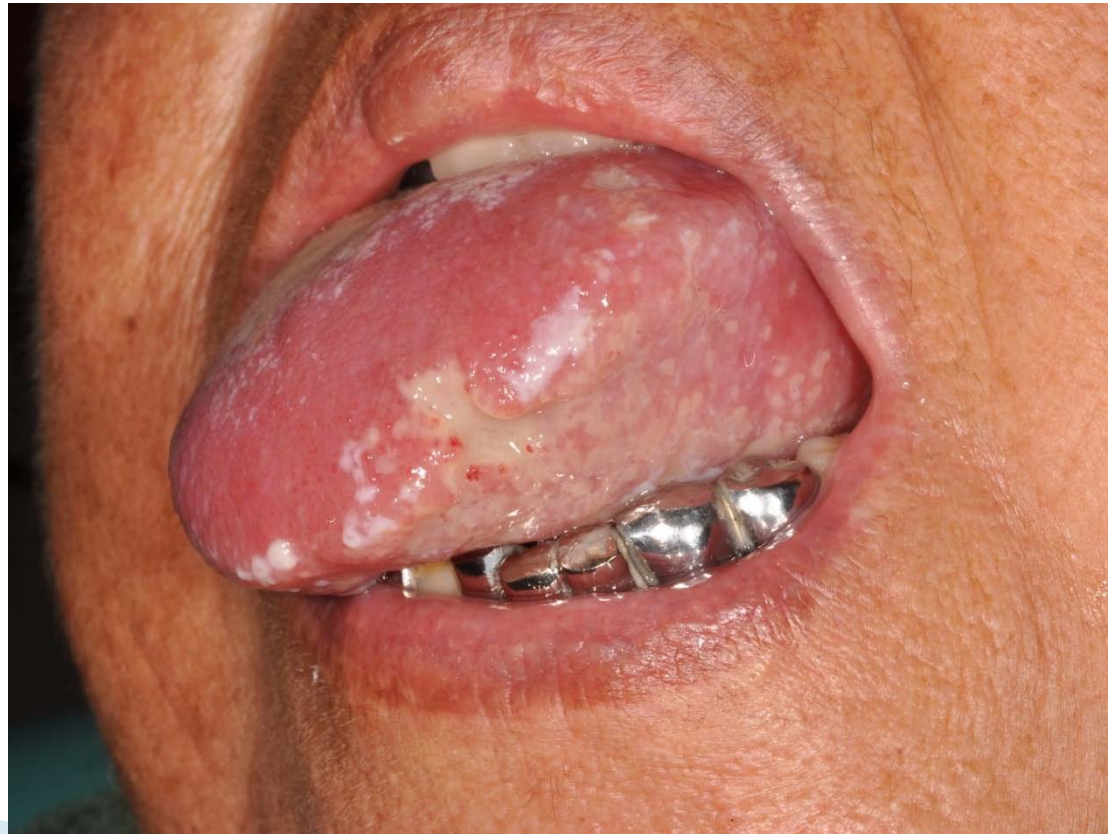指導老師：口腔病理診斷科全體醫師

General data


- ▶ Name: 鄭蕭OO
 - ▶ Sex: Female
 - ▶ Age: 75y/o
 - ▶ Martial status: Married
 - ▶ Attending V.S: 陳鴻榮
 - ▶ First visit: 99/10/22
- 

Chief complaint

- ▶ A ulceration over the left border of tongue with painful sensation over 40 days.



Present illness

- ▶ About 40 days ago, the female bit her tongue. After that, she found a ulcer on left border of tongue.
 - ▶ Since then, the size of ulcer had been larger and larger, with painful sensation.
 - ▶ Hence, she went to local clinical for help. And the dentist there suggested her to come to our department for further evaluation.
- 

Past history

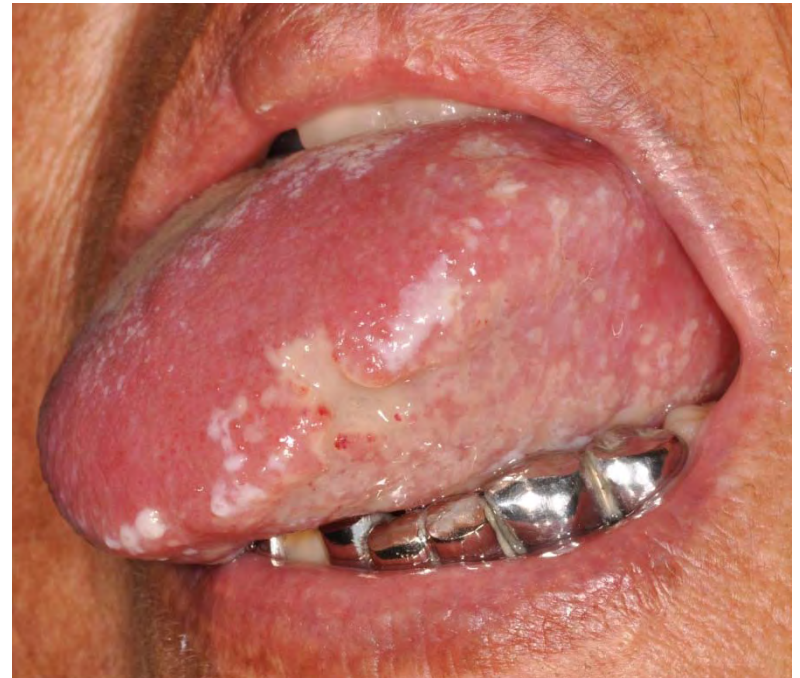- ▶ **Past Medical History**
 - Diabetes Mellitus, type II
 - Vertebrate Surgery
- ▶ **Past Dental History**
 - Prosthodontic treatment

Personal history

- ▶ Risk factor related to malignancy
 - Alcohol: (–)
 - Betel quid: (–)
 - Cigarette: (–)
- ▶ Other oral habits: none

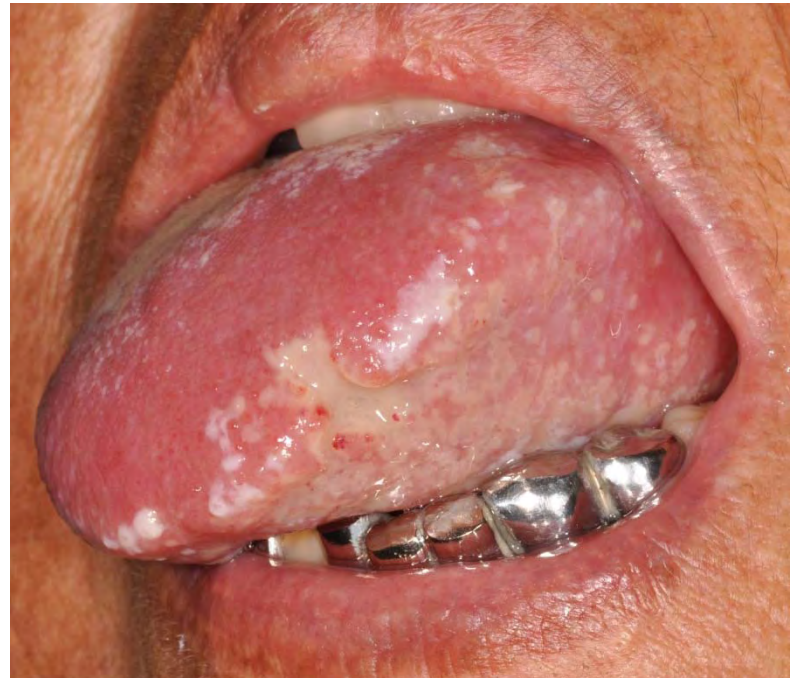Intraoral examination

- ▶ A ulceration on the left border of tongue, with scattered white patches over the left border, ventral and dorsal of tongue.
- ▶ Size: 2.5X0.5(5 x 5) cm
- ▶ Irregular shape
- ▶ Rough surface
- ▶ White/ yellow color
- ▶ Firm consistency
- ▶ Fixed mobility
- ▶ Painful sensation



Intraoral examination

- ▶ Redness (-)
- ▶ Swelling (-)
- ▶ Purulent drainage (-)
- ▶ Fever or local heat (+)
- ▶ Pain (+)
- ▶ Tenderness (+)
- ▶ Lymphadenopathy (-)
- ▶ Fluctuation (-)
- ▶ Induration (-)



Intraoral Examination


- ▶ Plaque deposition
- ▶ Crown & bridge:
tooth 11, 21, 22 , 31, 32, 33, 34, 35, 36, 37,
41, 42, 43, 44, 45, 46, 47
- ▶ Missing teeth: tooth 17, 23, 24, 25, 26, 27

Differential Diagnosis



Inflammation, neoplasm or cyst?


- ▶ Redness (-)
- ▶ Swelling (-)
- ▶ Purulent drainage (-)
- ▶ Fever or local heat (+)
- ▶ Pain (+)
- ▶ Tenderness (+)
- ▶ Lymphadenopathy (-)
- ▶ Fluctuation (-)
- ▶ Induration (-)
- ▶ Consistency: firm



Inflammation

But cannot completely rule out neoplasm

Working Diagnosis

- ▶ Pseudomembranous candidiasis
 - ▶ Tuberculosis(secondary lesion)
 - ▶ Syphilis
 - ▶ Squamous cell carcinoma
- 

Candidiasis

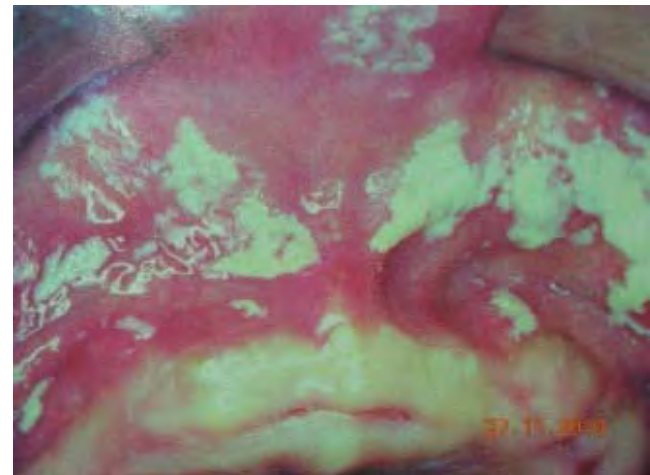
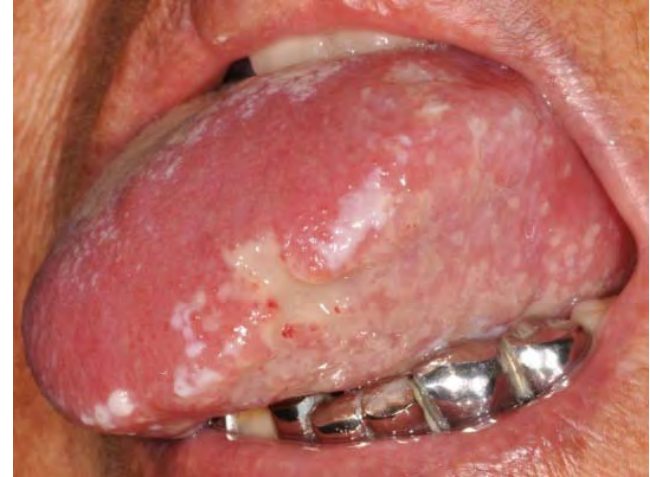Pseudomembranous

→ curdled milk / cottage cheese

→ broad-spectrum antibiotics or
impairment of immune system
(HIV or leukemia)

→ underlying mucosa: normal or
erythematous

if bleeding: maybe affected
(by lichen planus or cancer
chemotherapy)

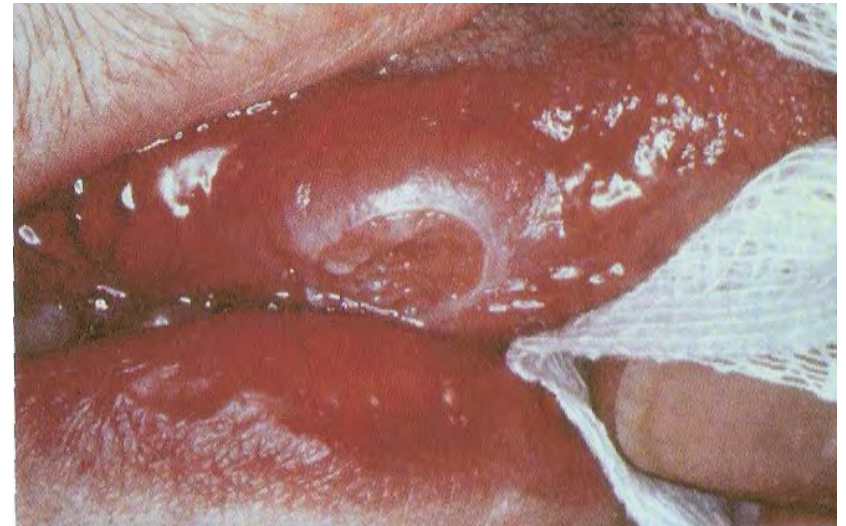
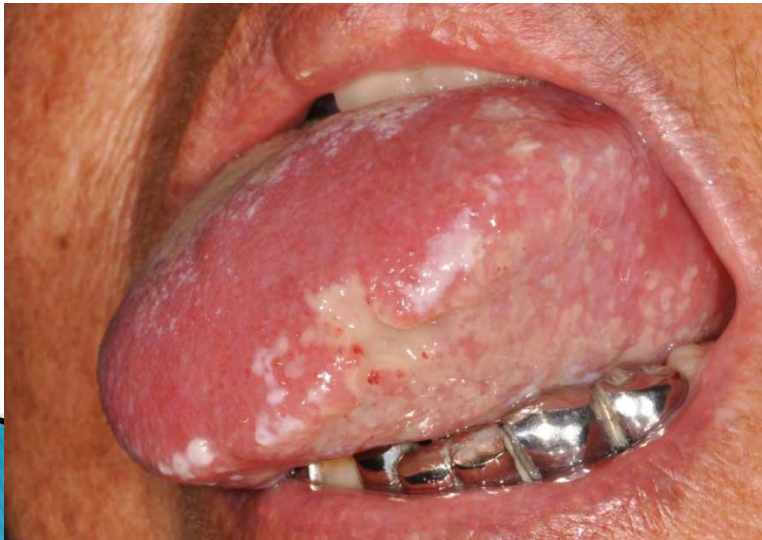

	This Case	Pseudomembranous candidiasis
Age	75	Varies
Gender	F	Both
Site	L't border of tongue	Tongue, palate, buccal mucosa
Size	2.5X0.5CM	Varies
Risk Factor	Alcohol : (-) Betel nut : (-) Cigarette : (-)	No specific
Duration	40days	Chronic (slow) or Acute(rapidly)

	This case	Pseudomembranous Candidiasis (thrush)
Color	White / Yellow	White/ yellow
Shape	Irregular	Irregular
Surface	Rough	Rough
Consistency	Firm	Soft
Pain	(+)	(-) burning sensation
Tenderness	(+)	(-)
Mobility	Fixed	Fixed
Induration	(-)	(-)
Ulcer	(+)	(+/-)

Tuberculosis

- Mycobacterium tuberculosis
- Secondary to pulmonary lesion > primary lesion
- Chest X-ray
- Be mistaken as traumatic ulcer or CA
- Sometimes involved bone

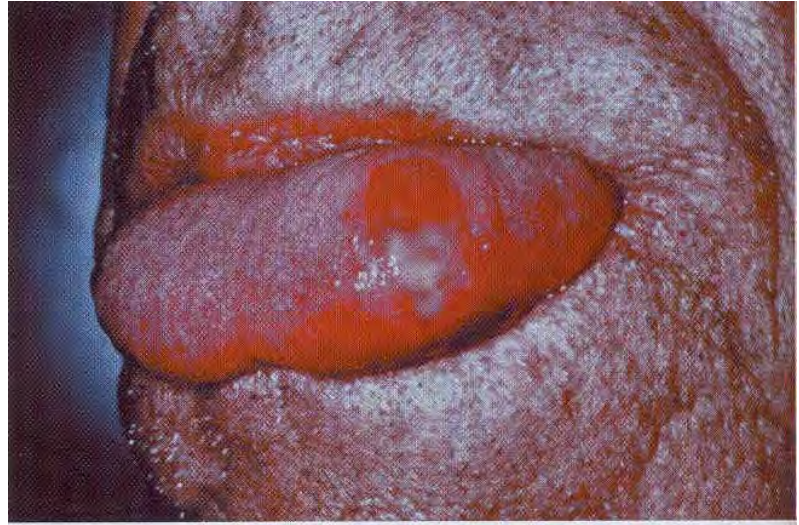
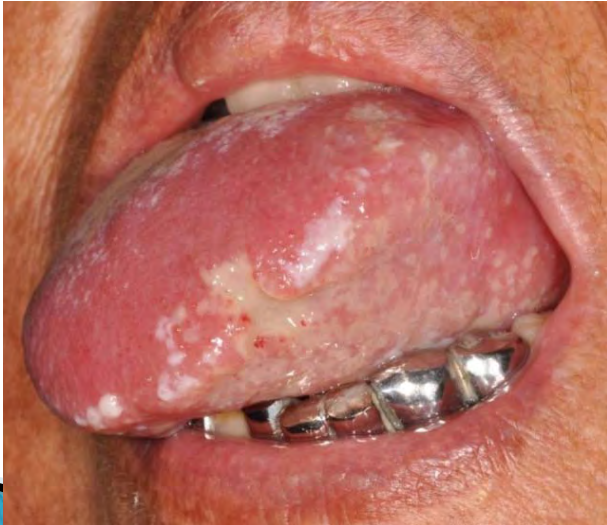
	This Case	Tuberculosis	
		Secondary	primary
Age	75	Varies	Child, adolescent
Gender	F	Both	
Site	L't border of tongue	(1)Tongue (2)Palate (3)lip	(1)Gingival (2)mucobuccal fold
Size	2.5X0.5CM	Varies	
Risk Factor	Alcohol : (-) Betel nut : (-) Cigarette : (-)	No specific	
Duration	40days	Become larger slowly	

	This case	Tuberculosis	
		Secondary	primary
Color	Yellow/White	Yellow	
Shape	Irrigular	Irrigular	
Surface	Rough	Granular	
Consistency	Firm	Firm	
Pain	(+)	(-)	(-)
Tenderness	(+)	(-)	
Mobility	Fixed	Fixed	
Induration	(-)	(-)	
Ulcer	(+)	(+)	

Primary Syphilis

- ▶ *Treponema pallidum*
- ▶ Genitalia and anus
- ▶ Chancre
- ▶ Heals within 3~8 weeks

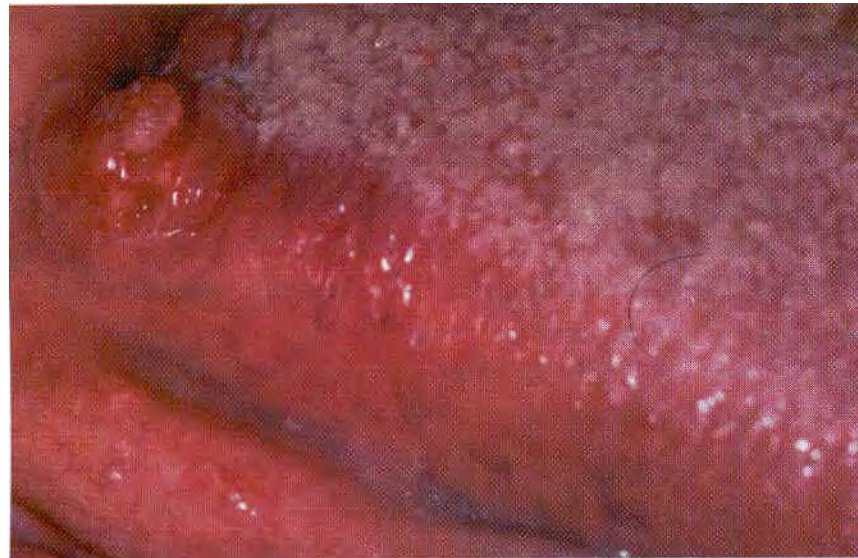
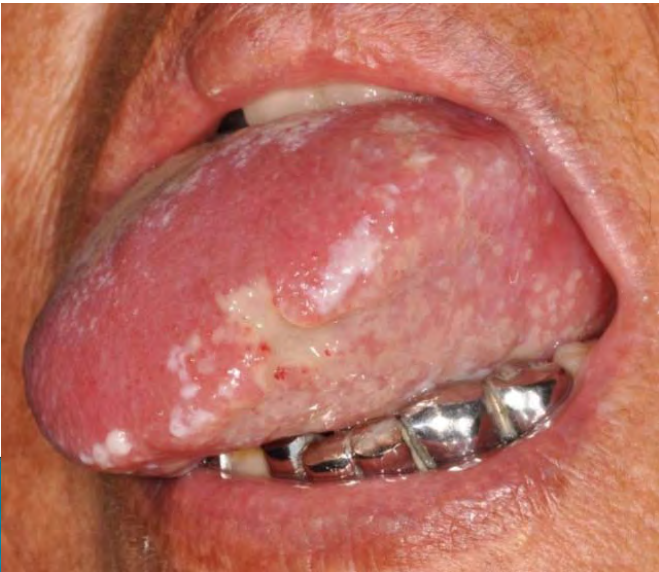
	This Case	Syphilis
Age	75	Varies
Gender	F	Both
Site	L't border of tongue	(1)Lip (2) Tongue , palate
Size	2.5X0.5 CM	Varies
Risk Factor	Alcohol : (-) Betel nut : (-) Cigarette : (-)	No specific
Duration	40days	3~90 days

	This case	Syphilis
Color	White/ Yellow	White
Shape	Irregular	Irregular
Surface	Rough	Smooth
Consistency	Firm	solid
Pain	(+)	(-)
Tenderness	(+)	(-)
Mobility	Fixed	Fixed
Induration	(-)	(-)
Ulcer	(+)	(+)

Squamous cell carcinoma


- ▶ Leukoplakia
- ▶ Etiology: alcohol; betel-nut; cigarette; syphilis; candidiasis; HPV 16, 18, 31, 33
- ▶ Metastasis: lung, liver, bone




	This Case	SCC
Age	75	↑
Gender	F	M
Site	L't border of tongue	(1)Lower vermilion (2)tongue (3)buccal mucosa
Size	2.5X0.5CM	Varies
Risk Factor	Alcohol : (-) Betel nut : (-) Cigarette : (-)	Alcohol : (+) Betel nut : (+) Cigarette : (+)
Duration	40days	> 1 month

	This case	SCC
Color	White/ Yellow	Yellow/ Red
Shape	Irregular	Irregular
Surface	Rough	Rough
Consistency	Firm	Firm
Pain	(+)	(+/-)
Tenderness	(+)	(-)
Mobility	Fixed	Fixed
Induration	(-)	(+)
Ulcer	(+)	(+)

Working Diagnosis

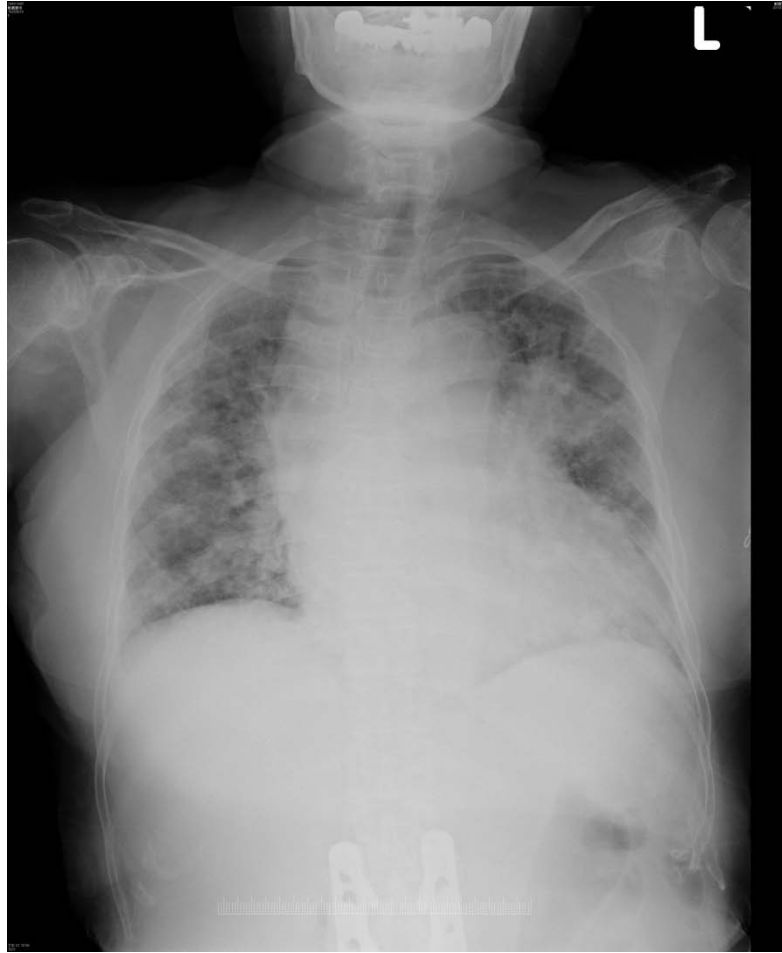- ▶ Tuberculosis(secondary lesion)
 - ▶ Pseudomembranous candidiasis
 - ▶ Syphilis
 - ▶ Squamous cell carcinoma
- 

Clinical Impression

- ▶ Tuberculosis over the left border of the tongue
 - ▶ Candidiasis over the left border, ventral and dorsal parts of the tongue
- 

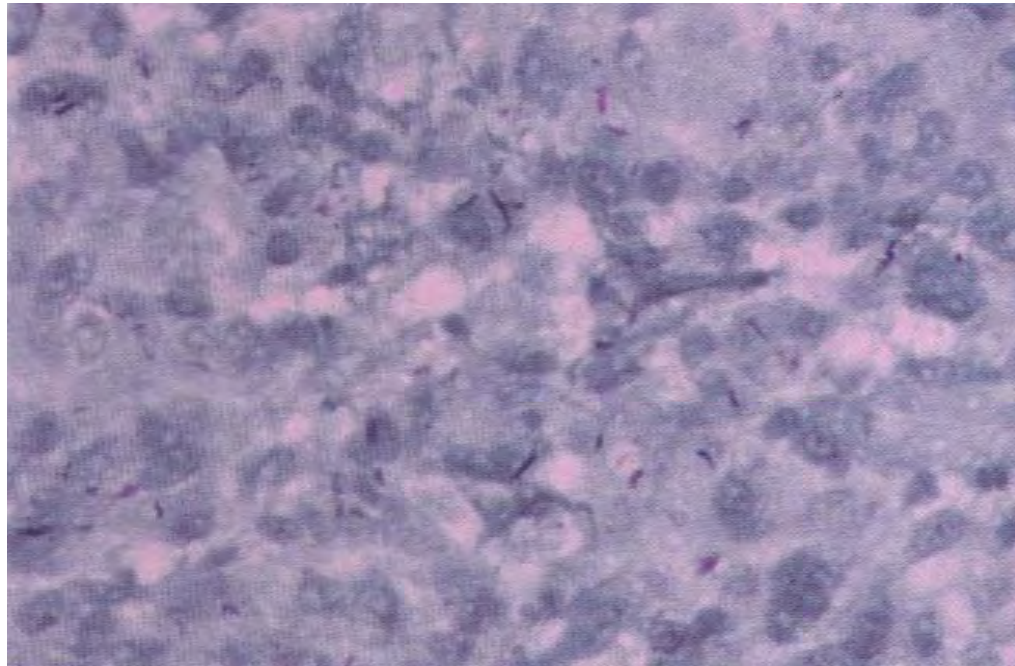
Dissusion

Chest X-ray



Histopathologic Features of TB

- ▶ Granulomatous inflammation
- ▶ Tubercle
- ▶ Acid fast stain—Ziehl-Veelsen stain



Thank you for your listening

