

Case Report



組別：Intern L組

組員：王宗民、林弘哲、侯政廷、杜鴻慶

指導老師：口腔病理診斷科全體醫師

Personal Data



☞ Name: 李○○

☞ Gender: Male

☞ Age: 47 y/o

☞ First visit dentist: 陳靜怡醫師

☞ First visit date: 100.07.21

Chief Complaint



☞ Toothache over tooth 12

Present illness



☞ The 42 y/o male had tooth 12 PFM about 10 years. This morning, he went to LDC for help and dentist suggested him to come to our OPD for further examination.

Past Medical History and Past Dental History



☞ Systemic diseases: HIV ,高血壓

☞ Drug Allergy: Denied

☞ Hospitalization: Denied

☞ Past dental history: No data

Personal Habit



- Personal habits:

- A (-)

- B (-)

- C (-)

- Other habits: Denied

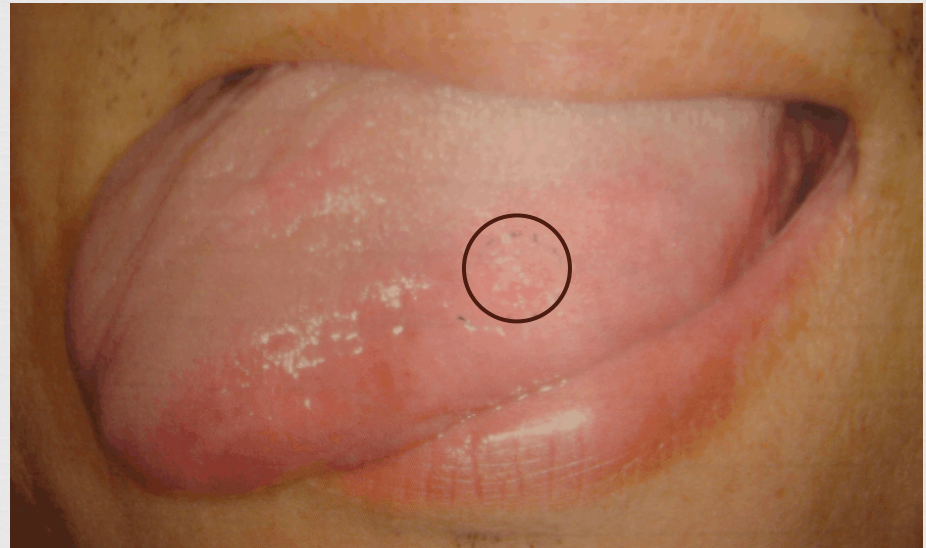OMF Findings(I)



Extraoral examination: N.P.

Intraoral examination:

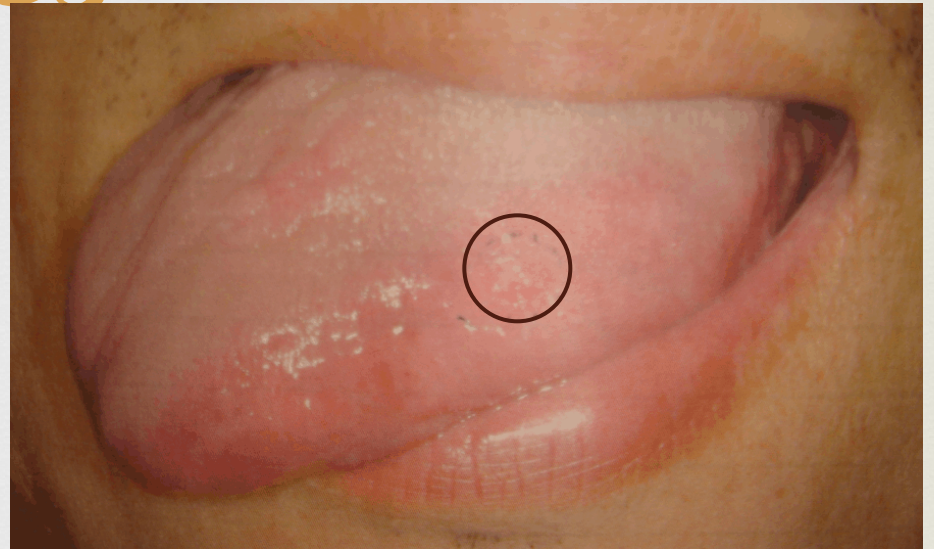- ☞ An ulcer at left lateral tongue border
- ☞ Max. Dimension: 0.6x0.3cm
- ☞ Shape: Hard to define
- ☞ Base: sessile
- ☞ Surface: ulcerative
- ☞ Color: red
- ☞ Consistency: firm



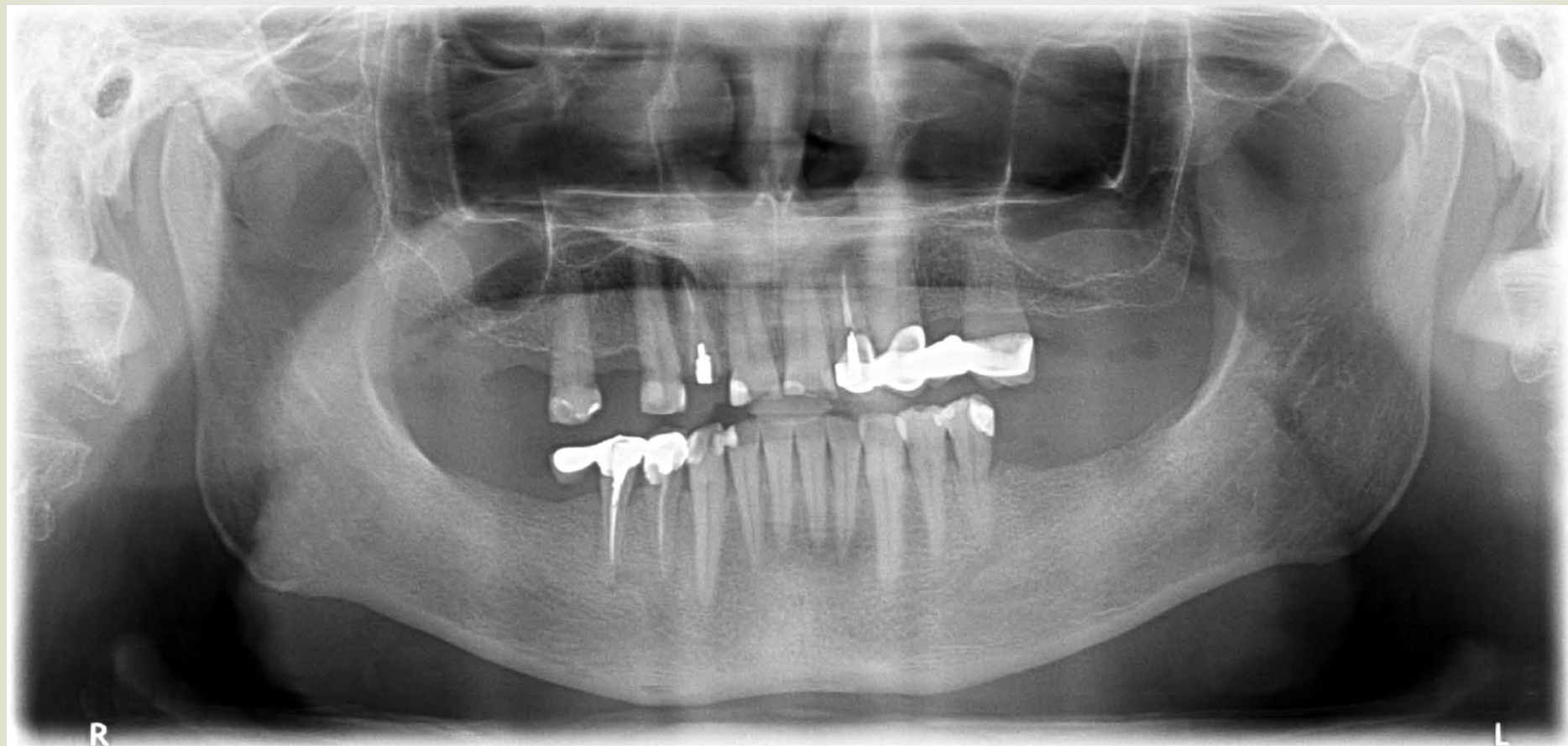
OMF Findings(II)



- ☞ Mobility: fixed
- ☞ Pain (-)
- ☞ Tenderness (-)
- ☞ Induration (+)
- ☞ Fluctuation (-)
- ☞ Discharge (-)
- ☞ Neck LAP (unknown)



PANOREX Finding



Differential Diagnoses



Criteria of differential diagnosis based on...

Delayed healing ulcer over L't lateral tongue border with reddish color, ulcerative surface, firm in consistency.

Inflammation ? Infection ? Cyst ? Neoplasm ?

- Color : red
- Consistency : firm
- Fever or local heat : (-)
- Discharge : (-)
- Pain : (-)
- Fluctuation : (-)
- Ulceration : (+)
- Induration: (+)
- Duration : 3 months
- Swelling : (-)



→ ***Neoplasm or Infection***

Central or Peripheral ?



- Lesion over tongue

→ *Peripheral*

Malignant or Benign ?



- Ulceration : (+)
- Mobility : fixed
- Induration : (+)

→ Malignant

Working Diagnosis

Neoplasm



1. Squamous cell carcinoma
2. Non Hodgkin's Lymphoma
3. Fibrosarcoma
4. Kaposi's Sarcoma

Infection

1. Tuberculosis
2. Herpes infection(HSV-1)

Neoplasm

Squamous cell carcinoma (1)

Factors	Our Case	SCC
Age	47	53
Gender	Male	Males
Site	Left tongue border	1. Buccal mucosa 2. Tongue 3. Gingiva
Duration	3 months	4-8 months
Color	Red	Yellow/Red
Shape	Hard to define	Irregular

Squamous cell carcinoma (2)

Surface	Ulcerative	Superficial ulcerated
Consistency	firm	Firm
Pain	(-)	Gingiva / alveolar site (-)
Tenderness	(-)	(+)
Mobility	Fixed	Fixed
Induration	(+)	(+)

Non Hodgkin's Lymphoma (1)

Factors	Our Case	Lymphoma
Age	47	60
Gender	Male	Both
Site	Left tongue border	CNS(most) Oral(only 4%---gingiva , tongue, palate)
Duration	3 months	Growth slowly(several months)
Color	Red	Red
Shape	Hard to define	Irregular

Non Hodgkin's Lymphoma (2)

Surface	Ulcerative	Ulcerative
Consistency	Firm	Soft
Pain	(-)	(+)
Tenderness	(-)	(-)
Mobility	Fixed	Fixed
Induration	(+)	(-)

Fibrosarcoma (1)

Factors	Our Case	Fibrosarcoma
Age	47	Any age Most common in young adult and children
Gender	Male	Male : Female = 1:1
Site	Left tongue border	Extremities ; bones of the head and neck (10%)
Duration	3 months	Slow growing
Color	Red	Normal
Shape	Hard to define	Irregular

Fibrosarcoma (2)

	Our case	Fibrosarcoma
Surface	Ulcerative	Smooth
Consistency	Firm	Firm
Pain	(-)	(+)
Tenderness	(-)	+/-
Mobility	Fixed	Fixed
Induration	(+/-)	(+)

Kaposi's Sarcoma (1)

Factors	Our Case	Major Aphthous Ulcer
Age	47	Over 60
Gender	Male	equal
Site	Left tongue border	Hard palate Gingiva tongue
Duration	3 months	Grow slowly and develop over years.
Color	Red	Brown or reddish
Shape	Hard to define	Nodular

Kaposi's Sarcoma (2)

Surface	Ulcerative	Smooth
Consistency	Firm	Firm
Pain	(-)	(+)
Tenderness	(-)	(-)
Mobility	Fixed	Fixed
Induration	(+)	(-)

Infection

Tuberculosis (1)

Factors	Our Case	Tuberculosis
Age	47	Unspecified
Gender	Male	Both
Site	Left tongue border	Tongue, Palate, Lip
Duration	3 months	4 weeks
Color	Red	Red
Shape	Hard to define	Irregular

Tuberculosis (2)

Surface	Ulcerative	Ulcerative
Consistency	Firm	Firm
Pain	(-)	(+)
Tenderness	(-)	(+)
Mobility	Fixed	Fixed
Induration	(+)	(-)

Herpes infection(HSV-1) (1)

Factors	Our Case	Herpes Infection
Age	47	Most often over upper 60
Gender	Male	Same
Site	Left tongue border	Lip Vermillion
Duration	3 months	7~10 days
Color	Red	Yellow
Shape	Hard to define	oval /ragged oval(crateriforme)

Herpes infection(HSV-1) (2)

Surface	Ulcerative	Superficial ulcerated
Consistency	Firm	Firm
Pain	(-)	(+)
Tenderness	(-)	(+)
Mobility	Fixed	Fixed
Induration	(+)	(+)

Clinical Impression



- ❧ Squamous cell carcinoma, left lateral tongue border
- ❧ Tuberculosis, left lateral tongue border



**THANKS FOR YOUR
ATTENTION!**

References



❧ Oral and Maxillofacial Pathology 3rd Edition

Neville/Damm/Allen/Bouquot

P287~289,410~426,766~778,362~369,766~771,550~561

❧ 口腔病理科教學網<http://oralpathol.dlearn.kmu.edu.tw/>