



Case Report

指導老師:

V.S. : 林立民 陳玉昆醫師 王文岑醫師

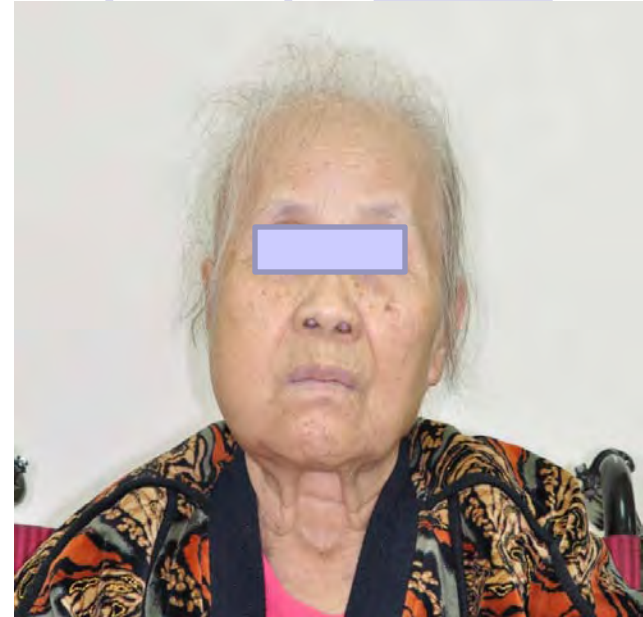Resident : 陳靜怡醫師 謝牧諺醫師

Int : 沈鼎曜 洪國雄 方子榮 洪崇勛

日期: 99.04.26

General Data

- Name : 張陳X英
- Gender : Female
- Age : 72
- Occupation : 無
- Attending V.S. : 楊家福醫師
- First visit : 99. 2. 24



Chief Complaint

- Refer from 國軍高雄總醫院 for right cheek swelling and trismus over 4 weeks

Present Illness



98/11

- This 72 y/o female is a patient of diffuse large B cell lymphoma diagnosed of stomach and duodenum with mediastinal lymph nodes involved.

99/2

- Progressive painful swelling over right cheek was noted. 國軍高雄總醫院 diagnosed as cellulitis before 4th chemotherapy, but symptom and sign presented for a long time, so she was referred to our OPD for help.

Past History




Past medical history

- Diffuse large B cell lymphoma of stomach and duodenum s/p chemotherapy
- Hypertension (under control)
- Drug allergy: denied
- Diabeted mellitus: denied

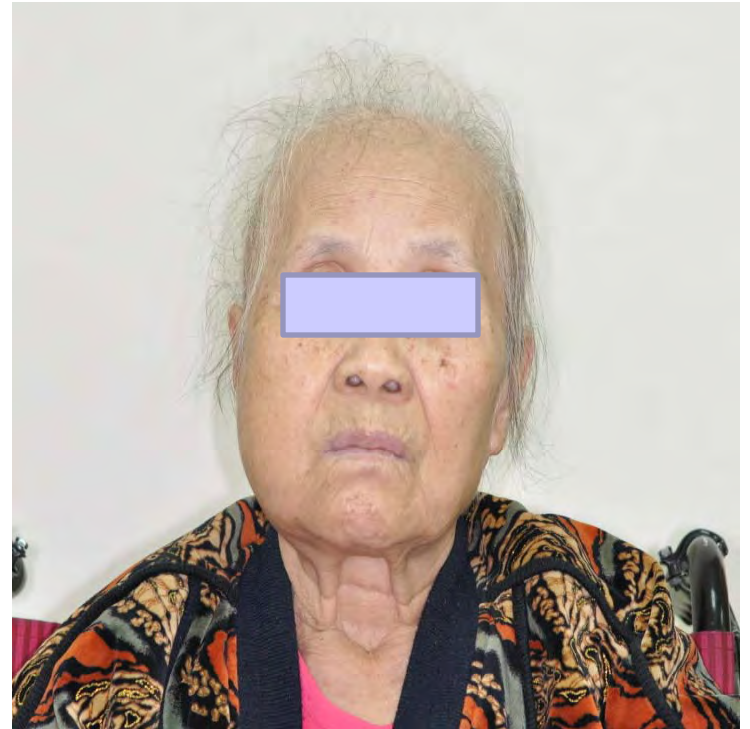Risk factors

- Alcohol: (-)
- Betel nut: (-)
- Cigarette: (-)



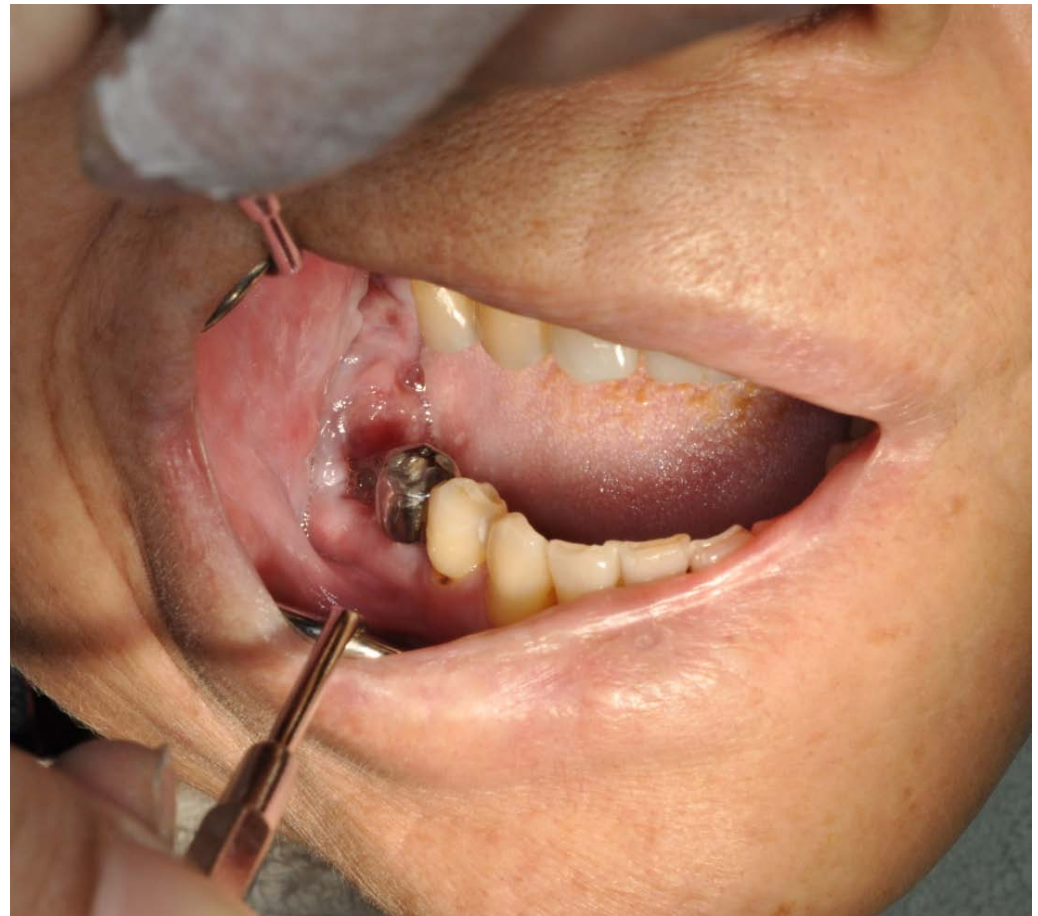Extraoral examination

- Right cheek swelling
- Trismus

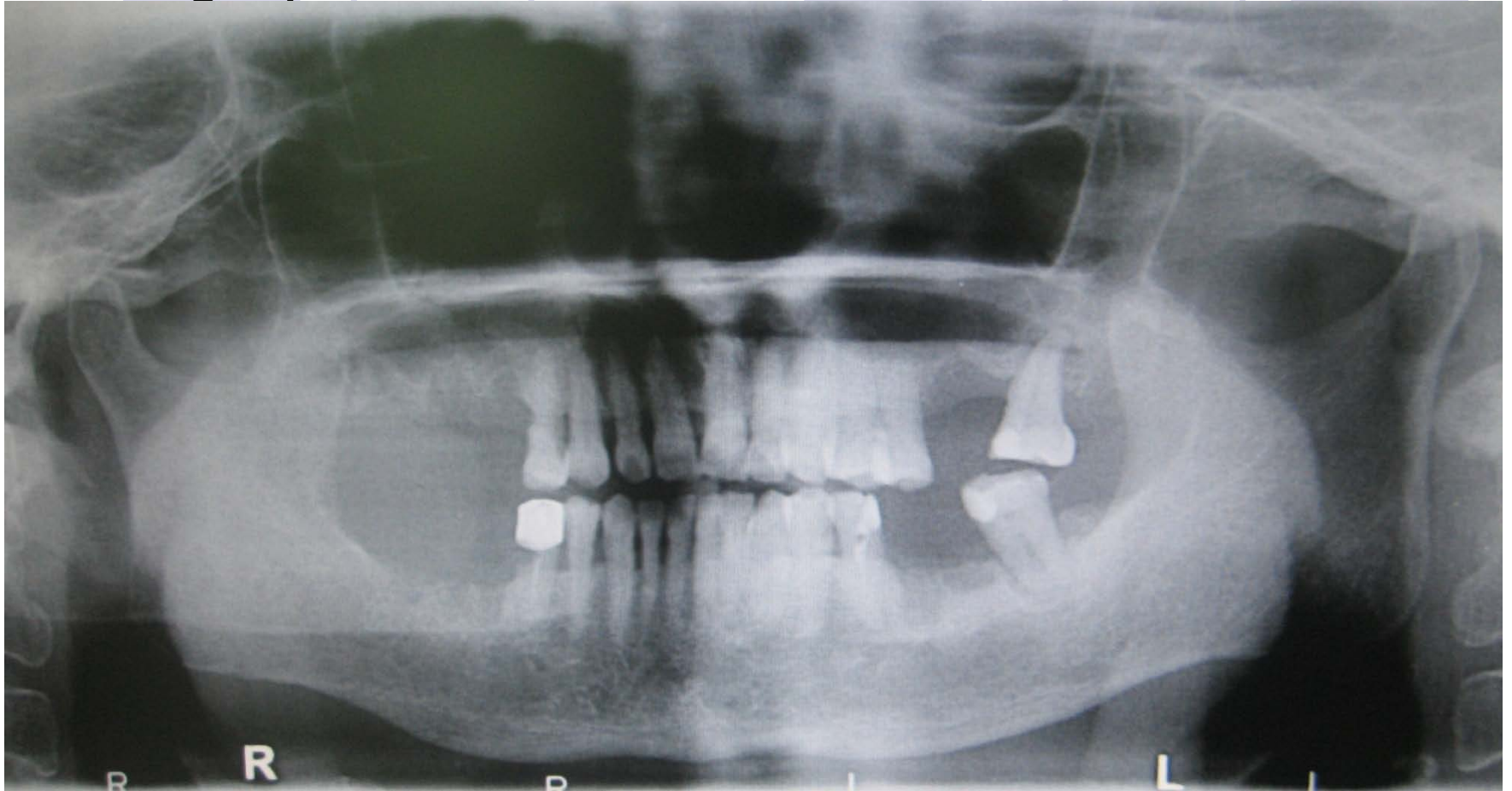


Intraoral examination



- Polypoid mass over right edntulous ridge to PMR
- Size: 3.5x1 cm
- Shape: polypoid
- Color: red
- Consistency: firm
- Fluctuation: (-)
- Mobility: fixed
- Pain: (+)
- Tenderness: (+)
- Induration: (+)



Radiographic examination



- Missing: 15, 16, 17, 18, 26, 28, 36, 38, 46, 47, 48
- Upper alveolar ridge resorption
- Sinus: clear
- TMJ: Unremarkable



**Inflammation ? Cyst ? Neoplasm ?
Infection ?**

Inflammation ? Infection ?

Cyst ? Neoplasm ?

- Color: red**
- Pain: (+)**
- Fever and local heat: (-)**
- Tenderness: (+)**
- Fixed**
- Induration: (+)**
- Shape: polypoid**
- **R/O inflammation, infection, cyst**
- **Neoplasm**

Benign

1. Movable (except palate)
2. Unattached to skin or mucosa (except palate)
3. No ulceration of skin or mucosa
4. Slow growth, Long duration
5. No pain
6. No facial nerve palsy
7. No bony invasion Features
8. well-defined radiolucency with corticated margin

Malignant

1. **Induration**
2. **Fixed to overlying skin or mucosa**
3. **Ulceration of skin or mucosa**
4. Rapid growth; growth spurt, Short duration
5. **Pain, often severe**
6. Facial nerve palsy
7. Bony invasion
8. ill-defined radiolucency without corticated margin

Peripheral or intrabony origin?

- No evident bony invasion
- Induration:(+)
- Fluctuation:(-)
- Consistency: firm
- Mobility: fixed

Peripheral

Intrabony





Differential Diagnosis



- Non-Hodgkin's lymphoma (metastatic)
- Squamous cell carcinoma
- Carcinoma ex pleomorphic adenoma
- Polymorphous Low-Grade Adenocarcinoma



Non-Hodgkin's lymphoma (metastatic)



Our case

Non-Hodgkin's lymphoma

gender

Female

Male

age

72 y/o

Adult

site






Pterygomandibular raphe

Buccal vestibule, posterior hard
palate, gingiva

swelling

(+)

(+) Diffuse swelling



Our case

Non-Hodgkin's lymphoma

consistency

firm

Boggy

color

red

Erythematous or purplish

tenderness

(+)

(-)

induration


(+)

?


LAP

(+)

(+)



Squamous cell carcinoma



Our case

SCC

gender

Female

Male : Female = 3 : 1

age

72 y/o

Mostly 40-80 yrs or older

site

Pterygomandibular raphe

On the lip, floor or roof of the mouth, tongue, soft and hard palate & gum

color

Red

Pink, white, red or white & red



Our case

SCC

consistency

firm

firm

pain

(+)

(+) or (-)

shape

polypoid






Exophytic (mass-forming ,
fungating , papillary verruciform ,
ulcerated)

Endophytic (invasive , burrowing ,
ulcerated)


Leukoplakic(white patch)

Erythroplakic(red patch)



Erythroleukoplakic (combined
red&white)



	Our case	SCC
fluctuation	(-)	(-)
mobility	fixed	fixed
induration	(+)	(+)



Carcinoma ex pleomorphic adenoma



Our case

Carcinoma ex pleomorphic adenoma

gender

Female

Slight female predilection

age

72 y/o

Sixth to eighth decade

site


Pterygomandibular raphe

Parotid gland


Pain

(+)

(+) or (-)



Polymorphous Low-Grade Adenocarcinoma



Our case

Adenoid cystic carcinoma

gender

Female

Female (2/3)

age

72 y/o

Elderly

site

Pterygomandibular raphe

Hard and soft palate(65%)


Upper lip and buccal mucosa

Pain

(+)

Mostly painless

Clinical impression



- Non-Hodgkin's lymphoma over edentulous ridge of tooth 46 to R't Pterygomandibular raphe



Thanks for your attention !