

# INTERESTING CASE

Intern K組： 張育嘉 廖宏修 何祖銘 謝嘉玲 郭吉倫 鍾芝華

報告日期：97. 4. 25

指導老師：口腔病理科全體醫師

# General data

- Name : 洪X
- Age : 59 y/o
- Gender : Female
- Occupation : house wife
- Marital status : Married
- Native: 高雄市
- 初診日期: 96.5.16
- 主治醫師: 沈也雄醫師

# Chief complaint

---

- Swelling over left lower second and third molars extracted socket

# Present illness

This 59 y/o female went to 青山LDC for FMS last year, the doctor suggested her came to our OPD for evaluation of tooth 37 & 38 for extraction.

- 96/5/16 extract 37RR & 38 horizontal impaction
- 97/4/14 swelling over 37, 38 extracted socket

Tx: debridement under LA, specimen was sent for HP

- 97/4/21 HP report : Chondrosarcoma, left mandible

Suggested wide excision + explain the risk of the disorder

# Past medical history

---

- ❑ Denied any systemic disease
- ❑ Drug allergy : denied

# Past dental history

---

- OD
- Prostho
- Scaling
- Extraction

# Personal habits

---

- Cigarette smoking (?)
- Alcohol drinking (?)
- Betel quid chewing (?)
- Other special oral habits (?)

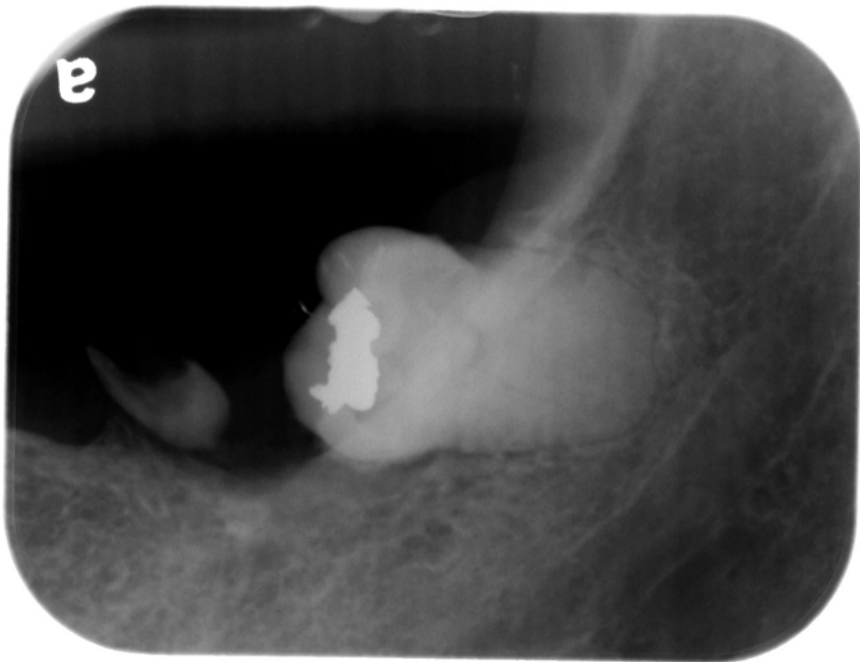
# Intraoral & Extraoral Exam

- Swelling over 37, 38 extracted socket
- Duration (?)
- Pain (-)
- Consistency- rubbery to firm
- Color - grayish to brownish
- Tenderness (-)
- Swelling (+)
- Ulceration (-)
- Fixed (-)
- Induration (-)
- Pus discharge (-)
- Local heat (-)
- Lymphadenopathy (-)



# X-ray Examination

□ 96/05/16

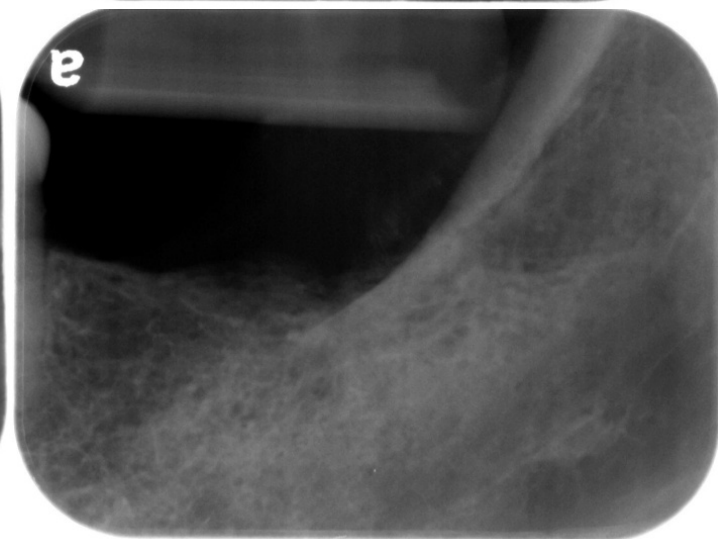
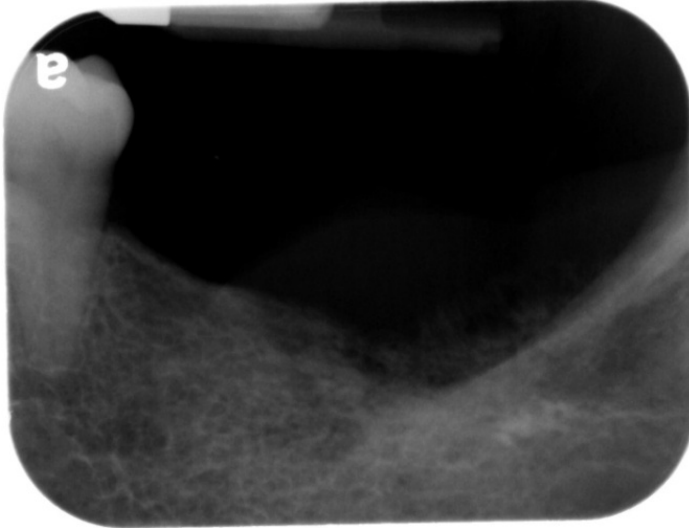
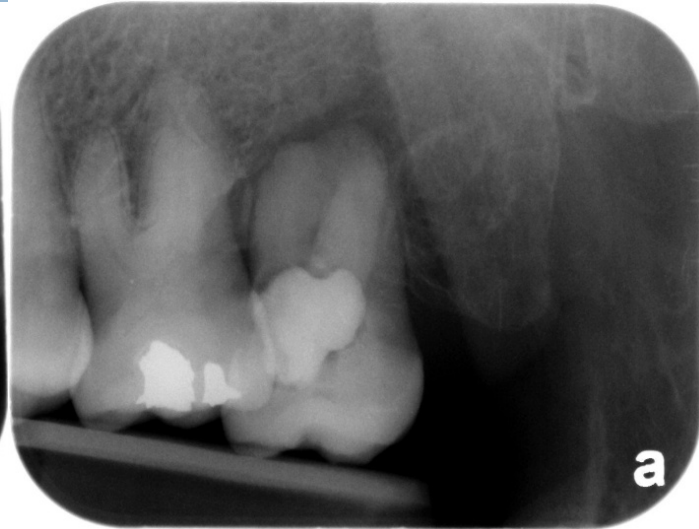
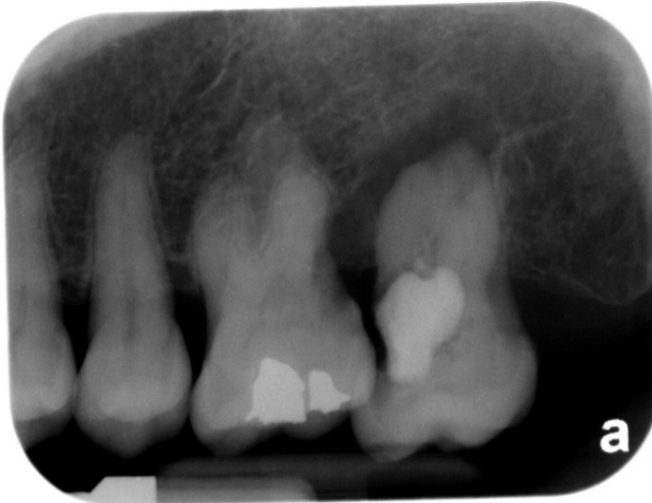
Tooth 37 residual root

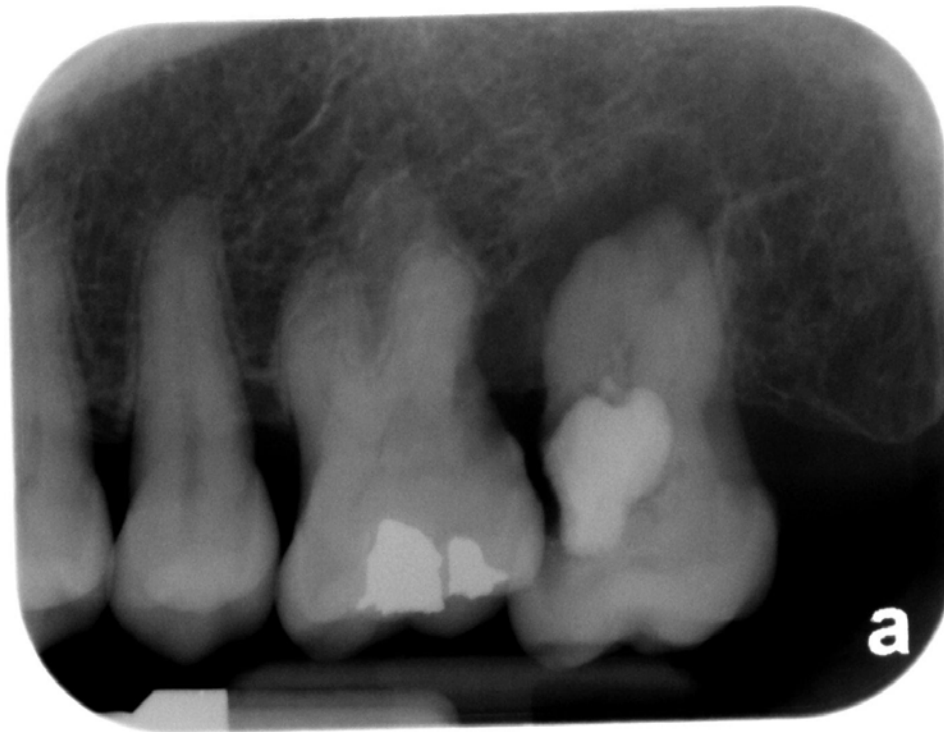Tooth 38 horizontal impaction  
with amalgam filling on  
occlusal side

# X-ray Examination

97/04/14



# X-ray Examination

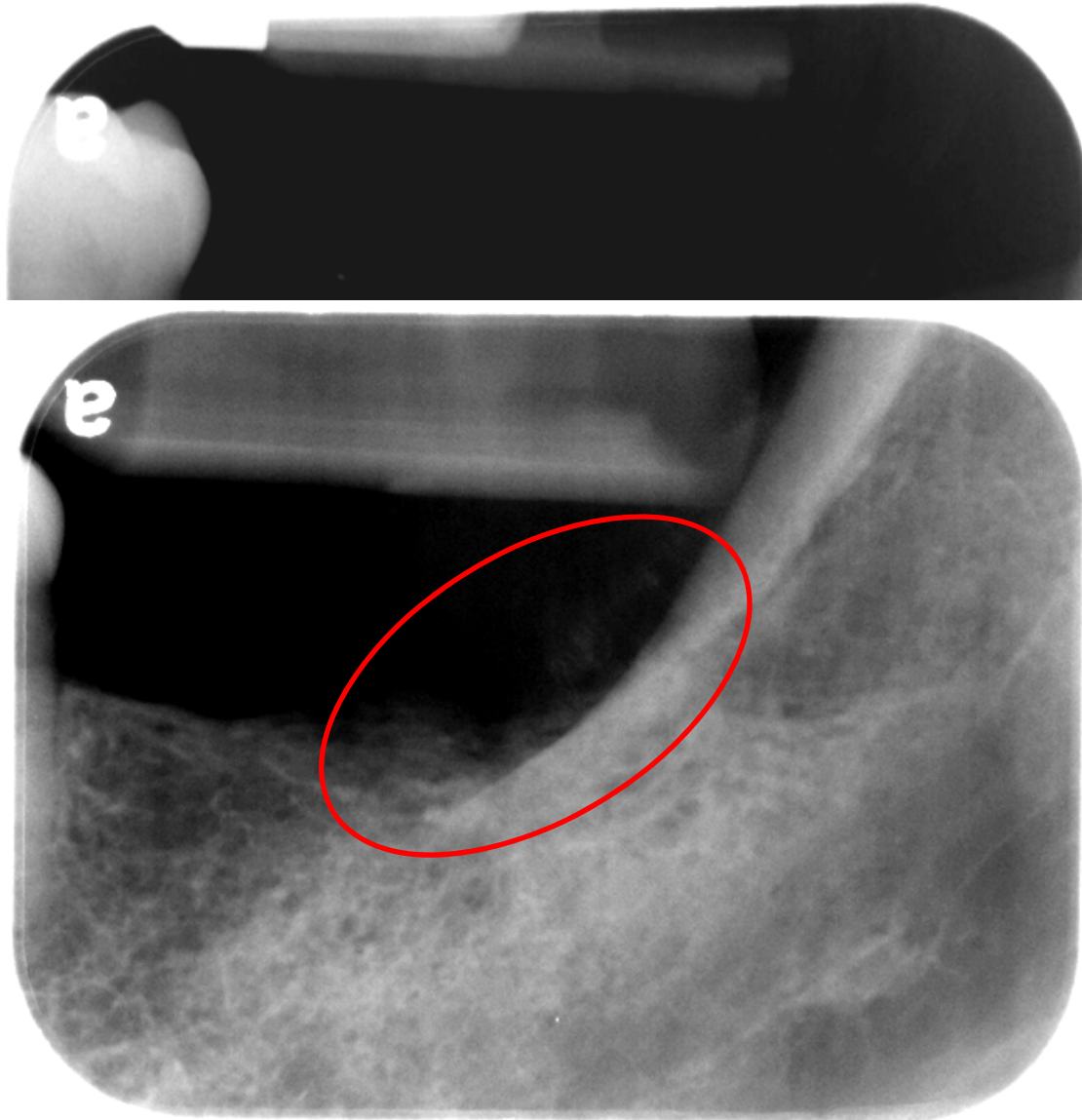


Tooth 26 : amalgam restoration on occlusal side, and a large decay on distal side. Bony defect was noticed on 26 distal side.

Tooth 27 : a large restoration and secondary caries on mesial side, with pulp involvement.

The tooth also has caries on distal side, and an ovoid-shaped radiolucency surrounding tooth 27 root

# X-ray Examination



There is an ill-defined radiolucency without a corticated border around 2cm X 0.5cm in diameter at 37, 38 edentulous ridge. There is sunray spicules (hair-on- end) on the edentulous ridge of 37 and 38 , and extending from the 37 edentulous area to the external oblique ridge



# Differential diagnosis

# Inflammation or cyst or neoplasm

## Clinical feature

- Local heat(-)
- Pain(-)
- Consistency - rubbery to firm
- Induration(-)
- Fixed(-)
- Tenderness(-)
- Pus discharge(-)

## X-ray finding

- Ill-defined without corticated border

**Neoplasm**

# Benign or malignant

## Clinical feature

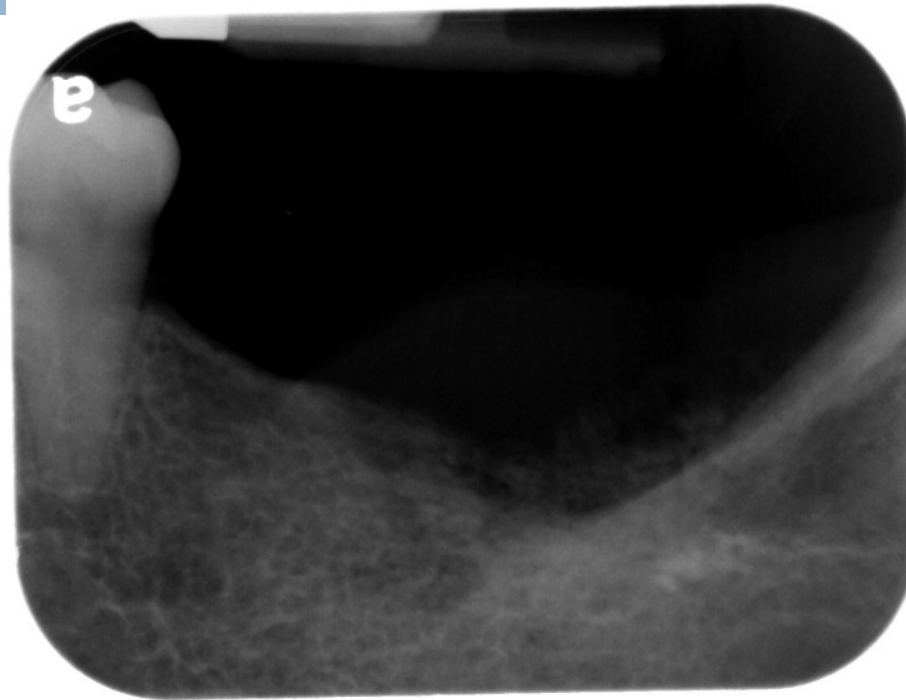
- Duration(?)
- Fixed(-)
- Induration(-)
- Ulceration(-)
- Lymphadenopathy (-)
- Pain(-)

## X-ray finding

- Ill-defined (+)

**Malignant or  
Benign**

# Intrabony or peripheral



## Peripheral



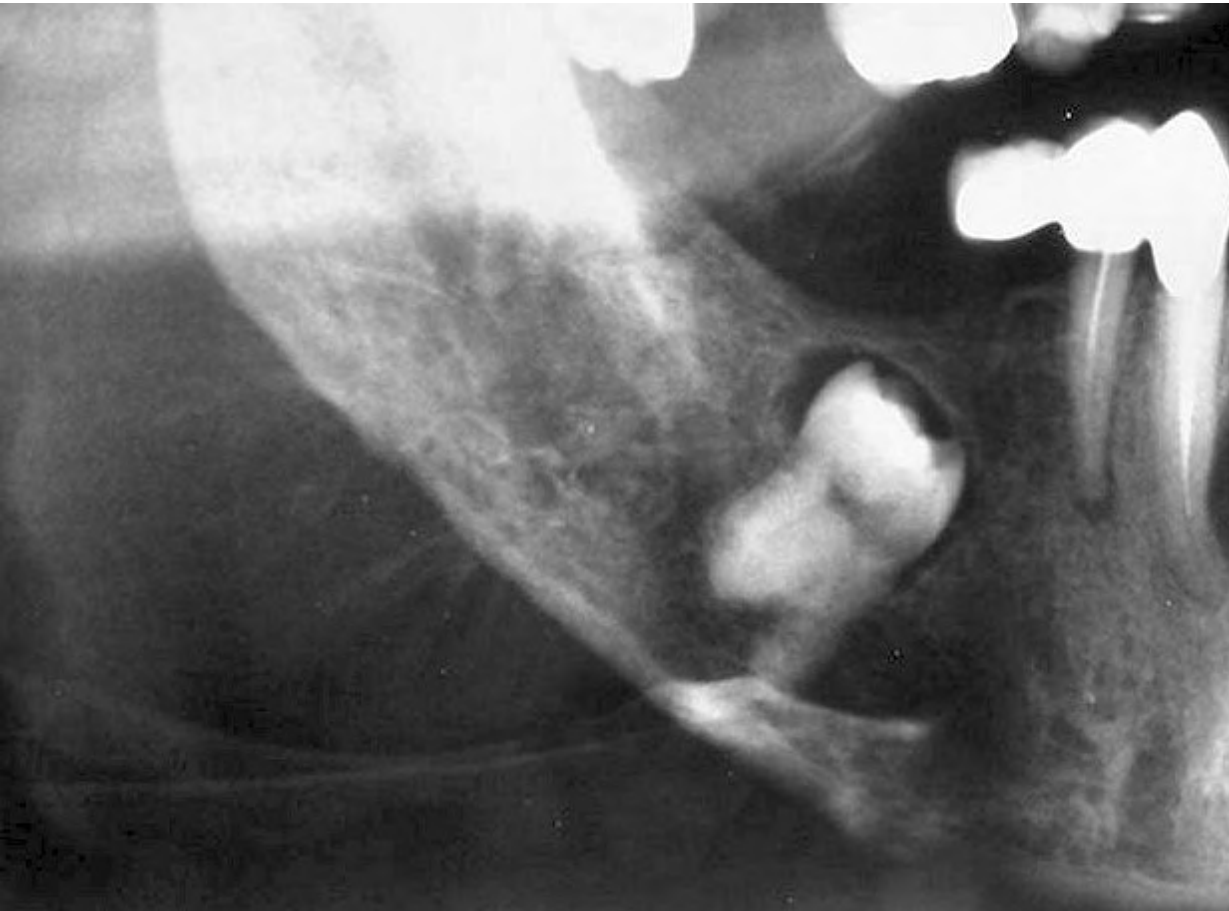
# Working diagnosis



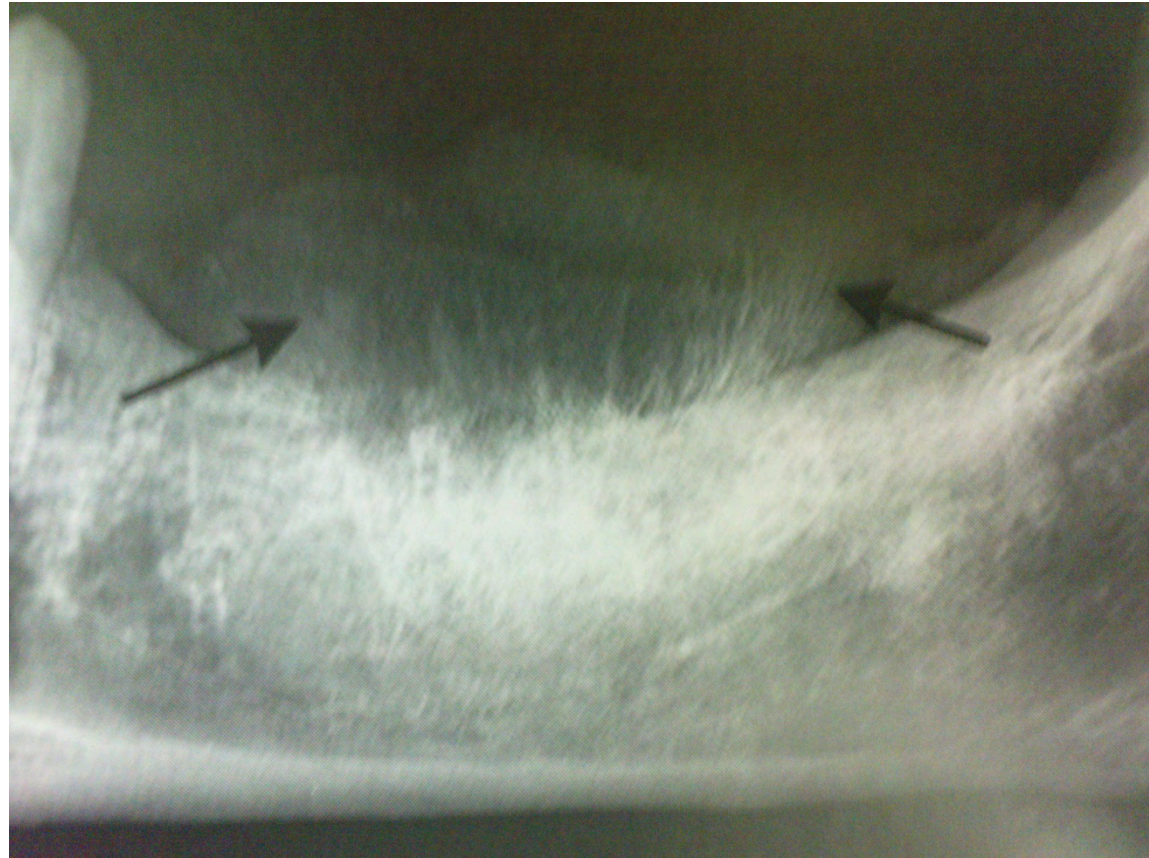
## Peripheral Malignant/Benign Neoplasm

- Osteosarcoma
- Chondrosarcoma
- Fibrous dysplasia
- Ewing's sarcoma

# Osteosarcoma



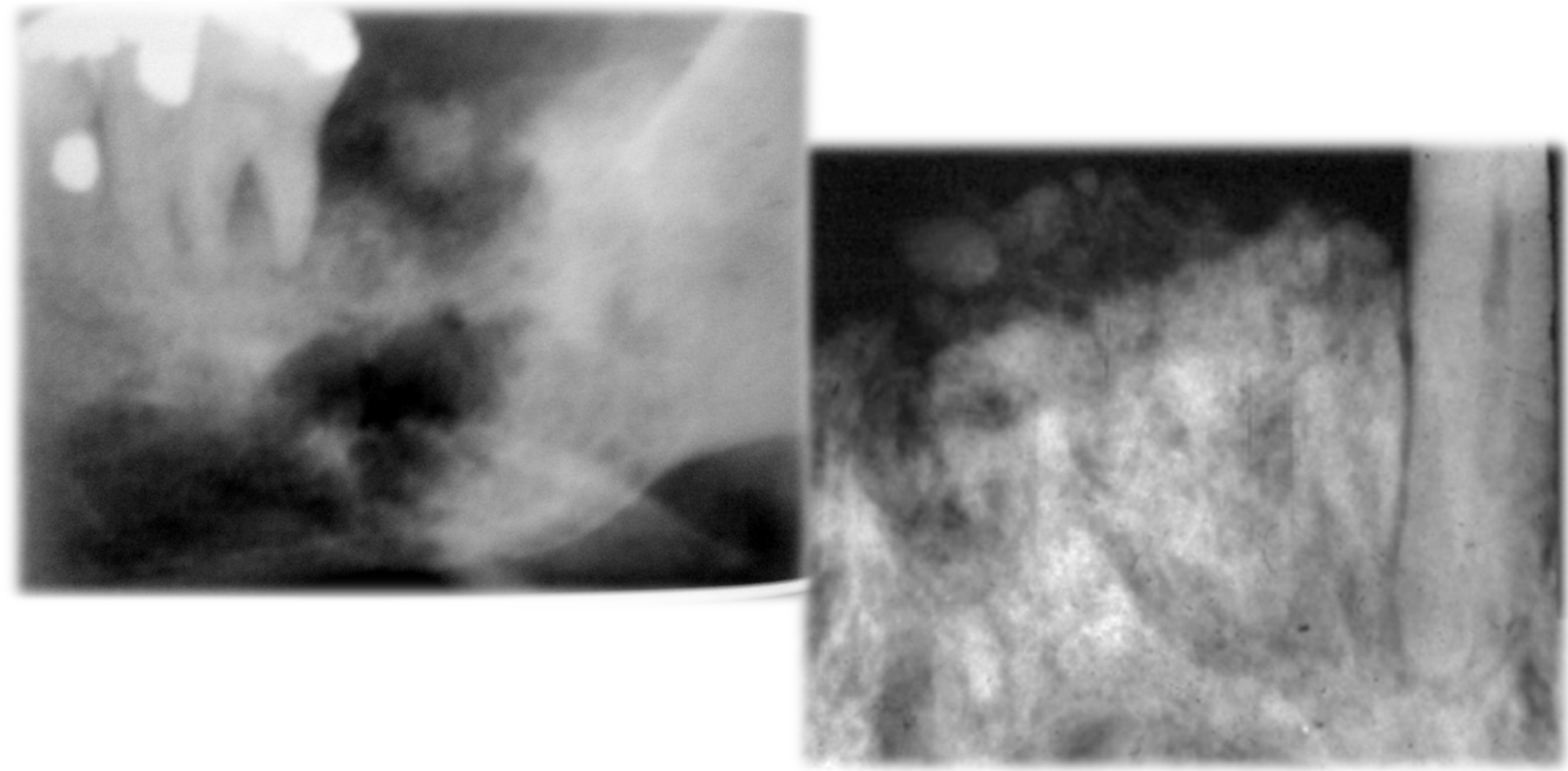
# Osteosarcoma



White. Pharoah, Oral Radiology; P293

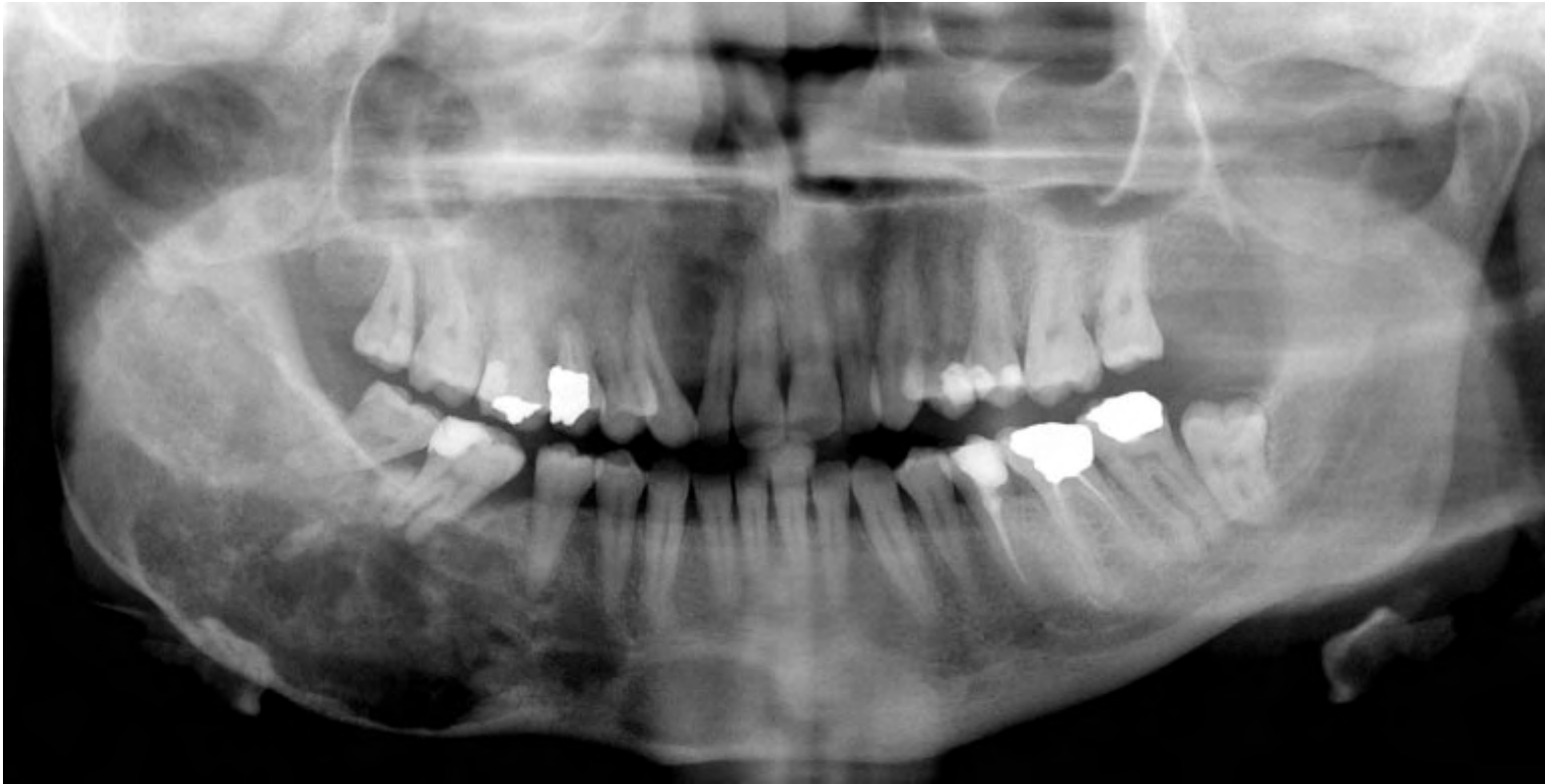	Osteosarcoma	Our case
Age	Fourth decade	59 y/o
Gender	Male	Female
S/S	Pain and Swelling	Painless Swelling over 37, 38 socket,
Location	Posterior mandible	Left posterior mandible
Radiographic feature	Radiolucency or mixed radiopacity Sunburst Ill-defined Spiking resorption	1. sunray spicules (hair-on-end) on the edentulous ridge of 37 2. ill-defined, without corticated border, and with sparse calcification

# Chondrosarcoma



	Chondrosarcoma	Our case
Age	Wide age range(60~70 y/o is the peak)	59 y/o
Gender	Equal	Female
S/S	<ol style="list-style-type: none"> <li>1. Painless mass or swelling</li> <li>2. Maybe separation or loosening teeth</li> <li>3. Maxillary tumor may cause nasal obstruction, congestion, epistaxis, photophobia, or visual loss</li> </ol>	Painless Swelling over 37, 38 socket,
Location	<ol style="list-style-type: none"> <li>1. Ileum, femur, humerus(facial cranial bone 10%)</li> <li>2. Maxillary:anterior region mandibular:coronoid process, condyle head)</li> </ol>	Left posterior mandible
Radiographic feature	<ol style="list-style-type: none"> <li>1. Round, ovoid, or lobulated</li> <li>2. Well defined and corticated</li> <li>3. Sunray or hair-on-end appearance</li> <li>4. Radiolucency contains scattered radiopaque foci</li> </ol>	<ol style="list-style-type: none"> <li>1. Sunray spicules (hair-on-end) on the edentulous ridge of 37</li> <li>2. Ill-defined, without corticated border, and with sparse calcification</li> </ol>

# Fibrous dysplasia

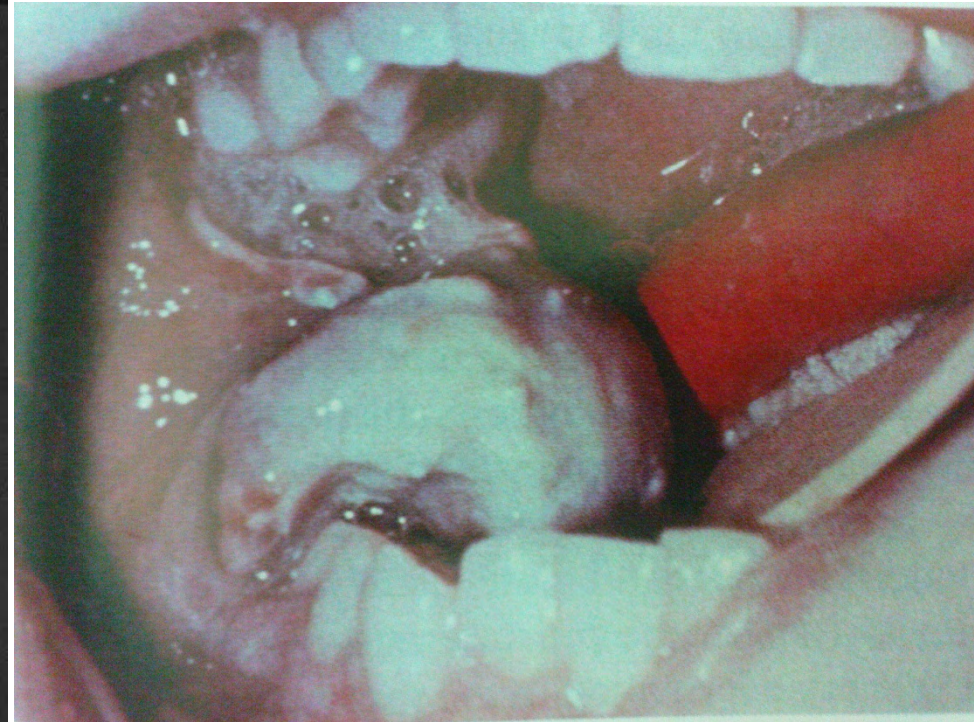
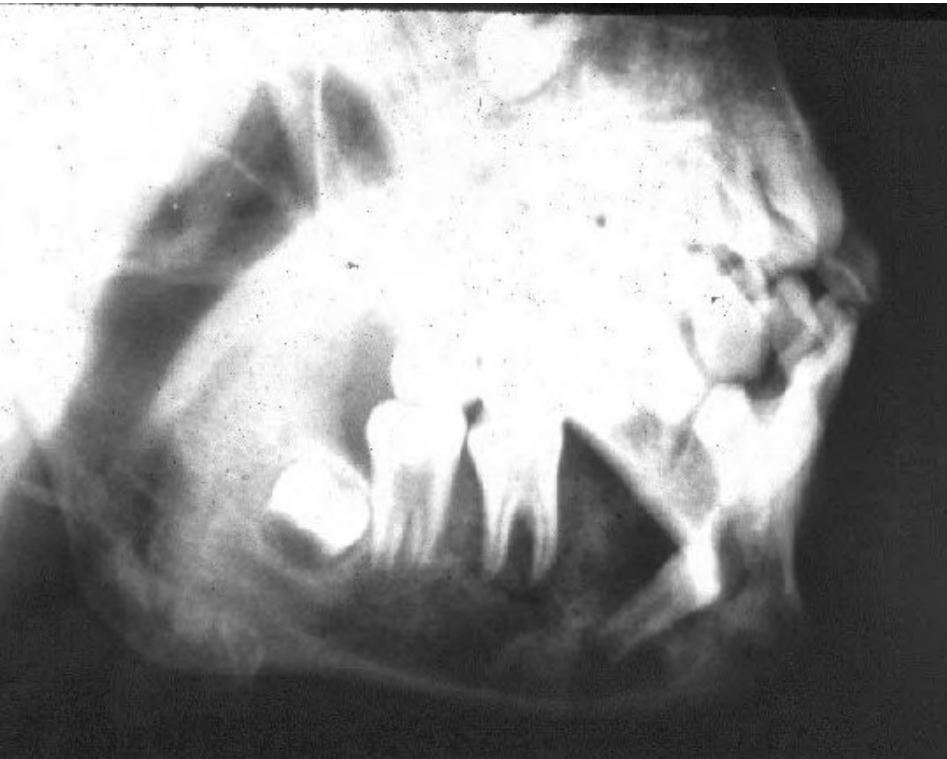



	Fibrous dysplasia	Our case
Age	20	59 y/o
Gender	Equal	Female
S/S	No S/S	Painless Swelling over 37, 38 socket,
Location	Maxilla	Left posterior mandible
Radiographic feature	Ground glass appearance Ill-defined PDL widening, lamina dura disappear	1. sunray spicules (hair- on- end) on the edentulous ridge of 37 2. ill-defined, without corticated border, and with sparse calcification



# Ewing's sarcoma



	Ewing' s sarcoma	Our case
Age	5–30	59 y/o
Gender	Male	Female
S/S	Swelling, pain, loose teeth, paresthesia, ulceration	Painless Swelling over 37, 38 socket,
Location	Mandibular posterior area	Left posterior mandible
Radiographic feature	Radiolucency, never corticated Ragged border	1. Sunray spicules (hair-on- end) on the edentulous ridge of 37 2. Ill-defined, without corticated border, and with sparse calcification

	Metastatic tumor	Our case
Age	40-60	59 y/o
Gender	No tender	Female
S/S	<ol style="list-style-type: none"> <li>1. Pain</li> <li>2. Numbness</li> <li>3. Root resorption</li> <li>4. paresthesia</li> </ol>	Swelling over 37, 38 socket
Location	<ol style="list-style-type: none"> <li>1. Mandible&gt;maxilla</li> </ol>	Left posterior mandible
Radiographic feature	<ol style="list-style-type: none"> <li>1. Radiolucent</li> <li>2. Irregular</li> <li>3. Poor defined</li> <li>4. Not corticated</li> <li>5. Mouth-eaten</li> </ol>	<ol style="list-style-type: none"> <li>1. Sunray spicules (hair-on-end) on the edentulous ridge of 37</li> <li>2. Ill-defined, without corticated border, and with sparse calcification</li> </ol>

# Clinical impression

---

- Osteosarcoma, left posterior mandible



Thank you for your attention!!