

## 98年度十大病例報告

報告者: 陳靜怡 第五年住院醫師

指導者: 林立民 教授

陳玉昆 主任

王文岑 主任

# Case 1

- Name : 江吳○明
- Gender : Female
- Age : 54歲
- 主治醫師 : 謝天渝醫師
- 初診日期 : 98.7.13
- Chief complaint:  
Multiple masses over  
OMF region for 2~3  
years



# Present Illness

- **This 54 year old female patient has suffered from swelling masses over right face and bilateral pre-auricular area for 2~3 years. She ever went to 高榮 for help and the doctor referred her to our OPD for further examination and treatment.**

# Past History And Personal Habit

- **Past Medical history**

**DM , HTN ( medication control for 8 years)**

**Hospitalization: thrombocytopenia**

- **Drug Allergy: Nil**

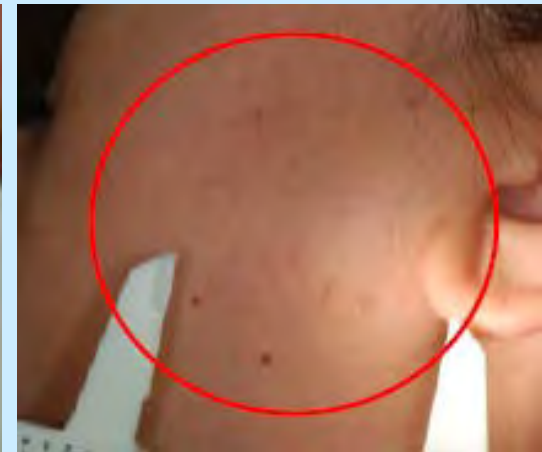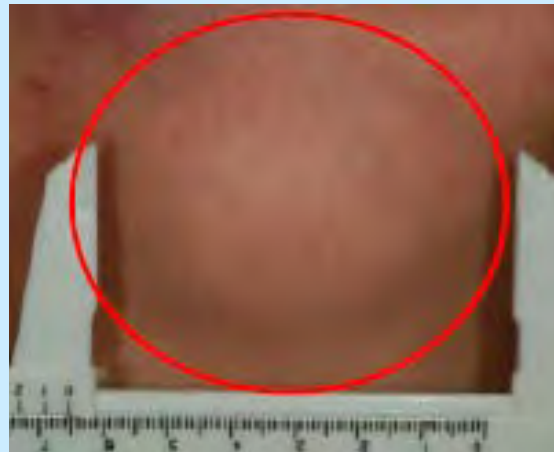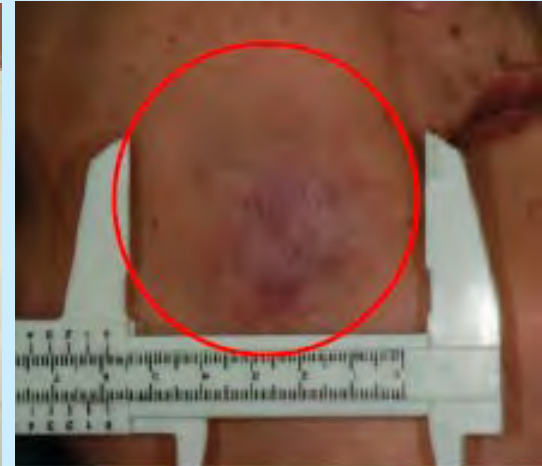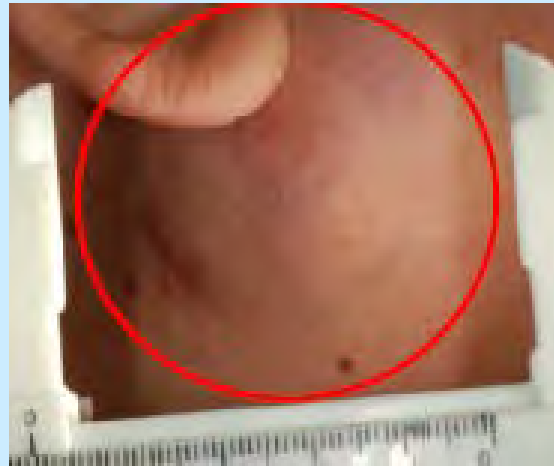- **Past dental history: NP**

- **Personal habits: A(-), B(-), C(-)**

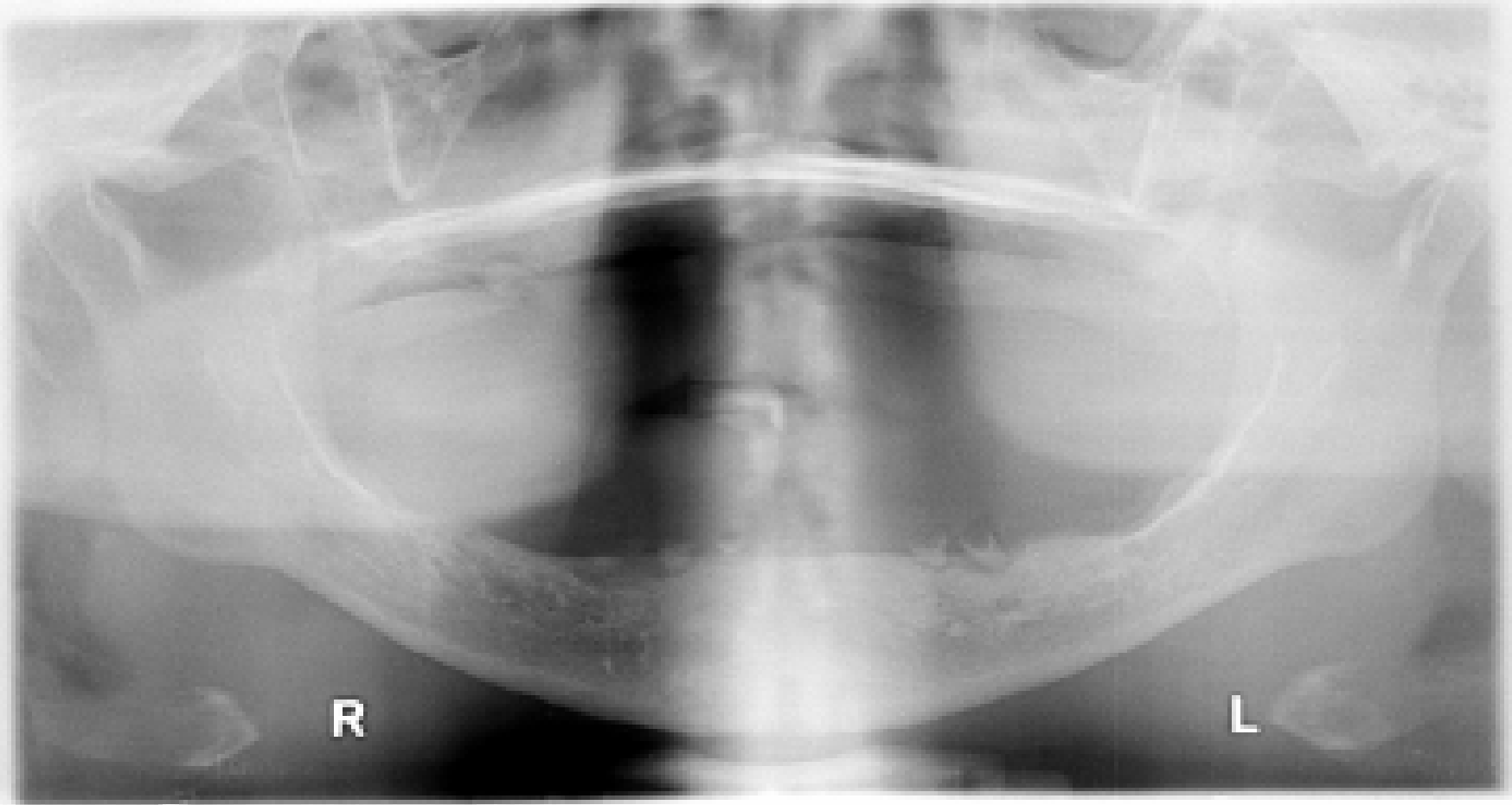


# Extra-Oral Findings

- Firm masses over right buccal, bil. preauricular and right submandibular , about 6.5x6.0 cm in max. dimension
- Fixed, firm, Painless, **Telangiectasia(+)**

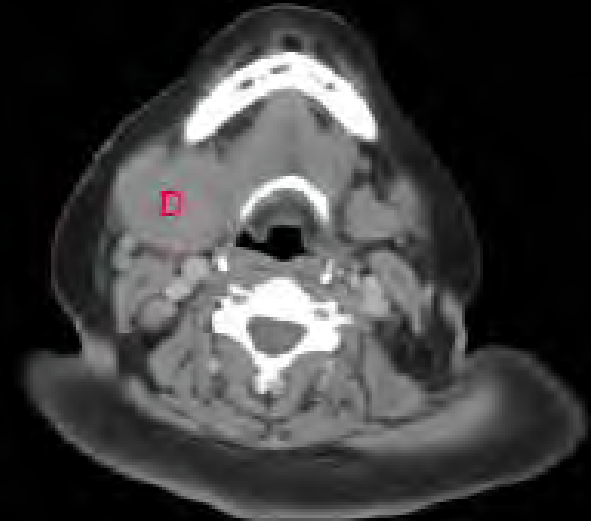
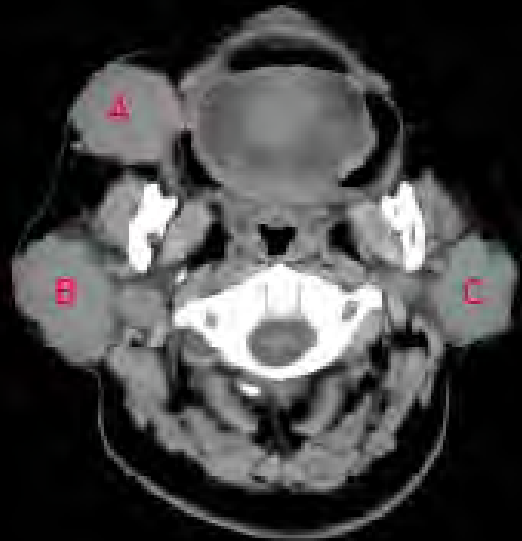
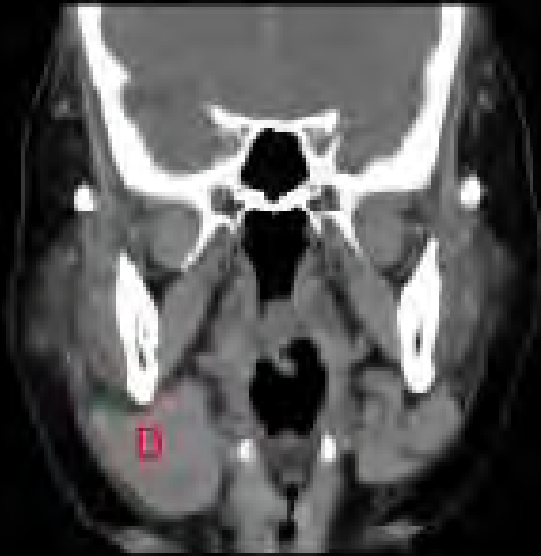

# Panoramic Film

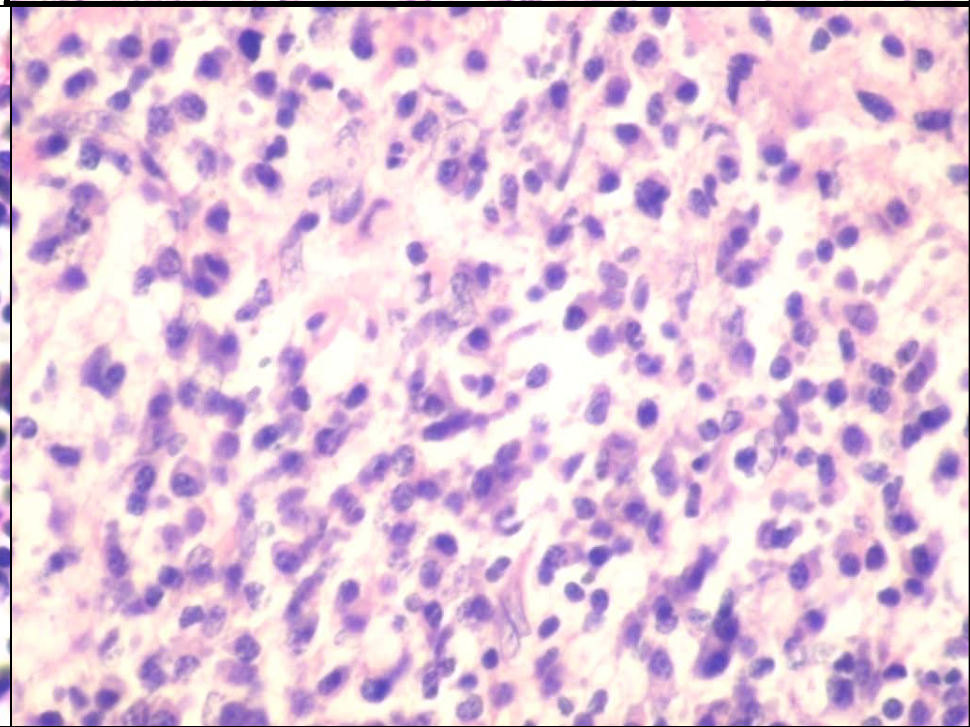
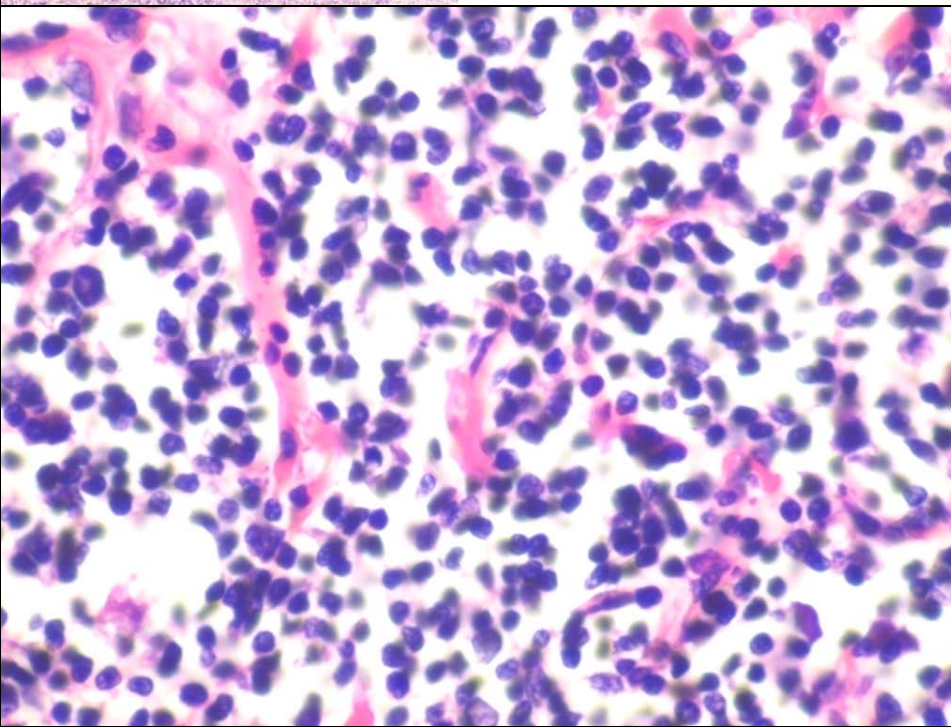
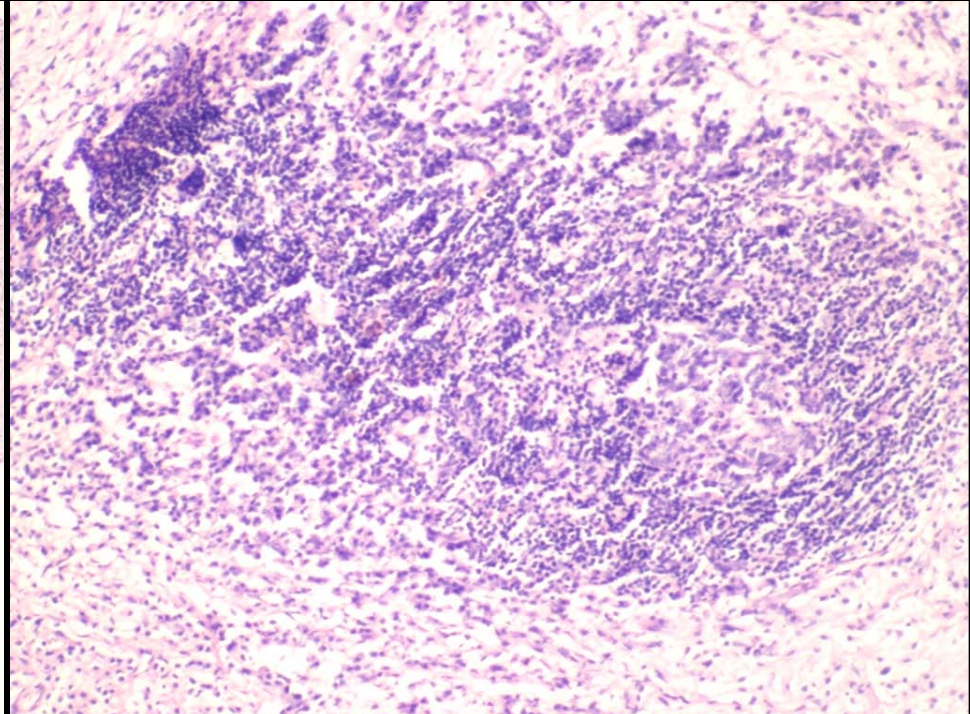
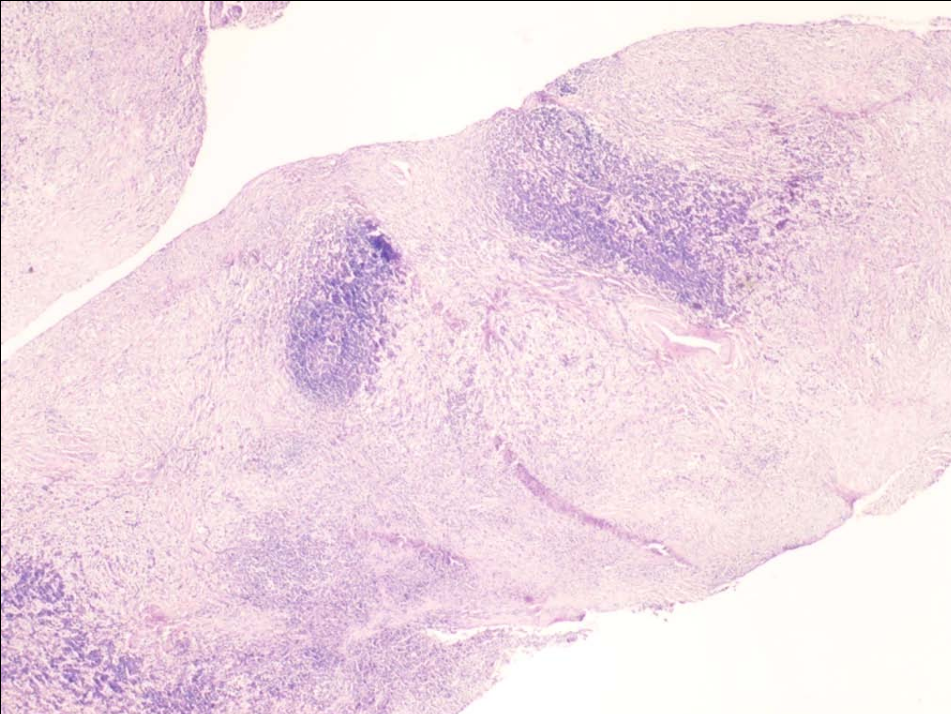


# CT Findings

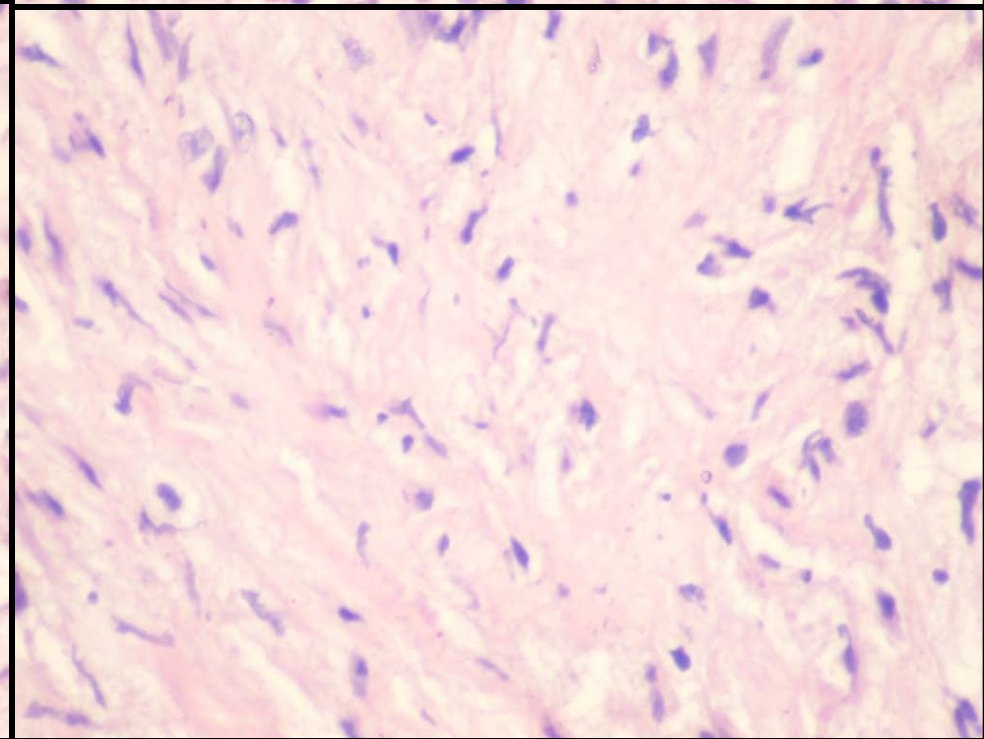
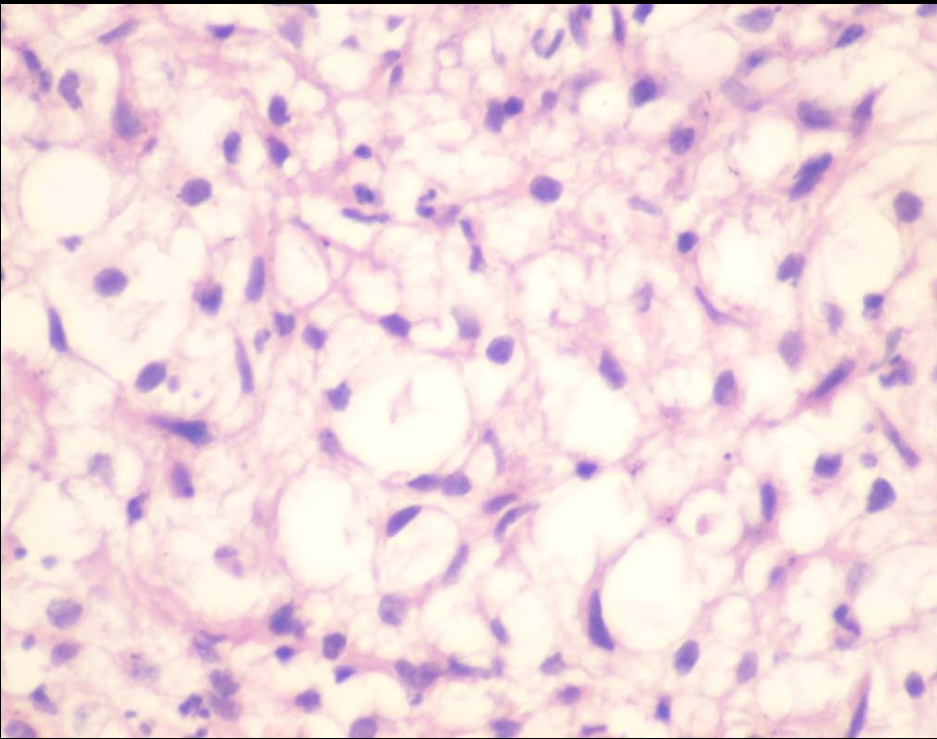
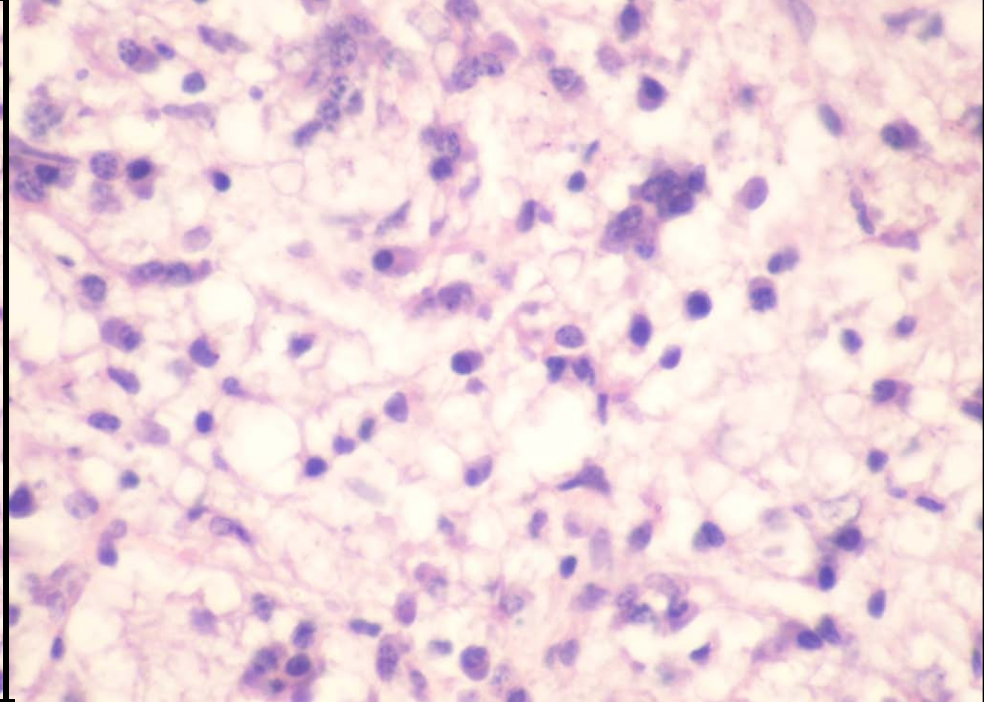
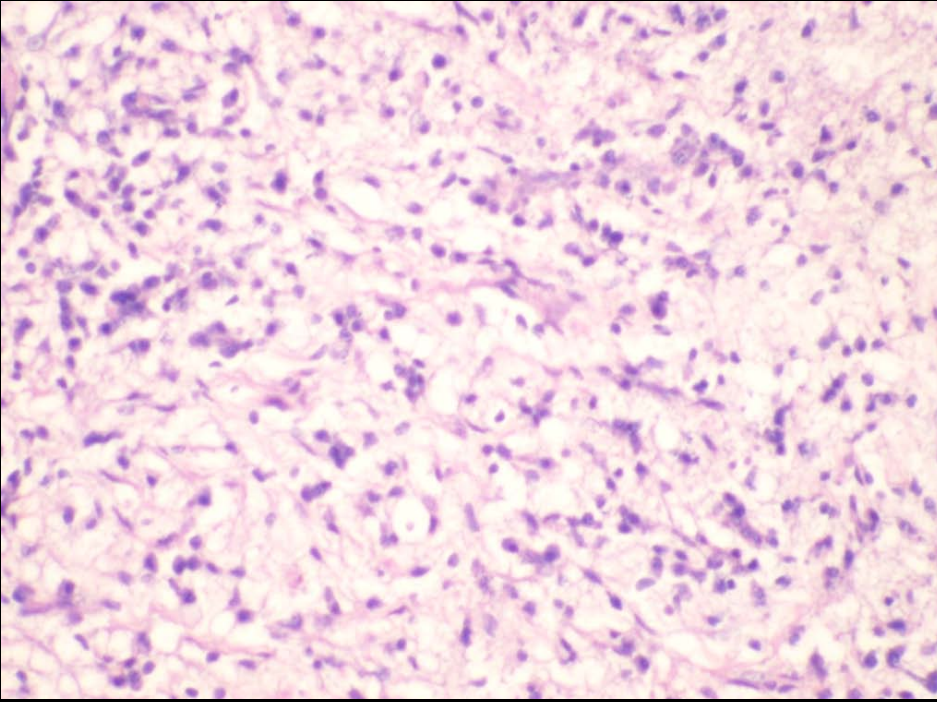
**Soft tissue density masses over right buccal space, bil. Parotid gland, and bil. Submandibular gland, about 6x5 in max. dimension**











# Summary of Microscopic Features

- **Granulomatous inflammation**
- **Marked infiltration of lymphocytes and plasma cells**
- **Lymphoid aggregation**
- **Large amount of xanthomatized histiocytes (foamy cytoplasm)**
- **Hyalinization and fibrosis**

# Differential Diagnosis

- Granulomatous lesions
  - **Xanthogranuloma**  
xanthomatized histiocyte, lymphoid follicles
  - Tuberculosis, Leprosy
  - Sarcoidosis
- Histiocytic lesion – Langerhan cell histiocytosis
- Benign lymphoepithelial lesions
  - Sjogren syndrome, Mikulicz's diseases  
epi-myoepithelial islands

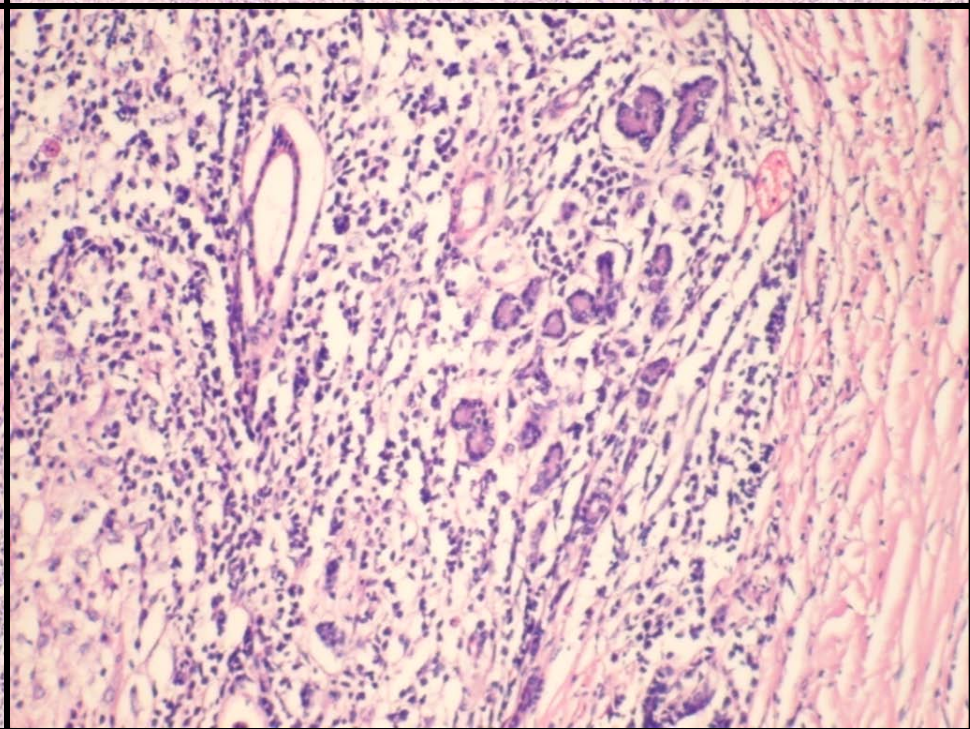
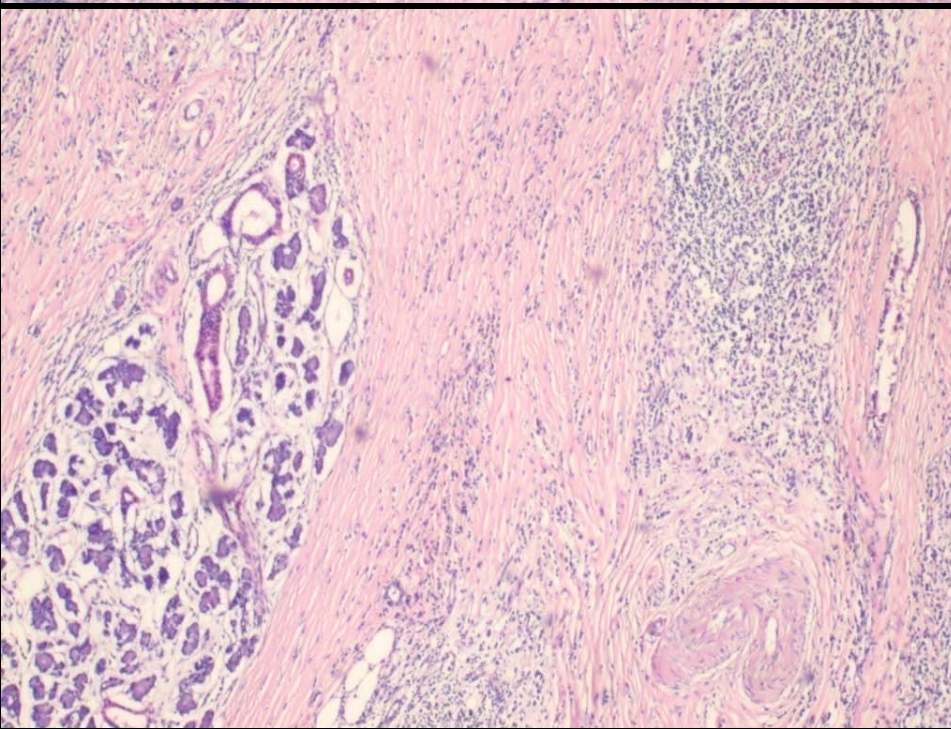
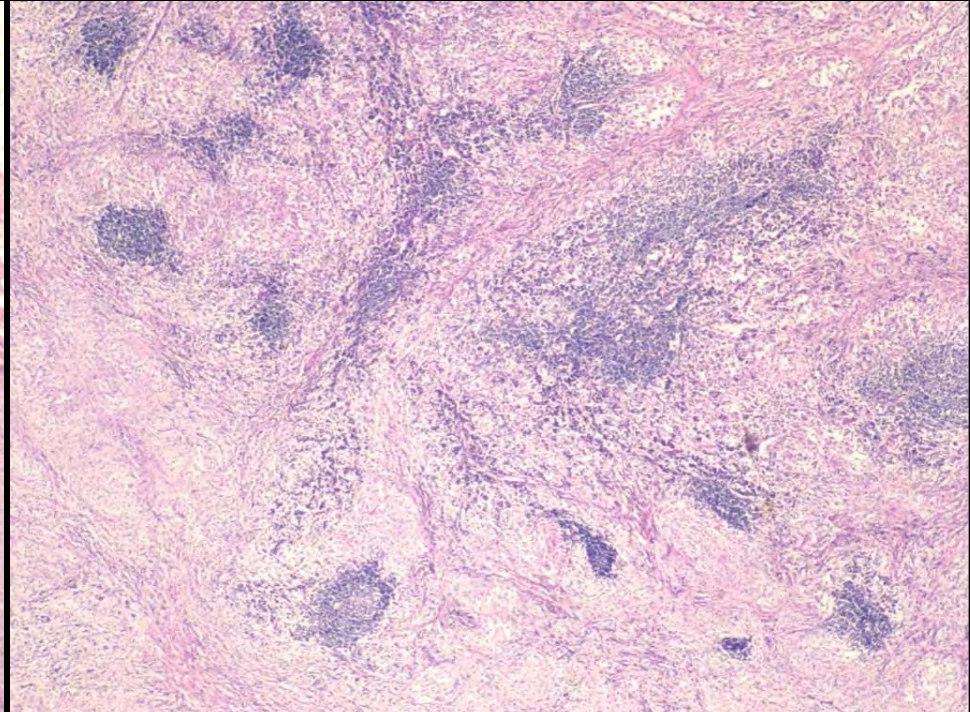
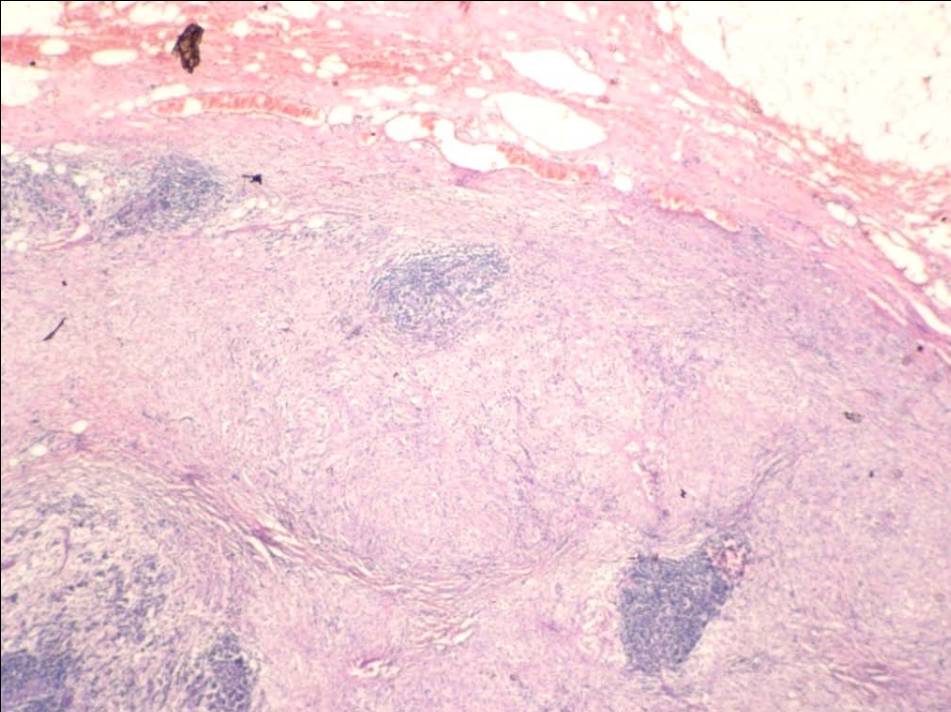
# **Histopathological Report**

- **Xanthogranuloma**

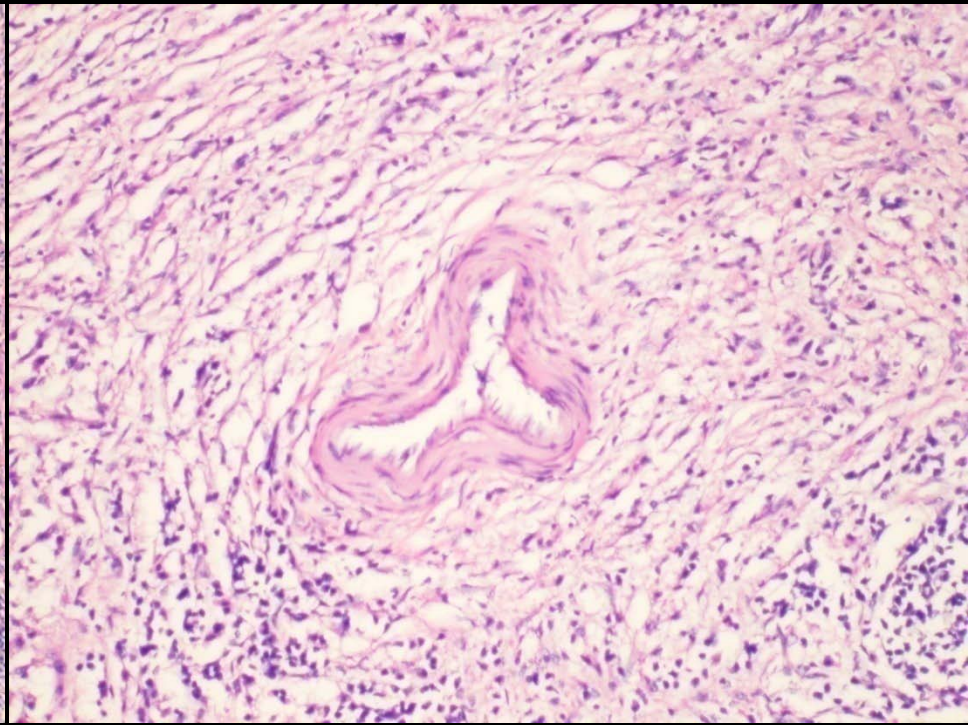
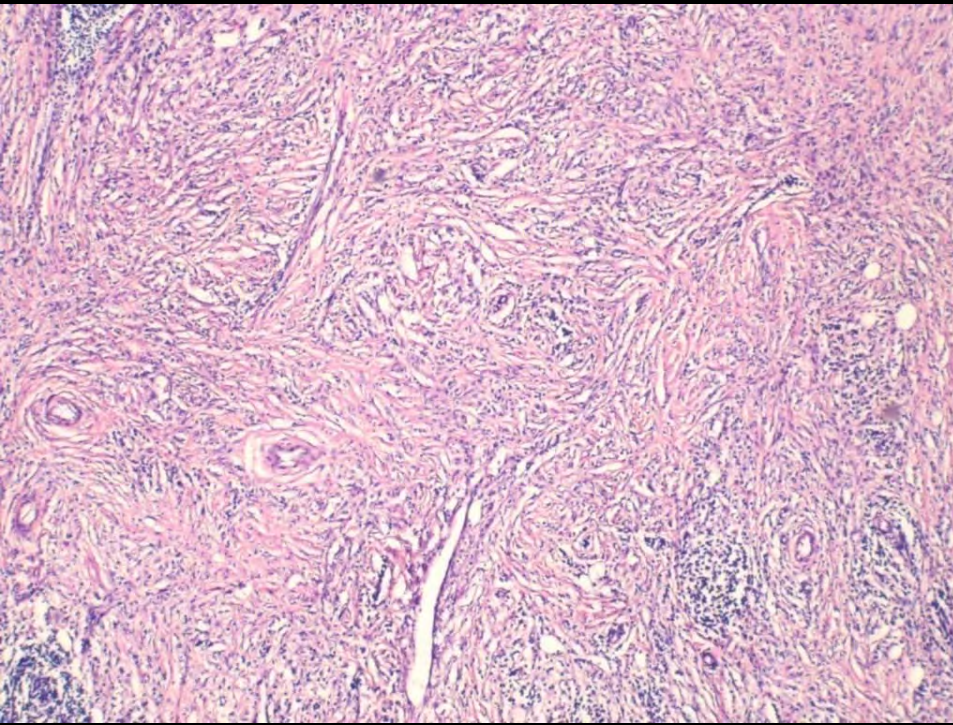
**Right parotid gland, Incision**

**KMUOP-09-1597**

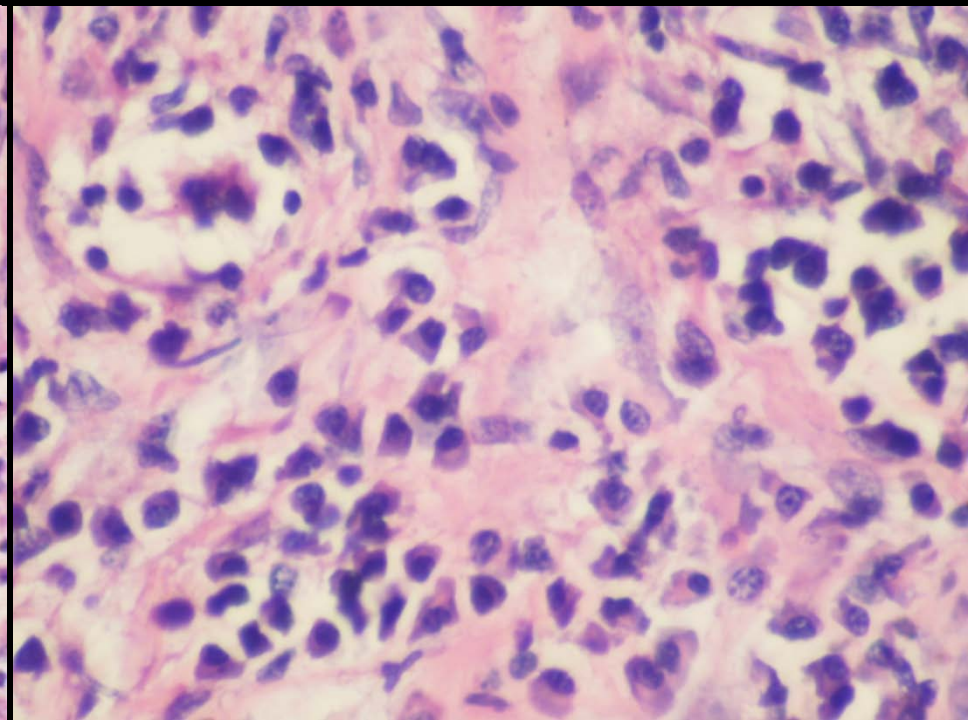
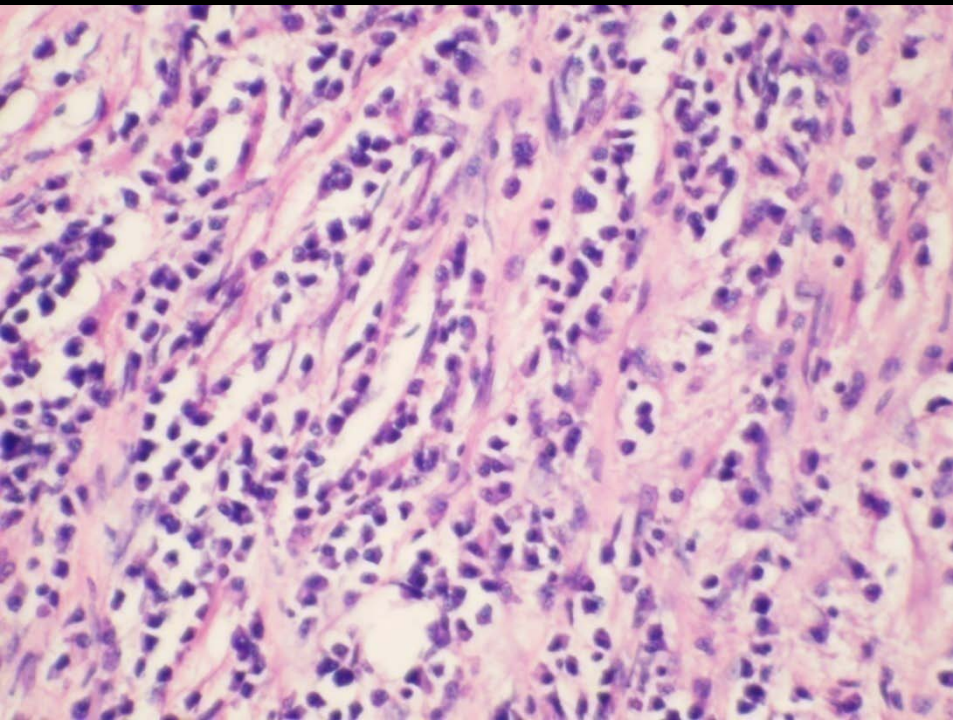
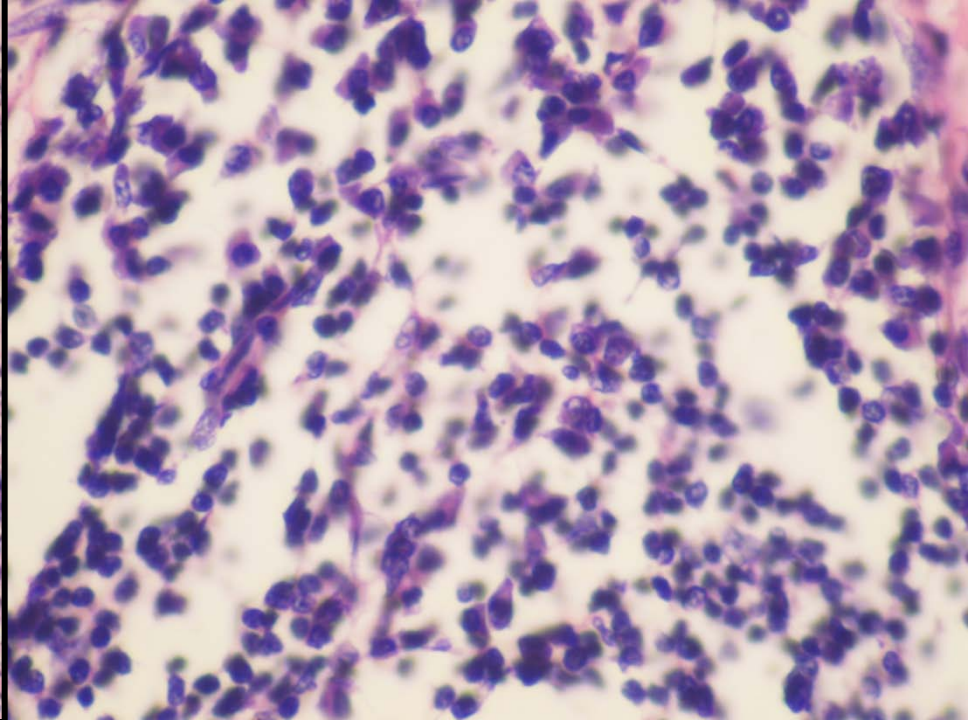
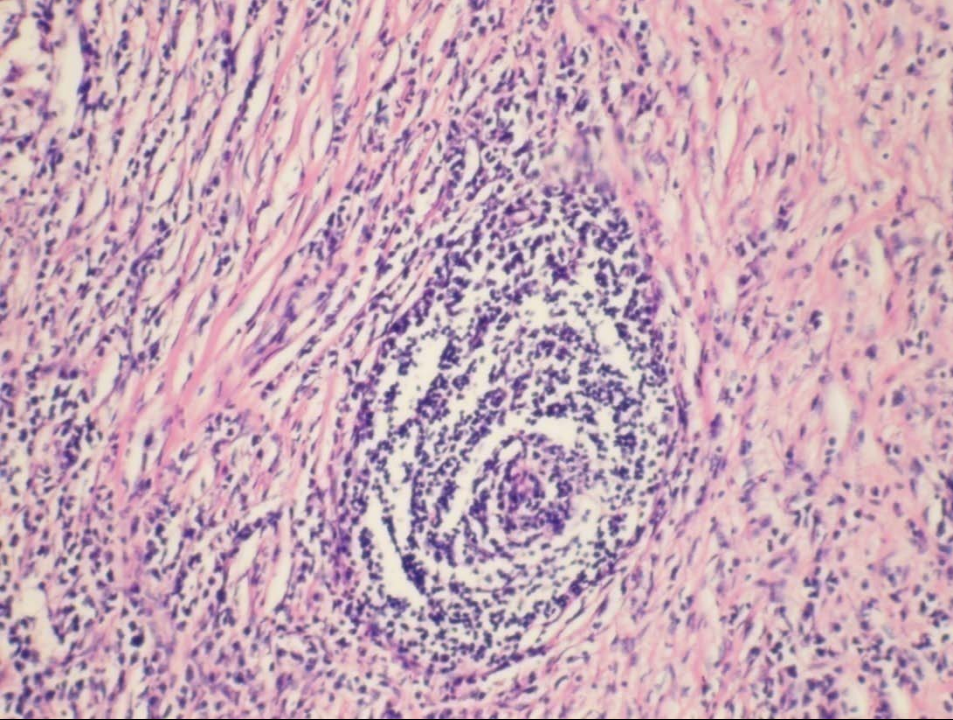




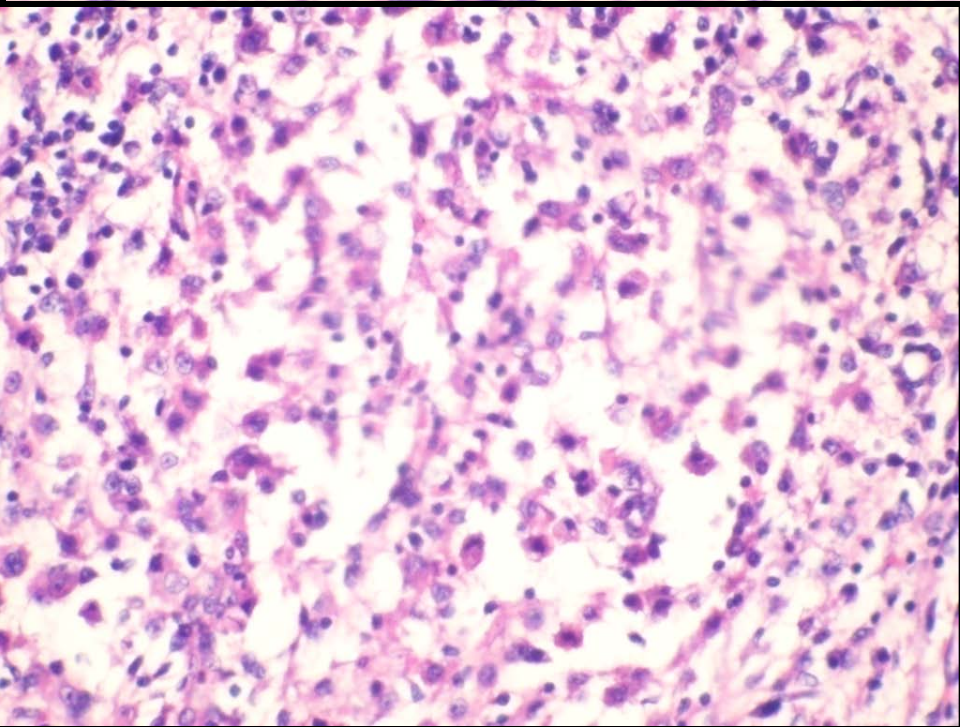
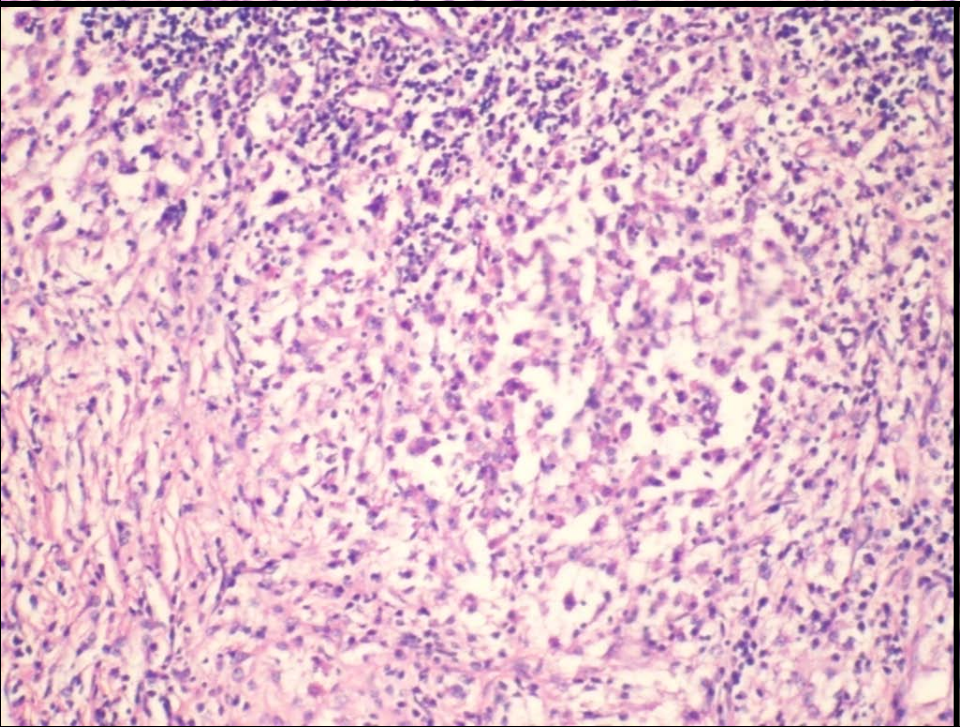
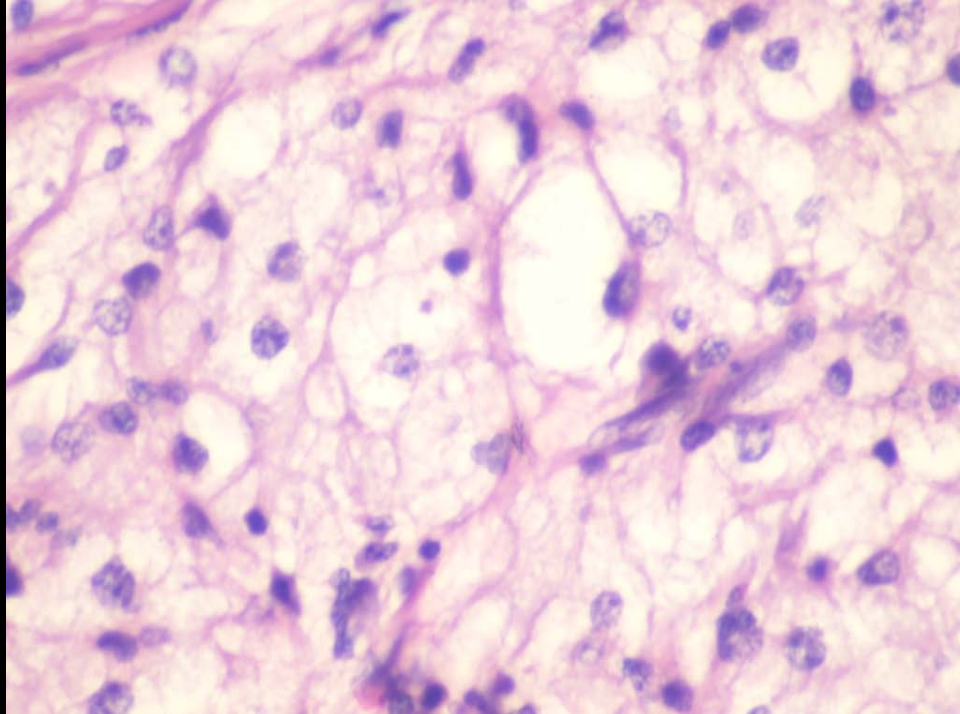
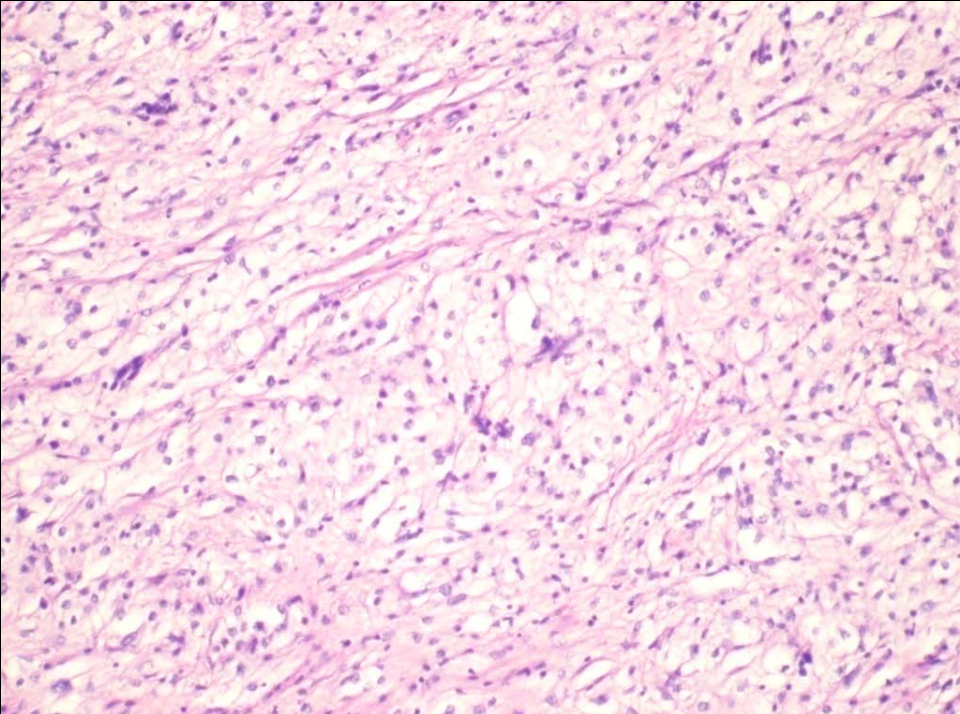




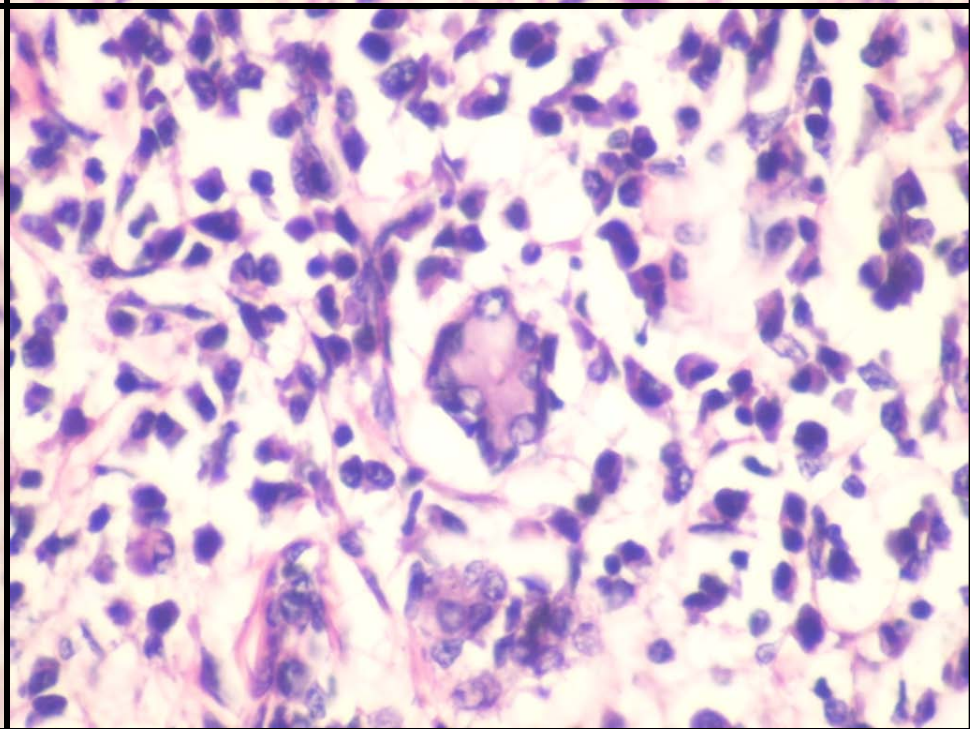
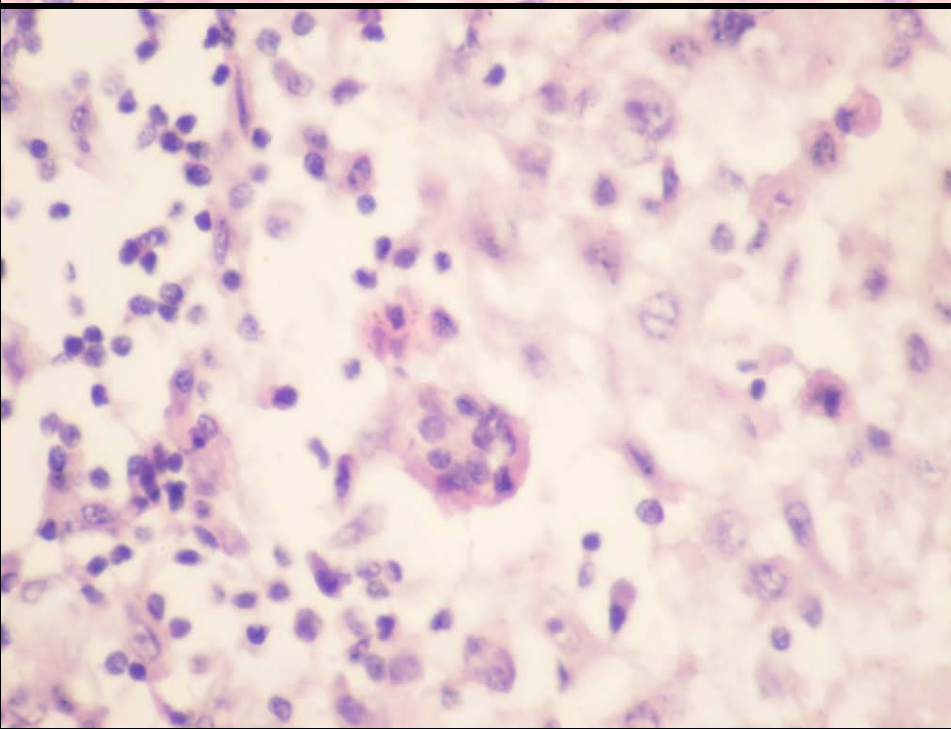
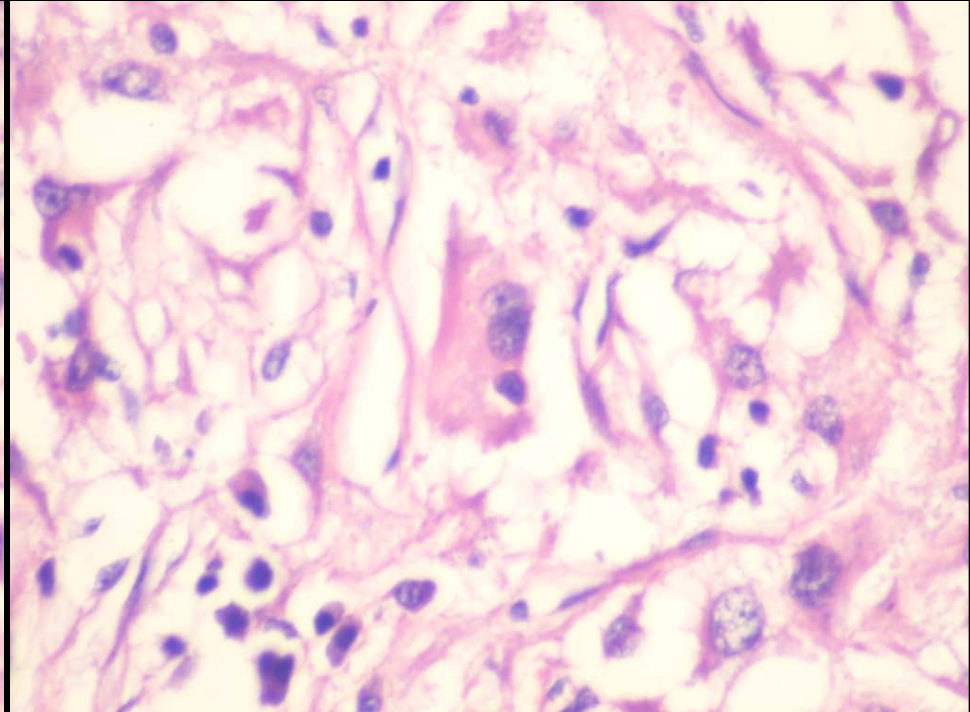
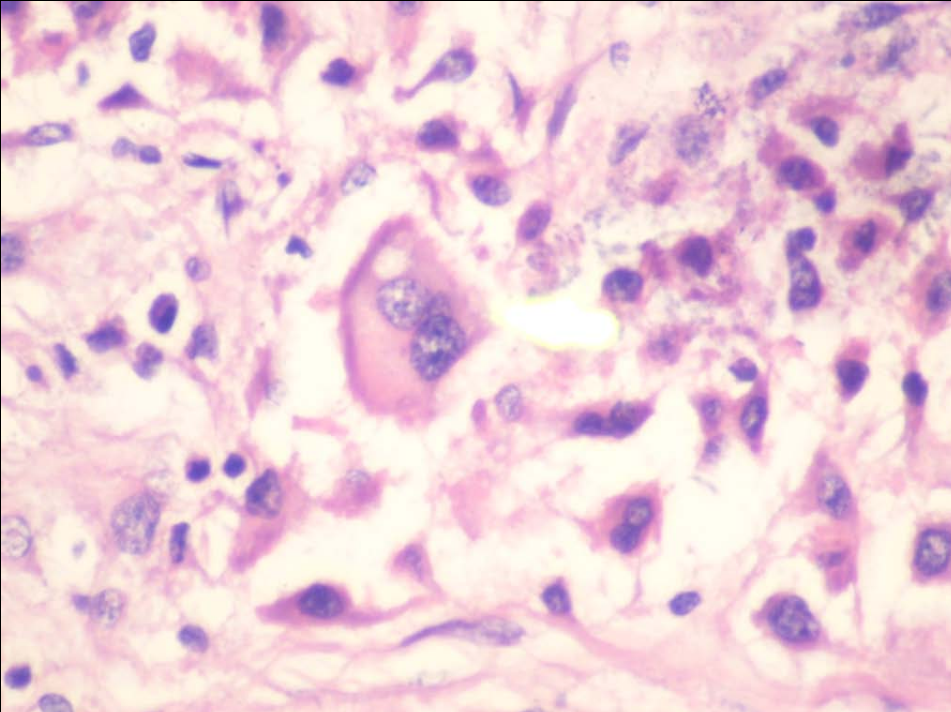












# Special Stains

- **Histochemical stain**

  - PAS – mucin, polysaccharide**

- **Immunohistochemical stains**

  - CD68 – histiocyte**

  - CD1a – Langerhan cell**

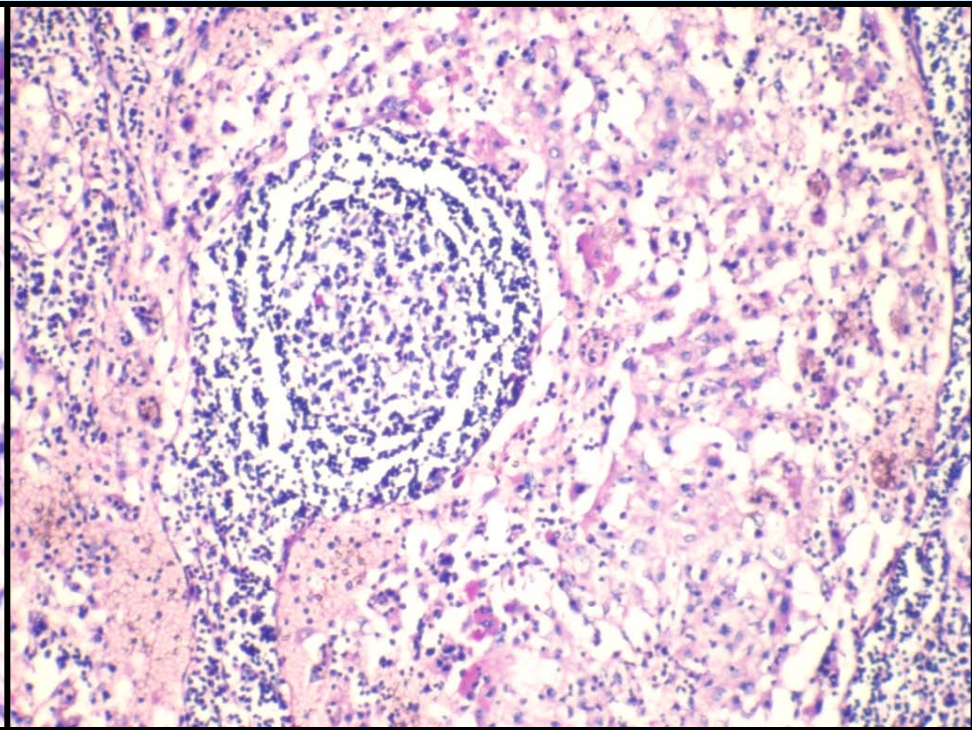
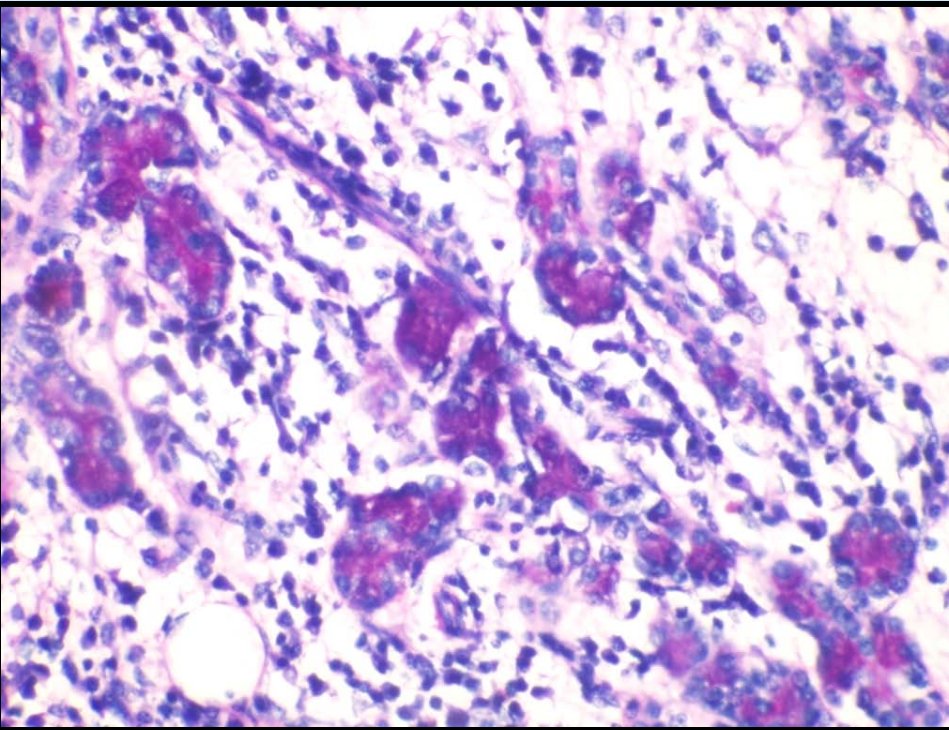
  - S-100 – Langerhan cell, myoepithelial cell**

  - T-cell – T lymphocyte**

  - B-cell – B lymphocyte**

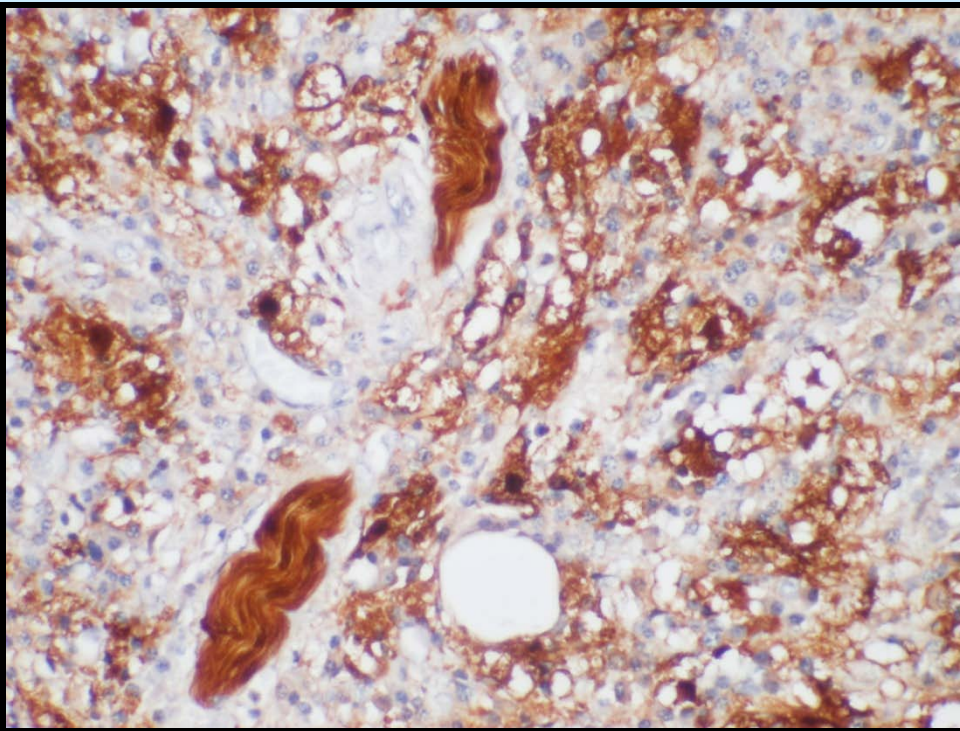
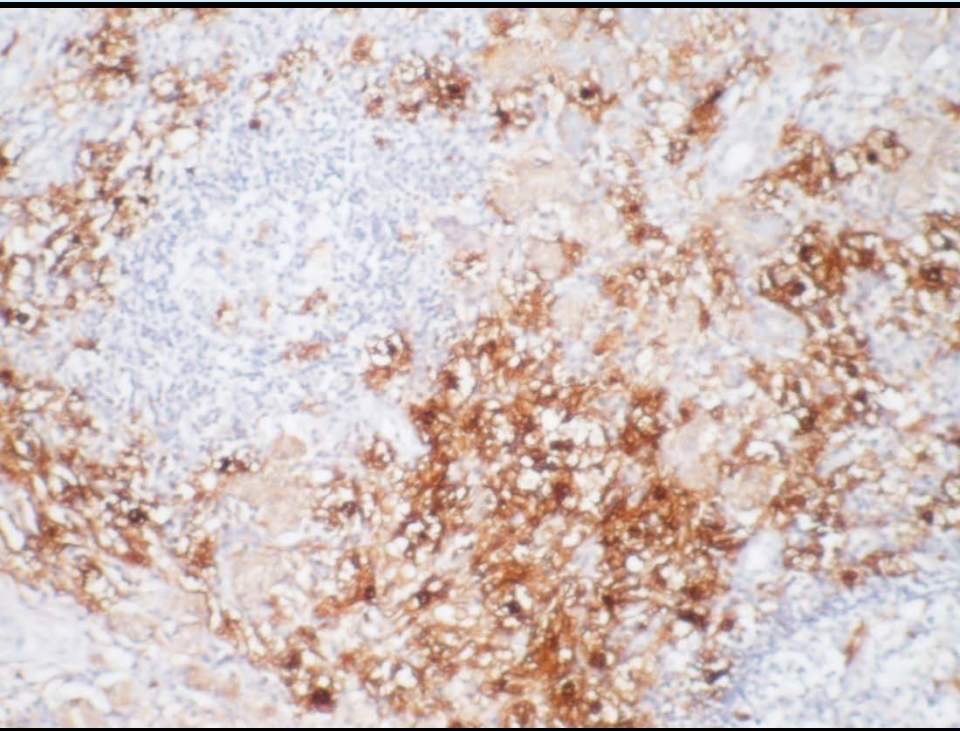


**PAS(-)**



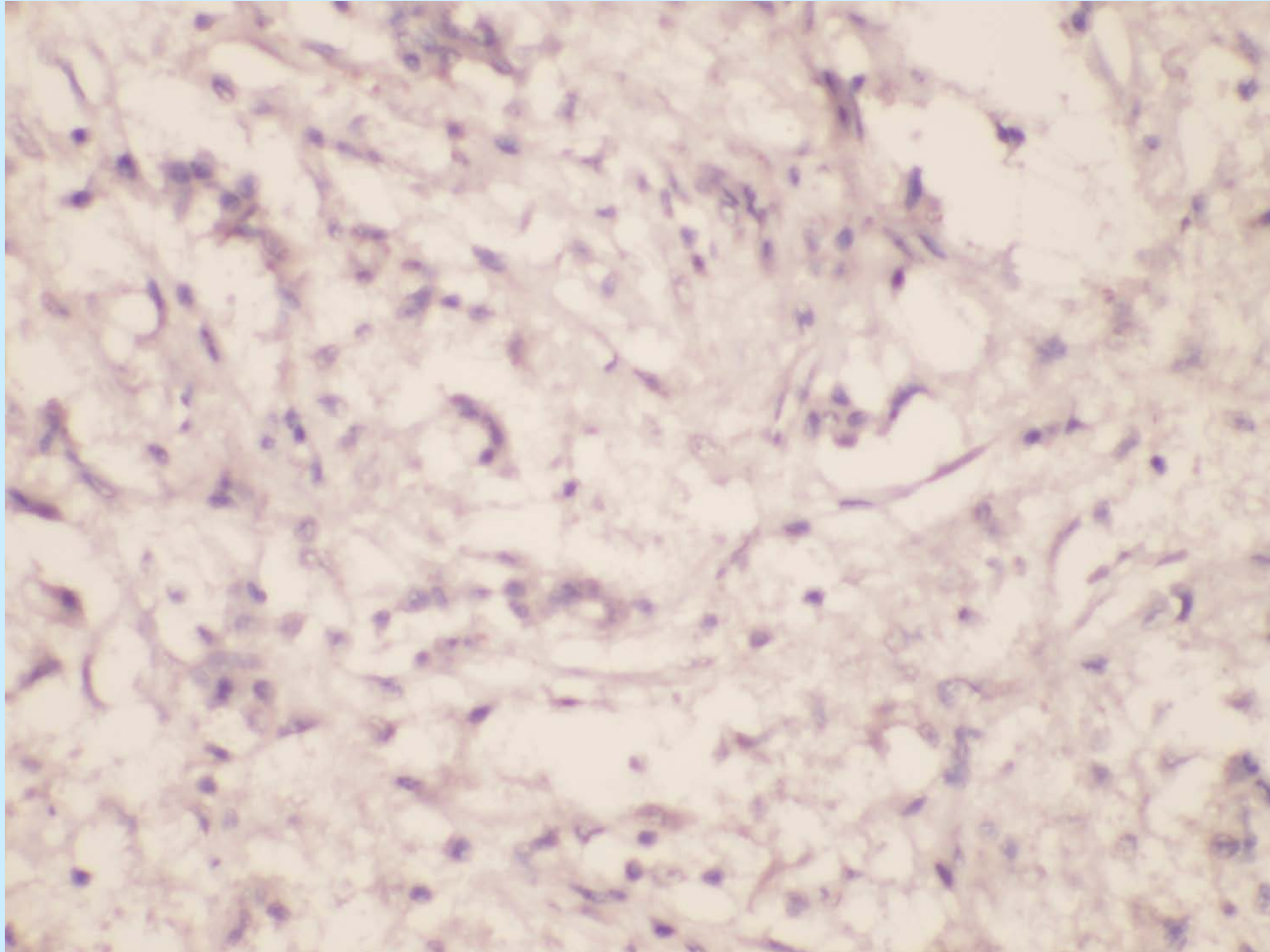


# S-100 (+)

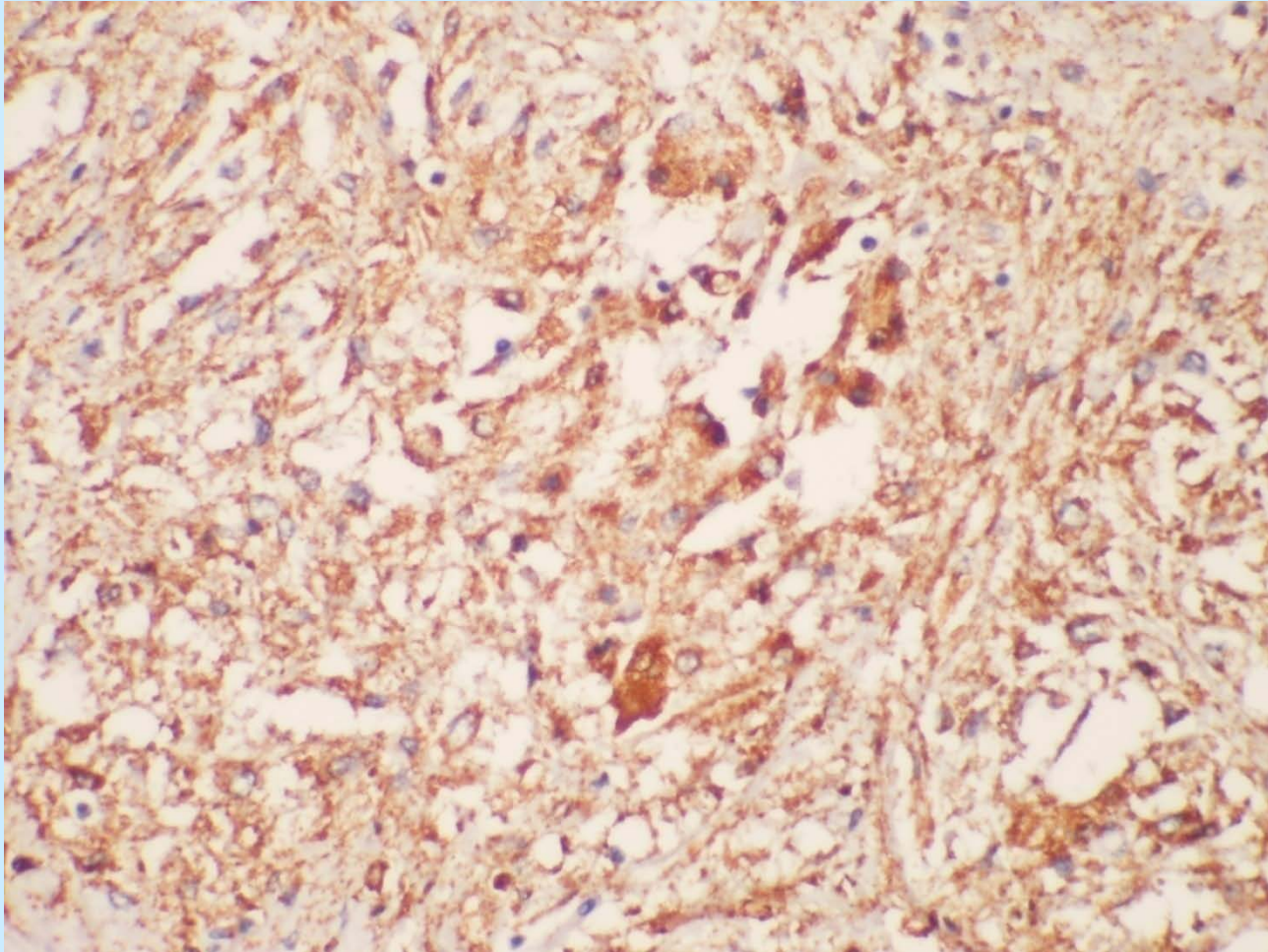




**CD1a(-)**

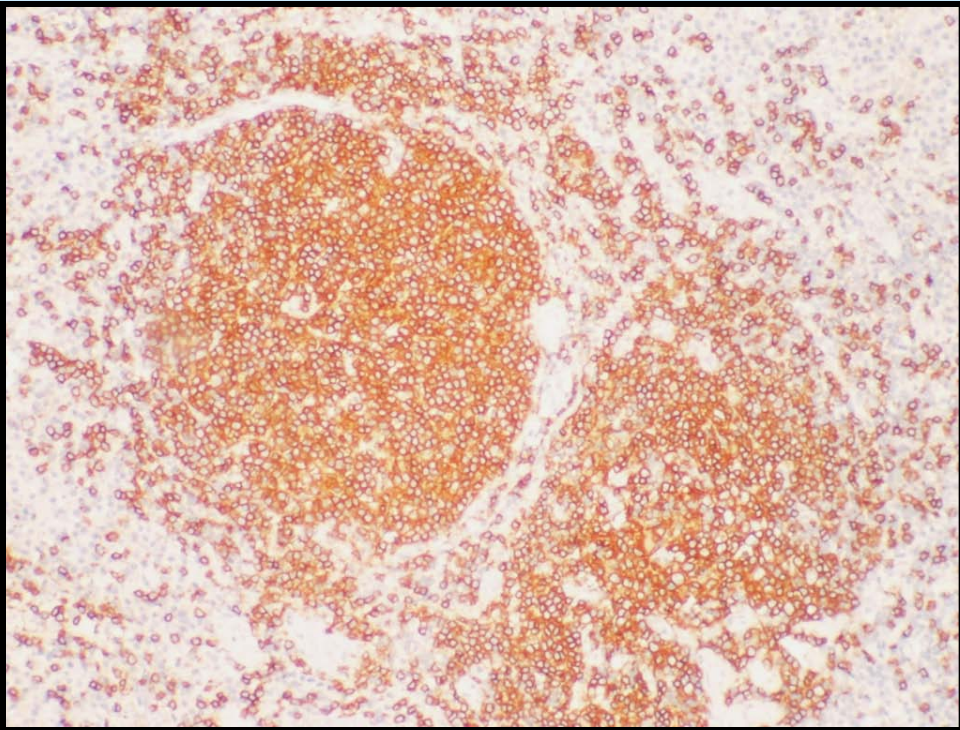
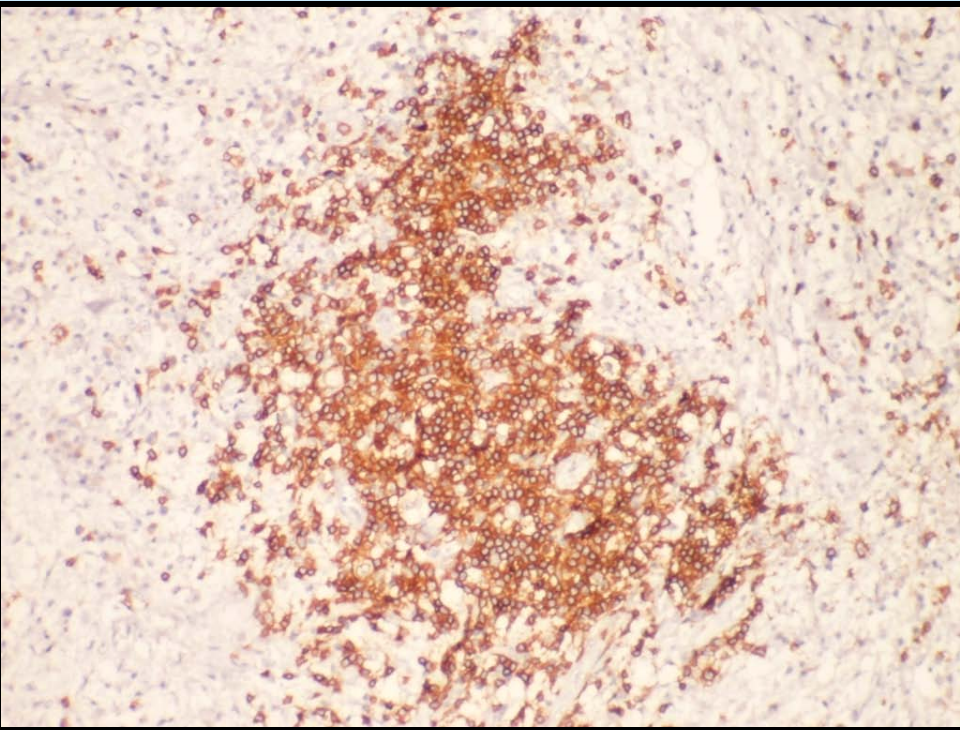


**CD68(+)**





# T-cell (+) and B-cell (+)



# **Histopathological Report**

- **Necrobiotic xanthogranuloma**

**Right parotid gland, Excision**

**Right submandibular gland, Excision**

**Right buccal space, Excision**

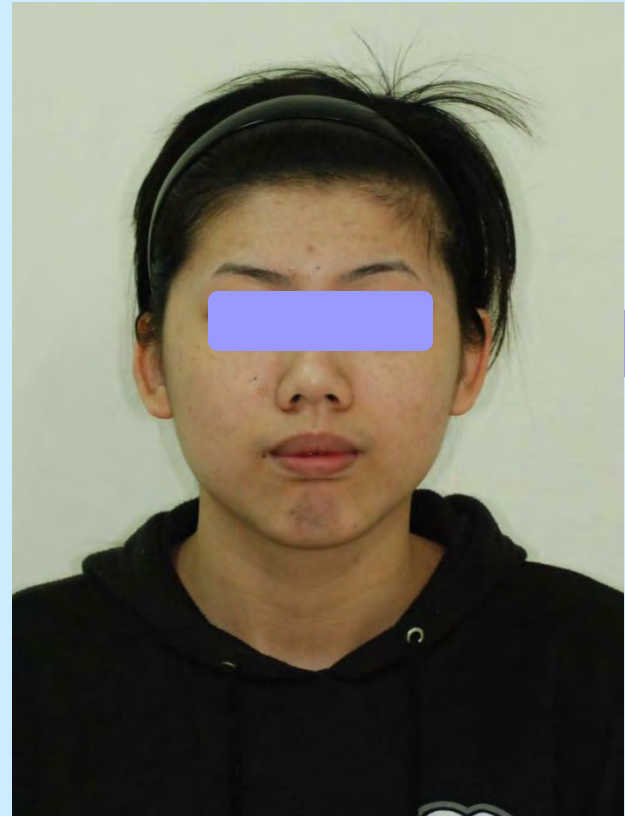**KMUOP-09-1899**

# Necrobiotic Xanthogranuloma

- A rare chronic granulomatous lesion, about 100 cases in literatures, class II histiocytic disorder
- Multiple involvement of skin, most common site – periorbital area (80-90%), may involve extracutaneous sites, **parotid gland: 1 case**
- Skin lesion – multiple indurate yellow-red plaques or nodules, slowly growing, **telangiectasia**, ulceration, scarring
- Associated with lymphoproliferative disorder
  - Paraproteinemia (80%), multiple myeloma (10%),

# Case 2

- **Name:** 張 O 媛
- **Gender:** Female
- **Age:** 19 y/o
- **初診日期:** 98.02.03
- **Chief complaint:**  
A multilocular R/L  
lesion over left condyle  
head



# Present Illness

- This 19 y/o female was a patient of our ortho and OS department. During Ortho-OS combined meeting, a multilocular R/L lesion over left condyle head was found. Then she was referred to Dr. 黃逸岳 for further treatment.

# Past History And Personal Habit

- **Past Medical history**

NP

- **Drug Allergy: Nil**

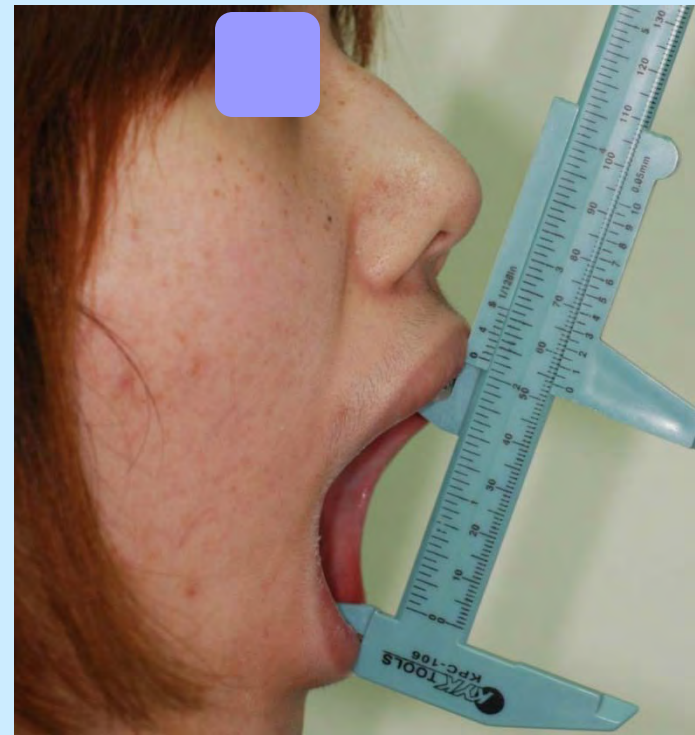- **Past dental history: ortho treatment**

- **Personal habits: A(-), B(-), C(-), other habit (-)**

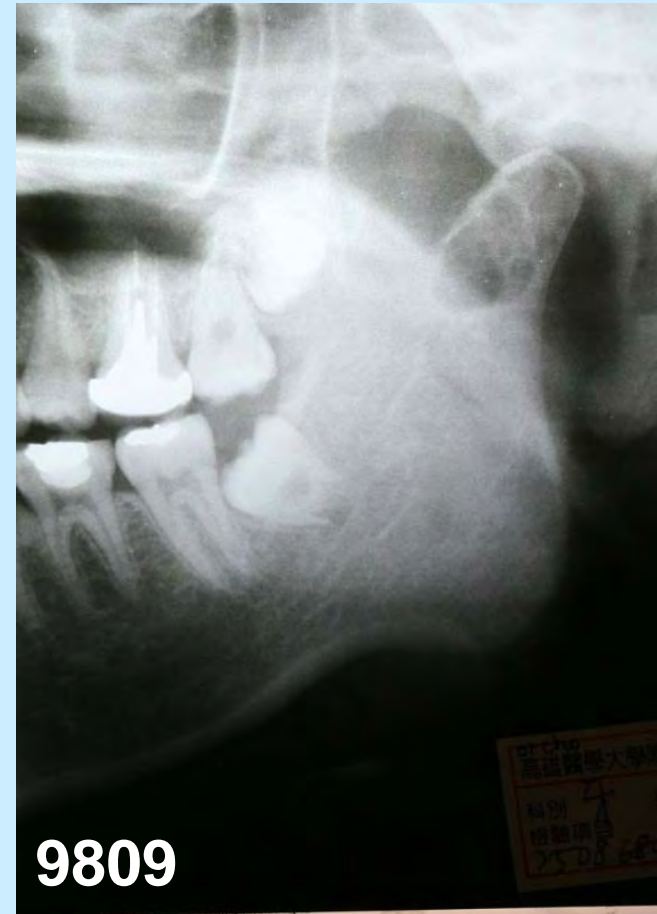
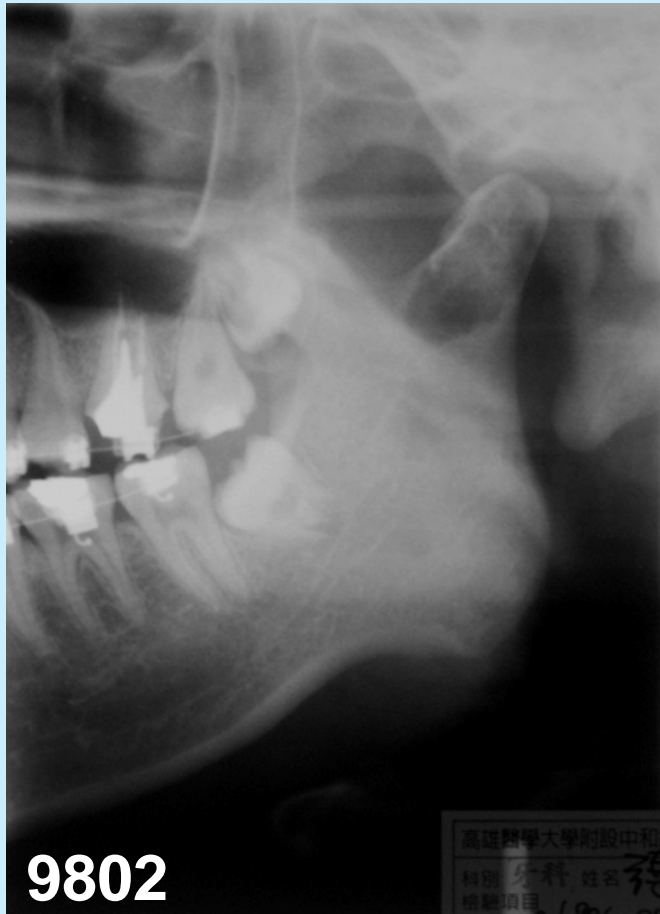
# Extra-Oral Findings

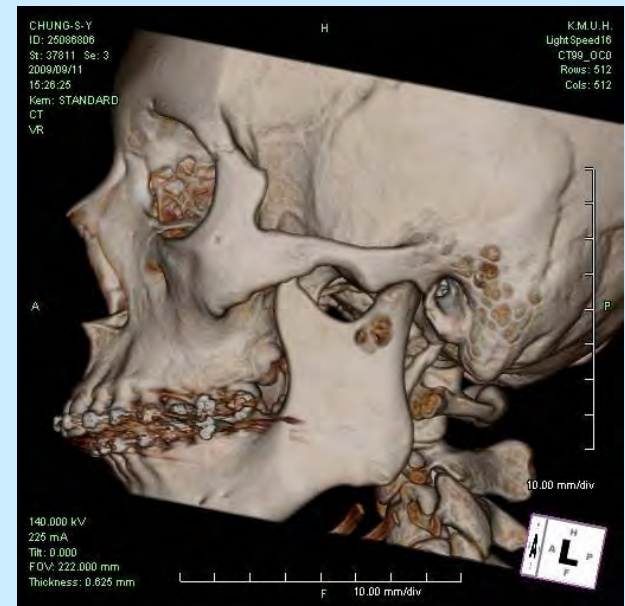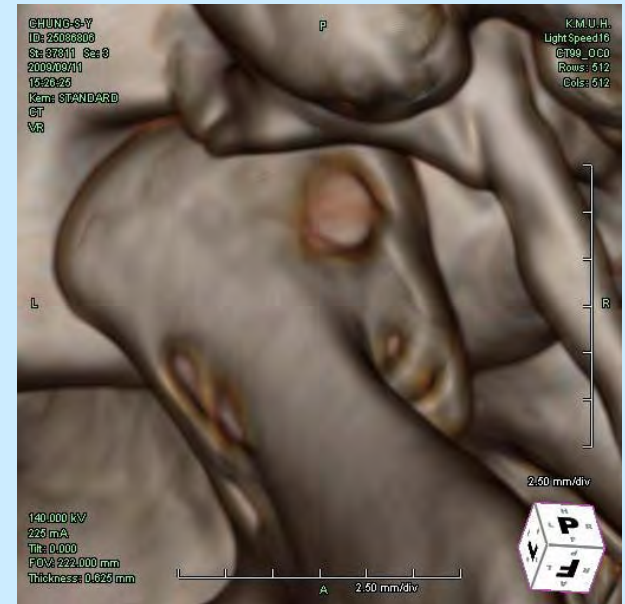
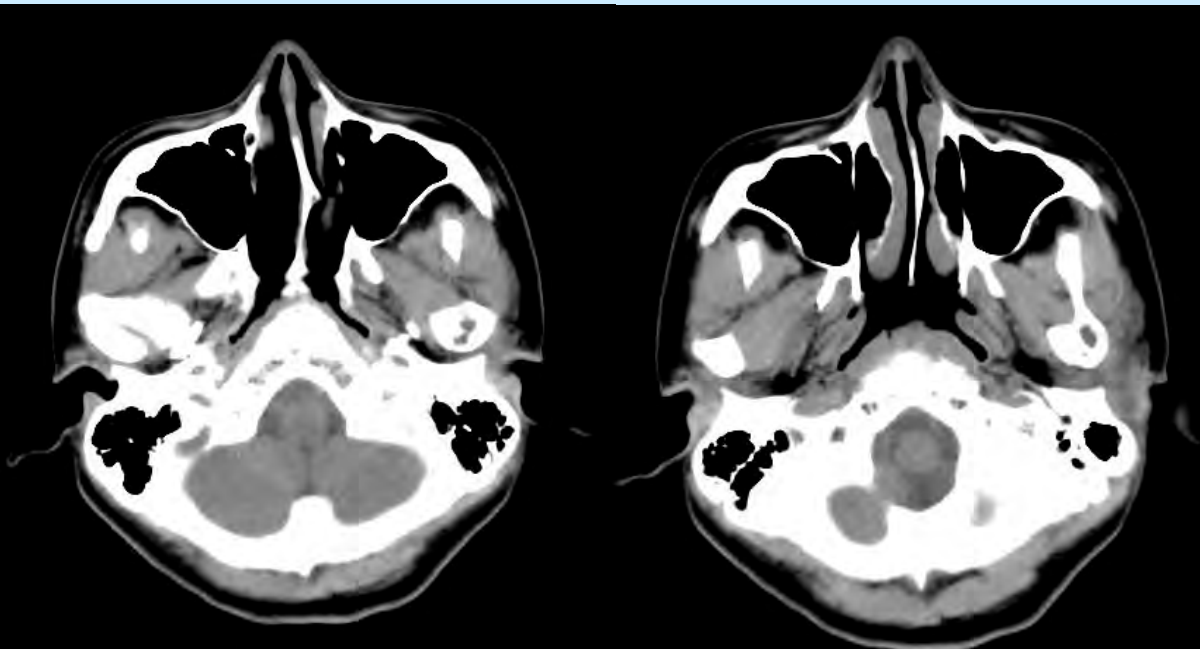
- MMO = 52 mm
- Clicking (+) when opening



# Panoramic film



# CT Scan

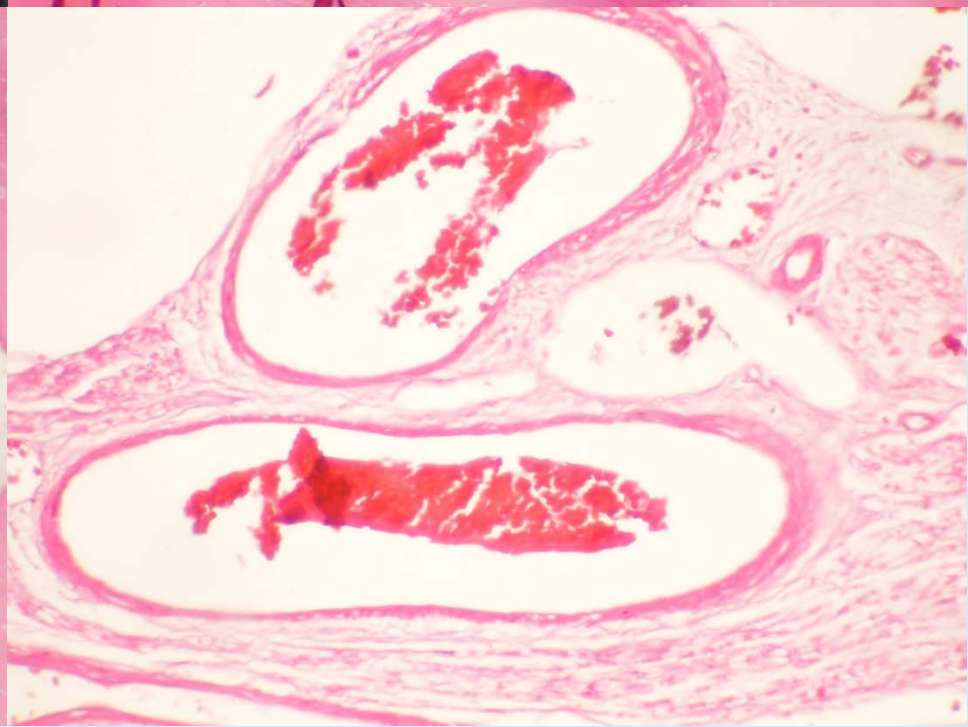
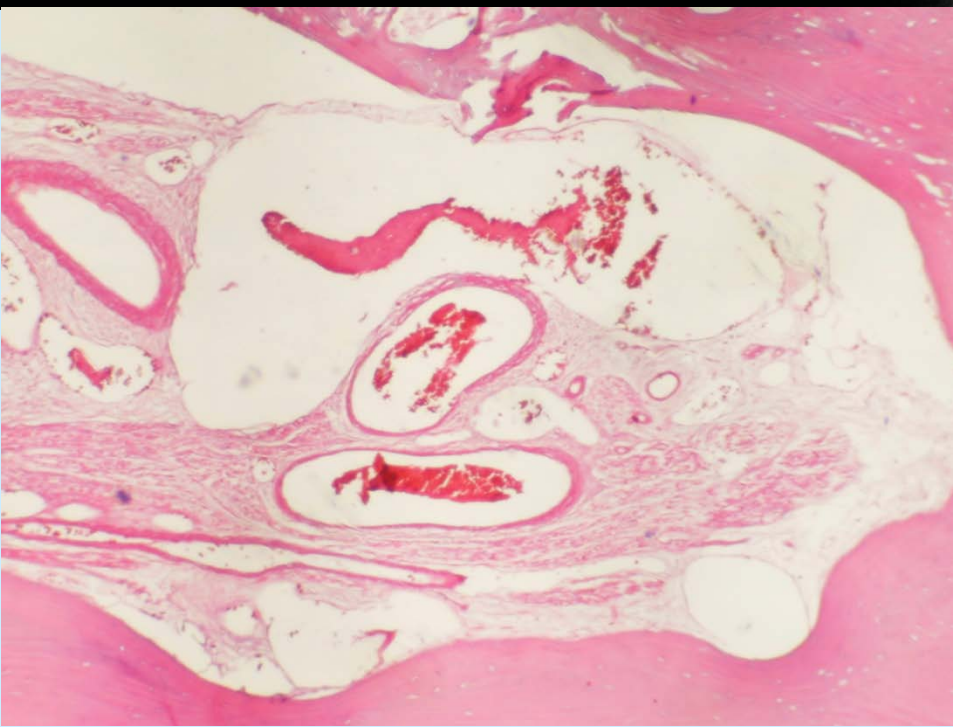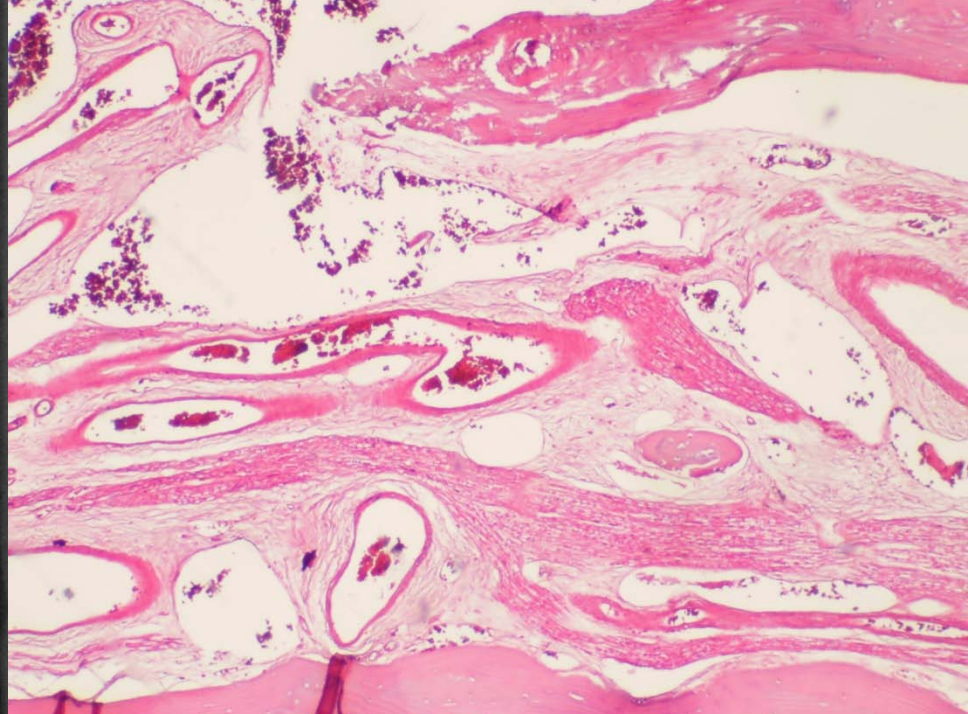
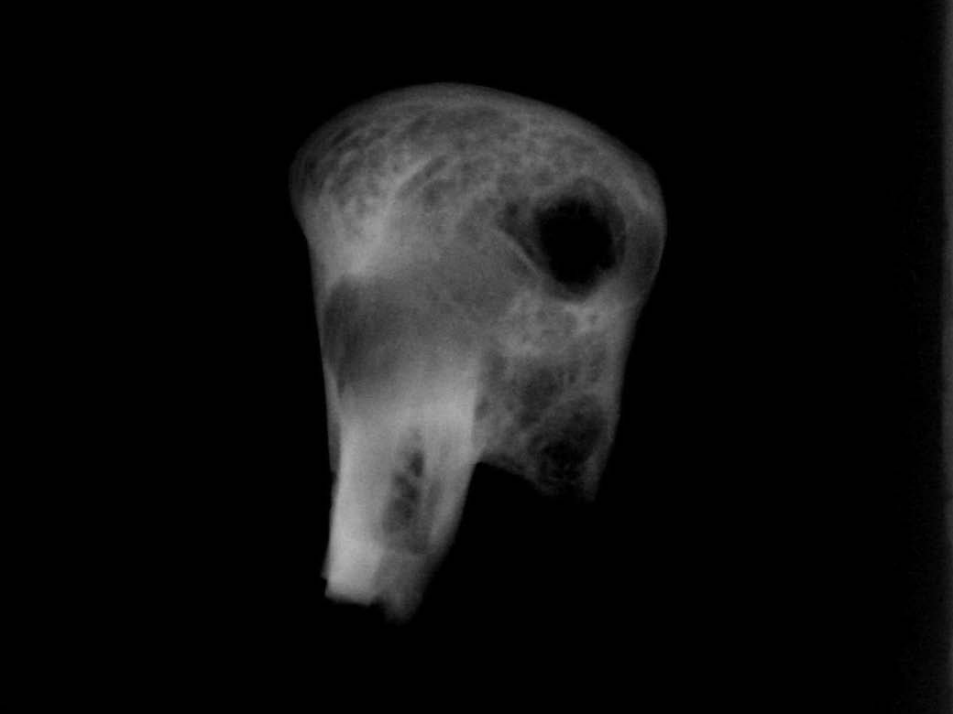




# **Clinical Impression**

- **Multilocular osteolytic lesion over left condyle head**





# HP Report

- **Cavernous hemangioma over left condyle head**

# Case 3

- **Name: 張 O 慈**
- **Gender: Female**
- **Age: 17 y/o**
- **主治醫師: 陳俊明醫師**
- **初診日期: 98.05.04**
- **Chief complaint:**  
**A mass over teeth 14, 15 palatal side for 6 months**

# Present Illness

- **This 17 y/o female suffered from the above episode for at least 6 months. She found that her mass was larger and larger in these days. She went to LDC for help recently because she felt painful over the right upper posterior area. And then, the dentist suggested her to go to the medical center for further evaluation. So she came to our OPD for examination**

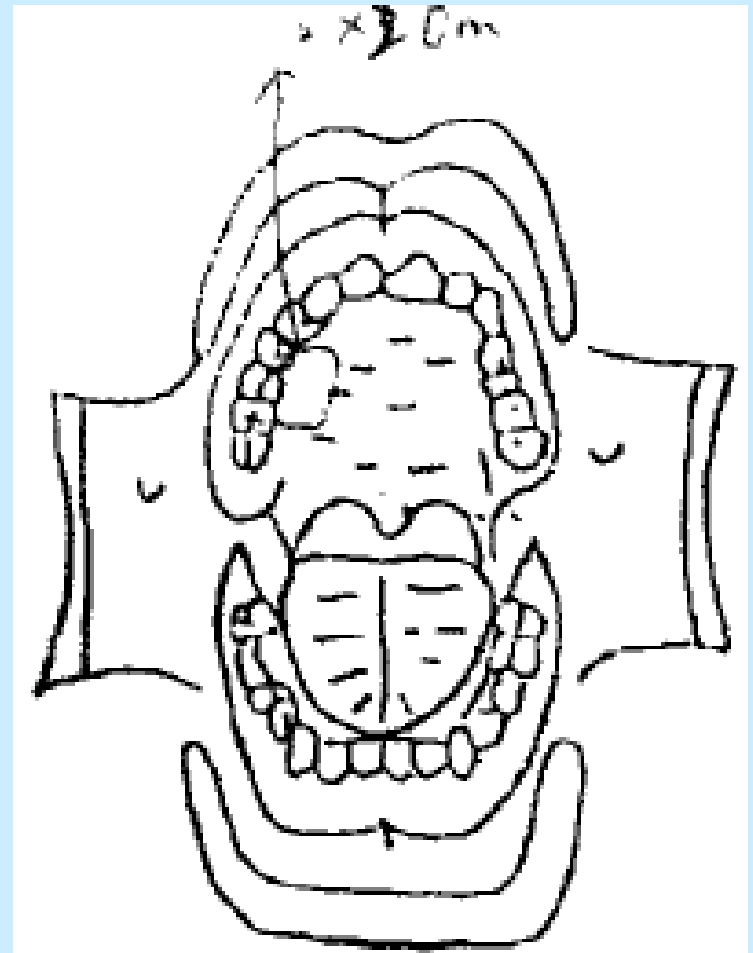


# Past History And Personal Habit

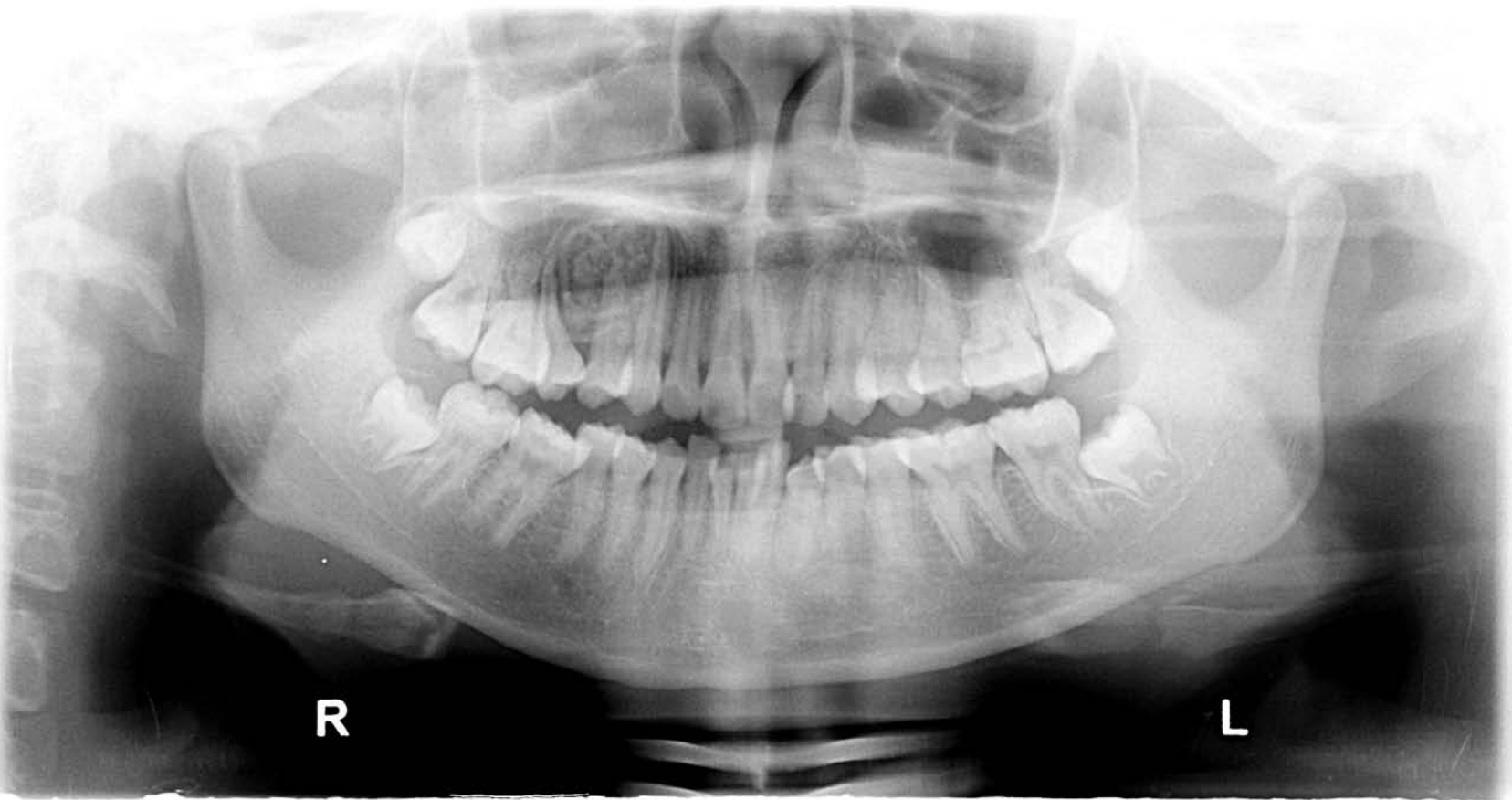- **Past Medical history**  
NP
- **Drug Allergy: Nil**
- **Past dental history: NP**
- **Personal habits: A(-), B(-), C(-), other habit(-)**

# Intra-Oral Findings

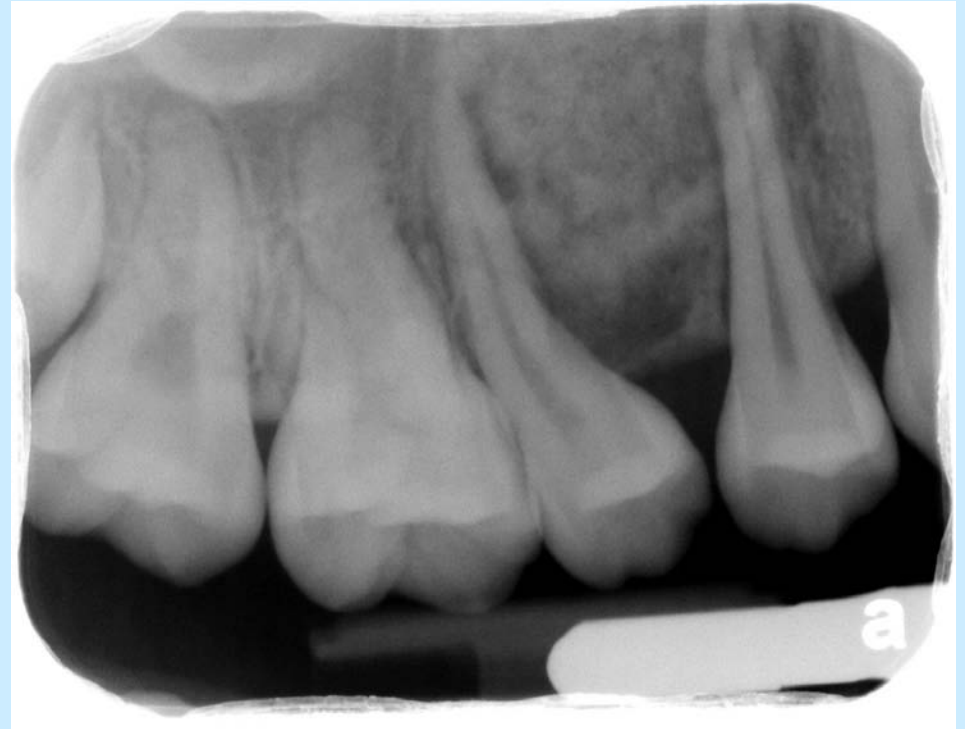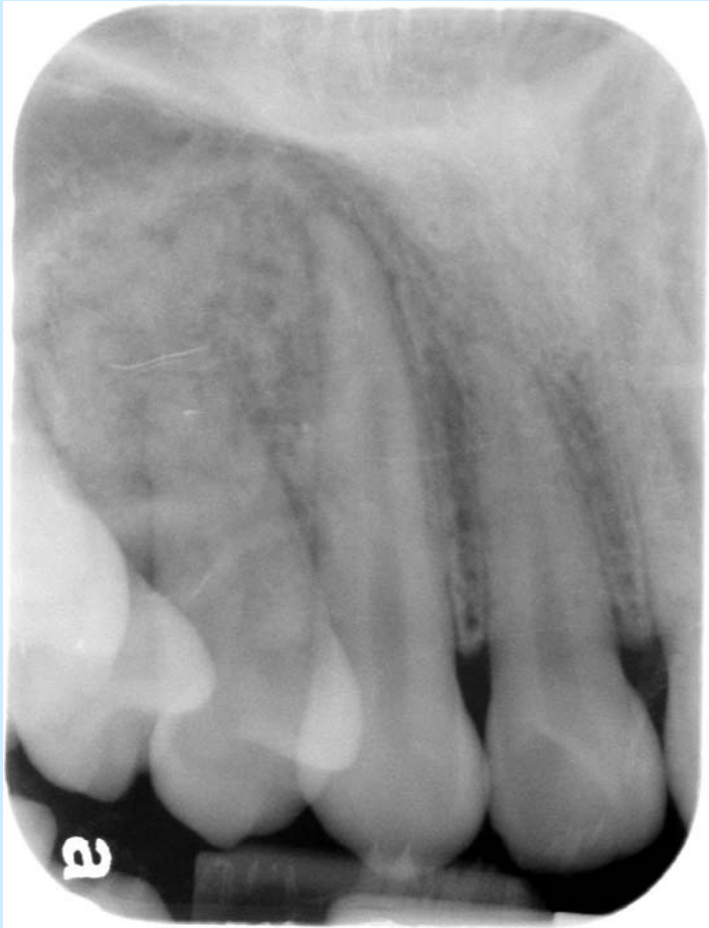- An hard dome-shaped sessile mass with smooth surface was found over the palatal side of tooth 14 & 15, measuring about 2 × 2 cm
- Painless



# Panoramic film



# Periapical film

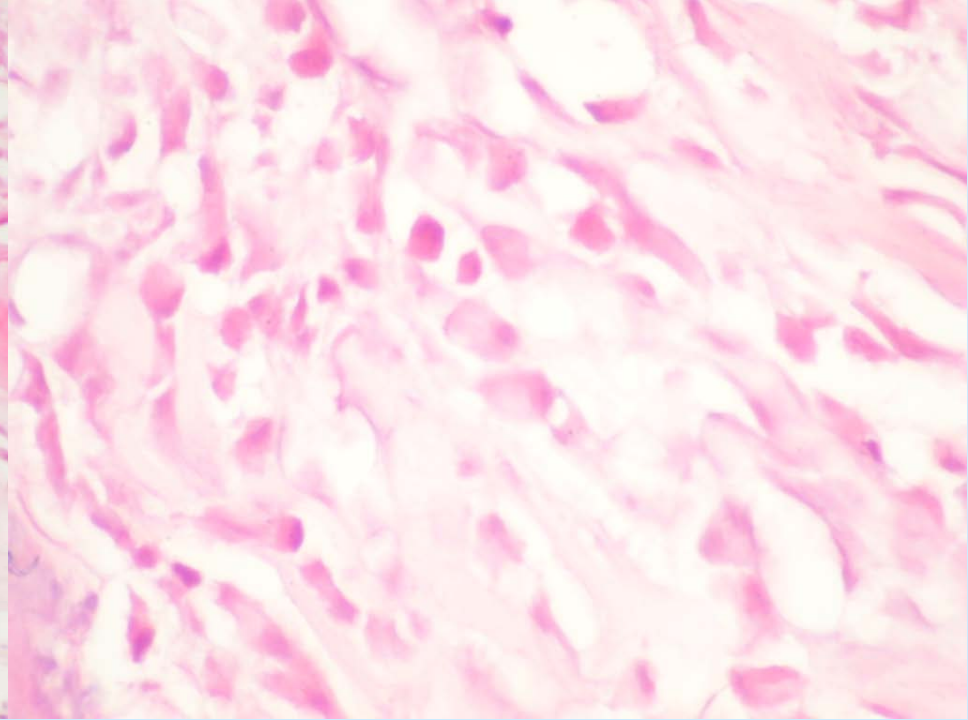
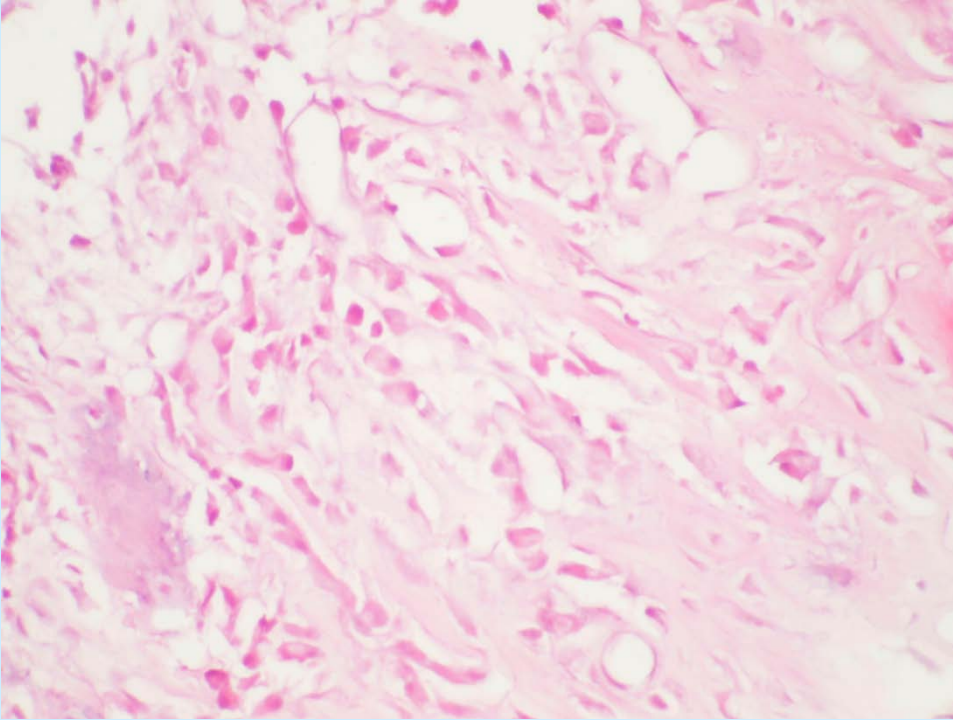
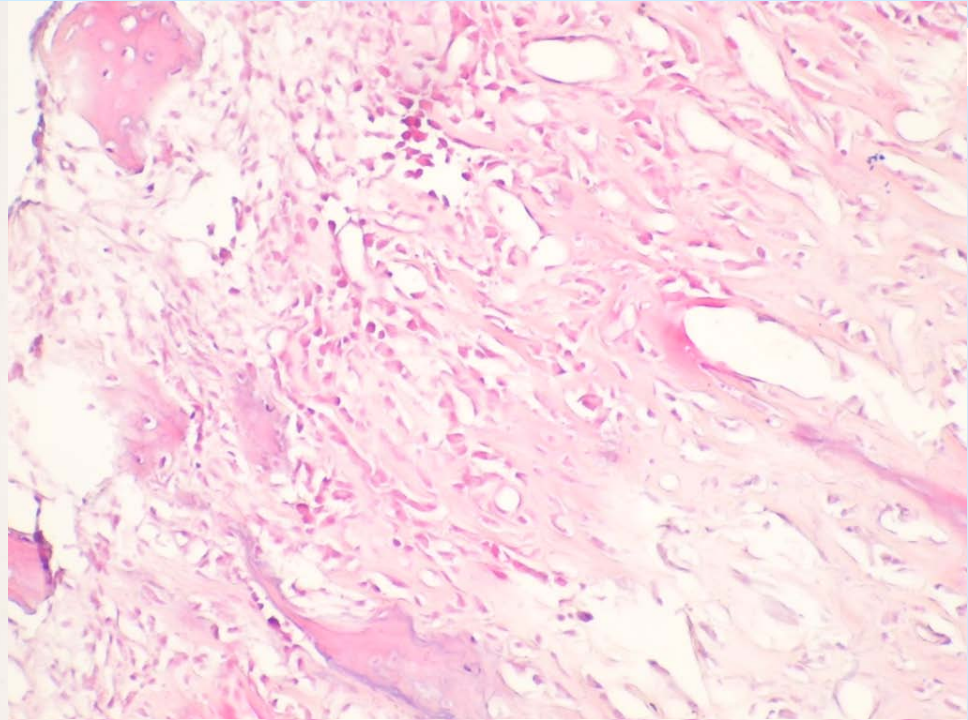
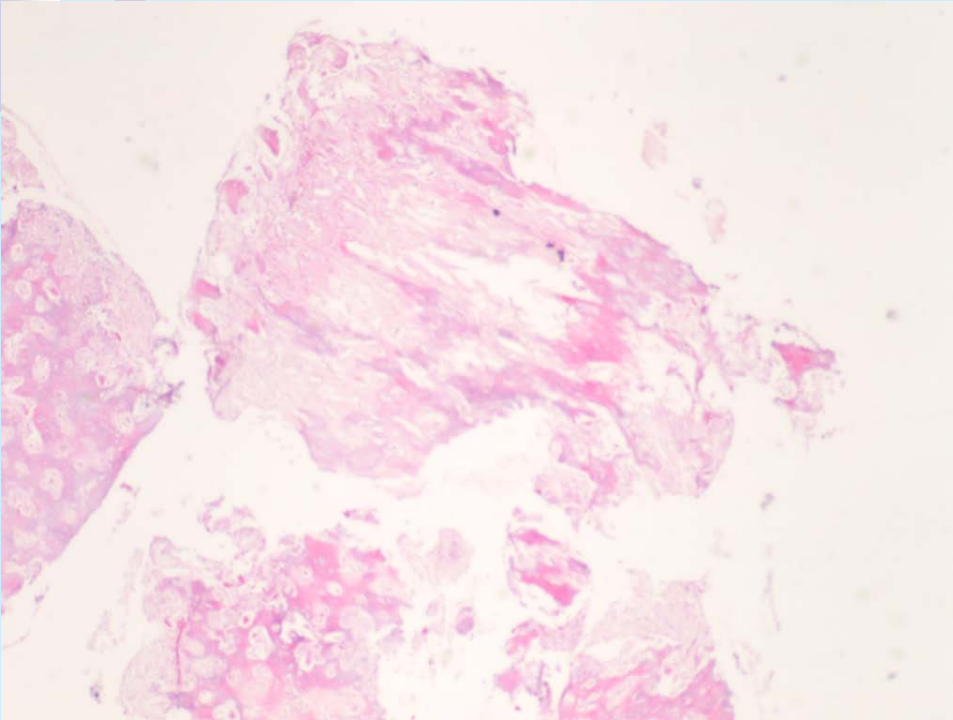




# **Clinical Impression**

- **Fibro-osseus lesion over right maxilla**



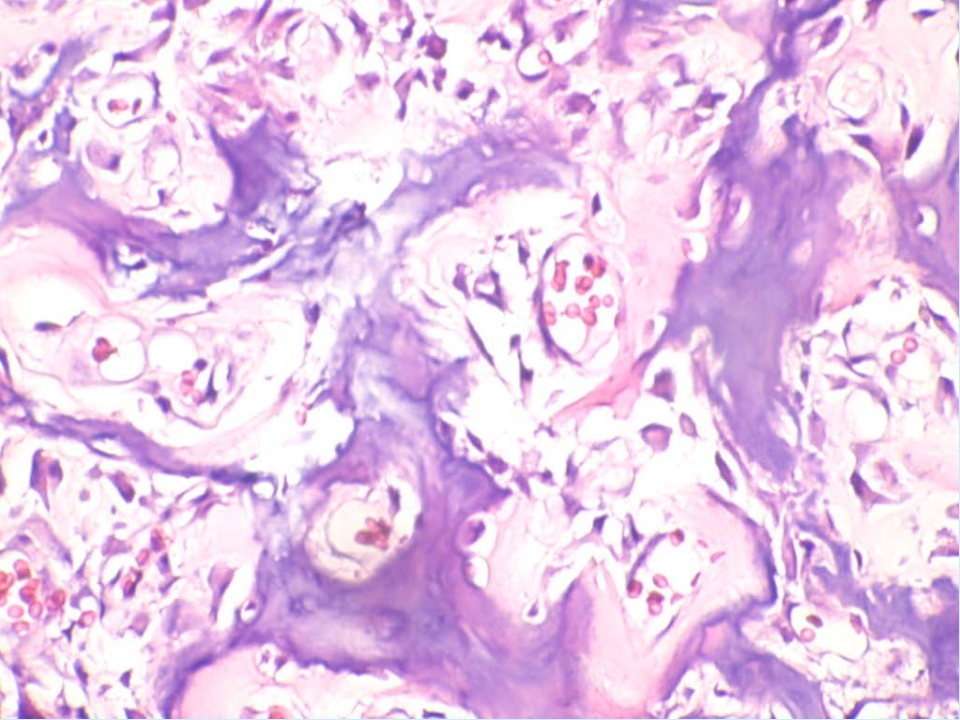
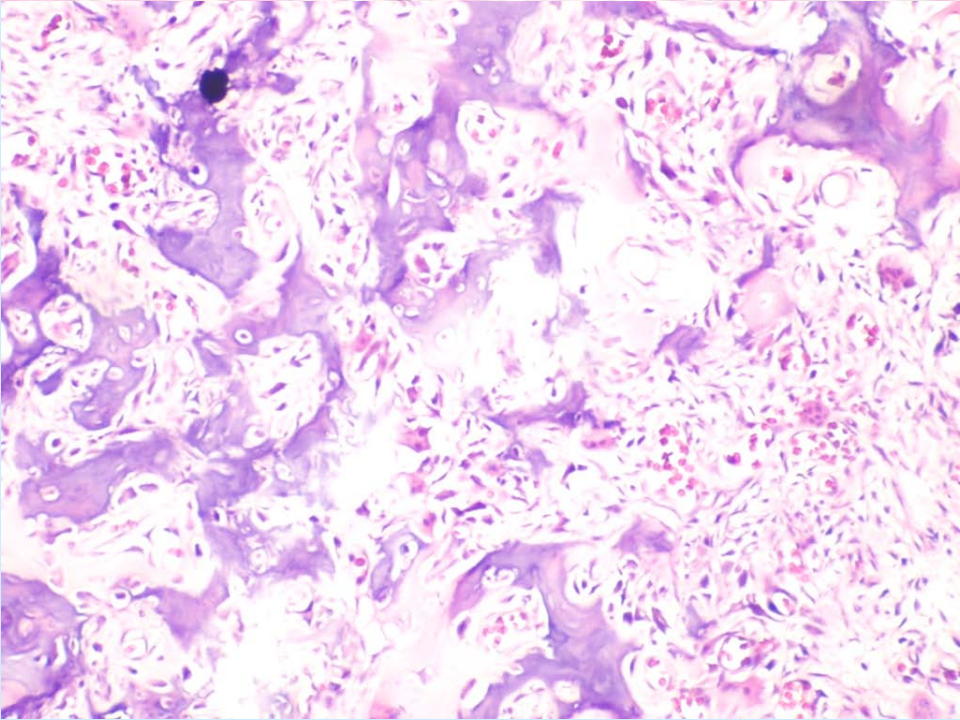
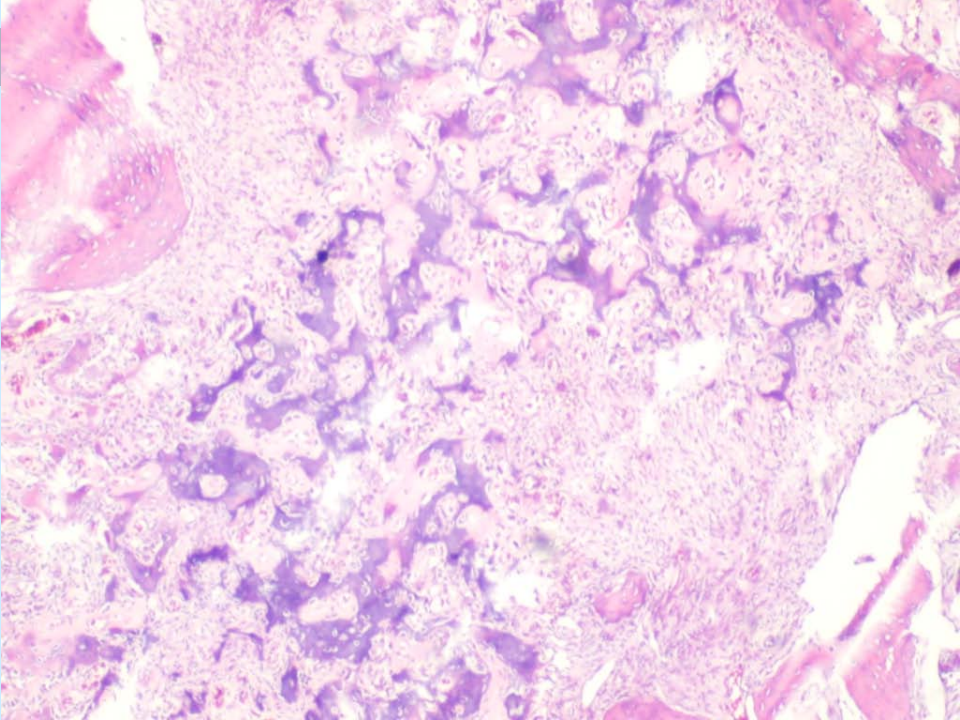
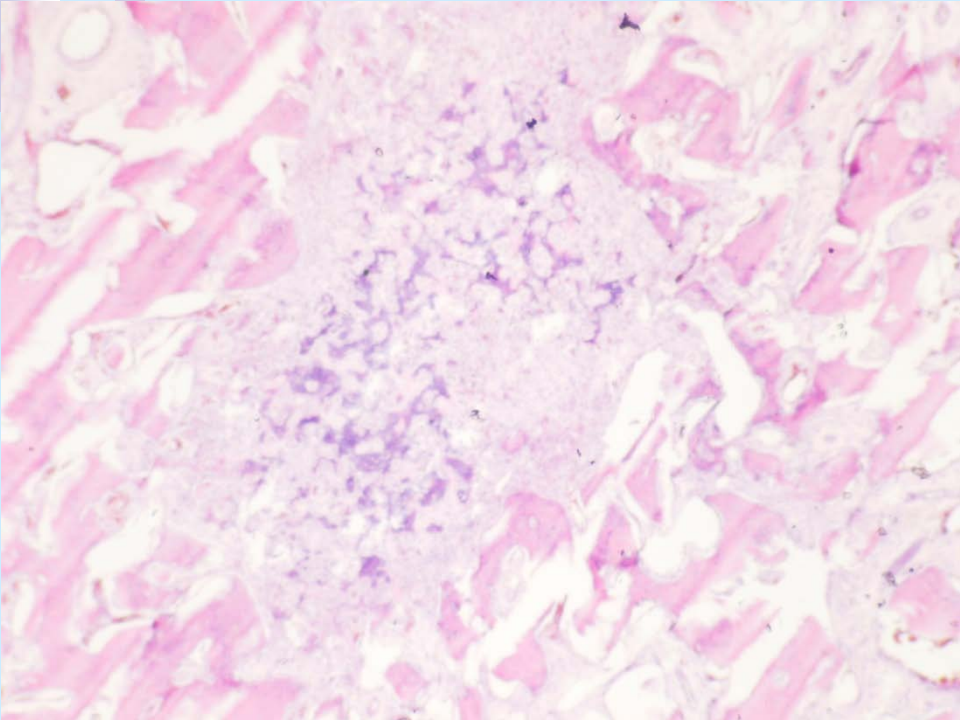




# HP Report

- **Osteoblastoma over right maxilla**







# Case 4

- **Name: 陳 O 宏**
- **Gender: male**
- **Age: 25 y/o**
- **主治醫師: 陳中和醫師**
- **初診日期: 99.02.04**
- **Chief complaint:**  
**Refer from 屏基 for checking mandibular expansion and huge radiolucency over mandibular body of radiographic finding**

# Present Illness

- This 25 y/o male suffered from lower facial swelling for half a year. He went to a LDC for help, and the dentist suggested him to go to 屏基 for further examination. In 屏基H, X-ray exam was performed, and a huge radiolucency image was found over mandibular body, then the P`t was suggested to our OMS department for consultation and further examination.

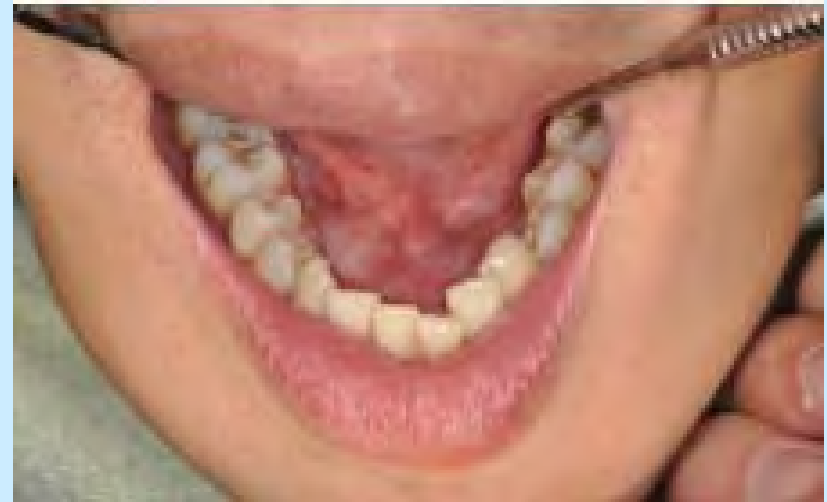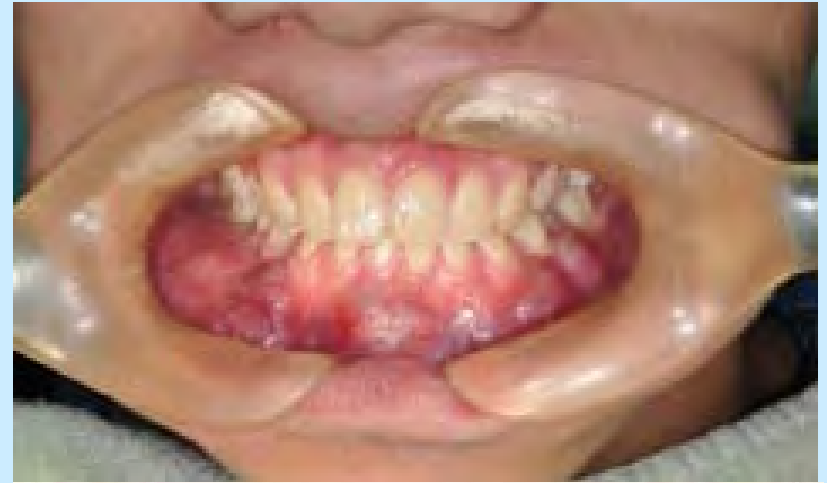# Past History And Personal Habit

- **Past Medical history**  
**Herniation**
- **Drug Allergy: Nil**
- **Past dental history: NP**
- **Personal habits: A(-), B(-), C(-), other habit(-)**

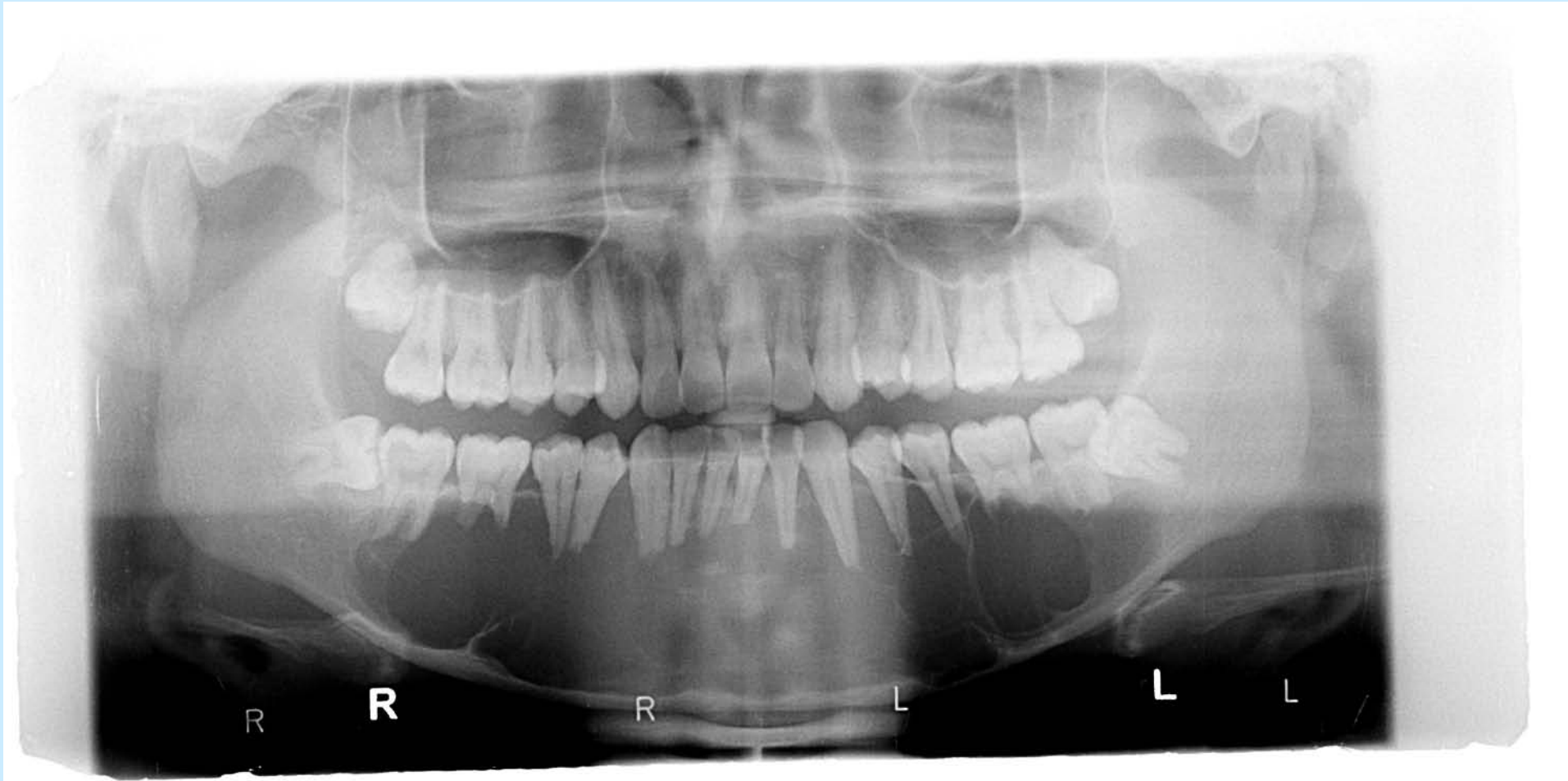


# Intra-Oral Findings

- **Multiple dome-shaped masses from tooth 37 to tooth 47, buccal and lingual side, bony hard, covering mucosa: intact, pink color**
- **Mobility(+): teeth 36-46**



# Panoramic film

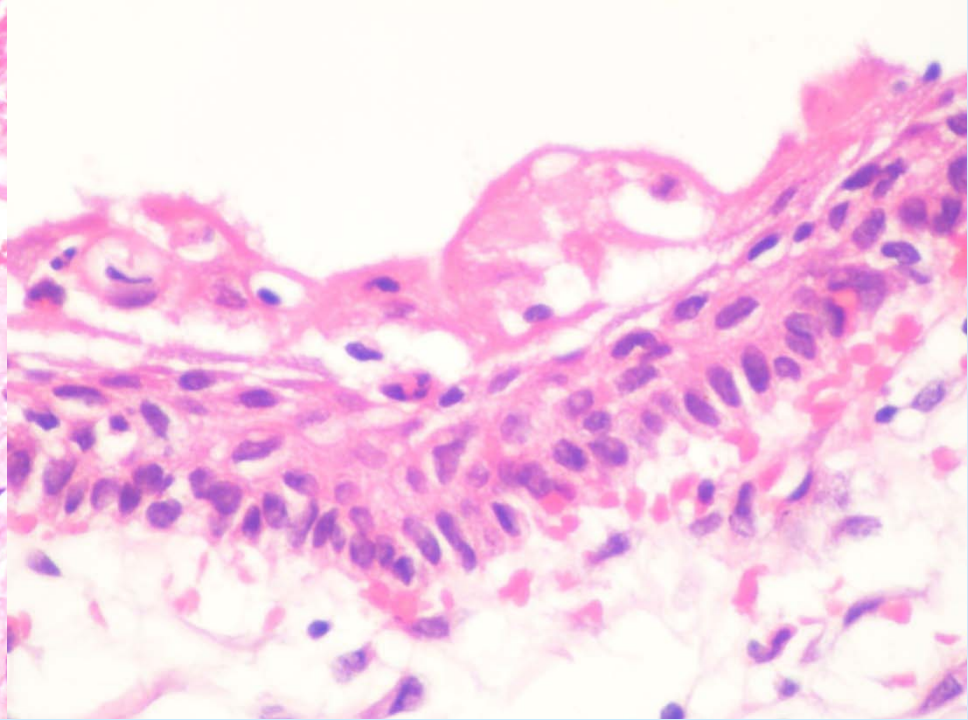
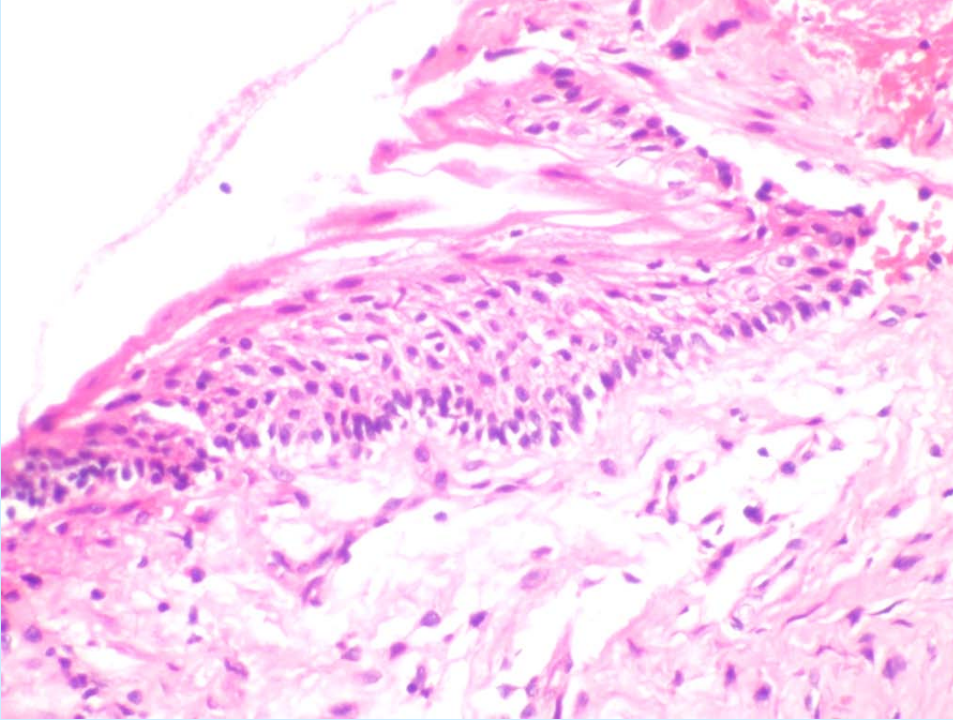
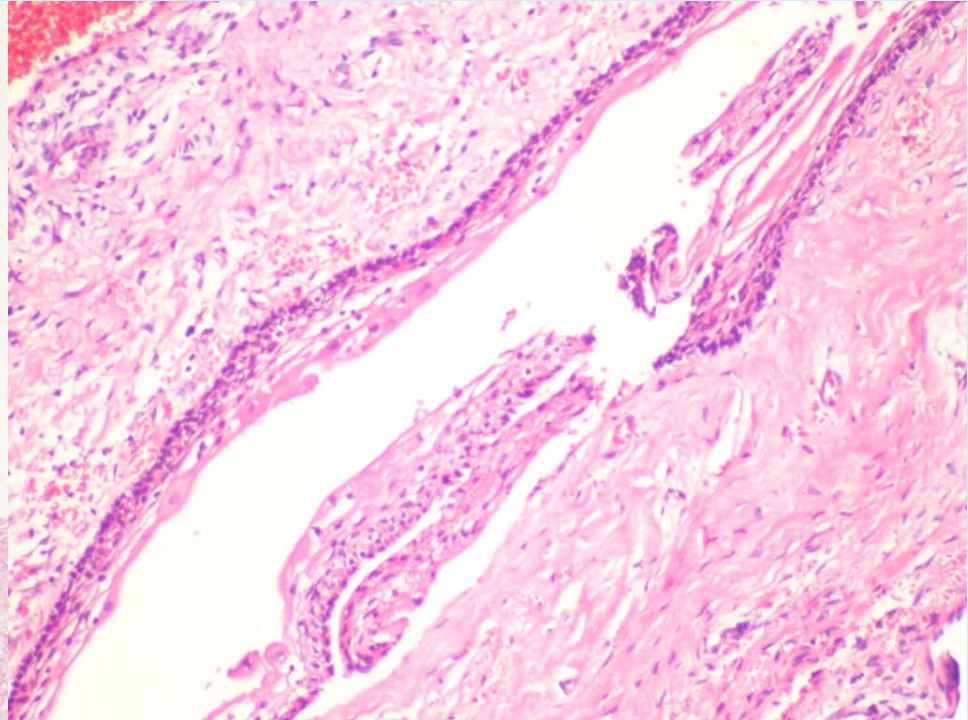
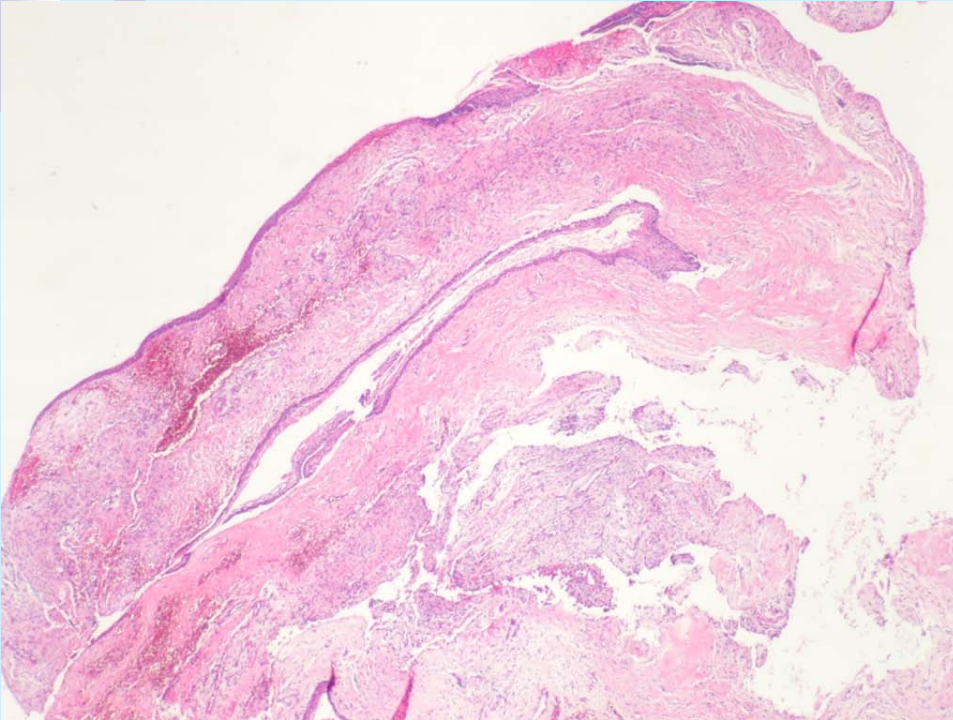




# Clinical Impression

- **Odontogenic keratocyst from tooth 36 to tooth 46**







# HP Report

- **Odontogenic keratocyst over bil. Mandibular boy and symphysis**

# Case 5

- **Name: 周 O 毅**
- **Gender: male**
- **Age: 23 y/o**
- **主治醫師: 黃逸岳醫師**
- **初診日期: 99.03.30**
- **Chief complaint:**  
**Referred from a LDC**  
**for management of a**  
**lesion over his left**  
**mandible**





# Present Illness

- **This 23 y/o male went to LDC for 38 extraction, but the dentist found a radiolucent lesion over 36-38 apical area, so he was referred to our OPD for further examination on 99.03.30.**

# Past History And Personal Habit

- **Past Medical history**

**NP**

**Hospitalization (+): R't hand fracture**

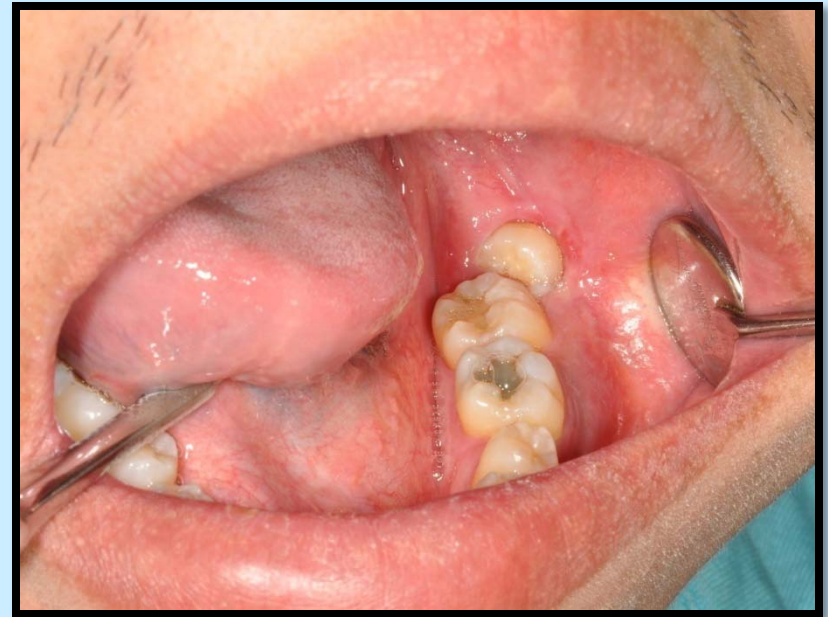- **Drug Allergy: Nil**

- **Past dental history: NP**

- **Personal habits: A(-), B(-), C(-), other habit(-)**

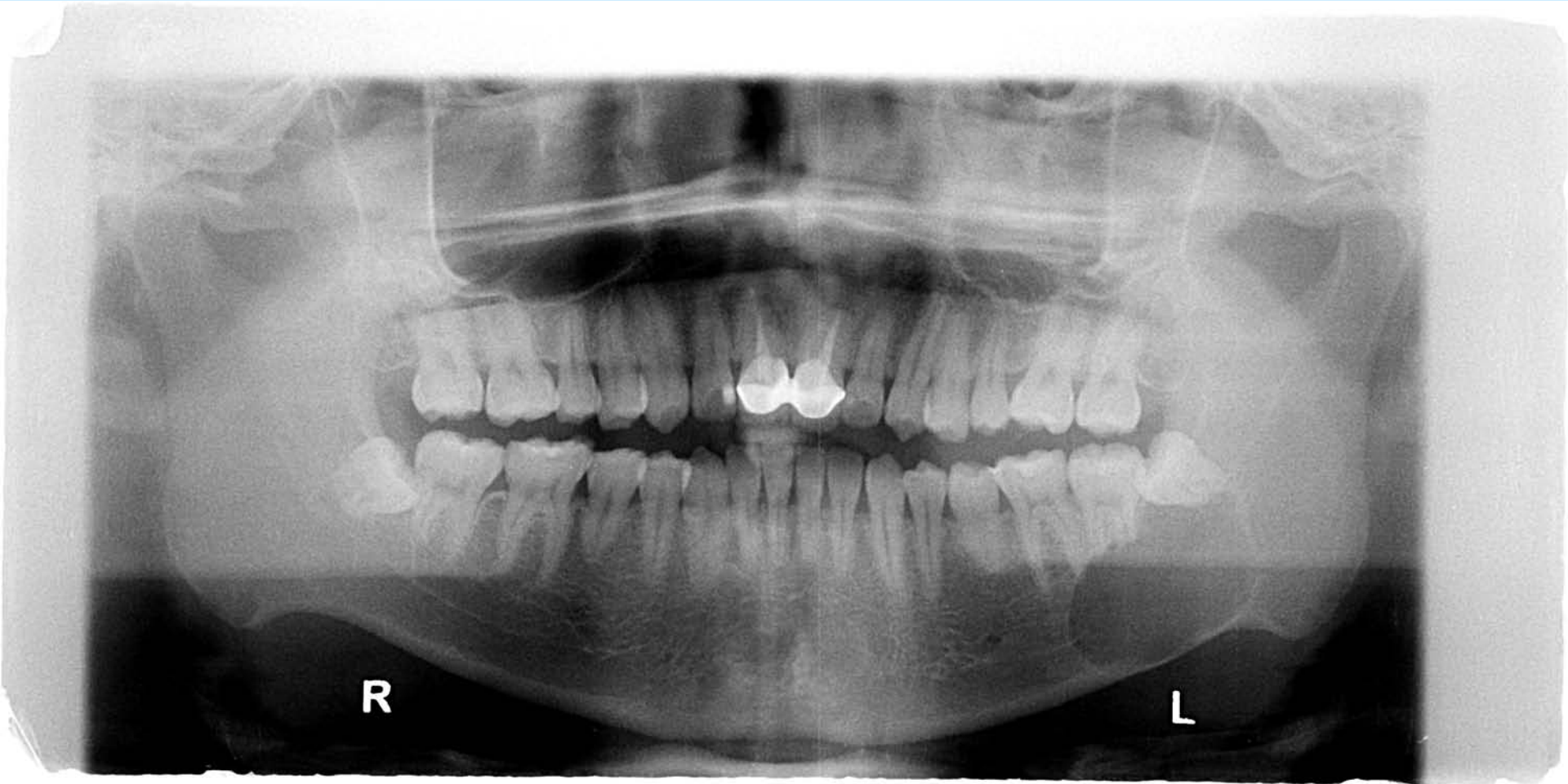# Intra-Oral Findings

- **Tooth 36-38 area bone expansion(+), bony hard, covering mucosa: intact, pink color**
- **Tooth mobility(-), pain(-)**





# Panoramic film

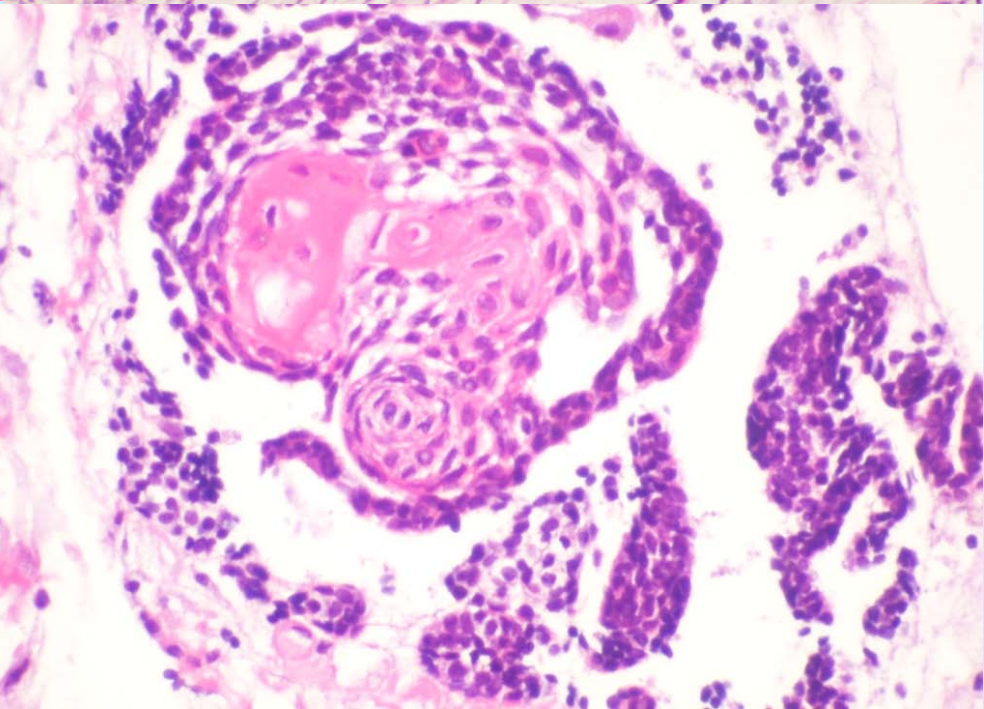
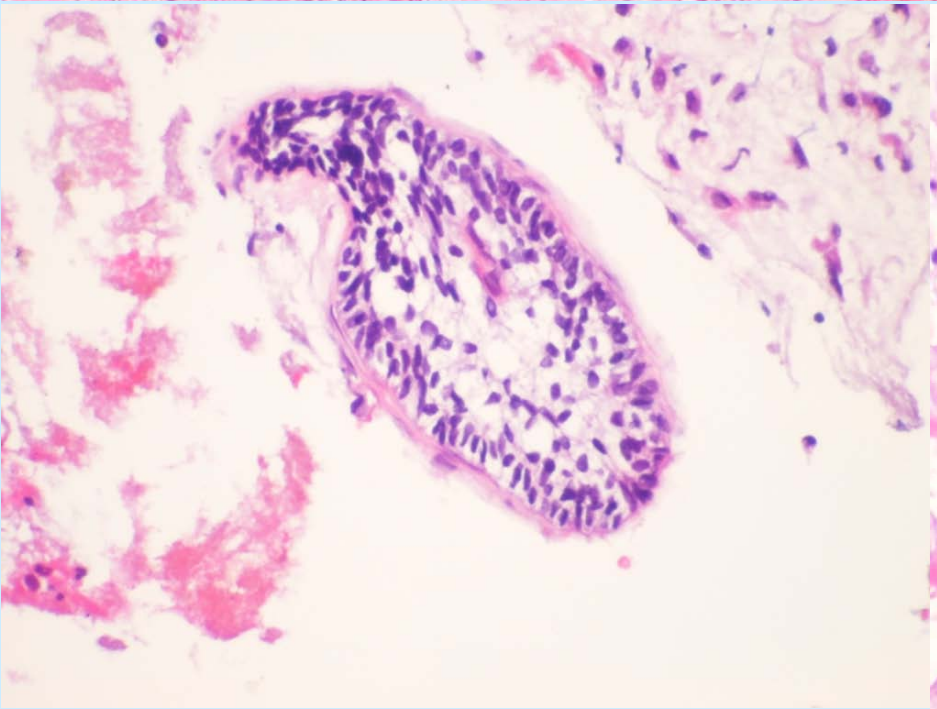
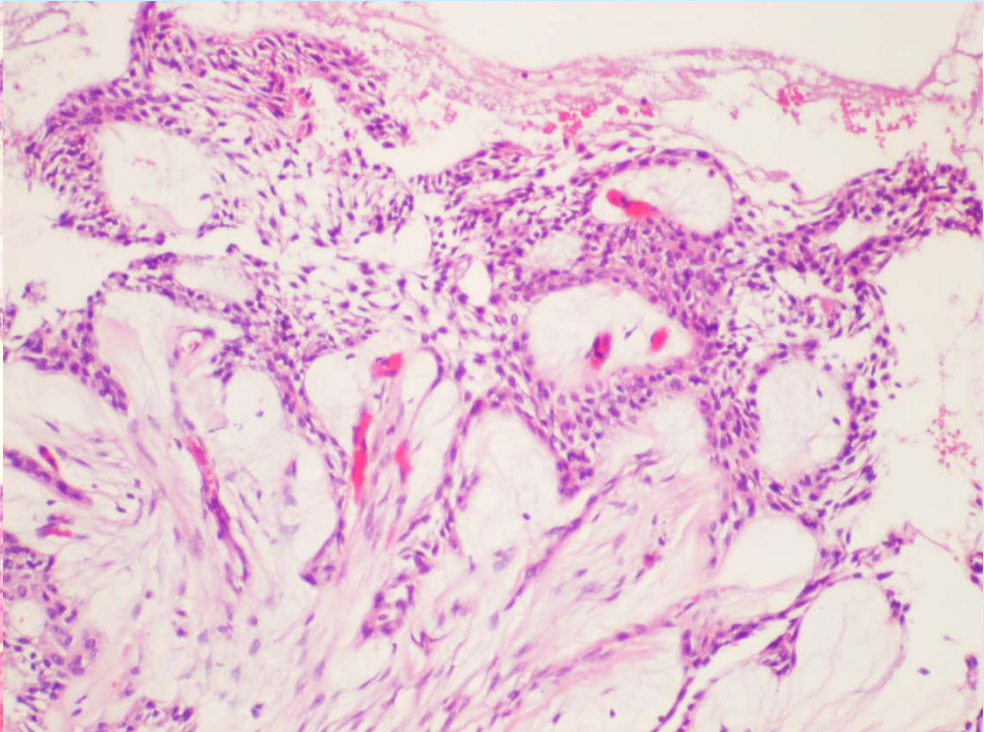
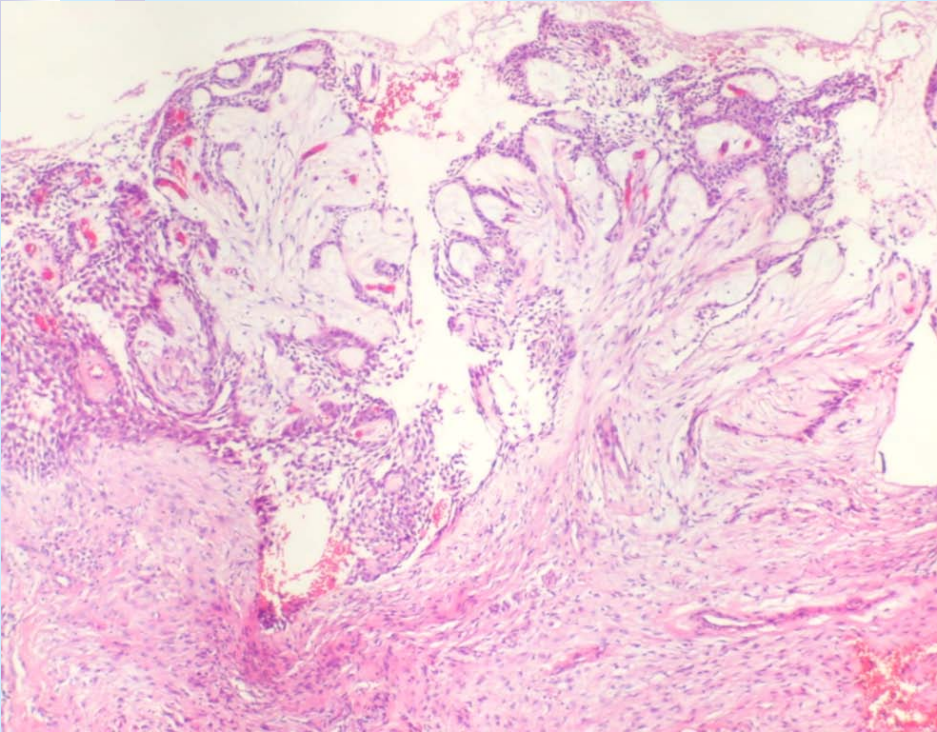




# **Clinical Impression**

- **Cystic lesion over teeth 36-38 apical area**



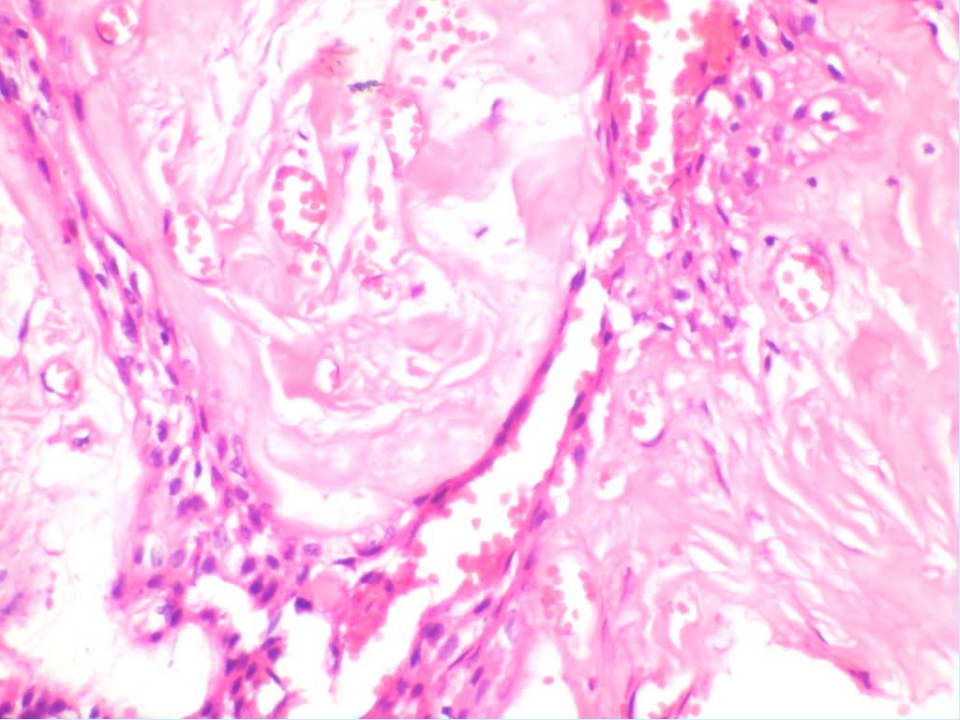
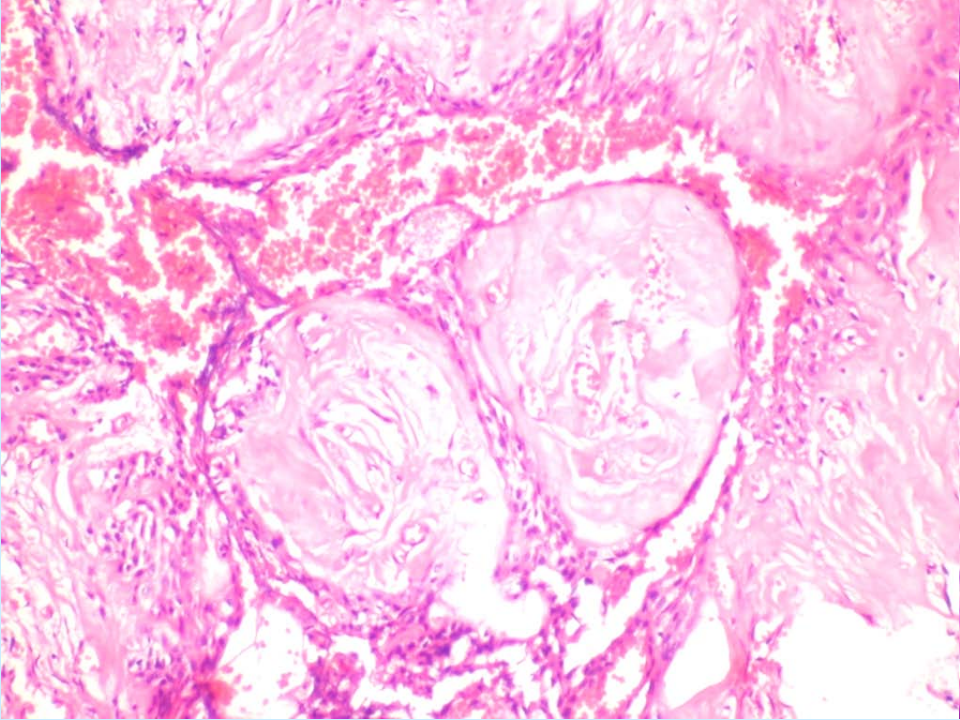
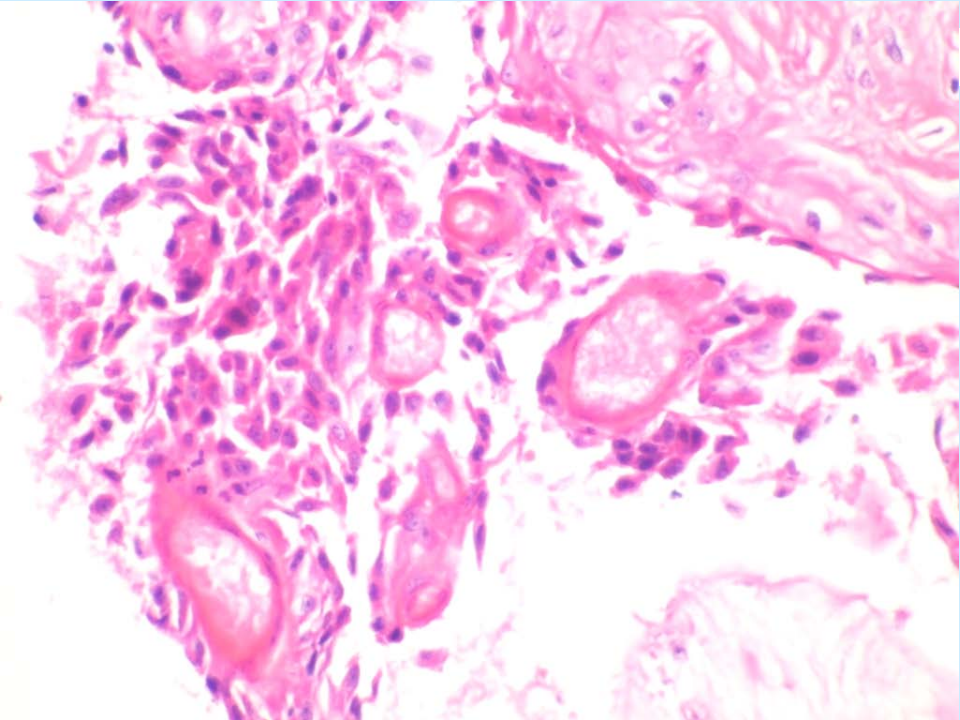
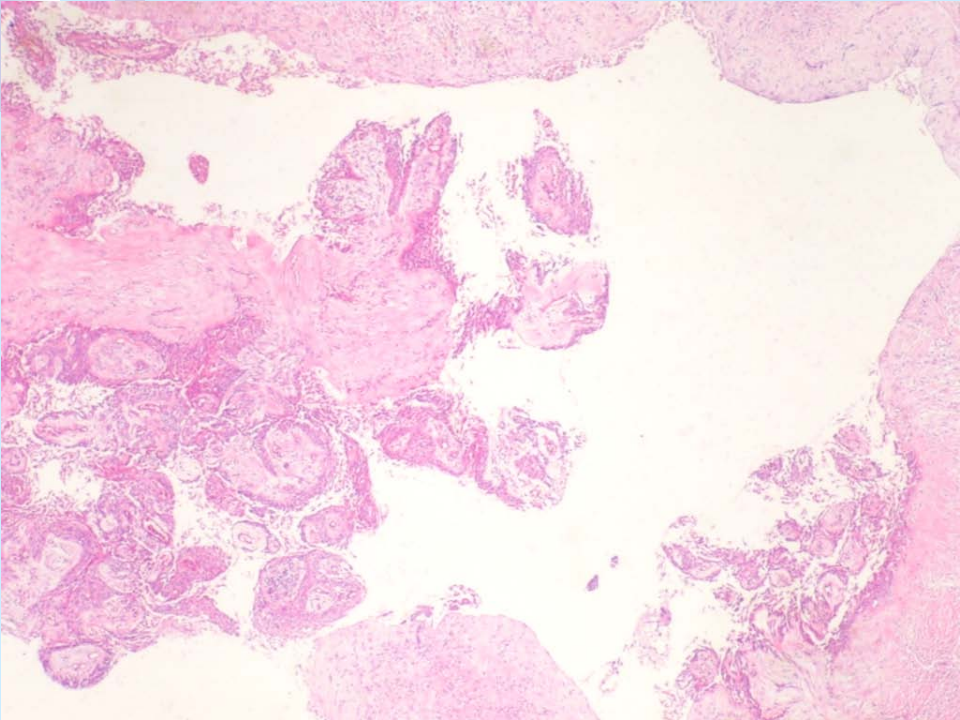




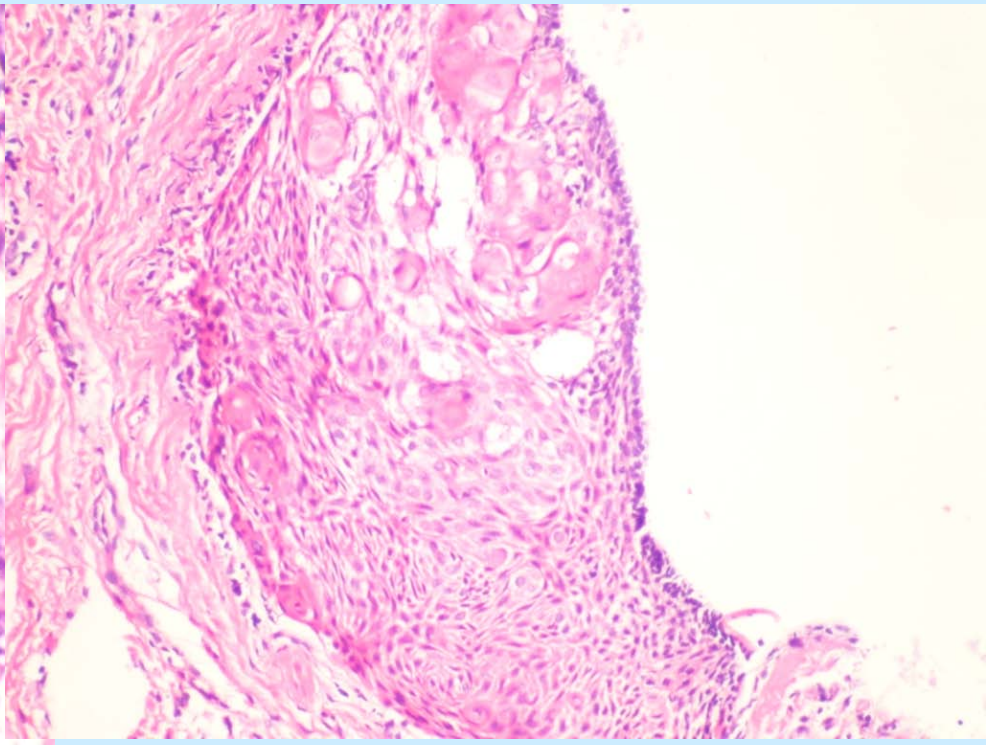
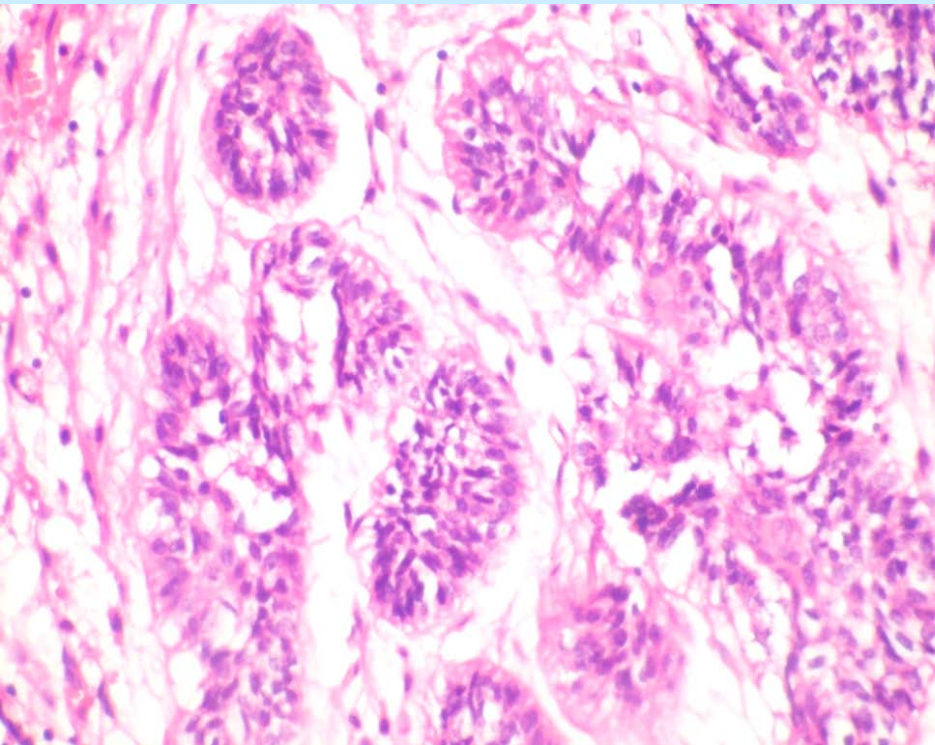


# HP Report

- **Ameloblastoma over left mandibular body**









# HP Report

- **Calcifying odontogenic cyst with ameloblastic change over left mandibular body**

# Case 6

- **Name:** 黃 O 偉
- **Gender:** male
- **Age:** 32 y/o
- **主治醫師:** 陳中和醫師
- **初診日期:** 98.05.13
- **Chief complaint:**  
Referred from a LDC  
for 38 extraction



# Present Illness

- **This 32 y/o patient felt discomfort over 38 area about 2 months ago. He came to LDC for help. The doctor referred him to our OPD for extraction of the 38 impaction. X-ray exam found a R/L lesion over left mandible.**



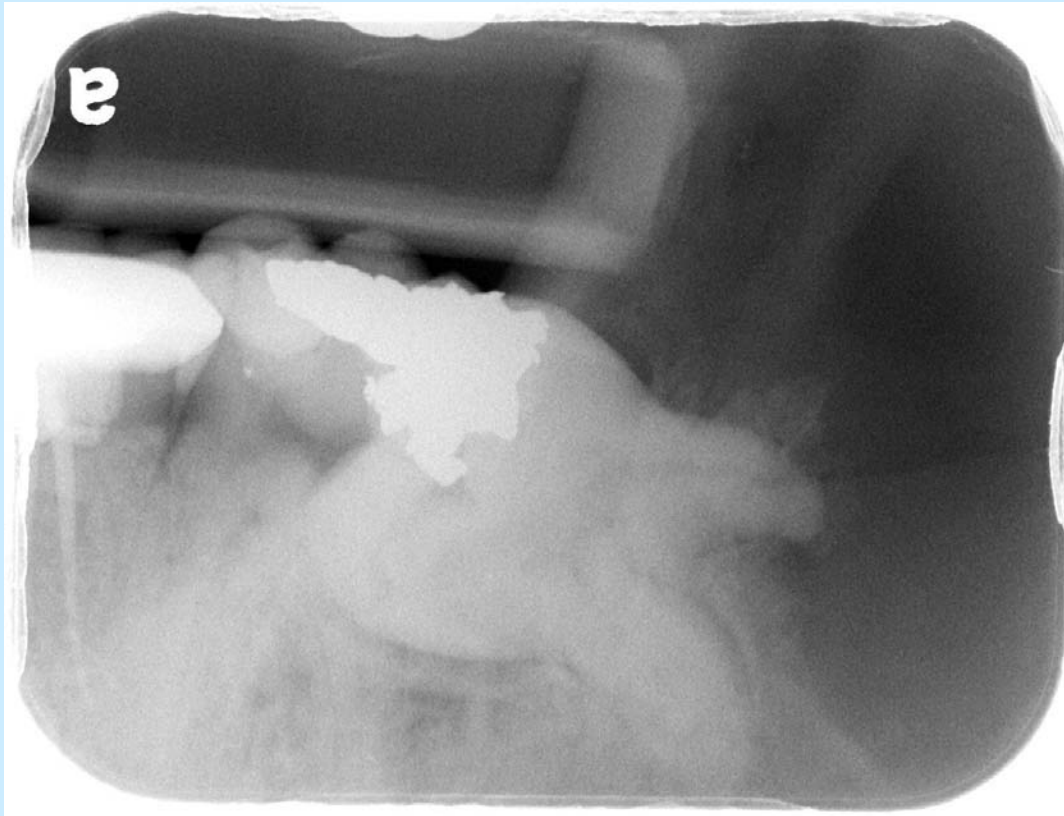# Past History And Personal Habit

- **Past Medical history**  
NP
- **Drug Allergy: Nil**
- **Past dental history: NP**
- **Personal habits: A(?), B(?), C(?), other habit(?)**

# Intra-Oral Findings

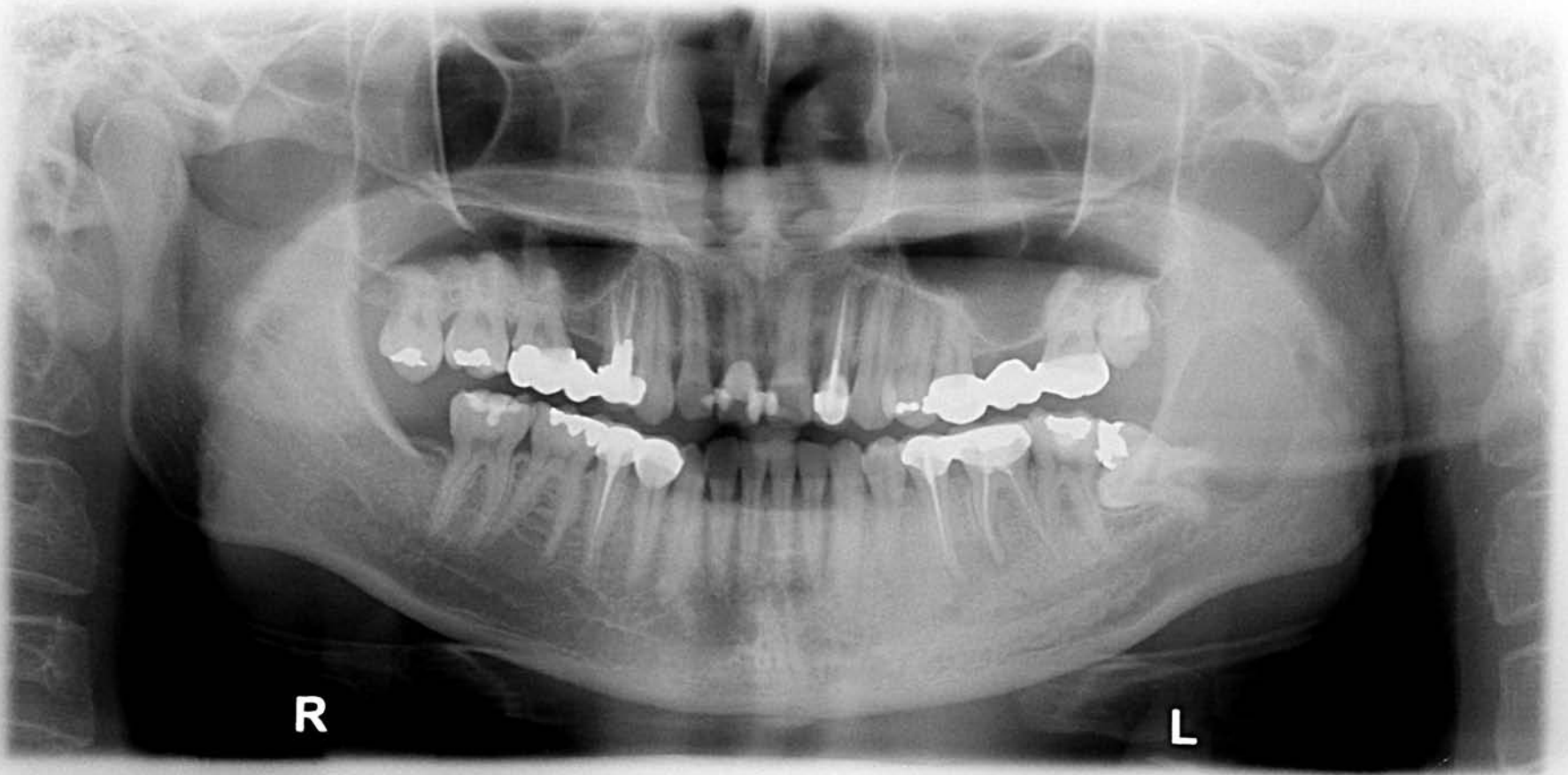- **Tooth 36-38 area bone expansion(+), bony hard, covering mucosa: intact, pink color**
- **Tooth mobility(-), pain(-)**

# Periapical film 98.05.13

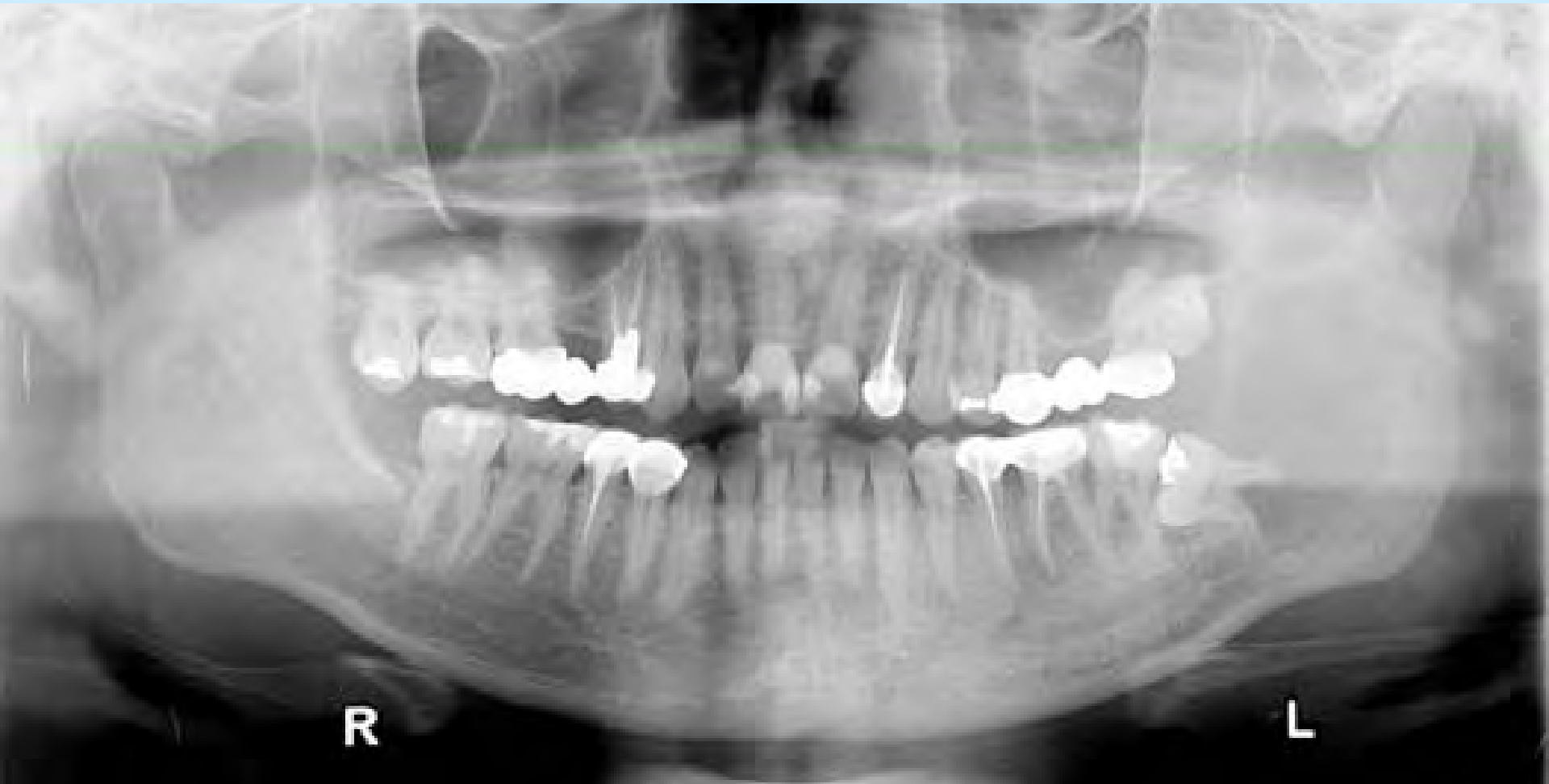



# Panoramic film 98.05



# Panoramic film 98.11

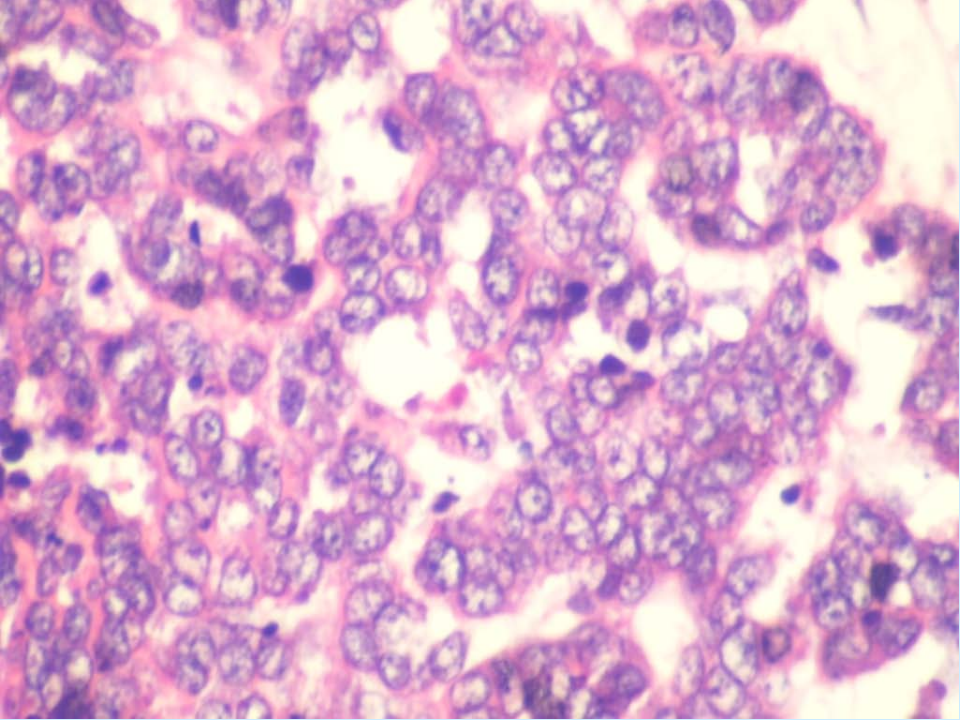
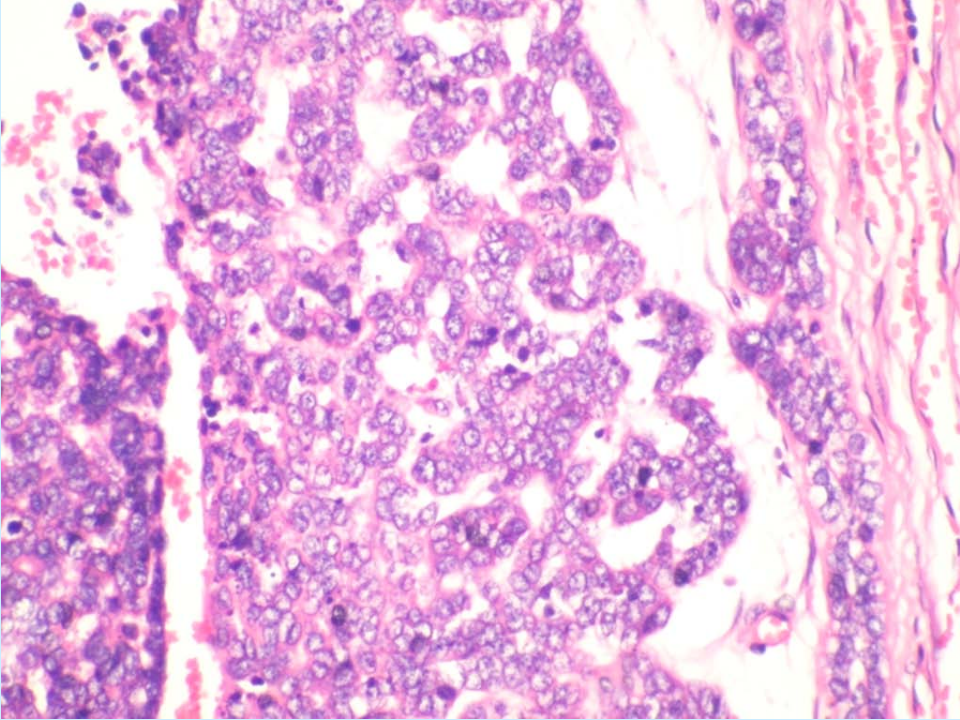
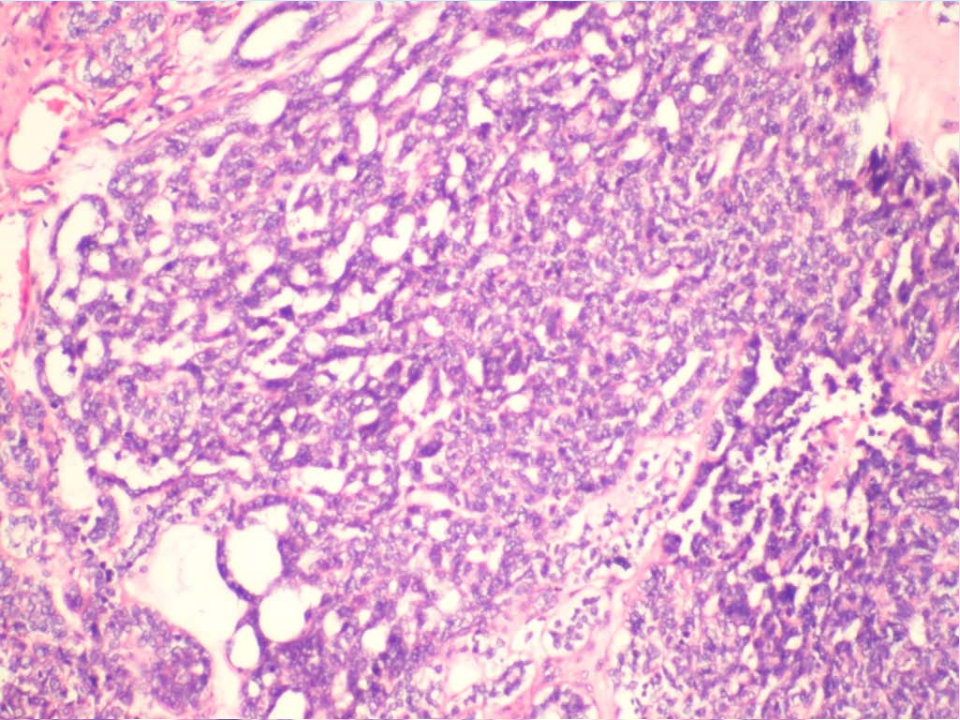
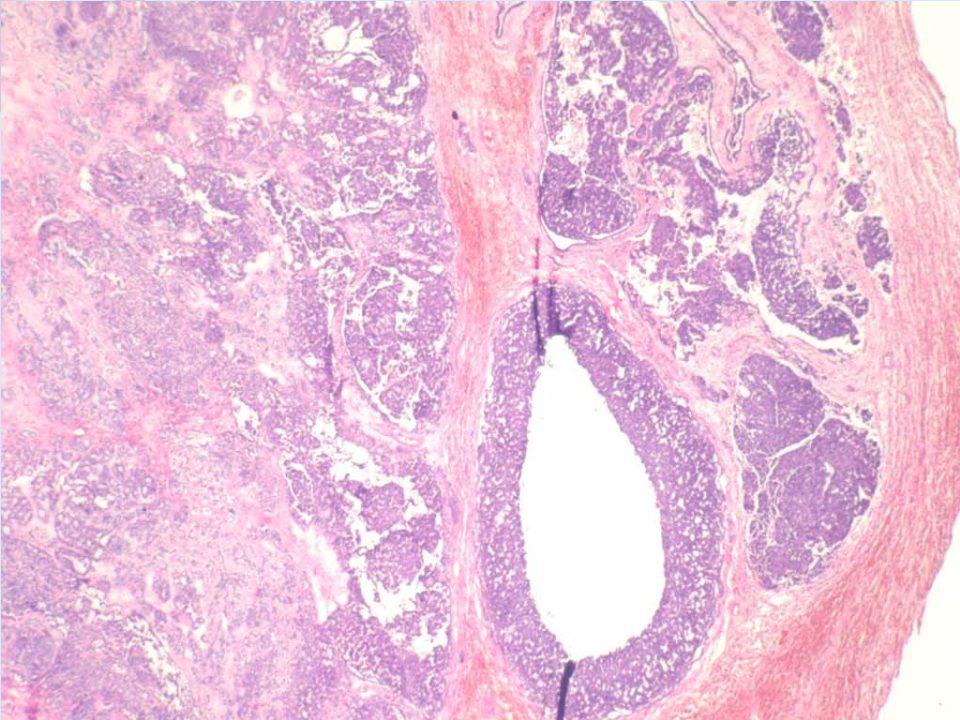




# **Clinical Impression**

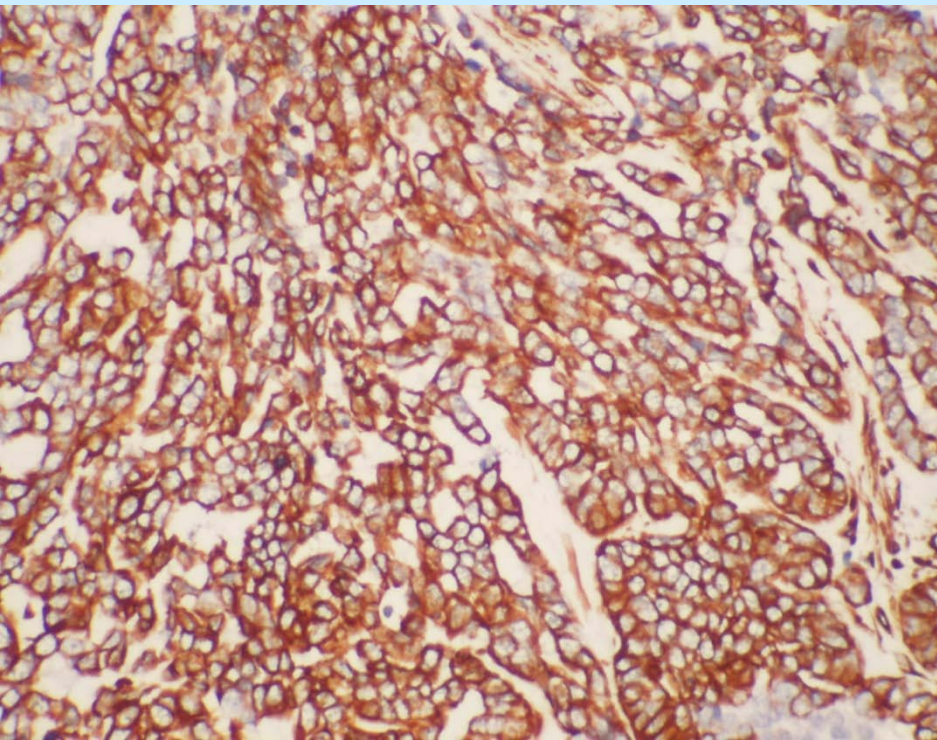
- **Cystic lesion over 38 apical area**



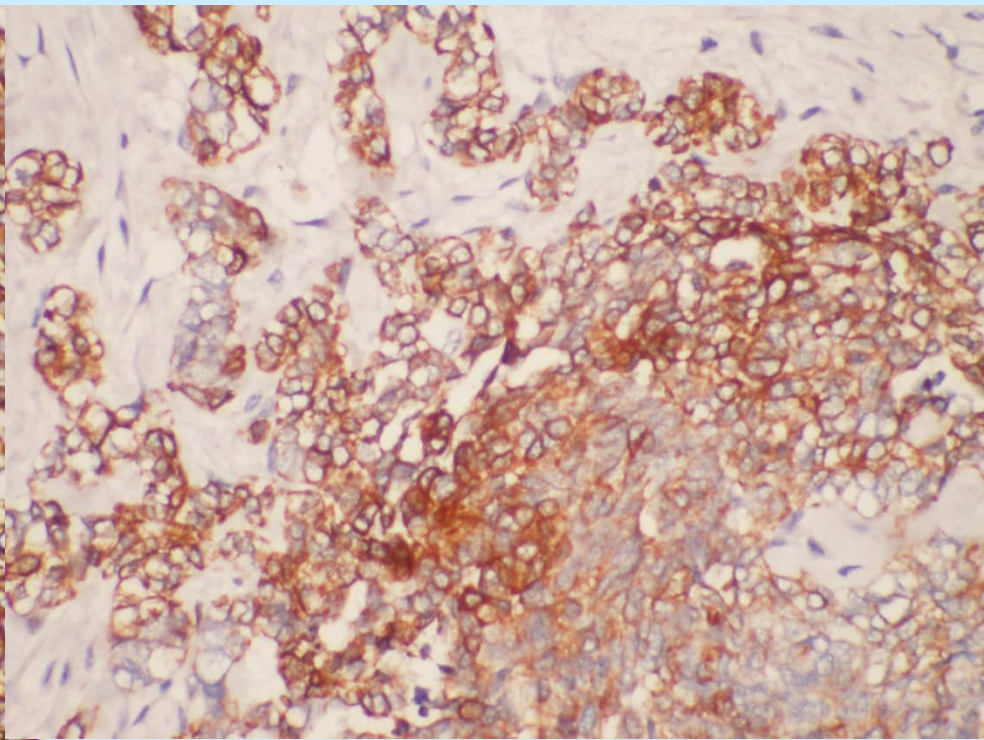




**Vimentin (+)**



**Cytokeratin (+)**

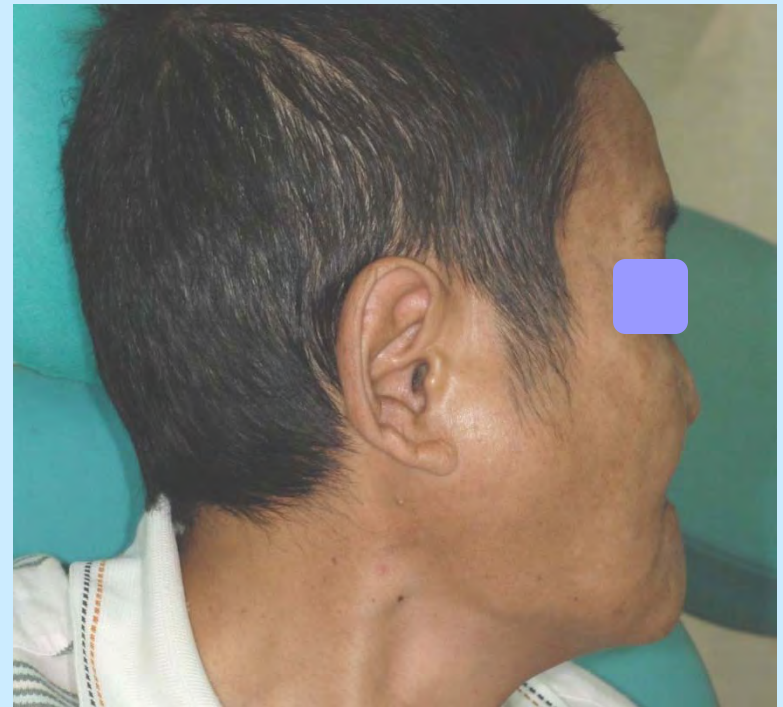


# HP Report

- **Salivary duct carcinoma over left mandibular body and ramus**

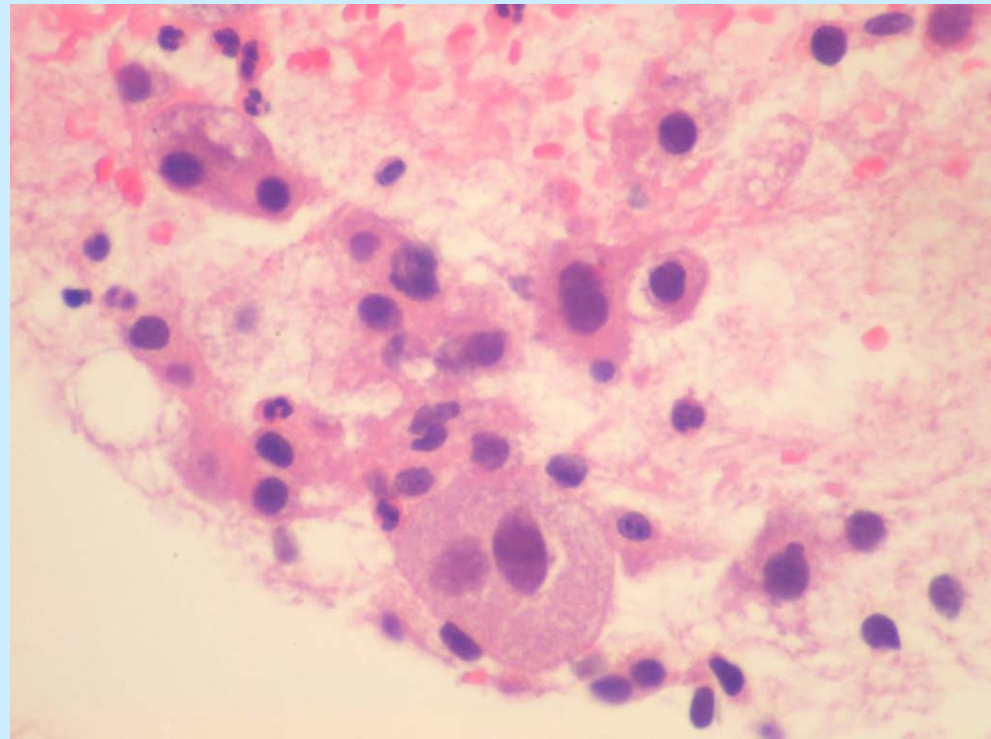
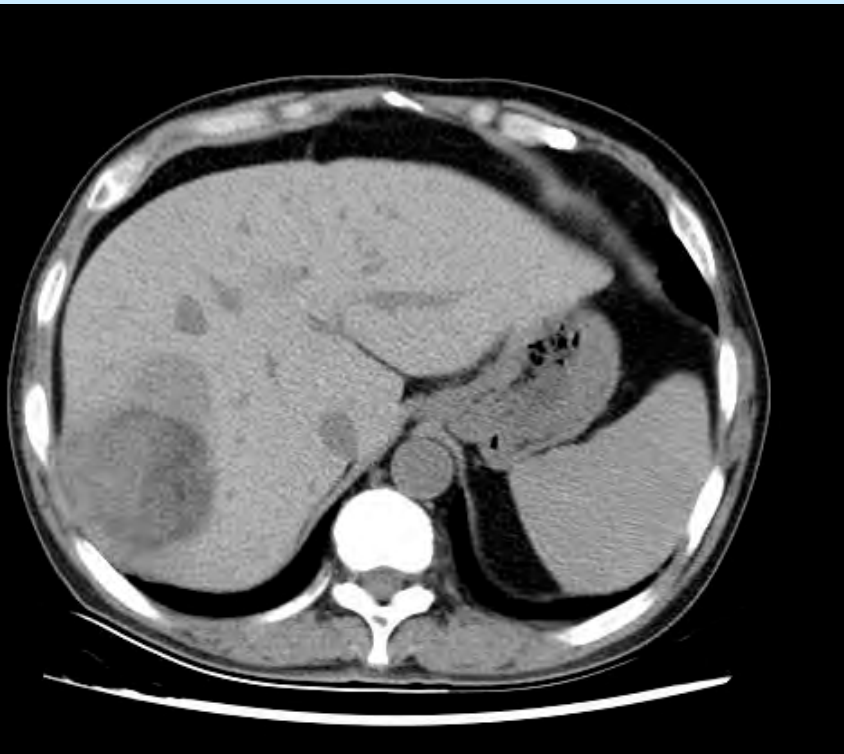
# Case 7

- Name: 陳 O 原
- Gender: Male
- Age: 51 y/o
- 照會醫師: 施亦倫 醫師
- 照會日期: 98.10.12
- Chief complaint:  
Right facial swelling  
since 98.07



# Present Illness - 1

- This 51 y/o male was a case of HCC (since 9803), s/p TACE twice





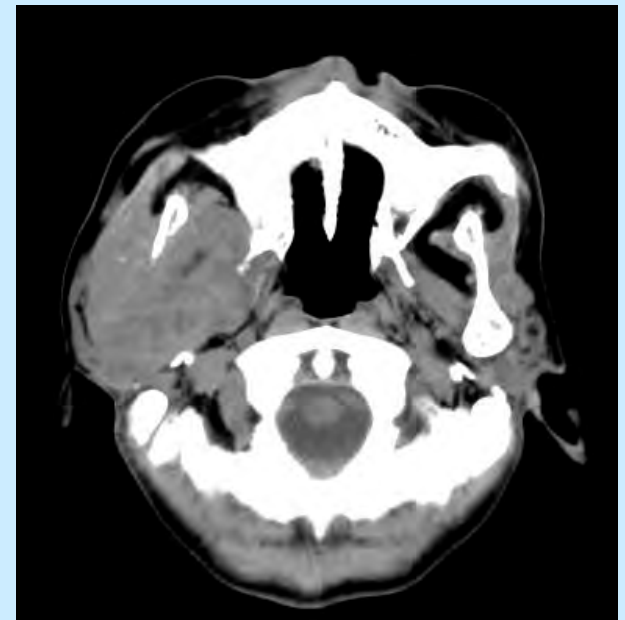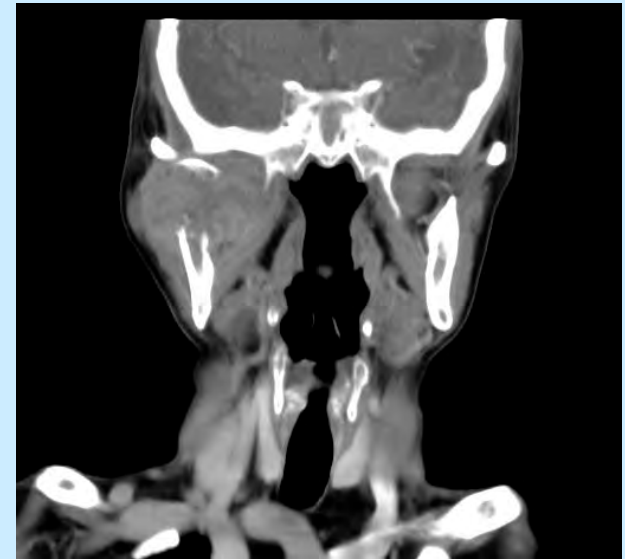
# Present Illness - 2

- **98.09.29**

**Came to our ER with chief complaint of right facial swelling (since 98/07) , left chest pain, and short of breath . A soft tissue mass was found in right masticator space in CT image.**

- **98.10.12**

**Consult OS for biopsy**



# Past Medical History

- **HBV, HCV, Alcohol-related hepatitis**
- **Liver cirrhosis**
- **Thalassemia**
- **L't temporal traumatic subarachnoid hmorrage on 95.05**
- **Gall bladder stone s/p cholecystectomy on 93.06**
- **Drug Allergy: Nil**



# Past Dental History And Personal Habit

- **Past Dental History**

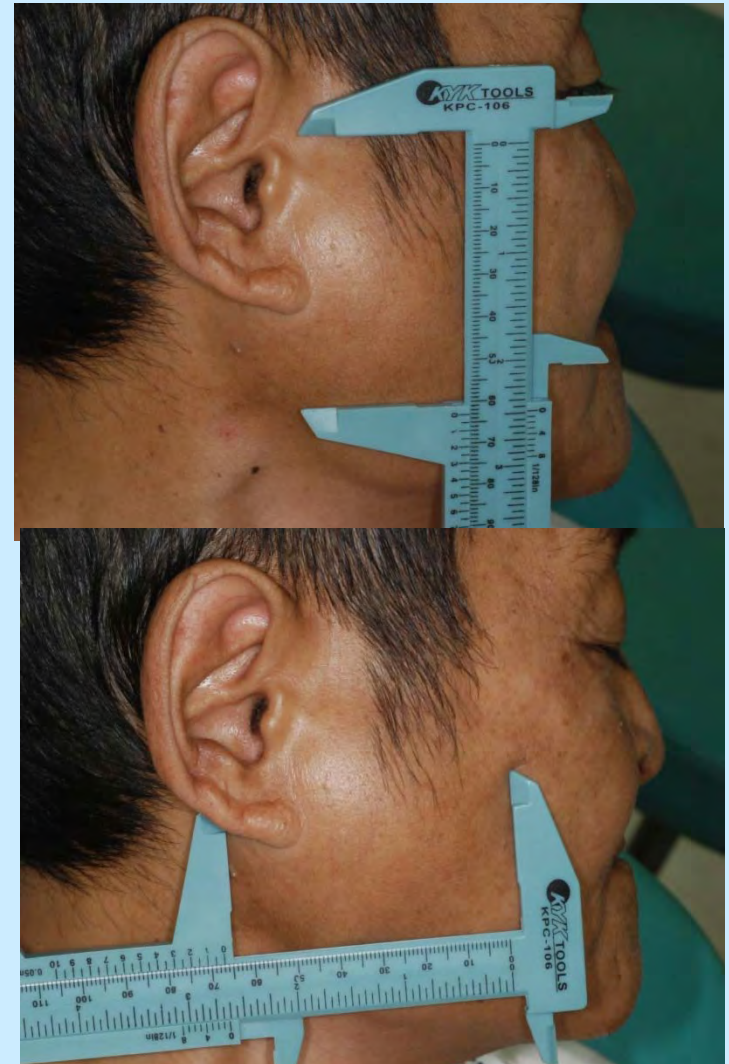
**NP**

- **Personal Habits**

**A(+), B(?), C(?)**

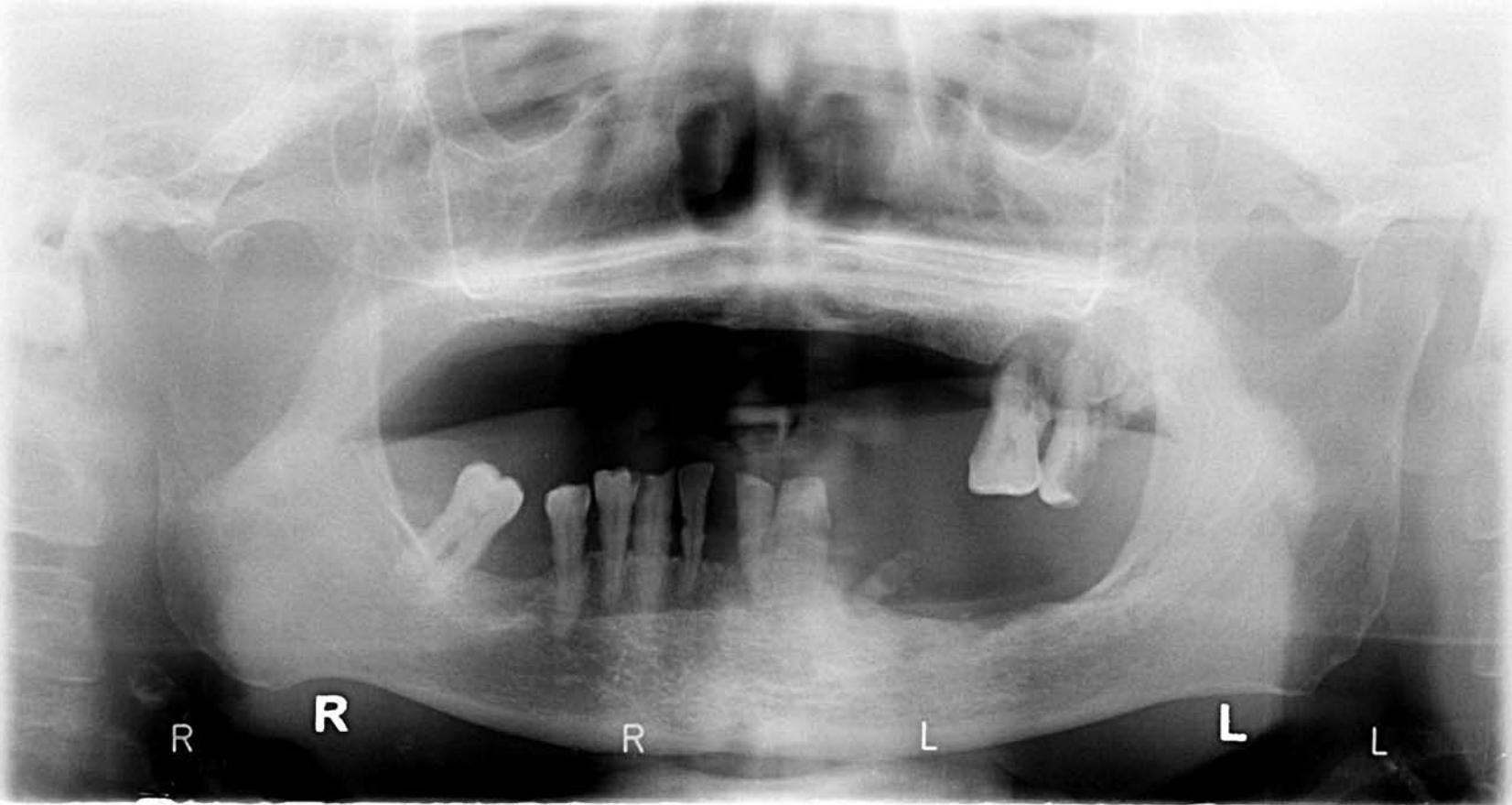
# Extra-Oral Findings

- A firm mass over right pre- and infra-auricular area, about 6.5x6.0 cm in dimension
- Fixed, firm, tenderness(+)





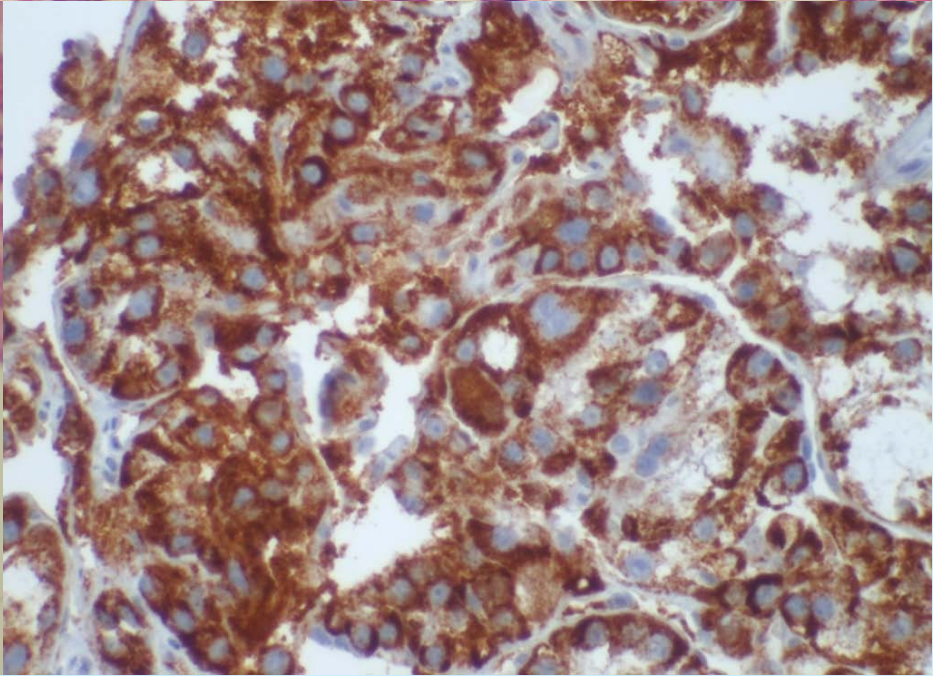
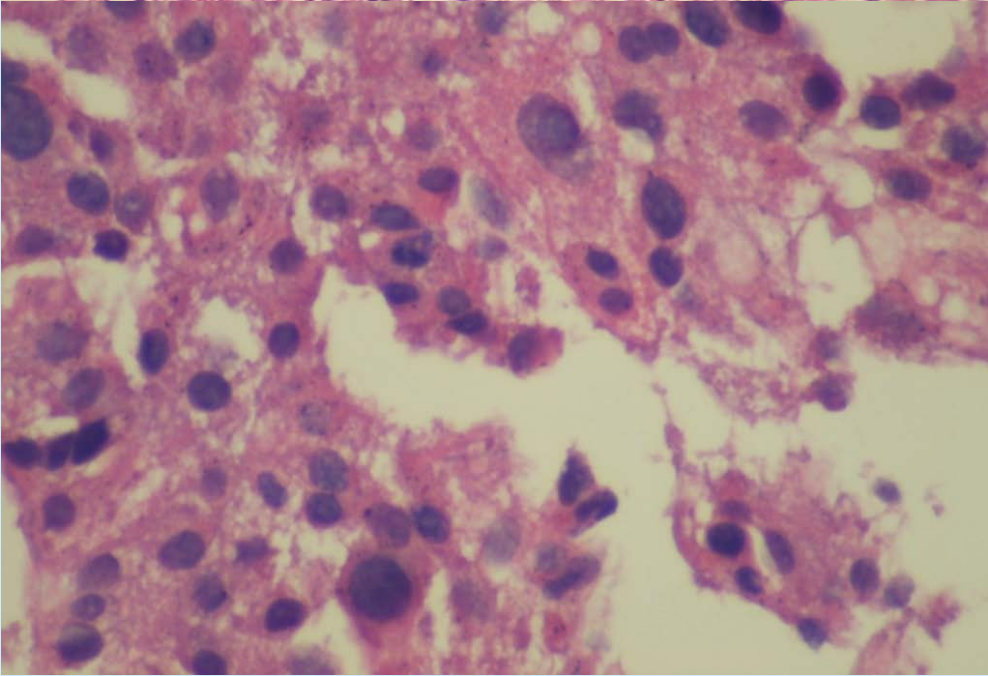
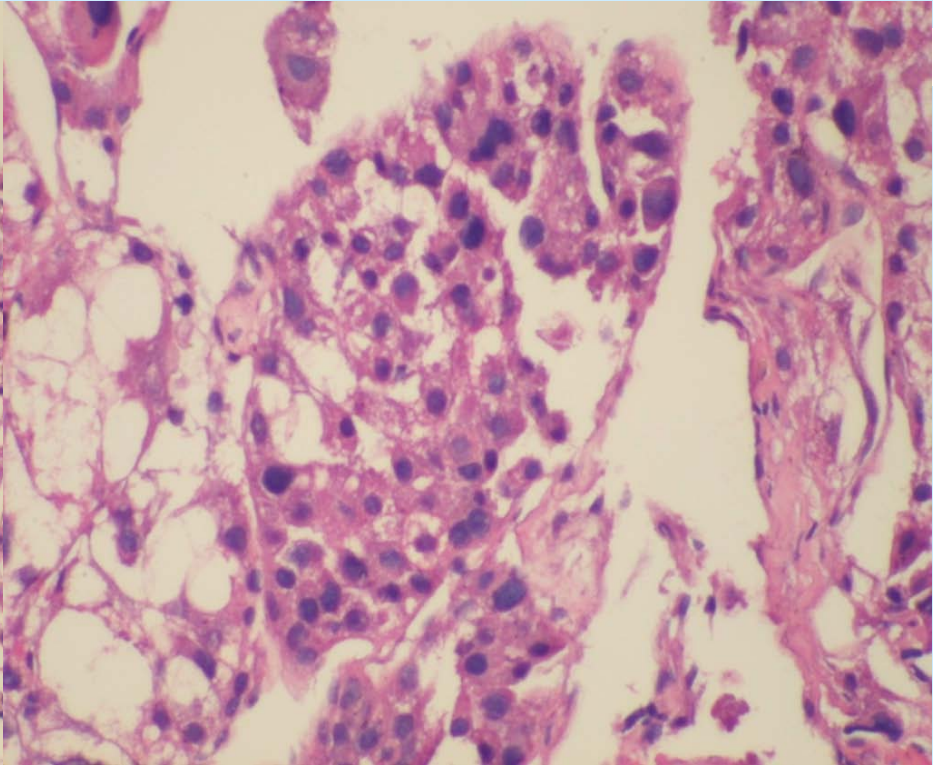
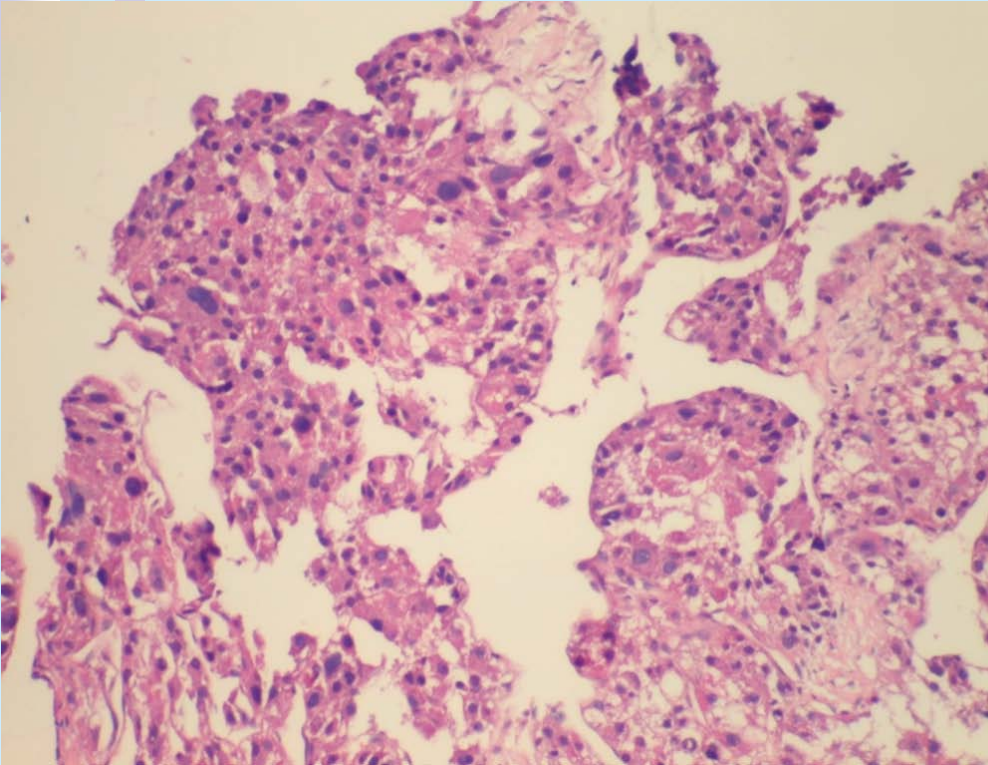
# Panoramic Film



# Clinical Impression

- **Metastatic neoplasm over right mandibular ramus, condyle and right masticator space, suspect HCC**
- **Needle biopsy was performed on 98.10.12**





# HP Report And Treatment

- **Hepatocellular carcinoma, metastatic over right masticator space**
- **98.10.14 consult**
  - **頭頸部 radiotherapy**



# Review 2000-2009

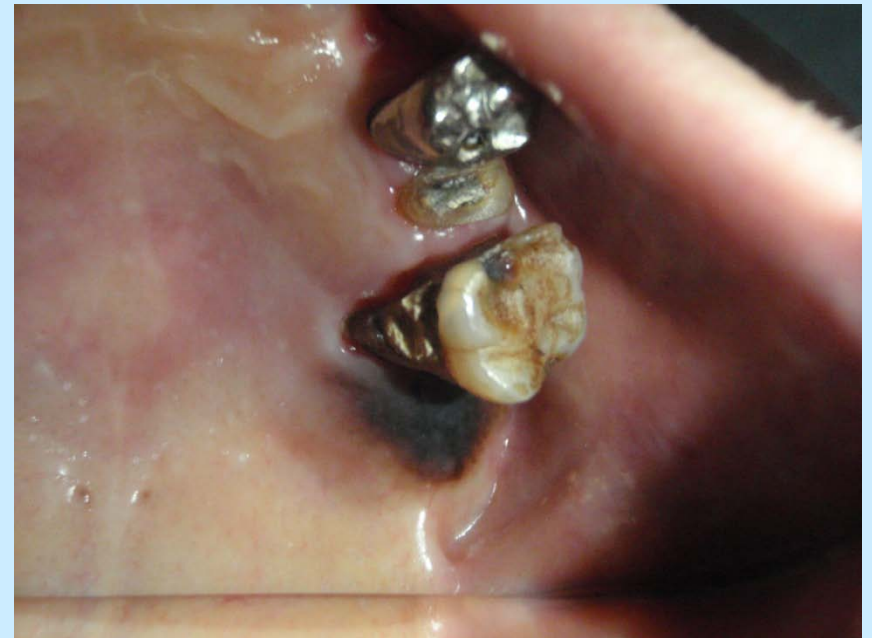<b>Oral Malignancy</b>	<b>2181 cases</b>	
<b>SCC+V Ca</b>	<b>2092 cases</b>	<b>96.0 %</b>
<b>MSGT</b>	<b>33 cases</b>	<b>1.5 %</b>
<b>Lymphoma, myeloma, leukemia</b>	<b>17 cases</b>	<b>0.8 %</b>
<b>Metastatic neoplasm</b>	<b>14 cases</b>	<b>0.6 %</b>
<b>Sarcoma</b>	<b>11 cases</b>	<b>0.5 %</b>
<b>Others</b>	<b>13 cases</b>	<b>0.5 %</b>

# Clinical Features

- **Age : > 50 y/o, mean: 61 y/o**
- **Gender : M:F = 13:1**
- **Site : Jaw bone – 6, Md:Mx = 5:1**  
**Soft tissue – 8, Gingiva (5/8)**
- **Primary tumor:**  
**HCC (9), Colon ca (3), Osteosarcoma (1)**  
**Lung(1, ?)**

# Case 8

- Name: 簡 O 輝
- Gender: Male
- Age: 77 y/o
- 初診日期: 98.12.18
- Chief complaint:  
A brownish lesion over  
upper right ridge



# Present Illness

- The 77 y/o male went to 陳慶長 LDC for oral examination. The dentist found a dark pigmented lesion over 17 edentulus area and suggested him to come to our OPD for further examination

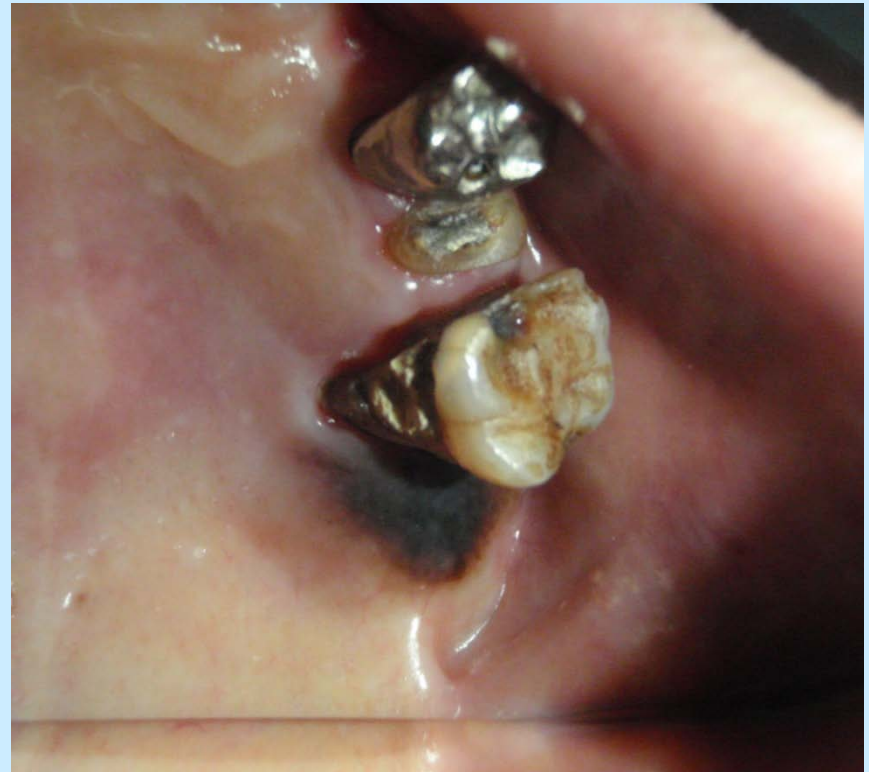

# Past History And Personal Habit

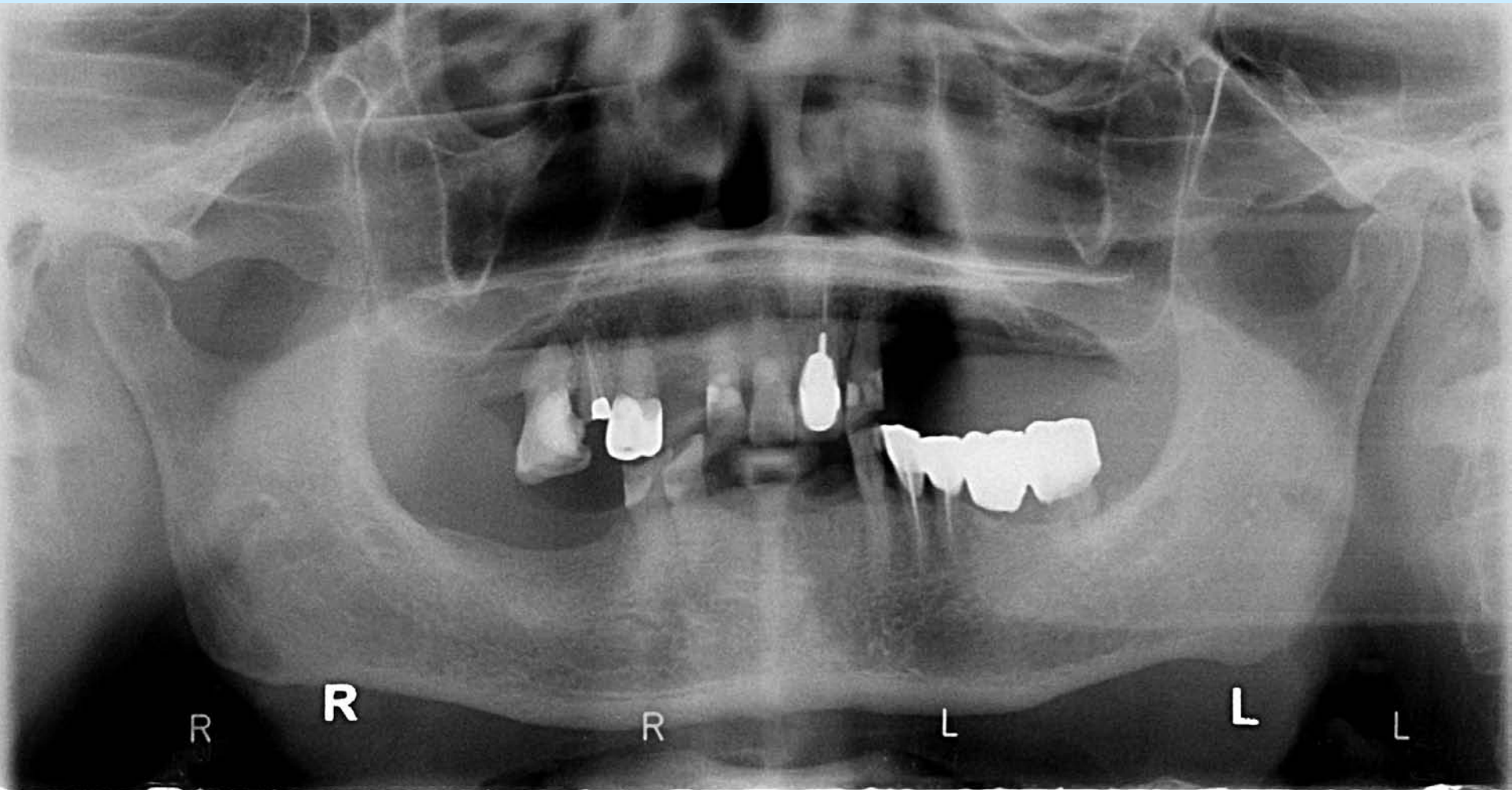
- **Past Medical history**  
DM
- **Drug Allergy: Nil**
- **Past dental history: NP**
- **Personal habits: A(-), B(-), C(-)**

# Intra-Oral Findings

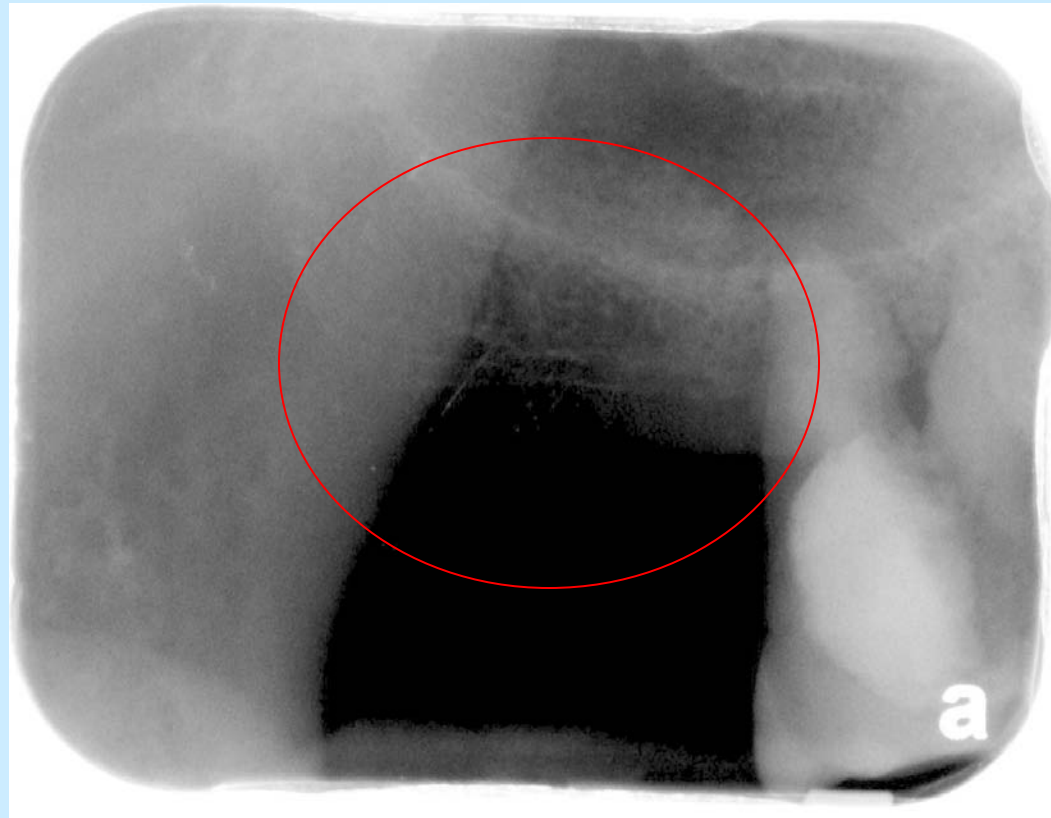
- **Size: 1.5 cm X 1.5 cm**
- **Surface: smooth**
- **Color: Dark brown to black**
- **Shape: Irregular**
- **Pain: (-)**
- **Tenderness: (-)**
- **Fluctuation: (-)**
- **Induration: (-)**



# Panoramic Film



# Periapical film – Bone Erosion



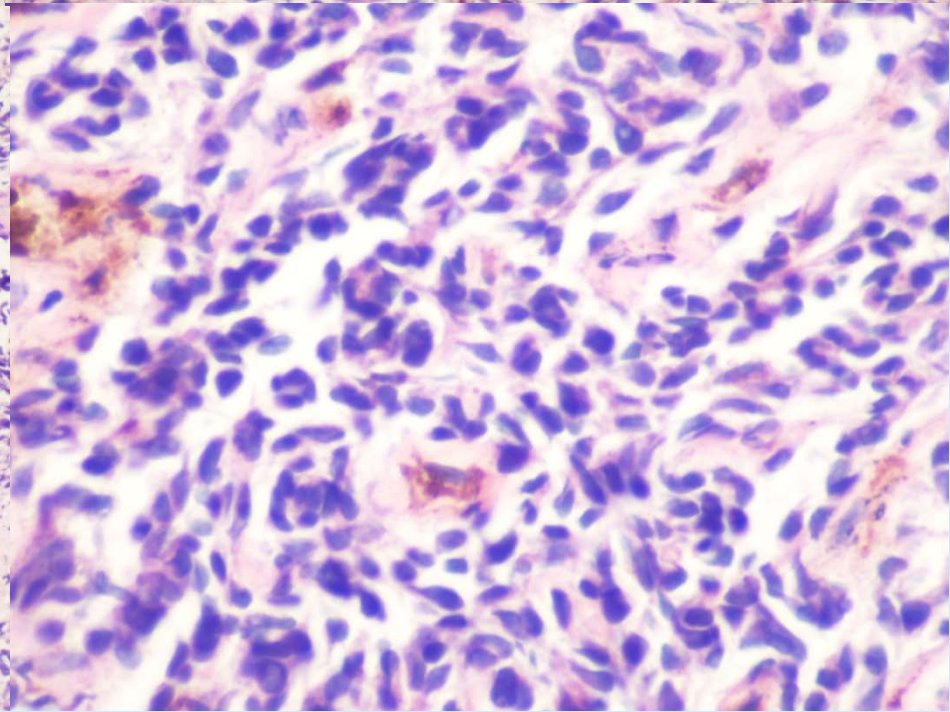
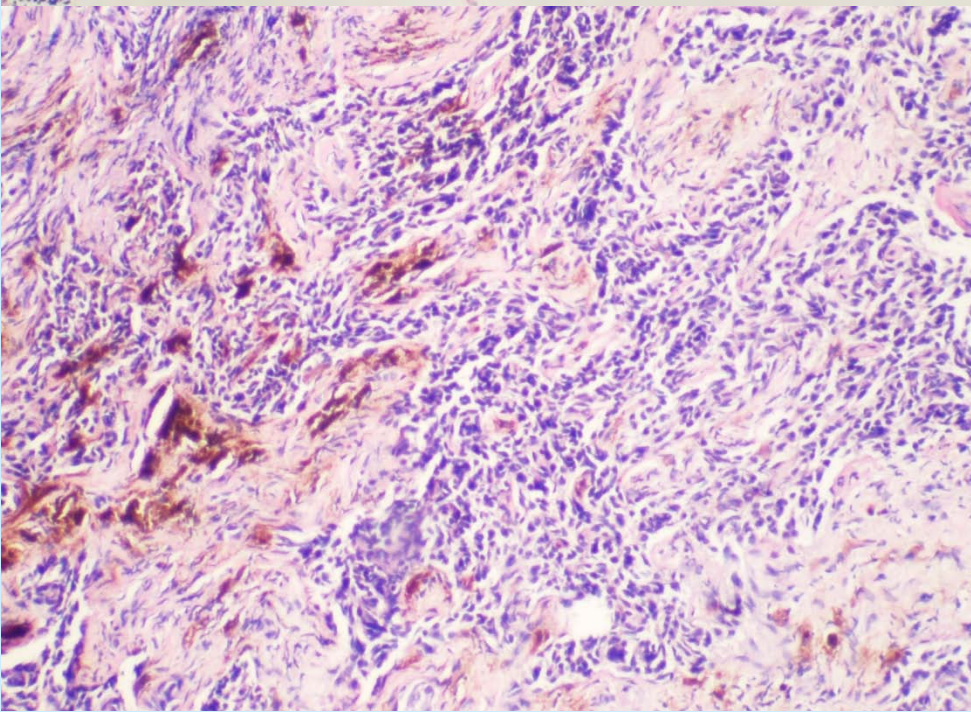
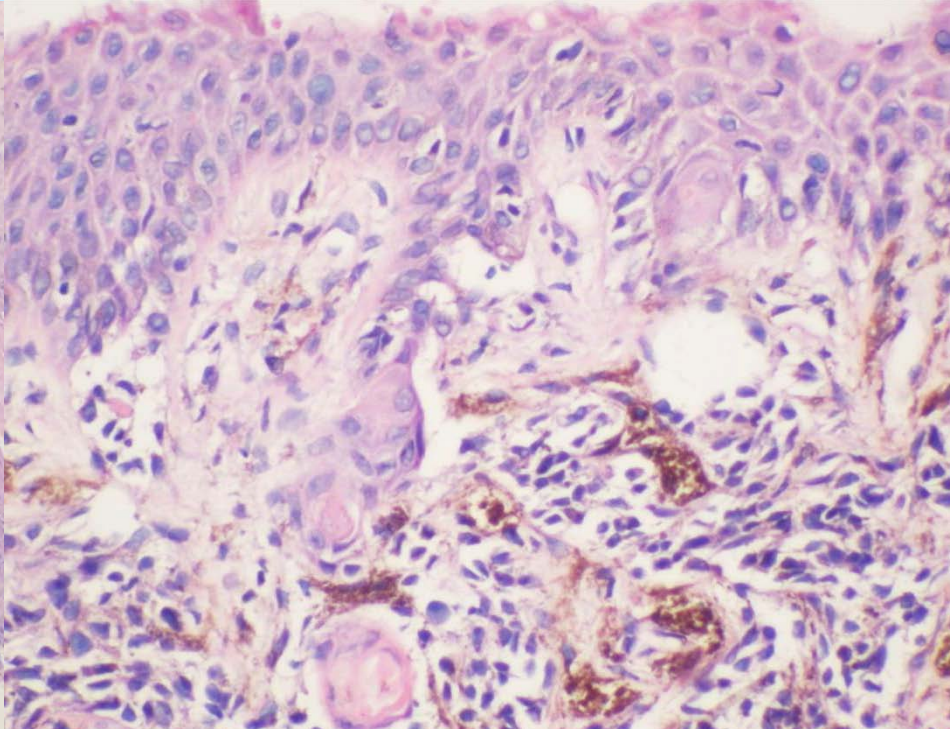
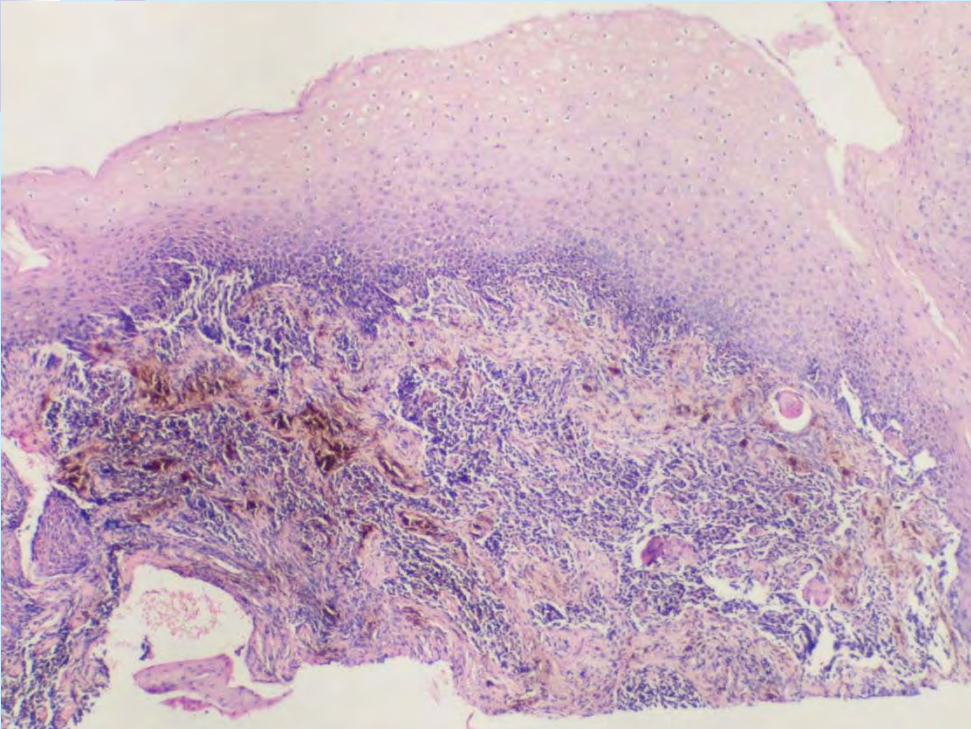




# **Clinical Impression**

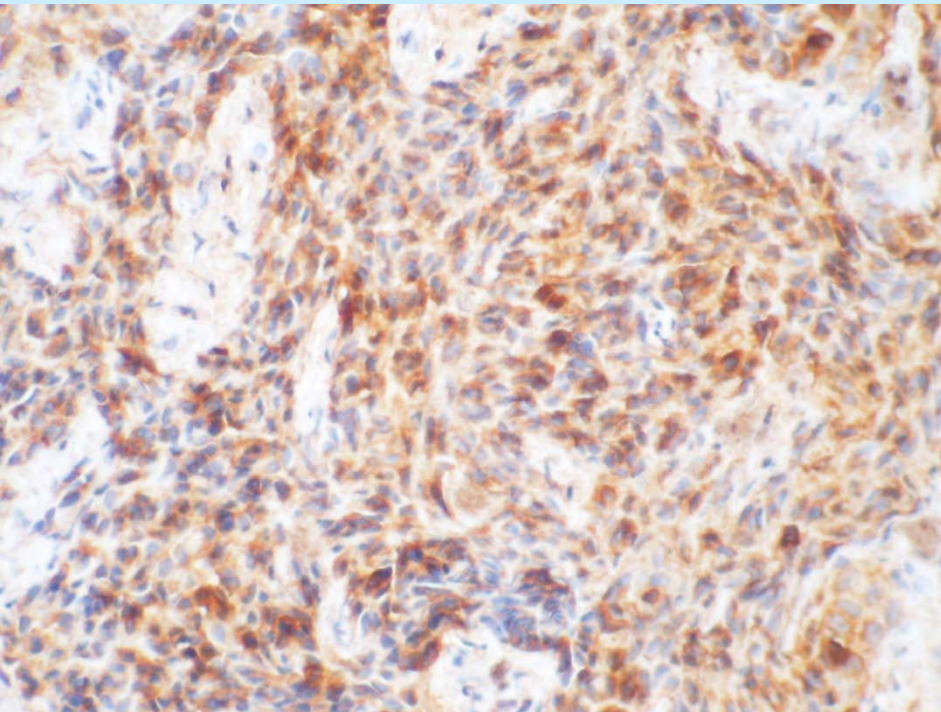
- **Melanoma over right tuberosity**



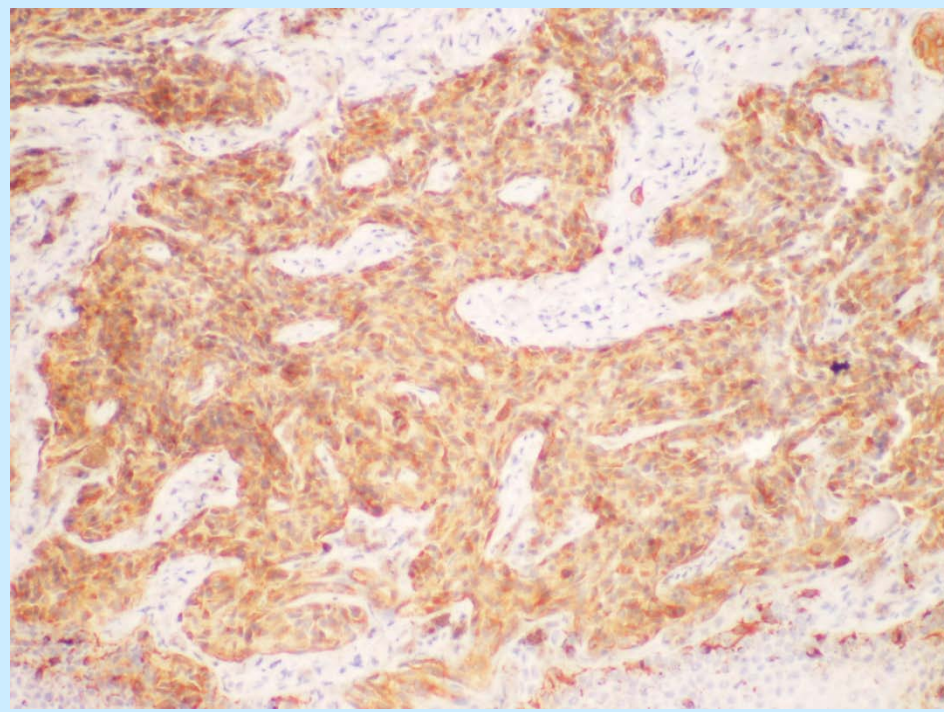




**S-100 (+)**



**HMB45(+)**





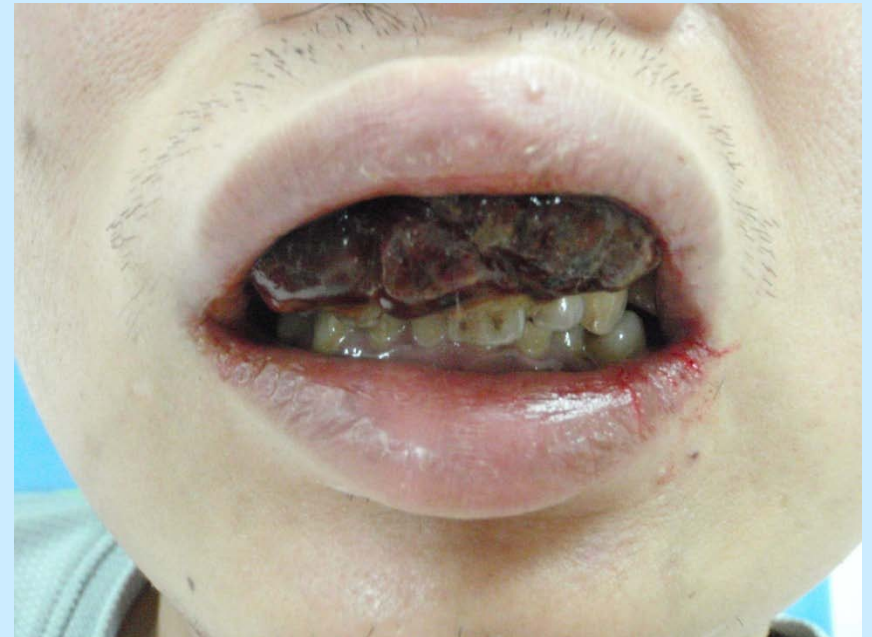# HP Report

- **Melanoma over right tuberosity**



# Case 9

- Name: 鄭 O 廷
- Gender: Male
- Age: 26 y/o
- 照會醫師: 施亦倫醫師
- 照會日期: 99.05.11
- Chief complaint:  
Multiple rapidly growing masses over gingiva of both arches



# Present Illness

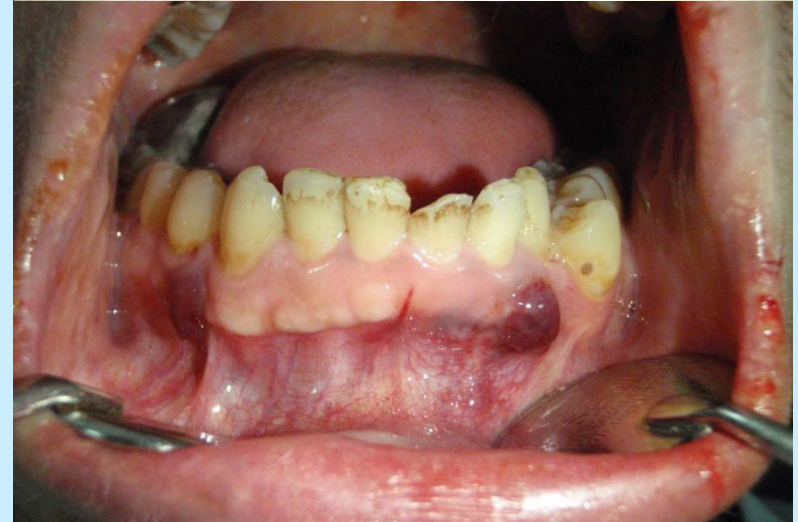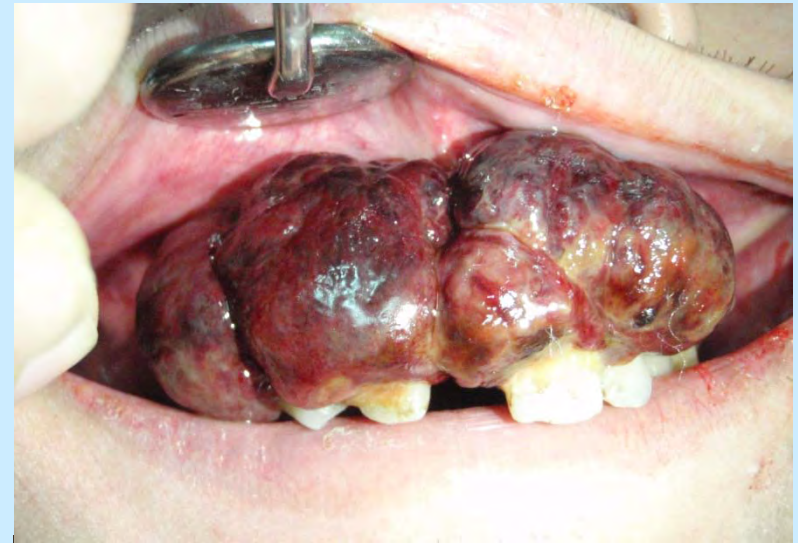- This 26 y/o male suffered from generalized swollen lymph nodes for past 3 weeks. Then gum swelling was noted within the past 2 weeks. He visited 義大H first. The condition did not improve so he changed to our Hema dept. for further investigation and management.

# Past History And Personal Habit

- **Past Medical history**  
NP
- **Drug Allergy: Unknown**
- **Past dental history: NP**
- **Personal habits: A(?), B(?), C(?)**

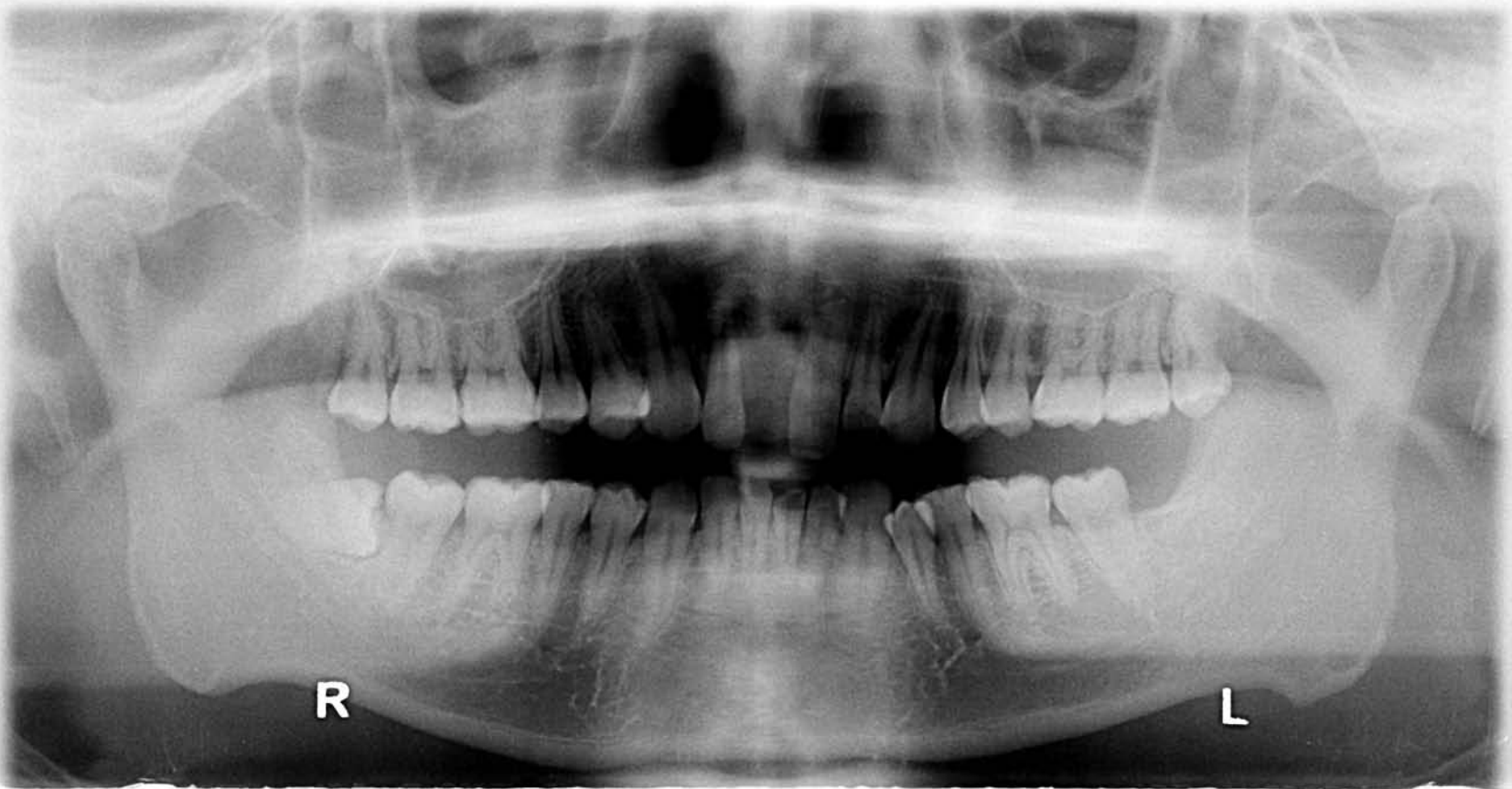# Intra-Oral Findings

- **Size: 6 X 3 cm in max. dimension**
- **Surface: ulcerated**
- **Color: Red to Dark brown**
- **Shape: polypoid , lobulated**
- **Pain: (+)**
- **Easily bleeding**





# Panoramic Film



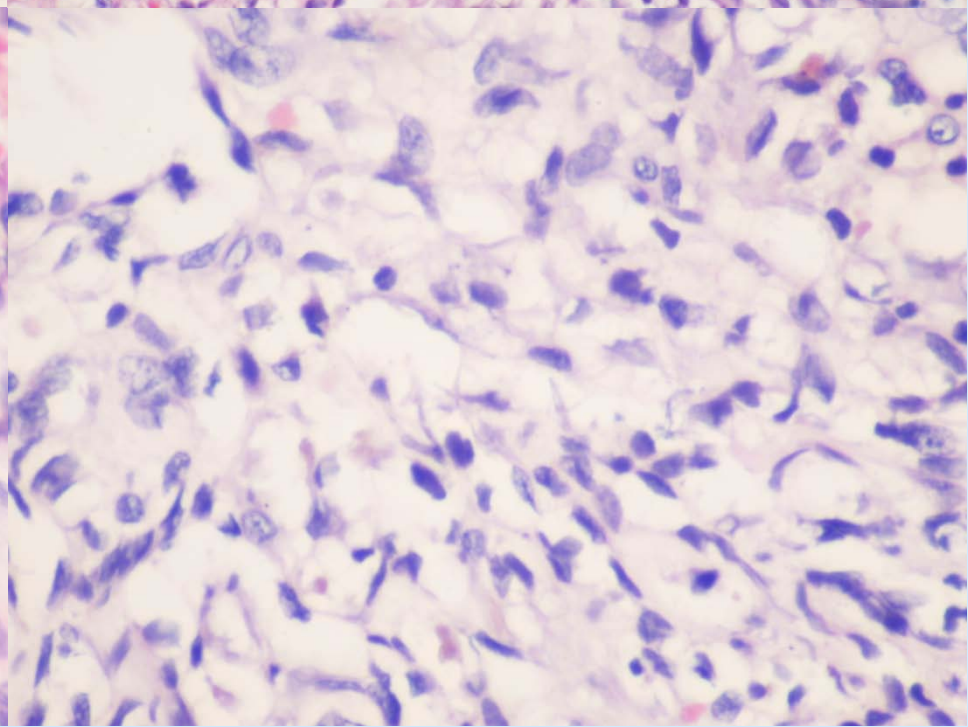
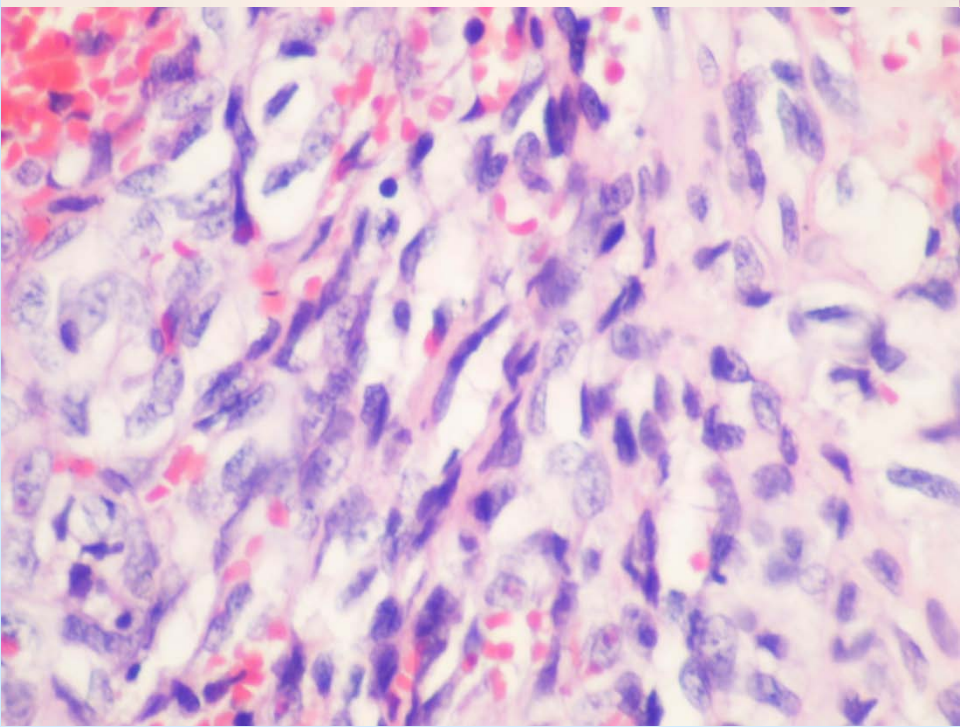
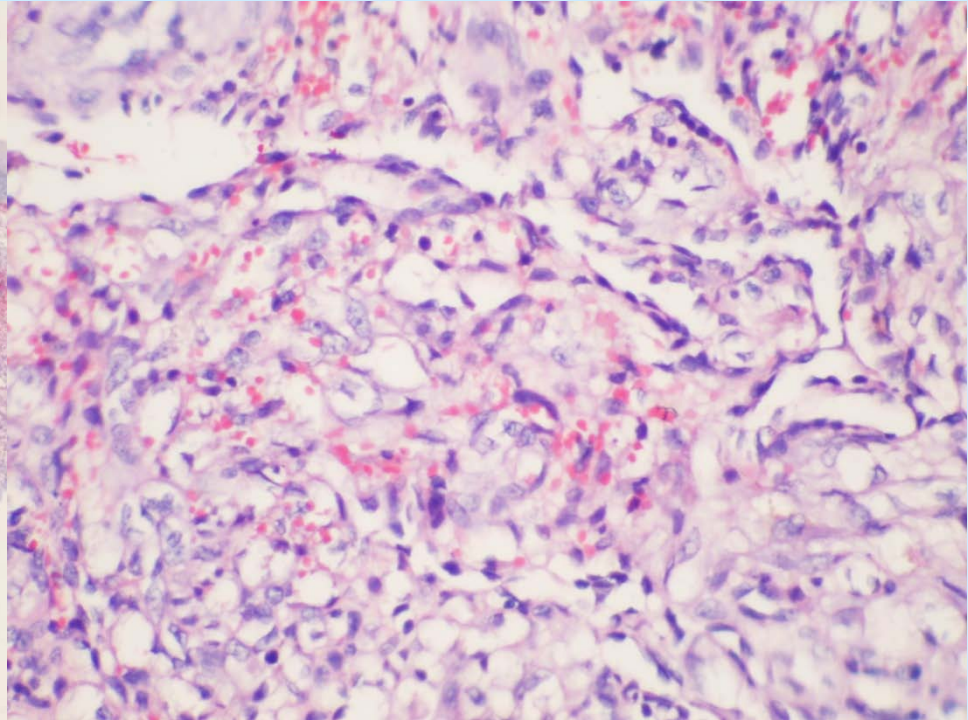
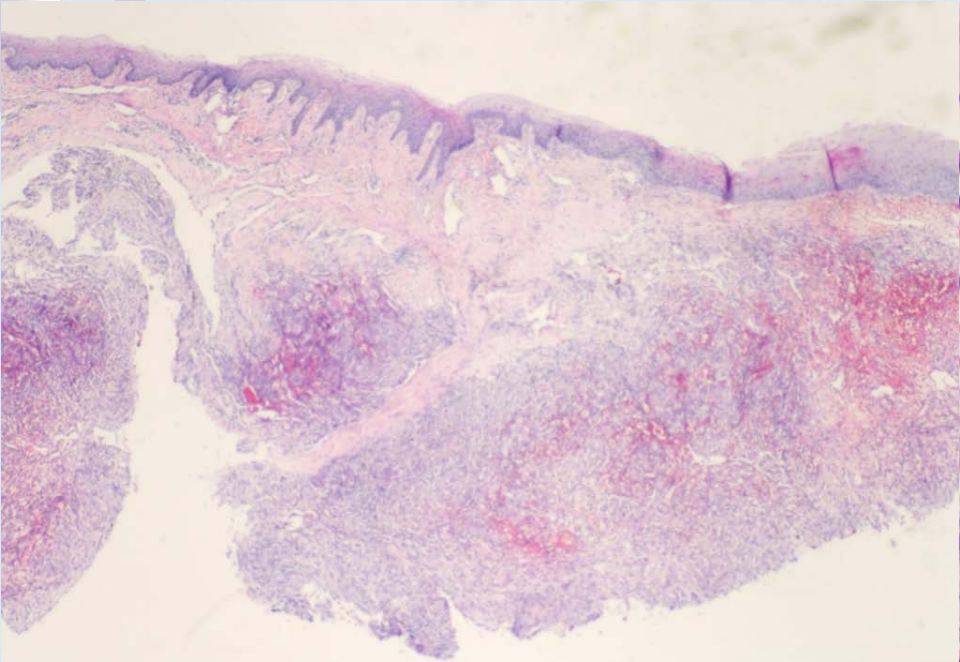


# Lab Data

- HIV (-)

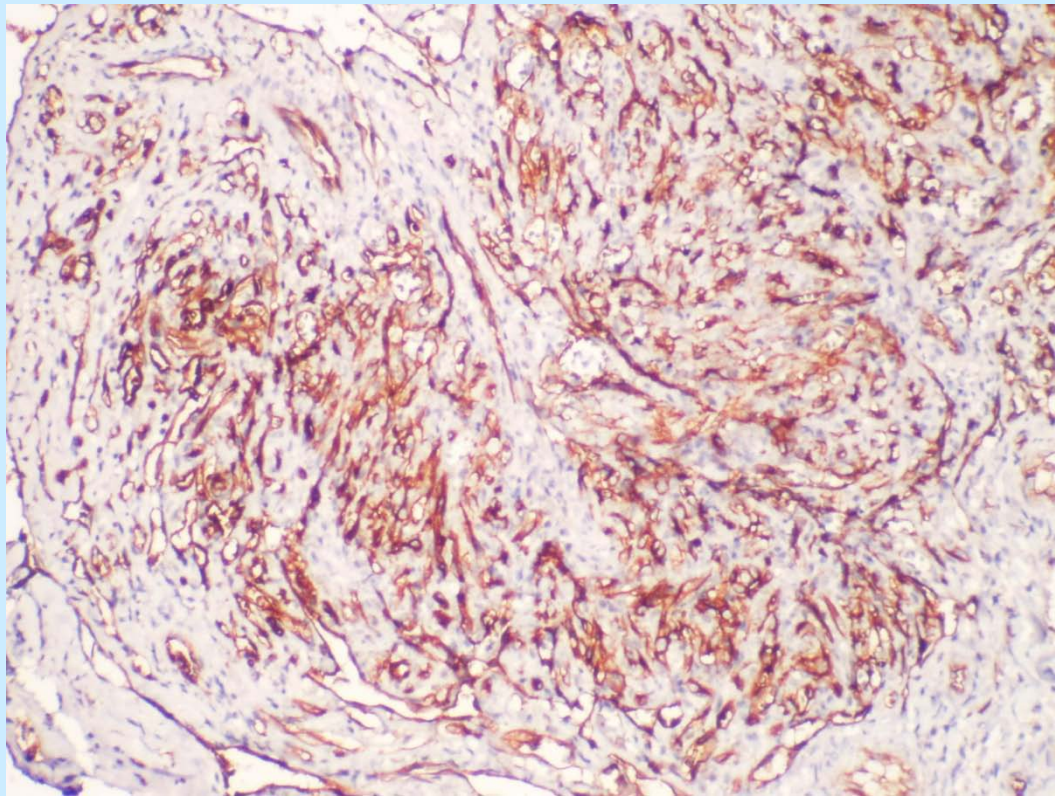
# Clinical Impression

- **Kaposi 's sarcoma over upper anterior gingiva and lower left (tooth 33) gingiva**





**CD34(+)**



# HP Report

- **Angiosarcoma, compatible with Kaposi 's sarcoma over upper anterior and lower left gingiva**
- **HHV8(+)** (病理科)