95年度口腔病理科十大病例報告

報告者:　陳靜怡　第二年住院醫師
指導醫師: 林立民教授
陳玉昆主任
王文岑主治醫師
報告日期: 2007.05.31

Case 1

- Name : 王 X X
- Gender : Female
- Age : 25
- First visit : 96.01.02

- Chief complaint

  A white mass over anterior right tongue border for 4 months

- Present Illness

  This 25 y/o female found a painless white nodule over her anterior right tongue tip for 4 month. The lesion became larger recently, so she came to OM OPD for further evaluation.

Past History

- **Past medical history**

  1. Systemic disease: Denied

  2. Hospitalization: Nil

  3. Drug allergy: Denied

- **Past dental history : NP**
- **Oral habits: Nil**

Intra-oral Findings

- **A dome-shaped, painless nodule over anterior R't tongue border**

  1. Dimension:0.5x0.3 cm

  2. Color: whitish

  3. Surface: smooth

  4. Consistency: rubbery

  5. Sessile

  6. Tenderness(-)

  7. Induration(-)

Treatment course

- **96.01.02**

  Clinical impression: Fibroma, R/O other mesenchymal benign tumors over right tongue border

  Referred to OS -- excisional biopsy, sent for histopathological exam.

- **96.01.09 and 96.01.13 -- post-op follow up.**

Microscopic Examination – 1

Pseudoepitheliomatous hyperplasia – acanthosis, basal layer hyperplasia, hyperparakeratosis

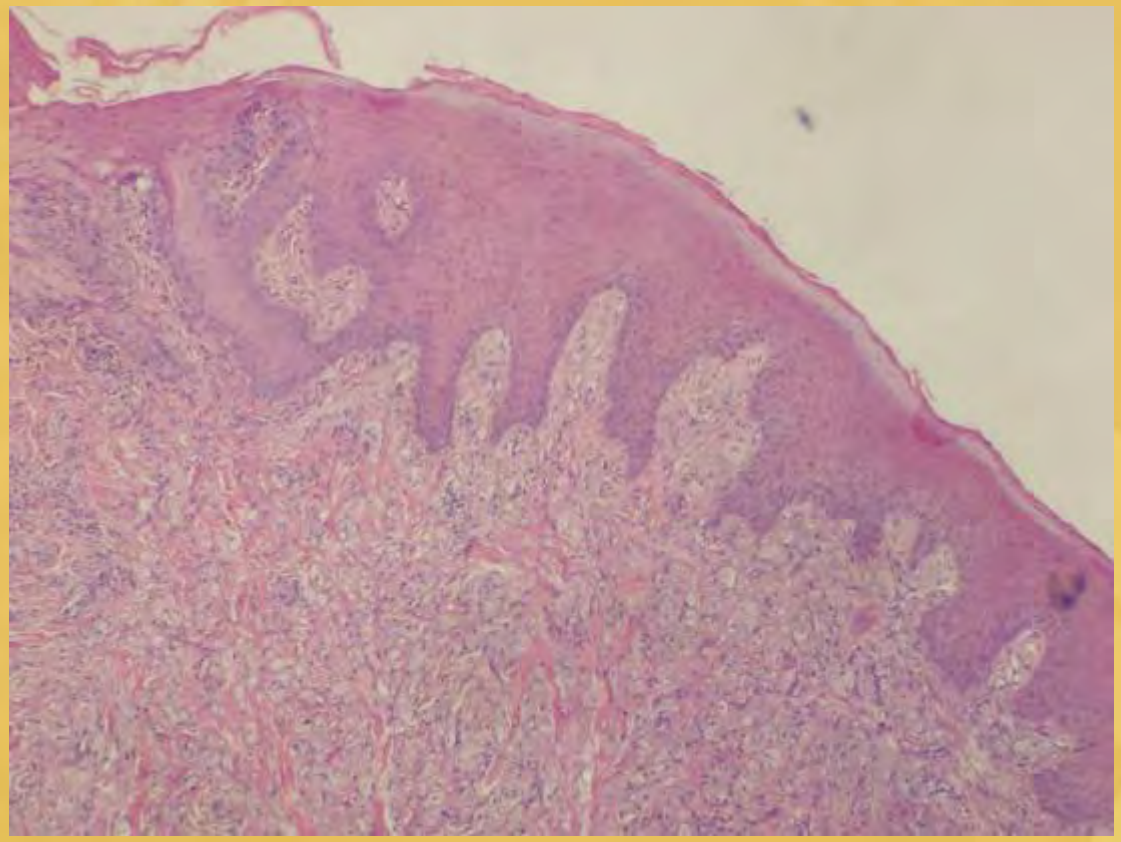

Microscopic Examination – 2

Granular cells – polygonal cells with granular eosinophilic cytoplasm, mixing with muscle fibers.

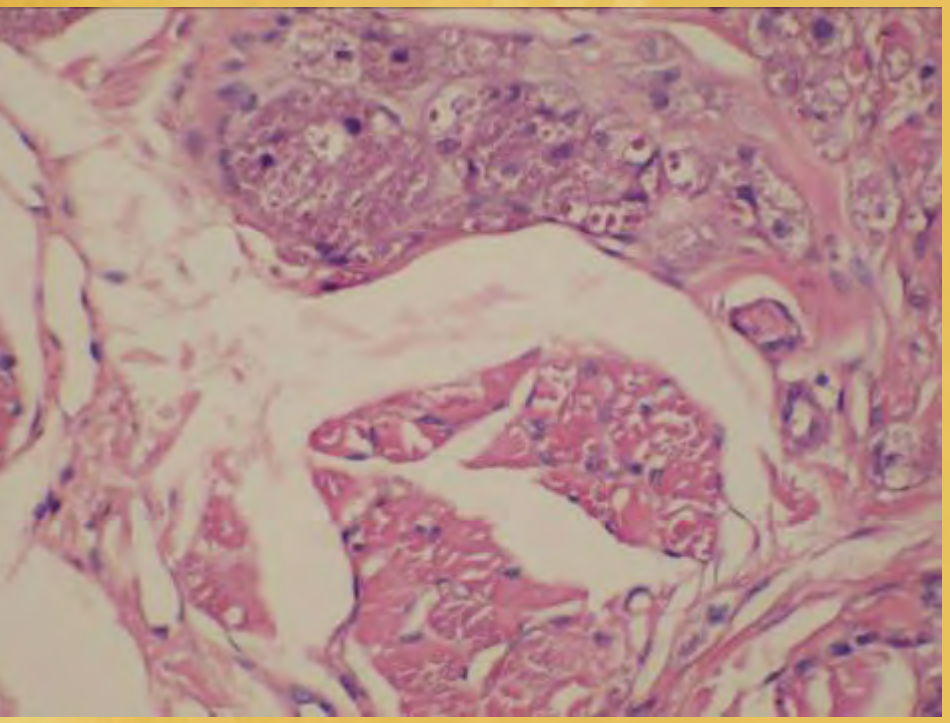

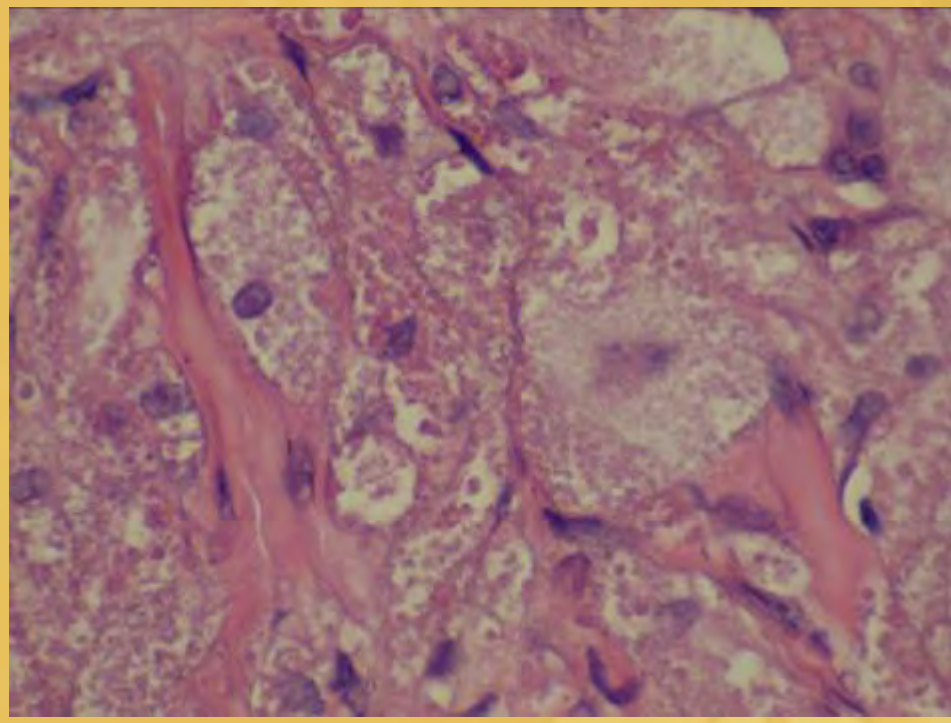

Immunohistochemical Stain

S-100(+)

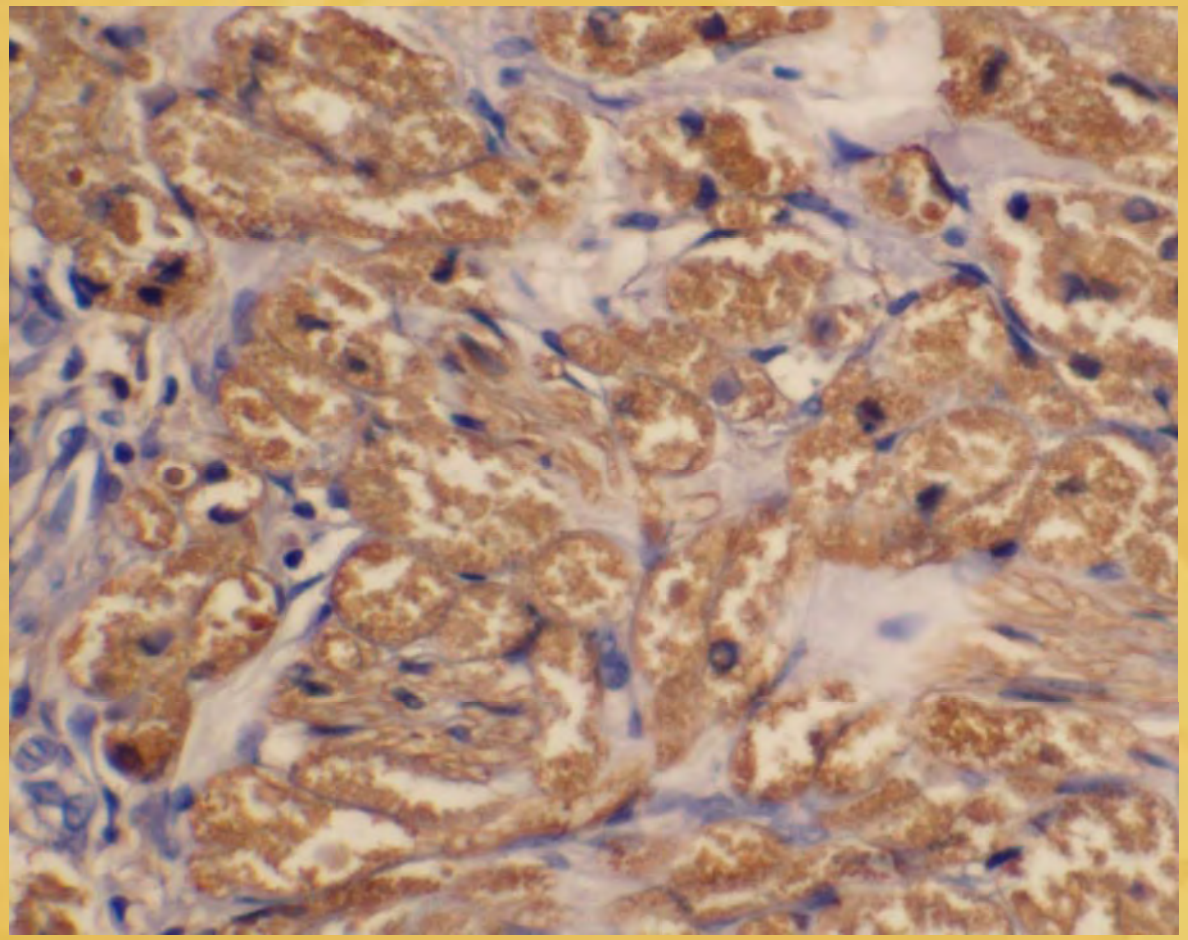

Final Diagnosis

- **Granular cell tumor**

  Oral cavity, Tongue border, Right anterior, Excision

Discussion

- **Immunohistochemical stain: S-100(+), suggest originating from Schwann cells or their precusors.**

- **Clinical features**

  1. 50% in head and neck region; 60% in tongue

  2. Predilection for female and blacks
- **Prognosis: good**
- **Recurrence: rare**

Case 2

- **Name : 沈 X X**
- **Gender : Male**
- **Age : 52**
- **First visit : 95.10.20**

- **Chief complaint**

  Bilateral swelling mass over mouth floor for about one year.

Present Illness

- **This 52 y/o male found bilateral swelling masses over mouth floor for about one year. He went to a hospital in Australia and biopsy was done. The histopathological report indicated that the lesion may originated from endocrine (protein) problem. He was suggested to accept further evaluation and treatment so he came to OS OPD on 95.10.20.**

Past History

- **Past medical history**
  1. **Systemic disease: HCV**
  2. **Hospitalization: 中耳炎**
  3. **Drug allergy: Denied**

- **Past dental history : NP**
- **Oral habits: A(-), B(?), C(-)**

Intra-oral Findings

- **Bilateral painless dome-shaped mass over mouth floor (sublingual gland)**

  1. Dimension: 6x5 cm

  2. Color: white

  3. Surface: smooth

  4. Consistency: firm

  5. Sessile

  6. Tenderness(-)

  7. Lymphadenopathy(-)

Treatment Course

- **95.10.20**

  Clinical impression : Salivary gland tumor induced by systemic problem, left mouth floor

  Incisional biopsy and sent for histopathological exam.

- **95.10.27 -- post-op follow up and HP report.**

Microscopic Examination – 1

Rete ridge atrophy of stratified squamous epithelium, hyperorthokertosis

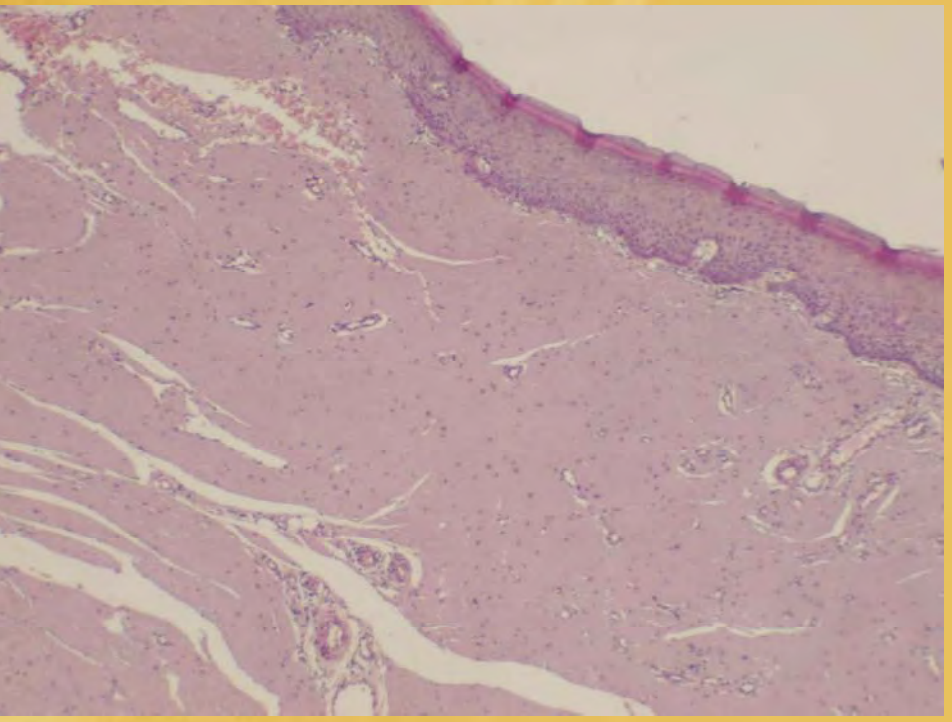

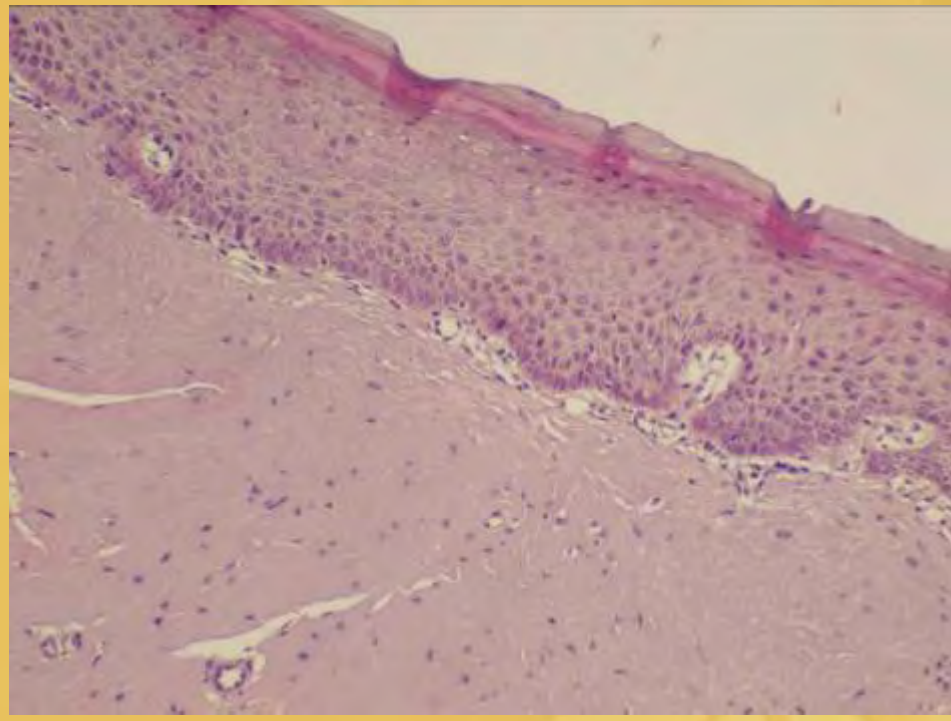

Microscopic Examination – 2

Large amount of amorphous, acellular, eosinophilic, homogeneous substance depositing in the fibrous connective tissue

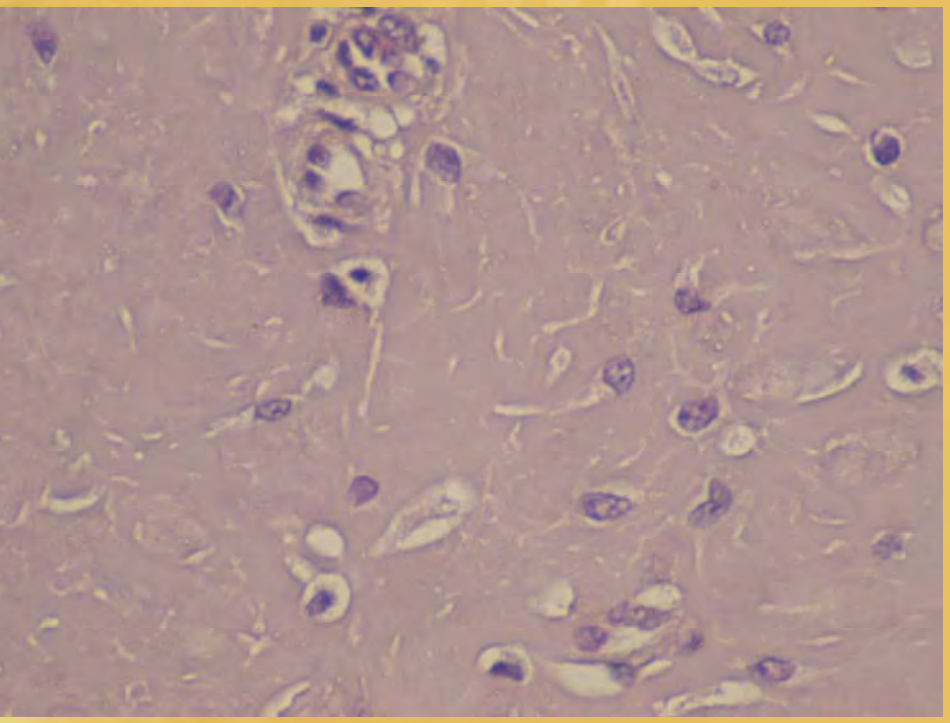

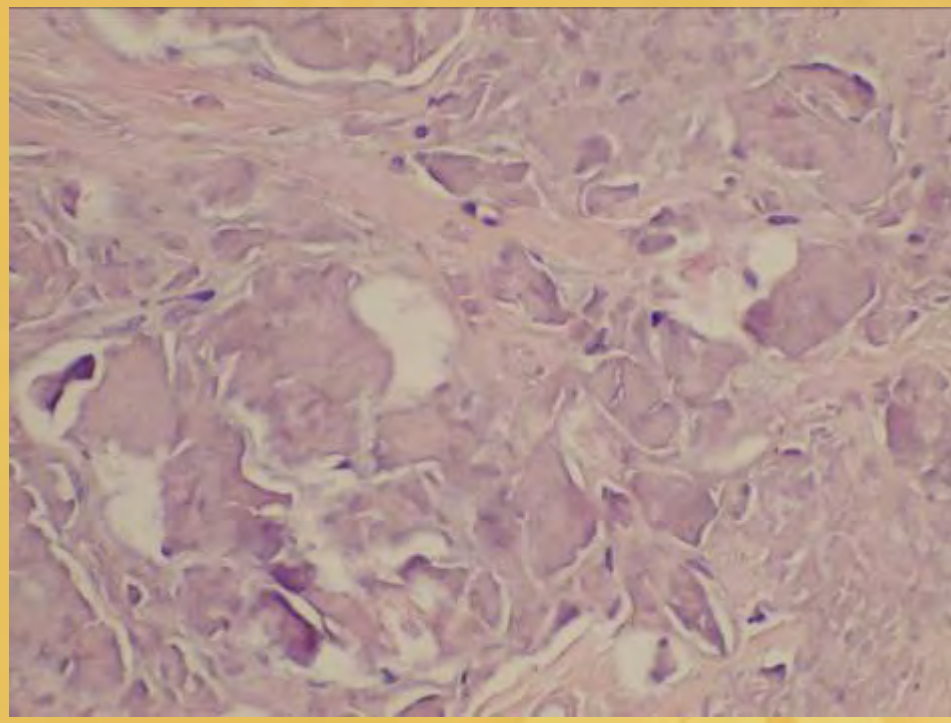

Histochemical Stain

Congo red (+), amyloid indicated

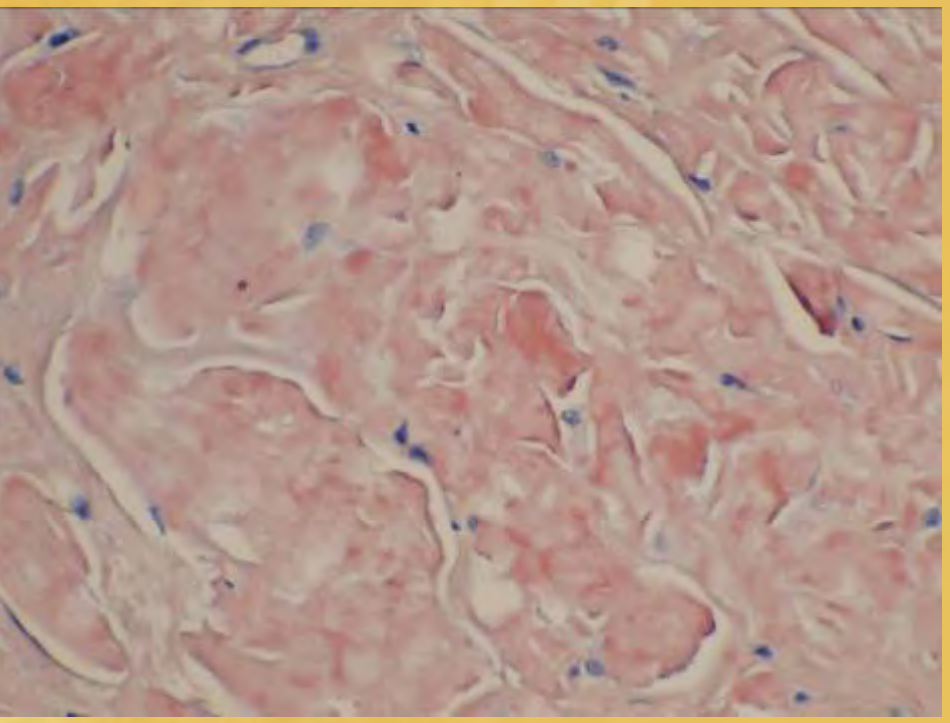

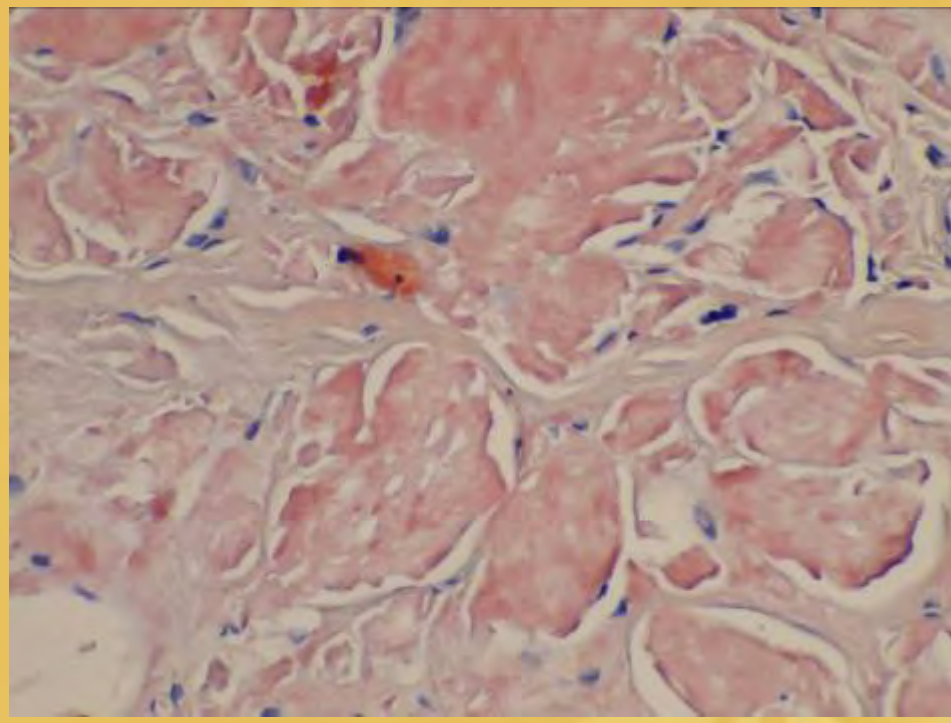

Final Diagnosis

- **Amyloidosis**

  Oral cavity, Mouth floor, Left, Excision

- **Referred to 血液腫瘤內科 for further evaluation and treatment.**

  1. R/O multiple myeloma

  2. Lab survey to determine type

Discussion

- **Oral manifestations – macroglossia, amyloid nodules**
- **Amyloidosis – extracellular deposition of amyloid**

Organ-limited – rare in oral soft tissue

Systemic

1. **Primary**
2. **Myeloma-associated**
3. **Secondary – a result of chronic inflammatory condition, eg: tuberculosis, osteomyelitis**
4. **Hemodialysis-associated**
5. **Heredofamilial (遺傳)**

Case 3

- **Name : 楊X X**
- **Sex : 男**
- **Age : 34 y/o**
- **First visit :95.01.16**

- **Chief Complaint**

  Pain and skin perforation over lower loeft face, left mandible exposure

Present Illness -- 1

- **95.01.16**

  This 34 y/o male suffered from trismus and painful white lesion over lower left buccal gingiva for 2 months. He came to OS OPD and incisional biopsy was performed.

Incisional Biopsy

- **Epithelial displasia with hyperkeratosis**

  Oral cavity, Gingiva, Lower left, Incision

- **P’t refused to accept further treatment and lost follow up.**

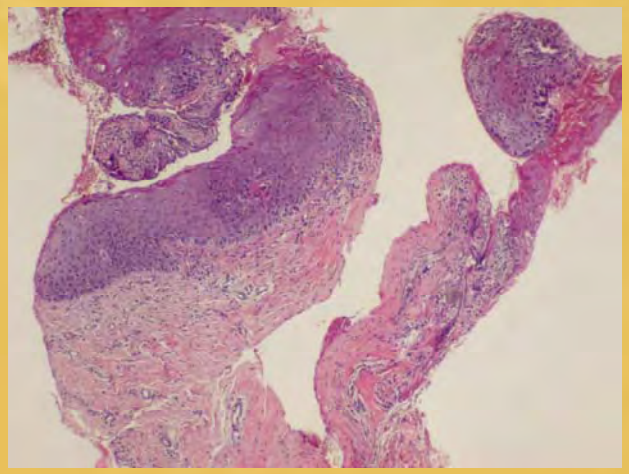

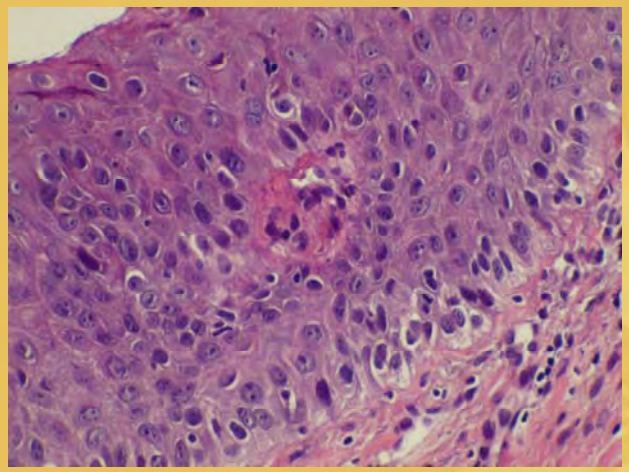

Present Illness -- 2

- 95.07~95.12

The lesion persisted and the patient went to 阮綜合hospital for help in 95.07. Biopsy was performed and the HP report was squamous cell carcinoma over left buccal mucosa. Then he accepted R/T and C/T in 阮綜合 hospital.

- 96.02.07

The patient came to our OPD due to left buccal skin perforation and mandible exposure.

Past History

- **Past medical history**

  1. Systemic disease: Denied

  2. Hospitalization: Nil

  3. Drug allergy: Denied

- **Past dental history : NP**
- **Oral habits:A(-), B(+), C(+)**

OMF Findings

- **Ulcerative lesion and perforation over left buccal skin with mandible exposure, about 6x4 cm in dimension, Pain(+), Induration(+)**
- **Two ulcerative lesions over lower border of right mandible with bone exposure**
- **Severe Trismus**

X-Ray Findings -- Panorex

Treatment Course

- **96.02.07**

  Clinical impression: Squamous cell carcinoma over left buccal mucosa s/p R/T and C/T

  Osteoradionecrosis over right mandible

- **96.05.04 – Operation**

  1. Wide excision + segmental resection

  2. Free flap reconstruction

Microscopic Examination -- 1

Keratin pearl formation, pleomorphism, hyperchromatism, abnormal mitosis, individual cell keratinization

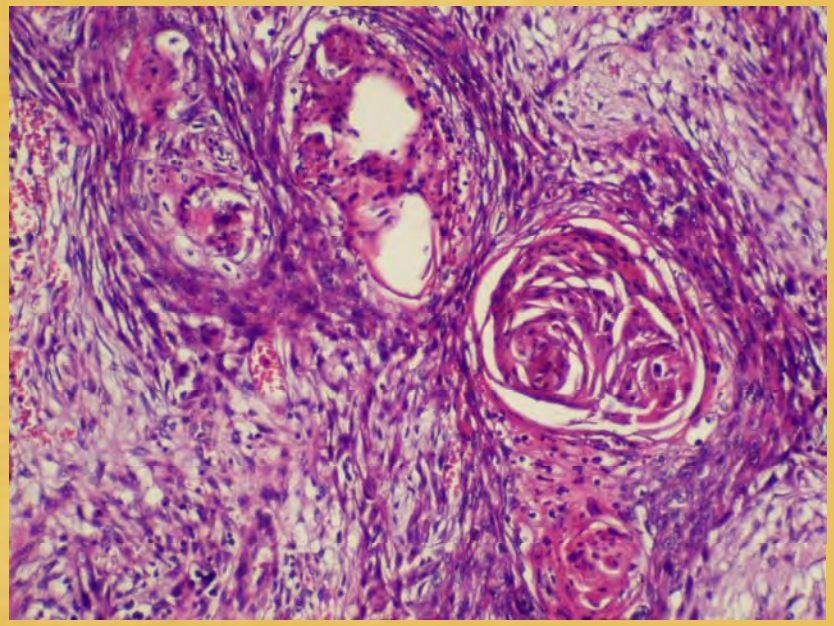

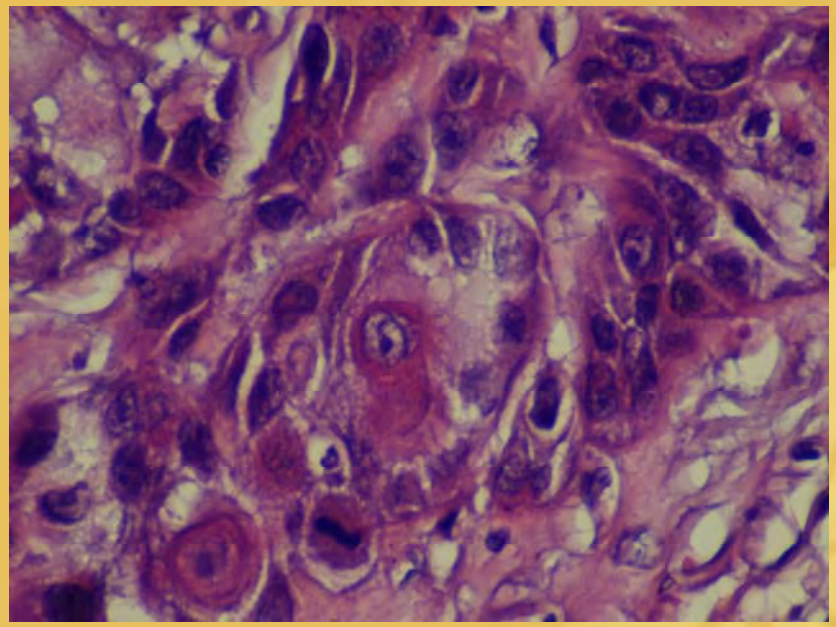

Microscopic Examination -- 2

Fat tissue invasion (+)

Perineural invasion (+)

Perivascular invasion (+)

Bone invasion (+)

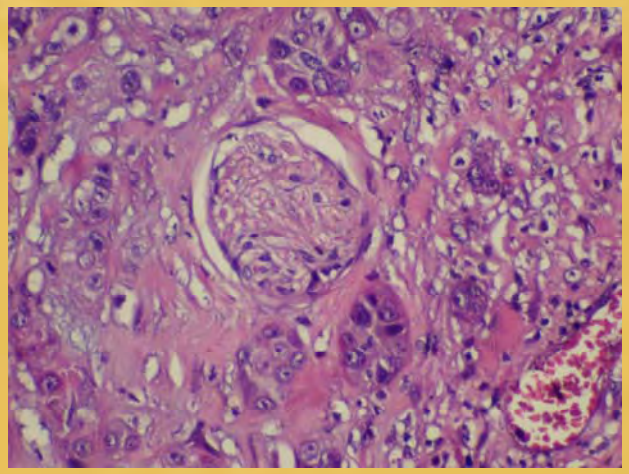

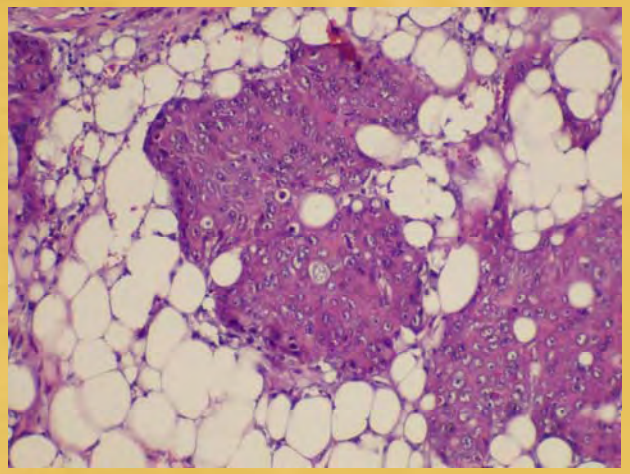

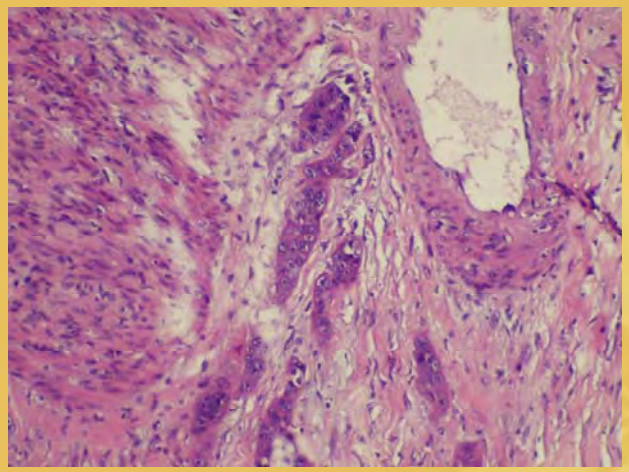

Final diagnosis

- **Squamous cell carcinoma, grade I, T4N0M0, stage IV**

  Oral cavity, Buccal, Left, Excision

  Bone, Mandible, left, Segmental resection

Case 4

- **Name : 林X X**
- **Sex : 男**
- **Age : 25 y/o**
- **First visit :95.08.30**

- **Chief Complaint**

  A mass over left side of maxilla was accidentally found via CT exam of head

Present Illness

- **This 25 y/o male patient was hospitalized in plastic ward due to traffic accident on 95.08.16. A large mass occupied his left maxillary sinus and maxilla was accidentally found via CT exam. The biopsy was consulted by plastic department under general anesthesia on 95.08.18.**

- **According to his family's statement, he had allergic rhinitis but never had the experience of discomfort over left side of maxilla and nose.**

Past History

- **Past medical history**

  1. Systemic disease: Denied

  2. Hospitalization: left supraorbital rim fracture

  3. Drug allergy: Denied

- **Past dental history : NP**
- **Oral habits: Nil**

OMF Findings

- **Extra-oral findings**

  Slightly swelling over left infraorbital area with ecchymosis
- **Intra-oral findings**

  1. Bone expansion(+)

  2. Covering mucosa: intact

  3. Pain(-)

  4. Tenderness(-)

  5. Pus or discharge(-)

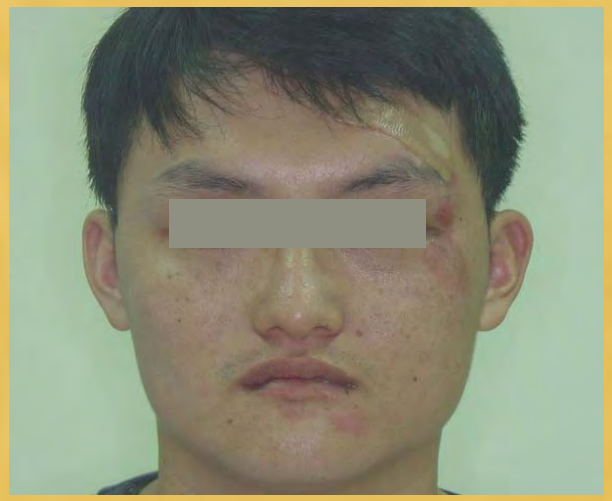

X-Ray Findings -- Panorex

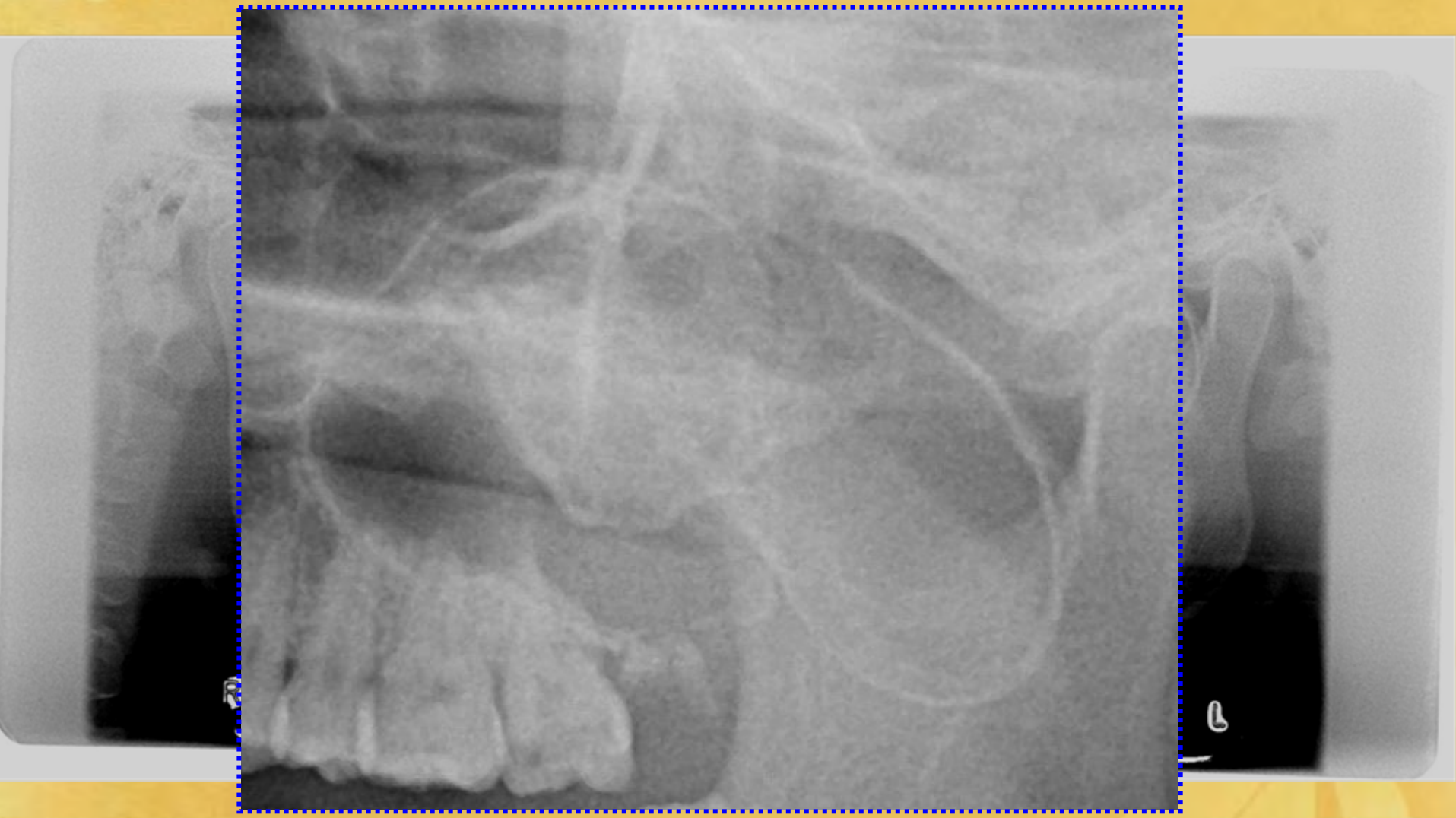

CT Findings

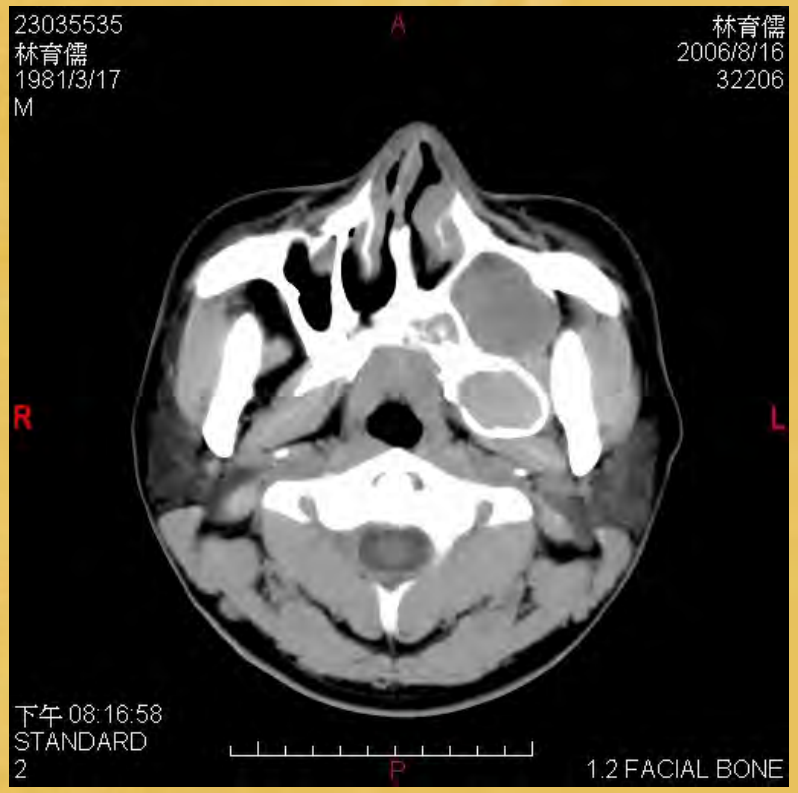
23035535
林育儒
1981/3/17
M
A
林育儒
2006/8/16
32206
R
L
下午 08:16:58
STANDARD
2
P
1.2 FACIAL BONE

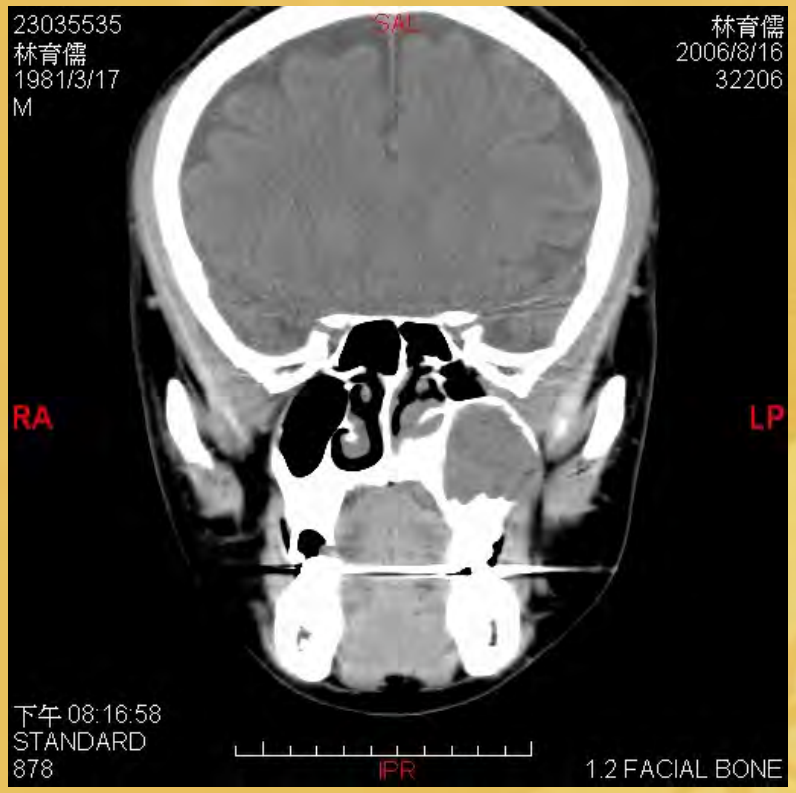
23035535
林育儒
1981/3/17
M
SAL
林育儒
2006/8/16
32206
RA
LP
下午 08:16:58
STANDARD
878
IPR
1.2 FACIAL BONE

Treatment Course

- **95.08.18**

  Consulted by plastic dept., -- incisional biopsy under GA, sent for histopathological exam

- **95.08.30**

  OS OPD for further management, arrange OP on 95.09.28

Microscopic Examination -- 1

Cyst Formation

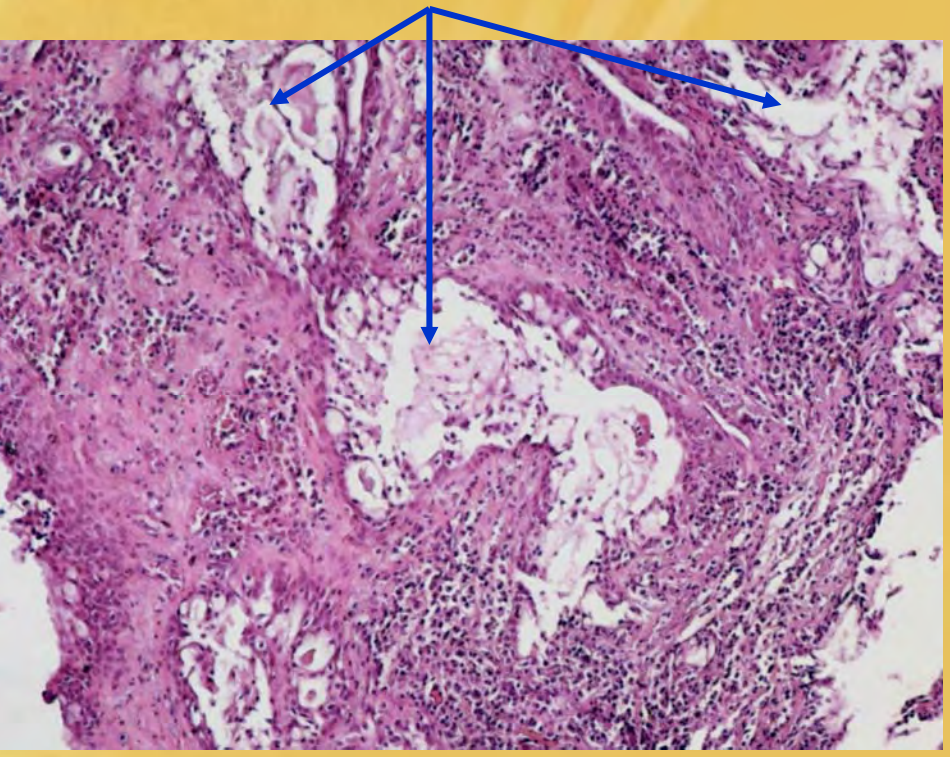

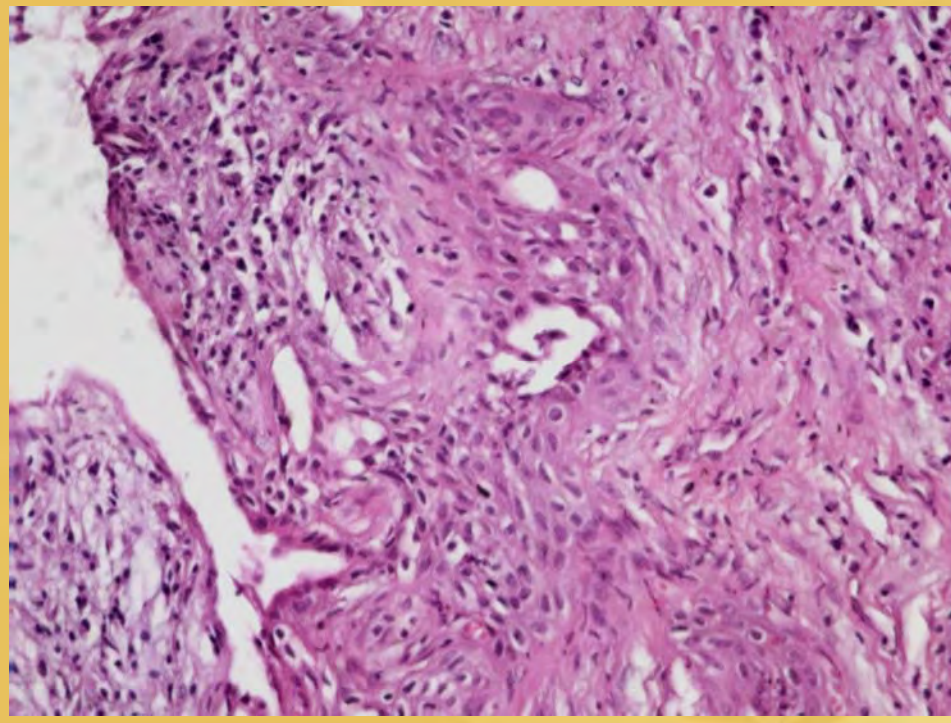

Microscopic Examination -- 2

Mucous producing cells

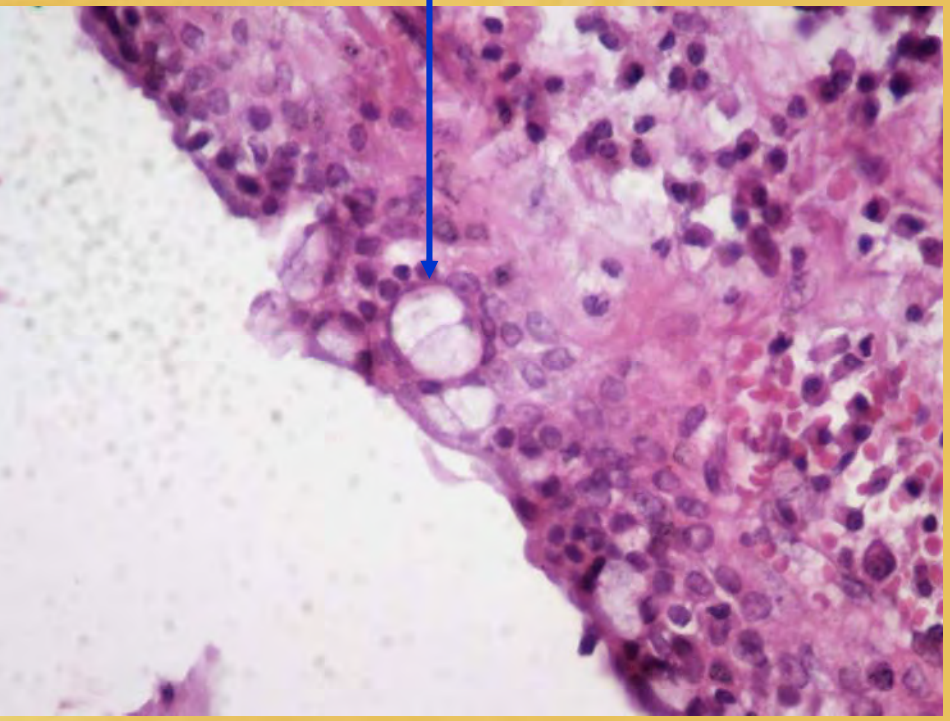

Epidermoid cells

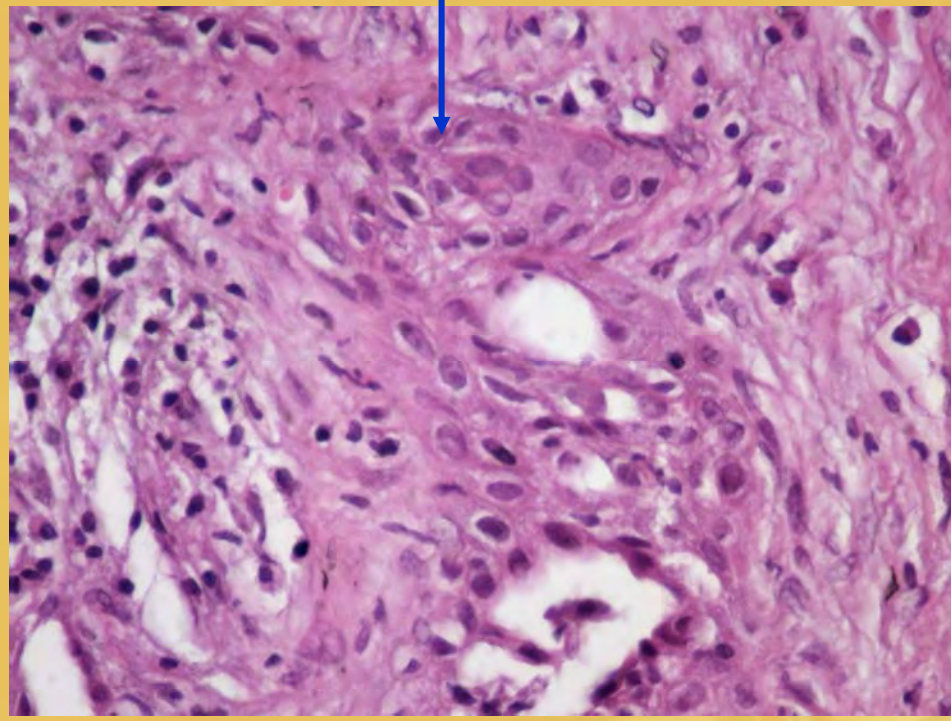

Immunohistochemical Stains

Cytokeratin(+)

EMA(+)

Mucicarmine(+)

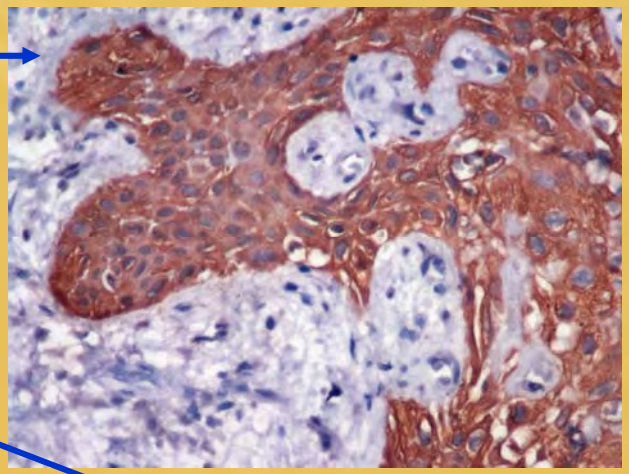

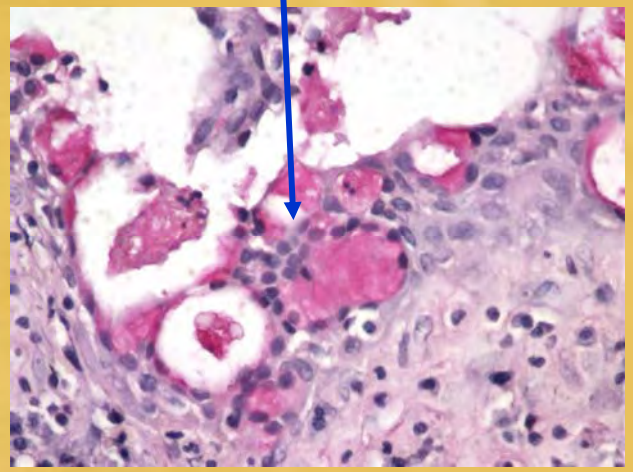

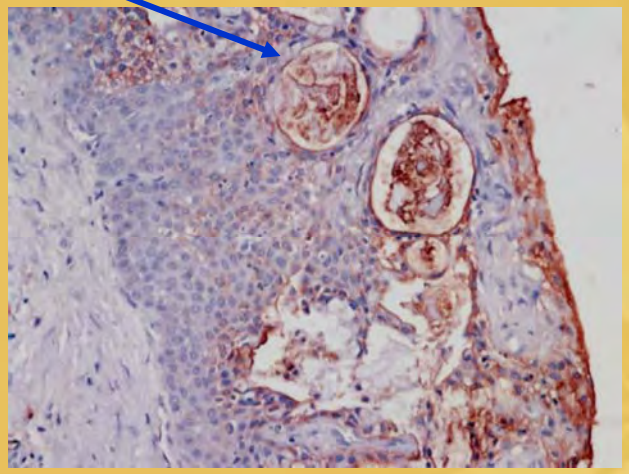

HP Report -- Incisional

- **Mucoepidermoid carcinoma, low grade**

  Sinus, Maxillary, Left, Incision

  Minimal histological change

  Bone, Maxilla, Left, Incision

- **95.09.28**

  Hospitalization and operation -- partial maxilloectomy

Final Diagnosis

- **Mucoepidermoid carcinoma, low grade**

  Sinus, Maxillary, Left

  Partial maxilloectomy
- **Criteria of pathological grading**

  1. Cyst formation (↑)

  2. Relative numbers of mucous cells (↑) , epidermoid cells and intermediate cells

  3. Cellular atypia (↓)

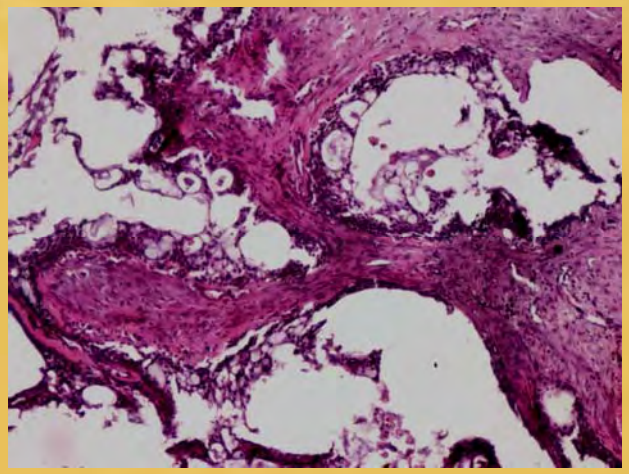

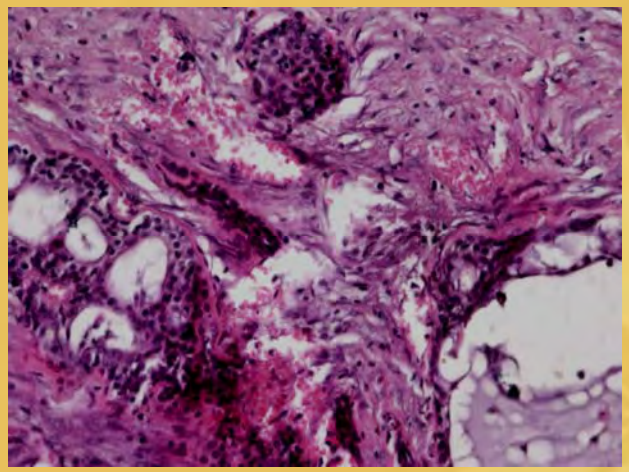

Discussion

- Origin – de novo formation, mucous cells of sinus lining
- Site: parotid gland > minor salivary gland

  (palate > tongue or buccal mucosa > retromolar > lip)

  Rarely it may arises as primary jaw tumor or as a laryngeal, lacrimal, nasal, paranasal, tracheal or pulmonary tumor
- Prognosis: depending on grade and stage

Case 5

- **Name : 林 X X**
- **Gender : Male**
- **Age : 60**
- **First visit : 95.05.29**

- **Chief complaint**

  Throbbing pain over lower right posterior area for 2 months

Present Illness

- **This 60 y/o male suffered from the above episode for 2 months. He had been to LDC and received endodontic treatment of 48 but in vain. He didn’t feel better and numbness of R’t lower lip was noted about 1 week ago.Then he went to another LDC. Radiolucent lesion was noted over R’t mandible opposed to 45, 46 area (edentulous) and then he came to OM OPD for further evaluation.**

Past History

- **Past medical history**

  Systemic disease: Denied

  Hospitalization: facial bone fracture due to T/A on 89/02/29, s/p ORIF

  Drug allergy: Denied

- **Past dental history**

  1. 45, 46 lost 30 yrs ago 2. OD, Endo

  3. Extraction

Personal History

- **Oral habit**

  Alcohol: (+) 1 BOT/day for 40 yrs

  Betel nut chewing: (+) socially for 5 yrs, quit for 2 yrs

  Cigarette: (+) 3PPD for 40 yrs

  Others(-)

- **Family history**

  NP

OMF Findings

- **Extra-oral**

  Slight swelling over right lower face

- **Intra-oral**

  Slightly elevated mass over lower right edentulous ridge

  1. Dimension: 2x2cm

  2. Surface: smooth

  3. Color: pink

  4. Covering mucosa: NP

  5. Pain(+), throbbing

  6. Tenderness(+) 7. Induration(-)

  8. Lymphadenopathy(-)

X-Ray Findings -- Panorex

Treatment Course

- **95.05.29 –**

  Clinical impression: Osteomyelitis, right mandible

  R/O malignancy

  Referred to OS -- incisional biopsy and 48 odontectomy, sent for histopathological exam.

Microscopic Examination -- 1

Highly cellular, basophilic wavy fibrous tissue

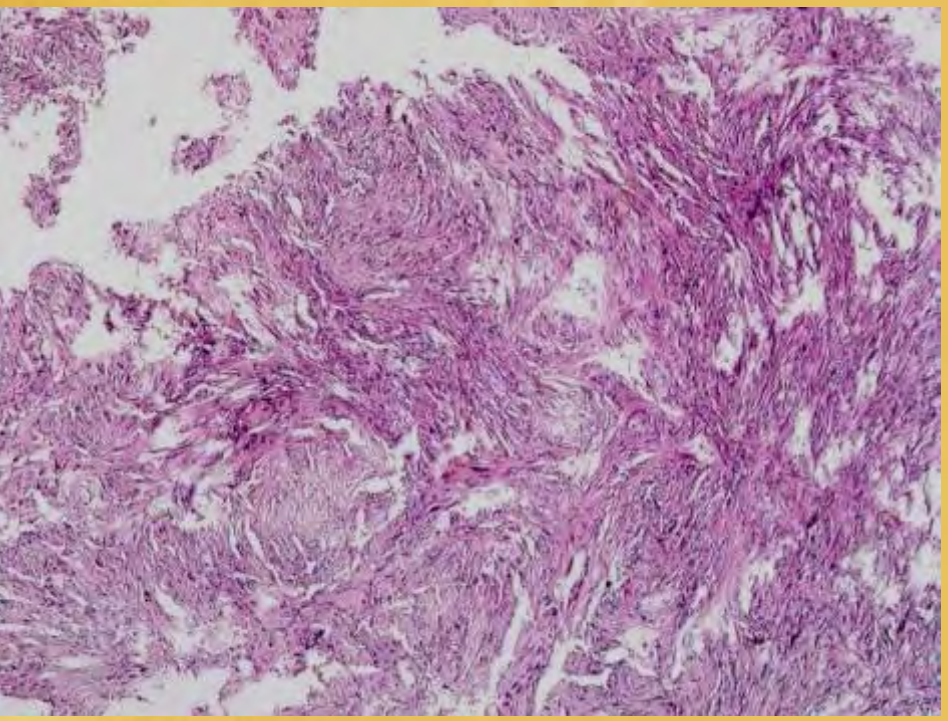

Spindle-shaped cells arranging in interlaced bundles and whorled appearance

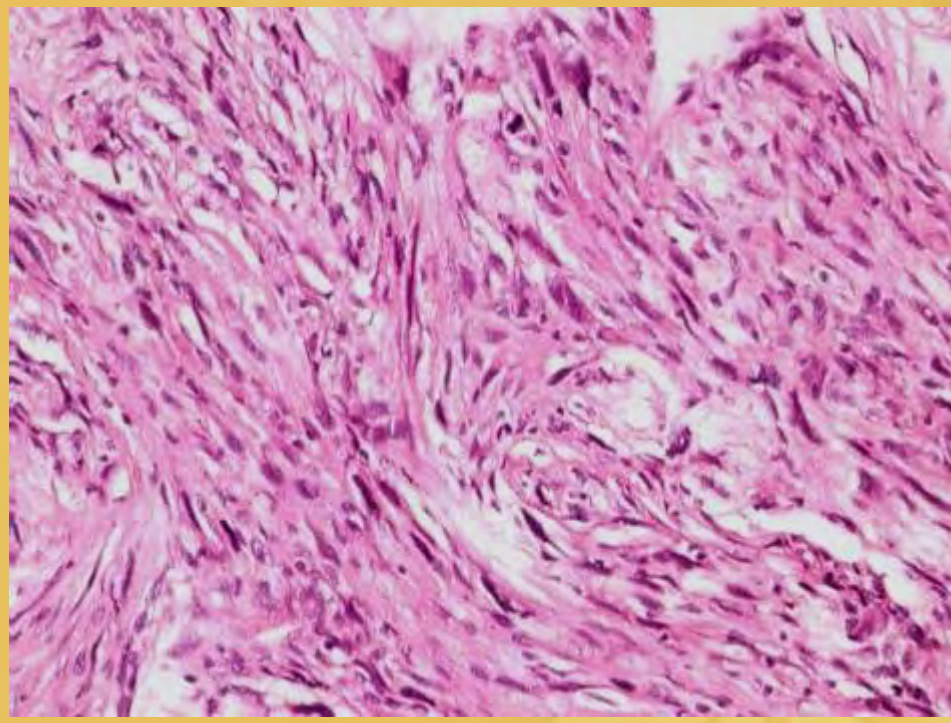

Microscopic Examination -- 2

Pleomorphism, hyperchromatism, axon-like structure

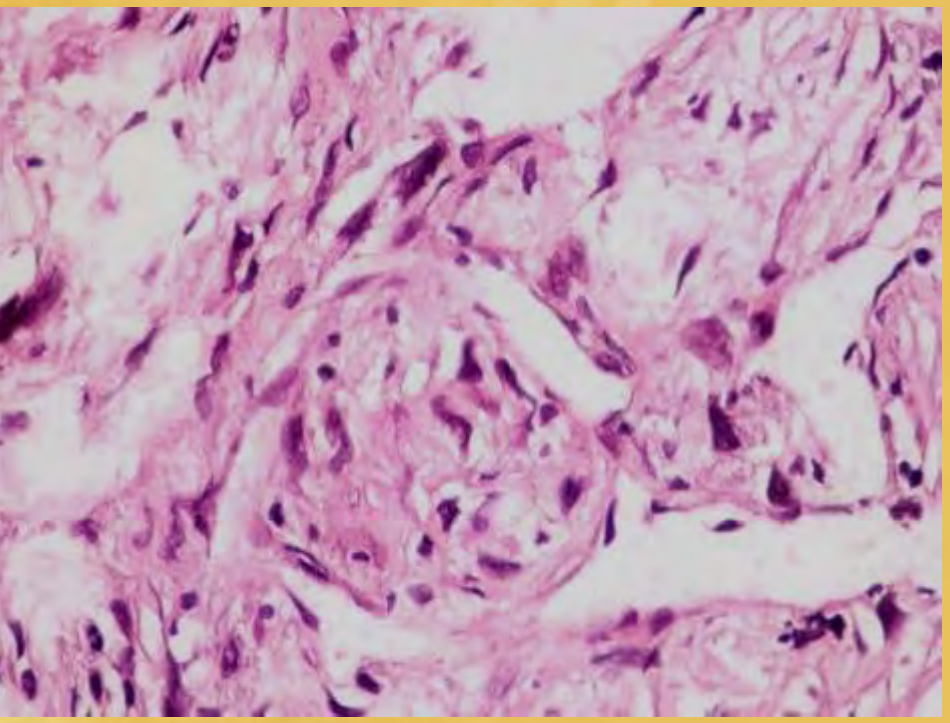

Abnormal mitosis

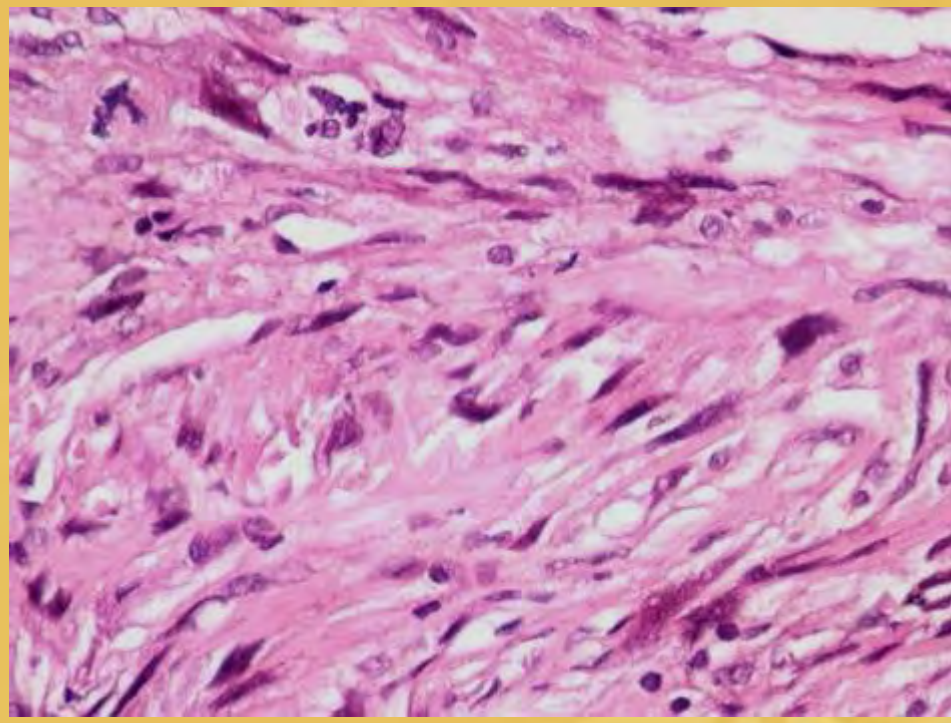

Immunohistochemical Stains

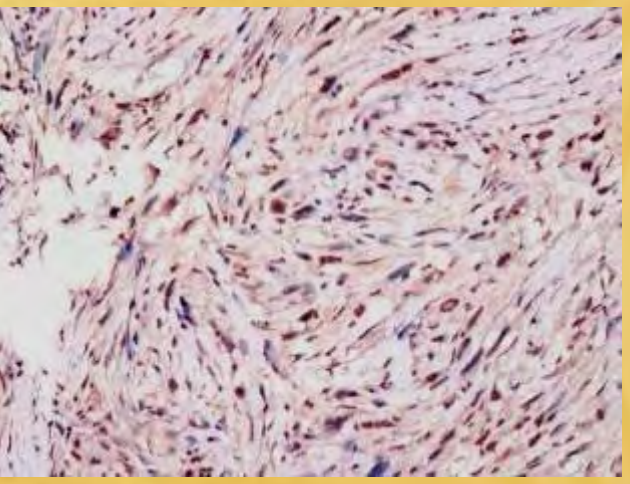

NSE(+)

NFP(+)

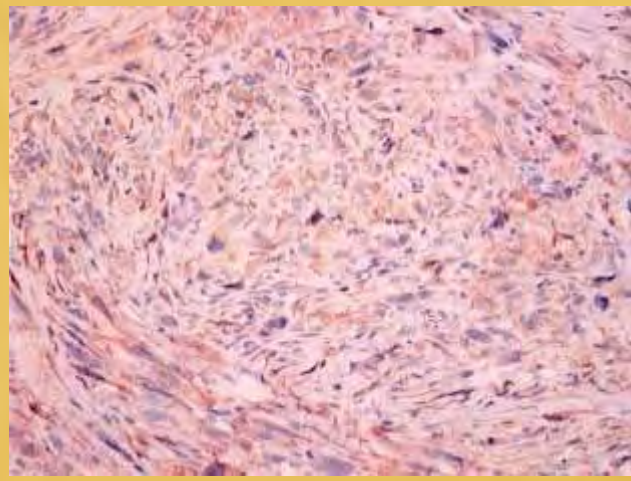

Ki67(+)

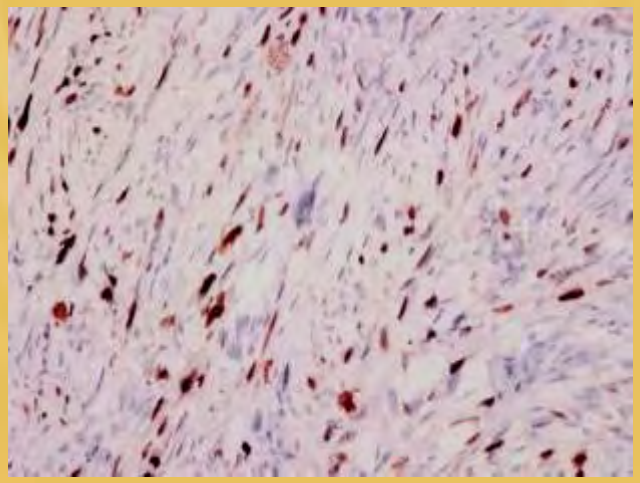

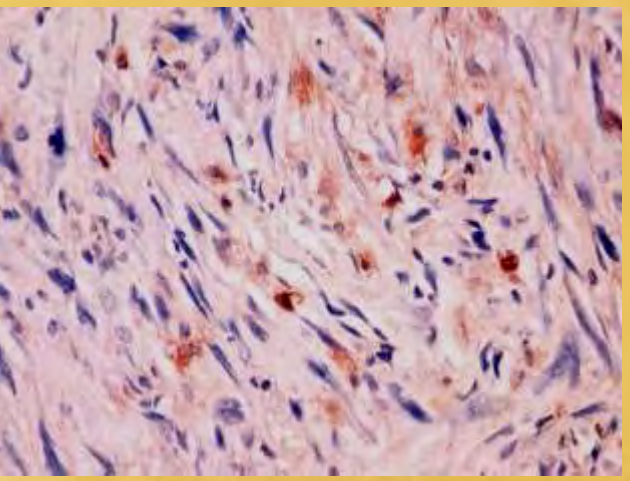

S-100(+)

CD34(-)

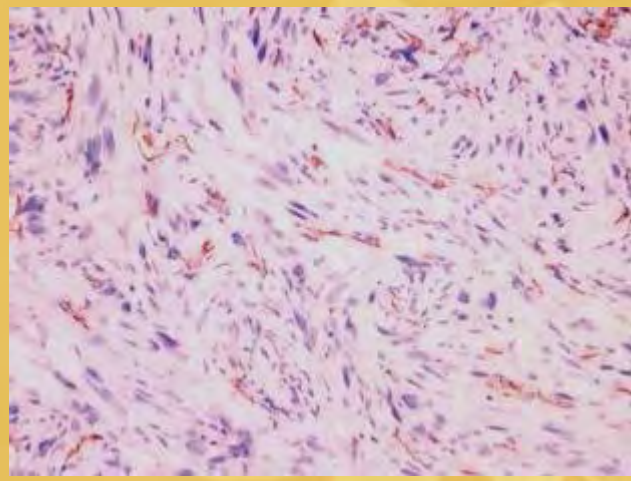

HP report -- Incisional

- **Neurofibrosarcoma**

  Bone, Mandible, Right, Incision

- **95.06.07 – arrange PET and bone scan**
- **95.07.01– arterial port implantation and 1st IAIC**
- **95.07.18 – hospitalization and operation**
  1. **wide excision + segmental resection**
  2. **free flap reconstruction by plastic surgeon**
- **96.01.08 ~96.04.19 -- IAIC**

Microscopic Findings of Excisional Specimens

- **Microscopic findings the same as incisional biopsy**

- **Immunohistochemical stain: the same result as incisional biopsy**

- **Frozen section: free**
- **Lymph node: free**
- **Margin: free**

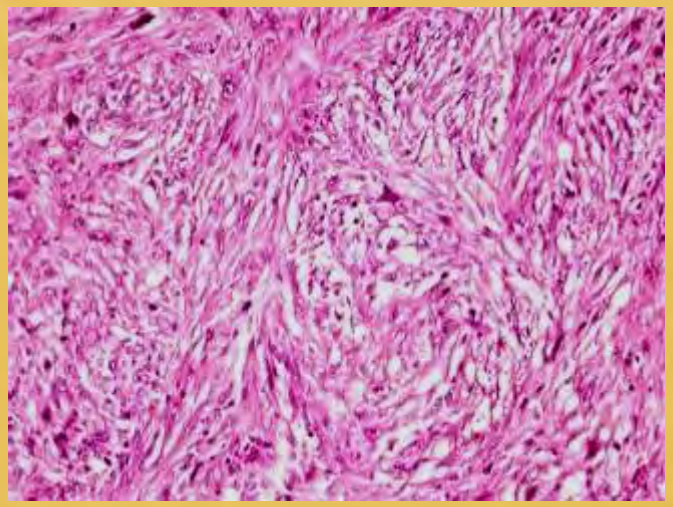

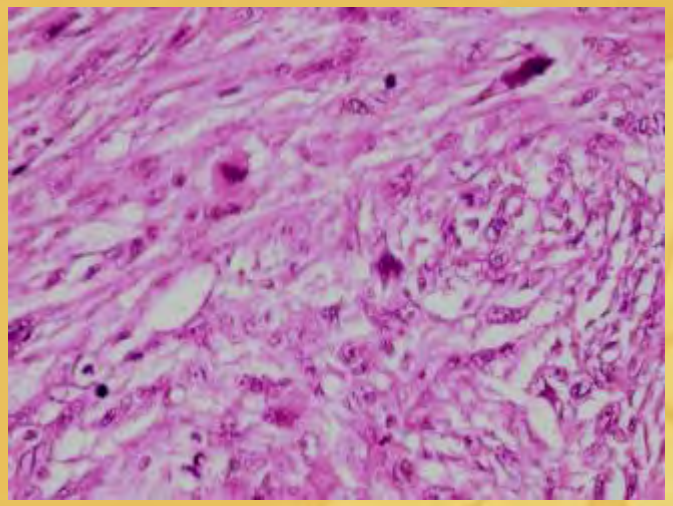

Final Diagnosis

- **Neurofibrosarcoma**

  Bone, Mandible, Right, Segmental resection

Discussion

- **Neurofibrosarcoma (Malignant peripheral nerve sheath tumor) – 5~10 % soft tissue tumors**
- **Origin**

  1. Peripheral nerve – brachial plexus, 32%
  (this cases: inferior alveolar nerve)

  2. Malignant transformation from previous existed neurofibroma – associated with neurofibromatosis, 24~50%

  3. Malignant transformation from previous existed shwannoma, rare
- **Prognosis: poor when associated with neurofibromatosis, 5 yr survival rate: 15%**

Case 6

- **Name : 楊 X X**
- **Gender : Male**
- **Age : 51**
- **First visit :95.07.19**

- **Chief complaint**

  Massive ulcer over lower left posterior area and upper anterior palatal area for 2 to 3 weeks

Present Illness

- **The 51 y/o male found two ulcerative lesions over lower left posterior and upper anterior palatal area 2 to 3 weeks ago. Patient did not recall any previous oral soft tissue trauma history. The ulcerative lesions became larger gradually, so he came to OS OPD for further examination.**

Past History

- **Past medical history**
  1. **Systemic disease: HTN under medications**
     heart disease
  2. **Hospitalization: skeletal trauma**
  3. **Drug allergy: Acetaminophen**

- **Past dental history : Wearing upper RPD for more than a decade**
- **Oral habits: A(-), B(+), C(+)**

Intra-oral Findings -- 1

- An ulcerative, crater-like lesion over gingiva from teeth 13-23, bone exposure
  1. Dimension: 2x2 cm
  2. Color: white & red
  3. Consistency: rubbery
  4. Pain: (-)
  5. Tenderness: (+)
  6. Induration: (+)

Intra-oral Findings -- 2

- An ulcerative, crater-like lesion over gingiva from 35-38
  1. Dimension: 3x2.5 cm
  2. Color: white & red
  3. Consistency: rubbery to firm
  3. Pain: (+)
  4. Tenderness: (+)
  5. Induration: (+)

X-ray Findings -- Panorex

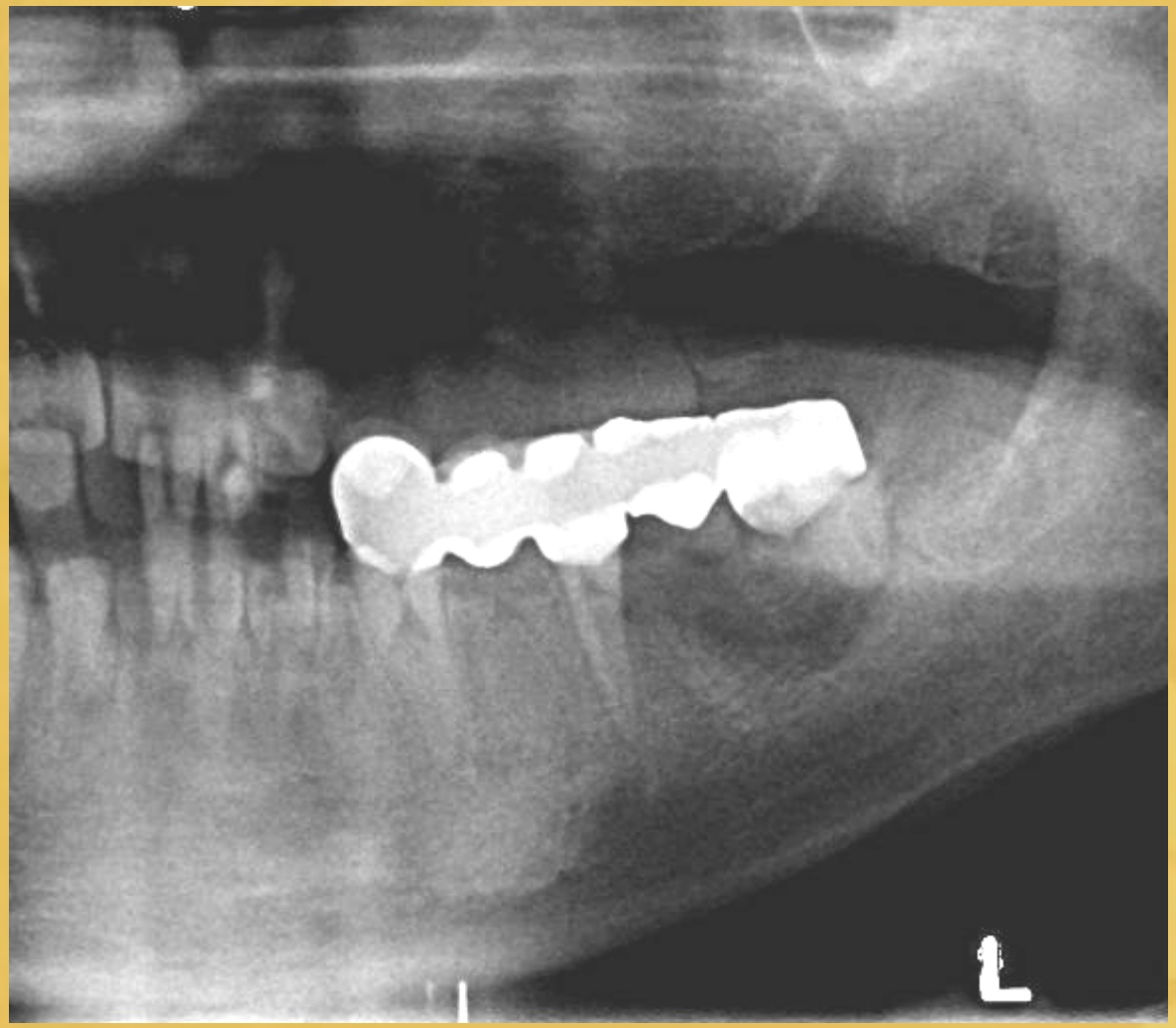

Microscopic Examination– 1

Lesion of anterior maxilla -- immature lymphoid cell proliferation, diffuse small basophilic cells

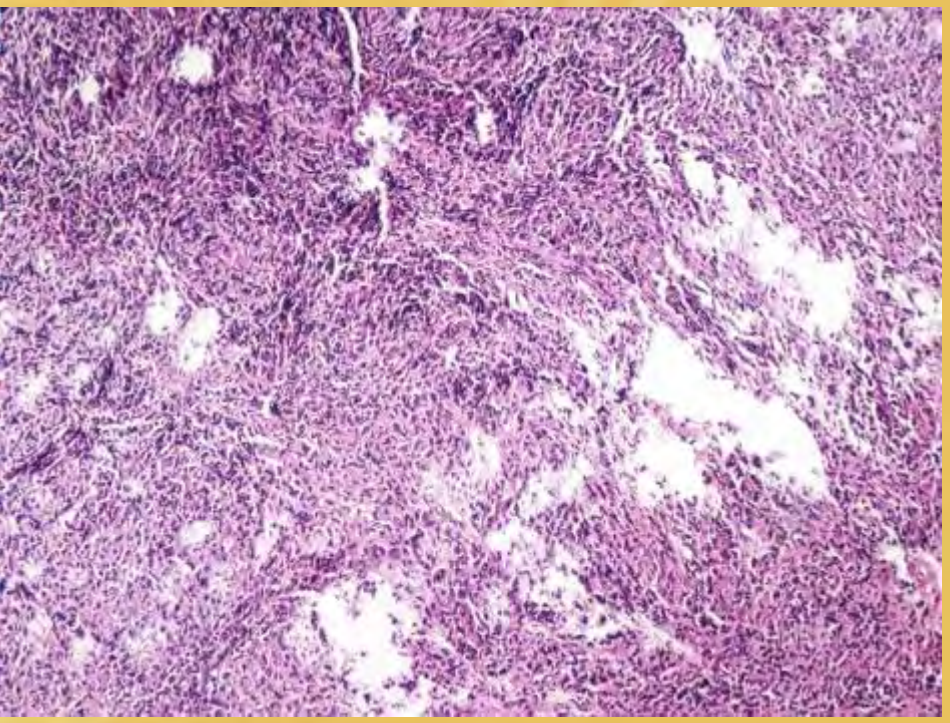

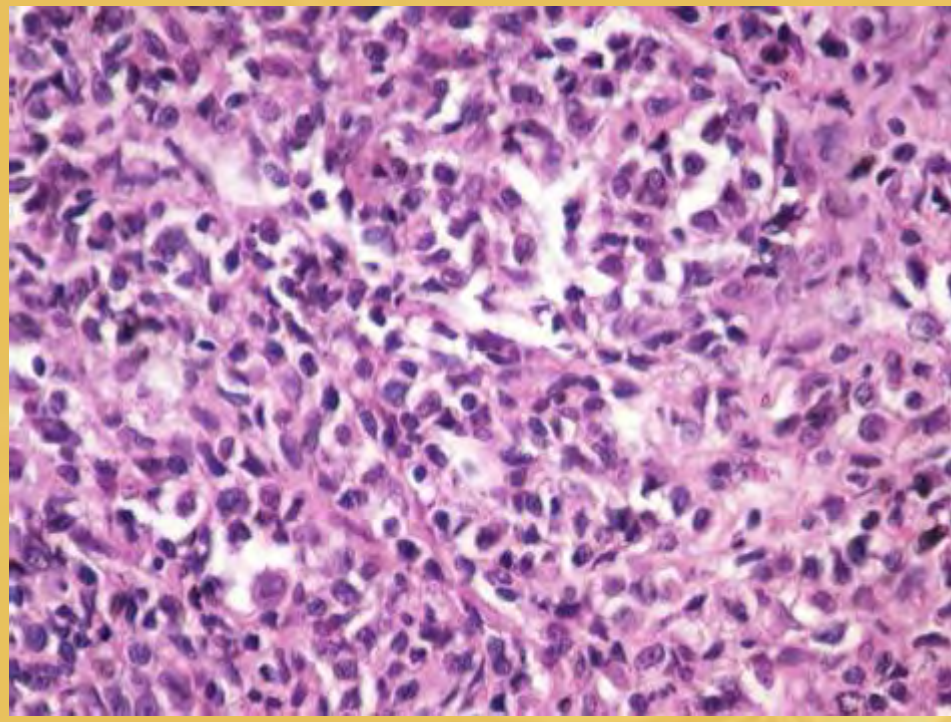

Microscopic Examination – 2

Lesion of 35-38 area -- immature lymphoid cell proliferation, diffuse small basophilic cells

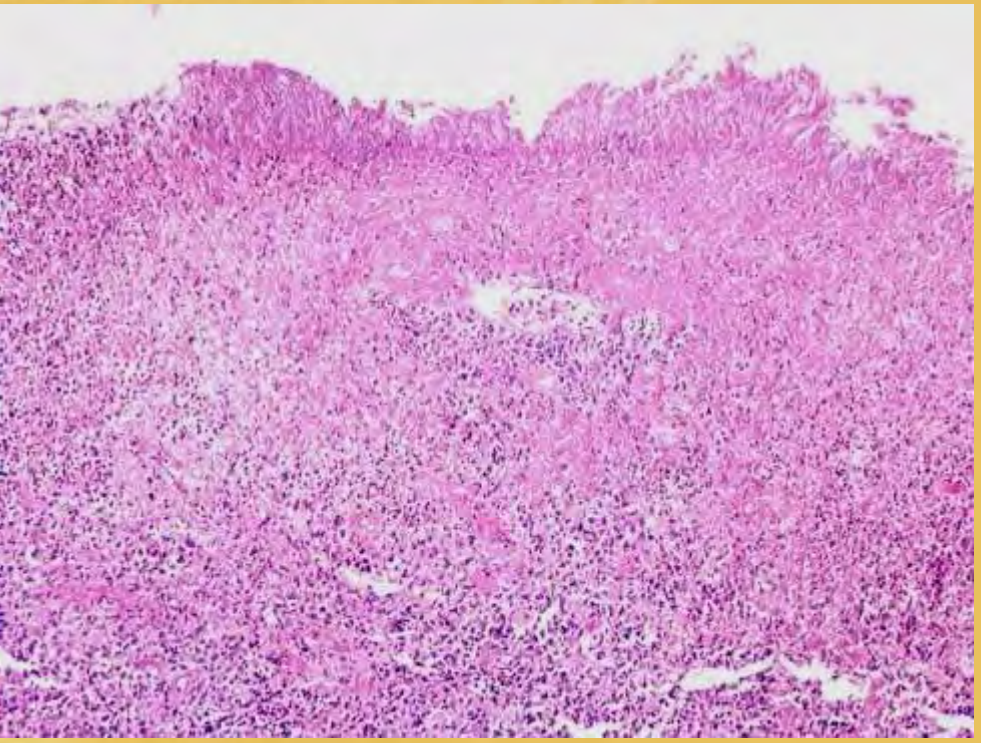

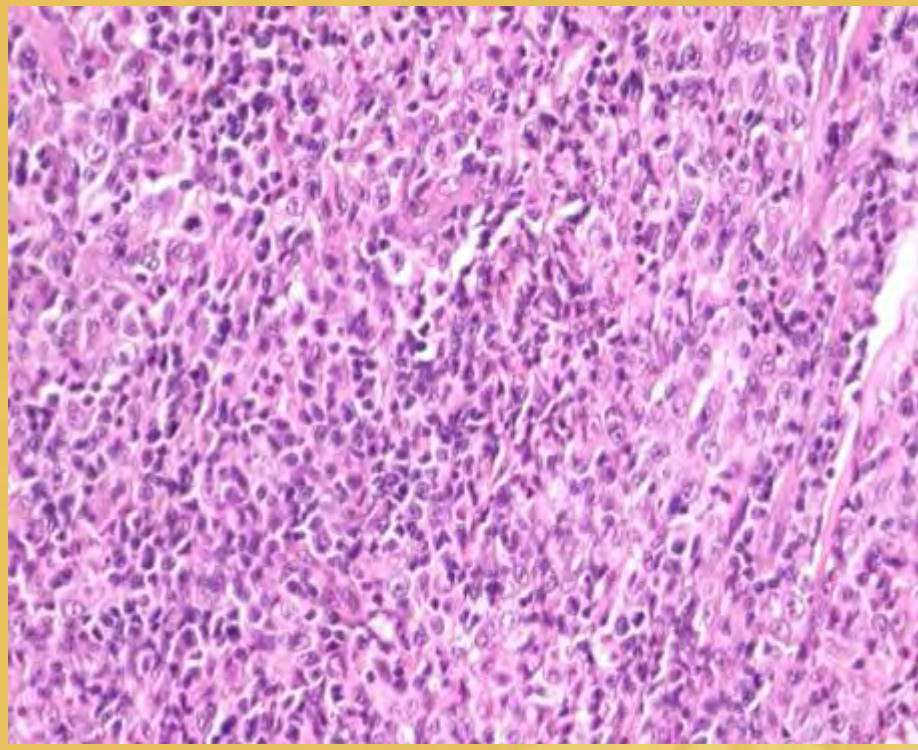

Immunohistochemical Stains

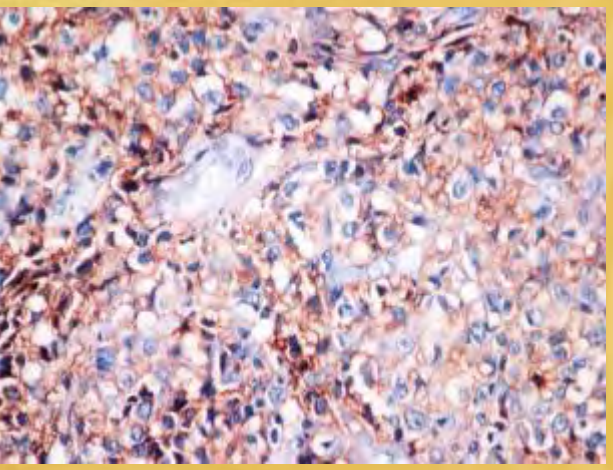

LCA(+)

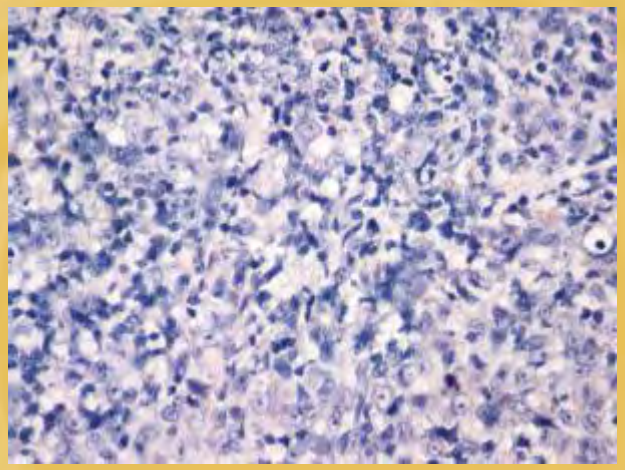

Lamda(-)

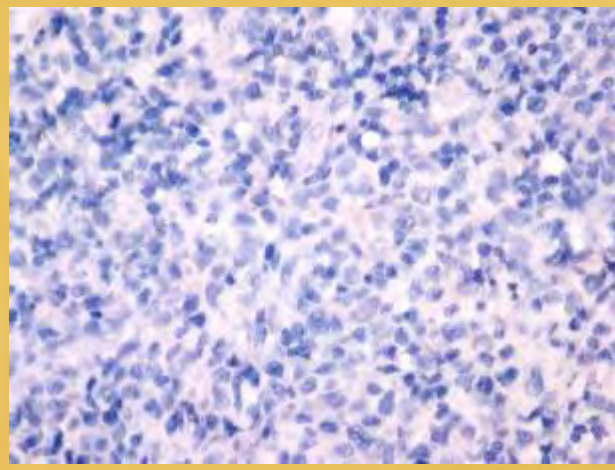

Kappa(-)

T cell(-)

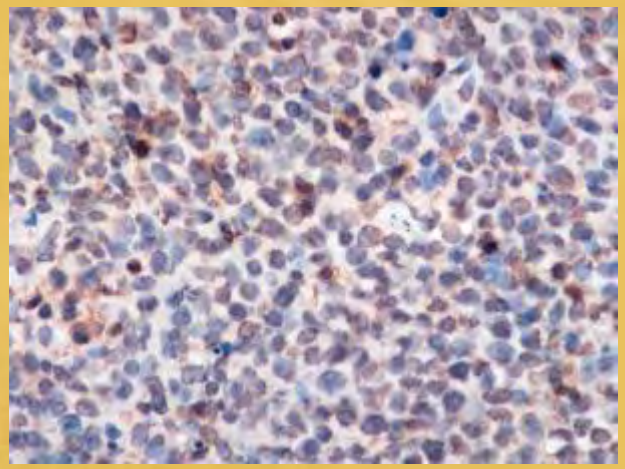

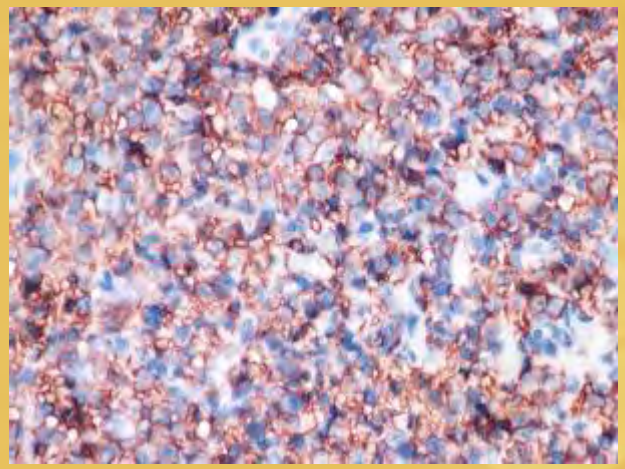

B cell(+)

Final Diagnosis

- **B cell lymphoma, small, diffuse type**

  Bone, Maxilla, Anterior, Incision

  Bone, Mandible, Left, Incision

- **Referred to Hema. Dept., chemotherapy accepted**

Discussion

- **Non-Hodgkin's lymphoma, small B-cell diffuse type → low-grade, extra-nodal**

- **Common site in oral cavity:**
  1. **jaw bone – ill-defined radiolucency**
  2. **buccal vestibule, gingiva and posterior hard palate**
     -- **non-tender, diffuse swelling with or without ulceration**

- **Treatment and prognosis: depending on grade and stage, RT + CT, or CT alone, response good but tend to recur in older adults (survival rate without treatment: 8~10 yrs)**

Case 7

- Name : 林 X X
- Gender : Male
- Age : 17
- First visit :95.09.19

- Chief complaint

  Painless swelling over upper left gingiva for more than one week

Present Illness

- **The 17 y/o male patient didn’t have uncomfortable experience of oral cavity before. On 95/09/16, his aunt found that a mass occupied on his upper left gingiva. The mass didn’t make him painful or uncomfortable. Then he was brought to XX內兒科診所 for help. After clinical examination, the doctor referred him to OS OPD for further treatment.**

Past History

- **Past medical history**
  1. **Systemic disease:**
     -- **Enuresis with medication at our urological department for 5 years**
     -- **Depressive disorder with medication at our psychological department for 2 years**
  2. **Hospitalization: Nil**
  3. **Drug allergy: Denied**
- **Past dental history : NP**
- **Oral habits: (-)**

Intra-oral Findings

- **A dome-shaped swelling mass over left side of maxilla opposed to teeth 21~25, buccal gingiva, vestibule and palatal gingiva**

1. Dimension: 6x5 cm

2. Color: pink

3. Consistency: firm

4. Covering mucosa: intact

4. Pain(-)

5. Tenderness(-)

6. Pus or discharge(-)

X-ray Findings --Panorex

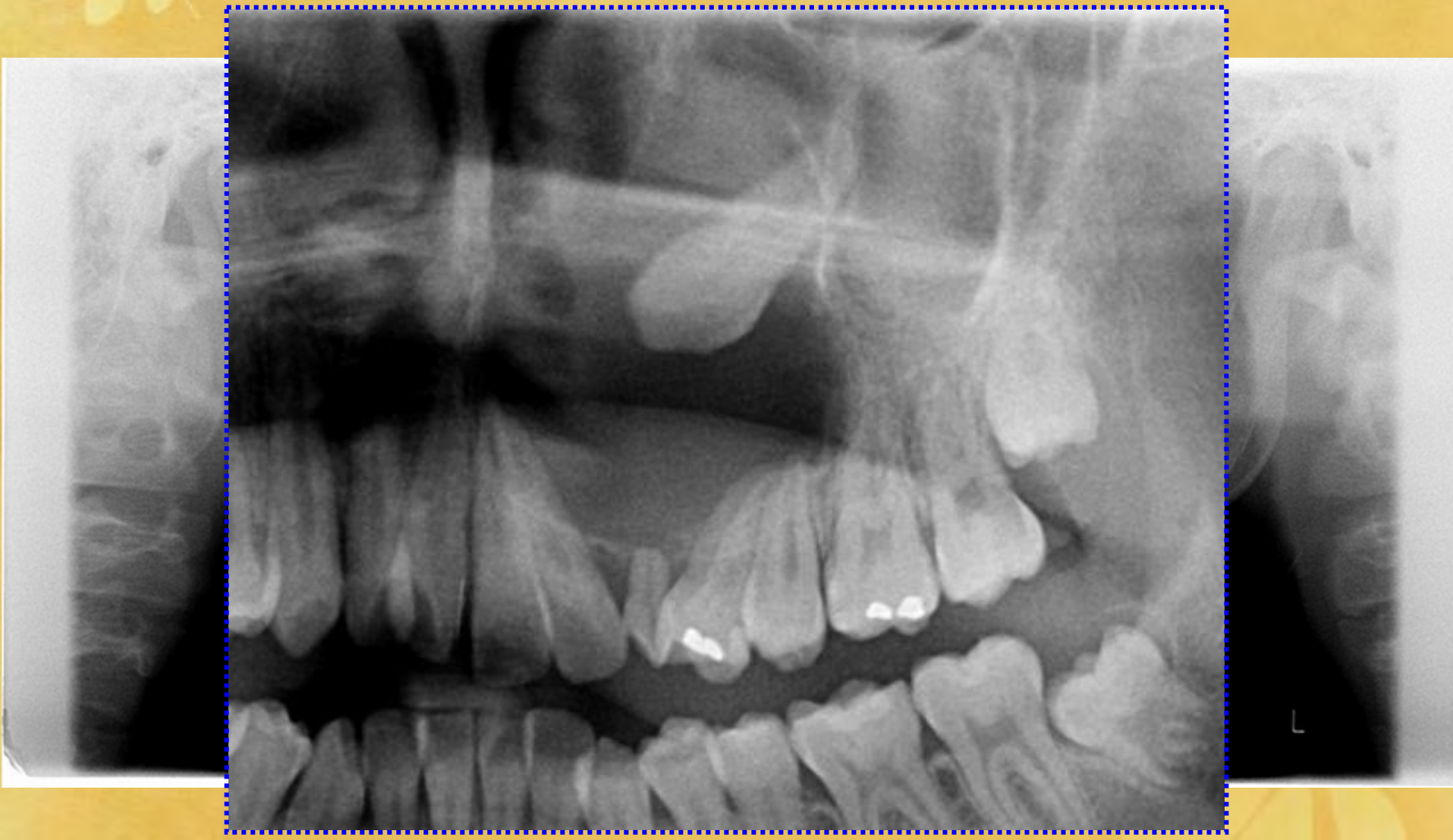

X-ray Findings – Occlusal

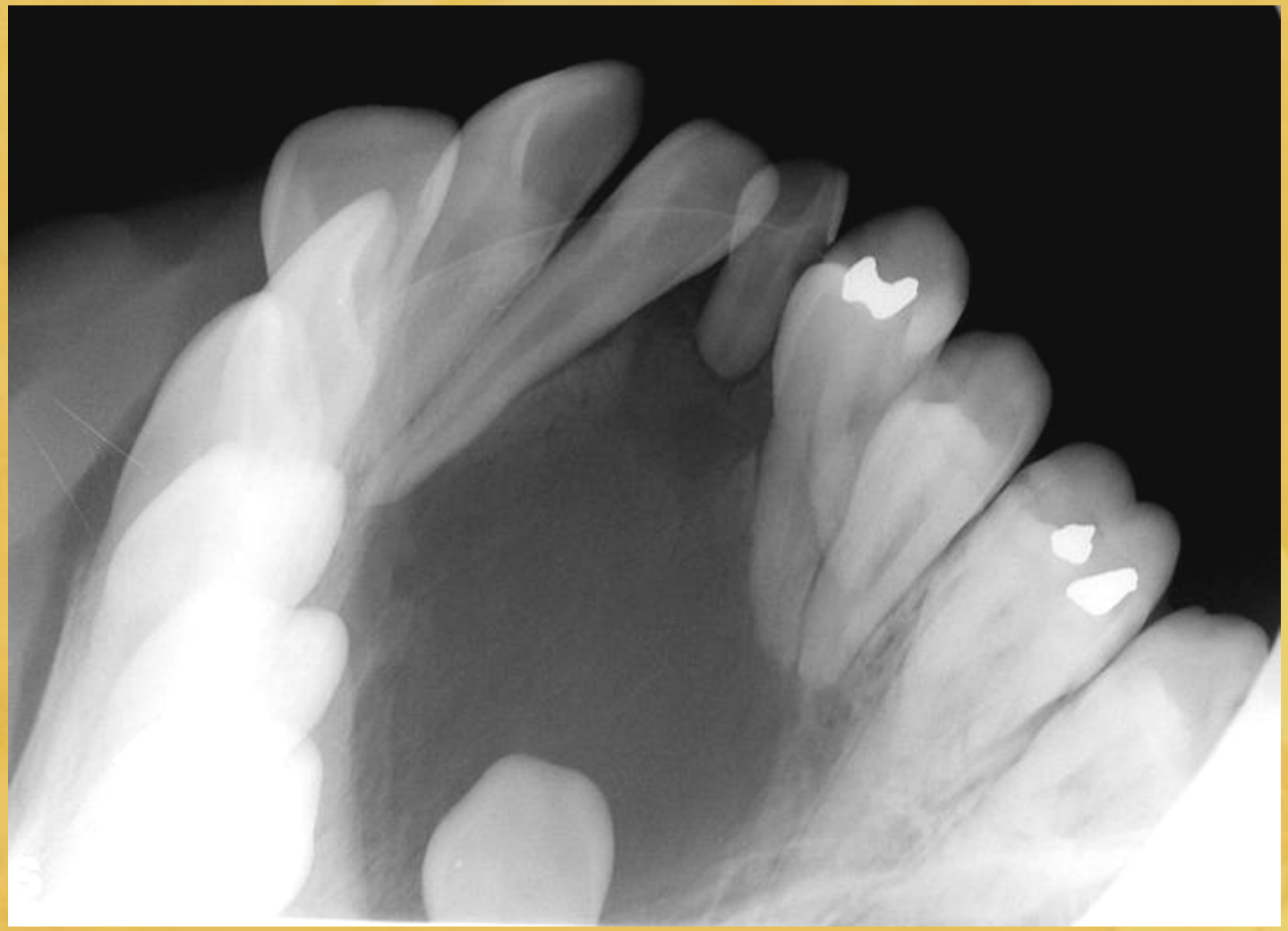

Treatment Course

- **95.09.19**

  Clinical impression: Dentigerous cyst, impacted 23

  Incisional biopsy, sent for histopathological exam

- **95.10.12**

  Hospitalization and operation -- cyst enucleation + bone graft

HP Report -- Incisional

- **Dentigerous cyst**

Bone, Maxilla, Impacted 23, Incision

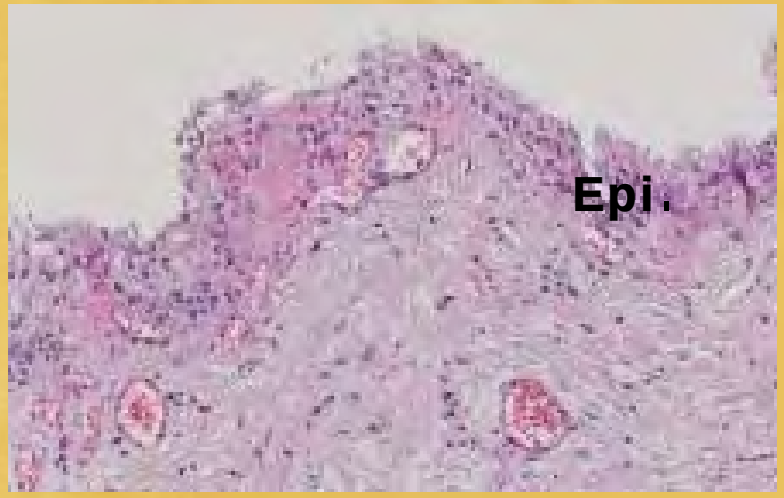

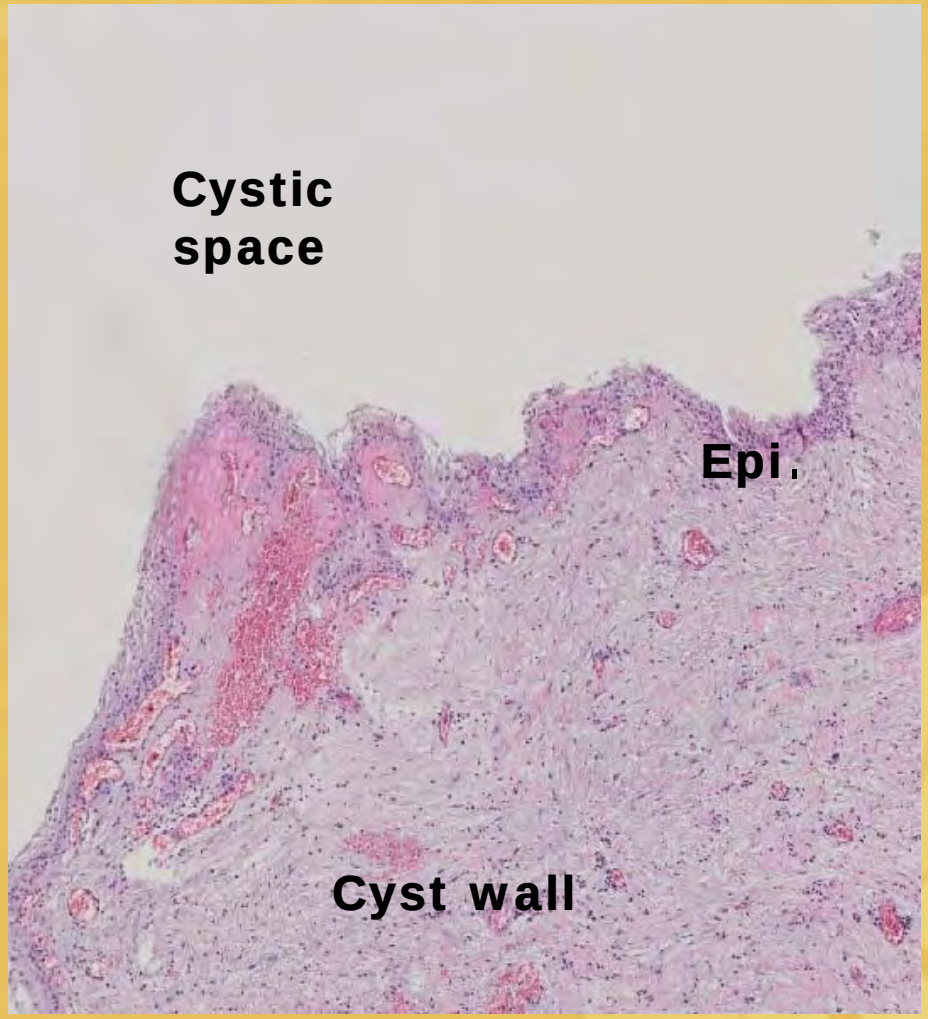

Gross – Hemisection

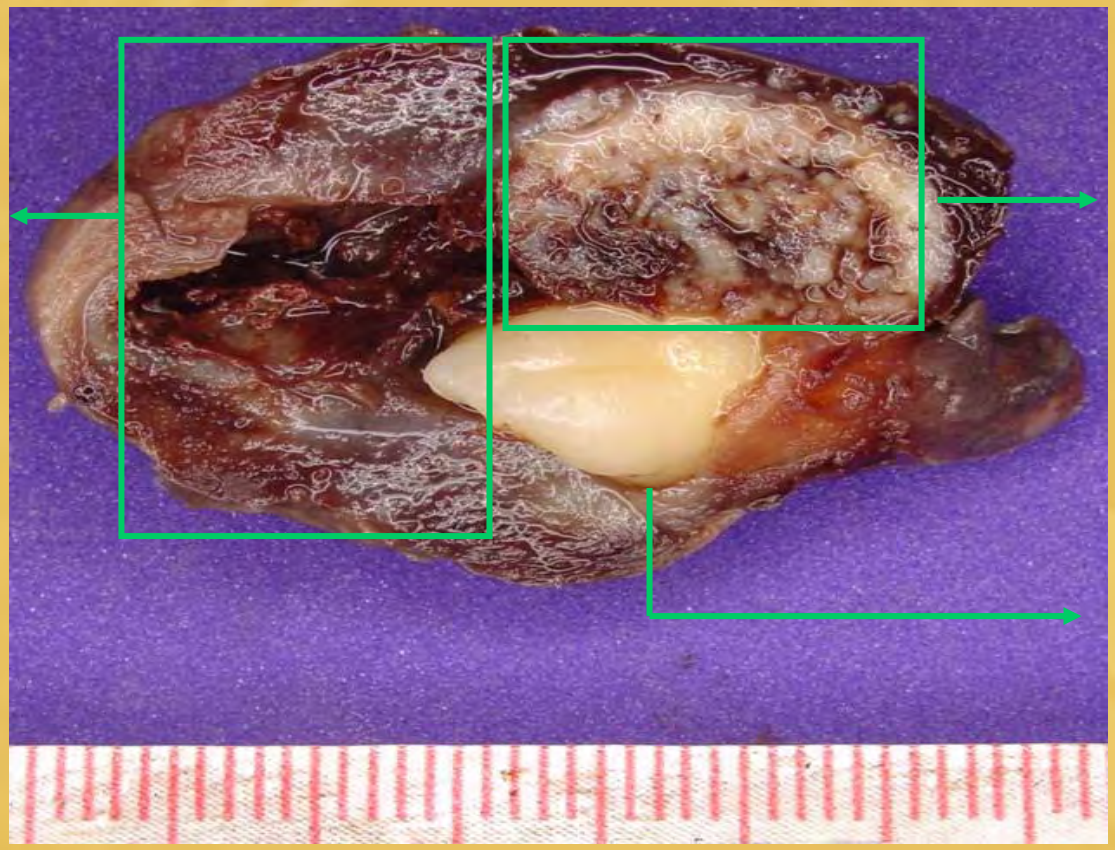

Radiograph -- Gross -- Slide

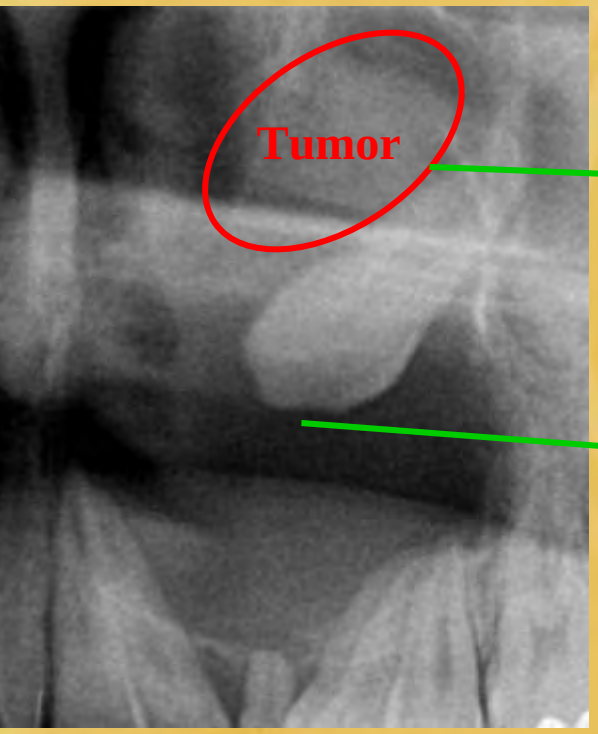

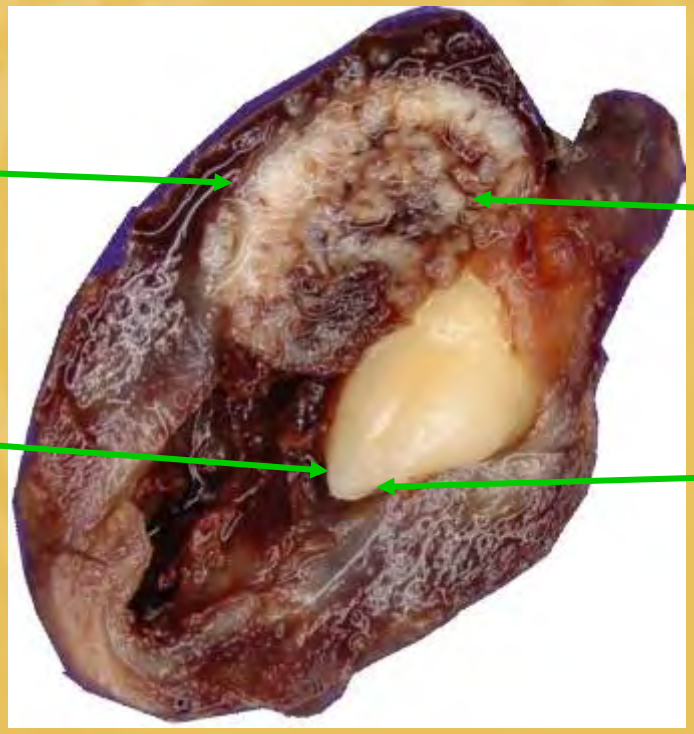

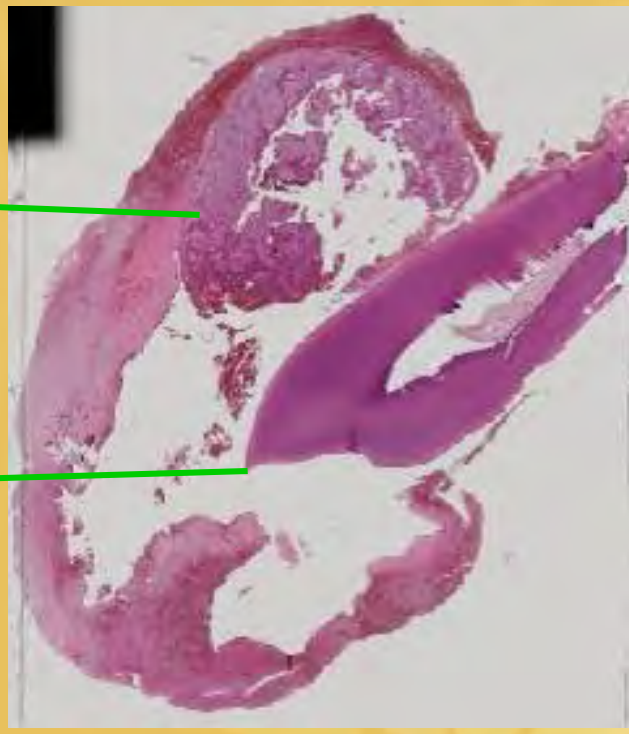

Microscopic Examination

Solid mass -- AOT

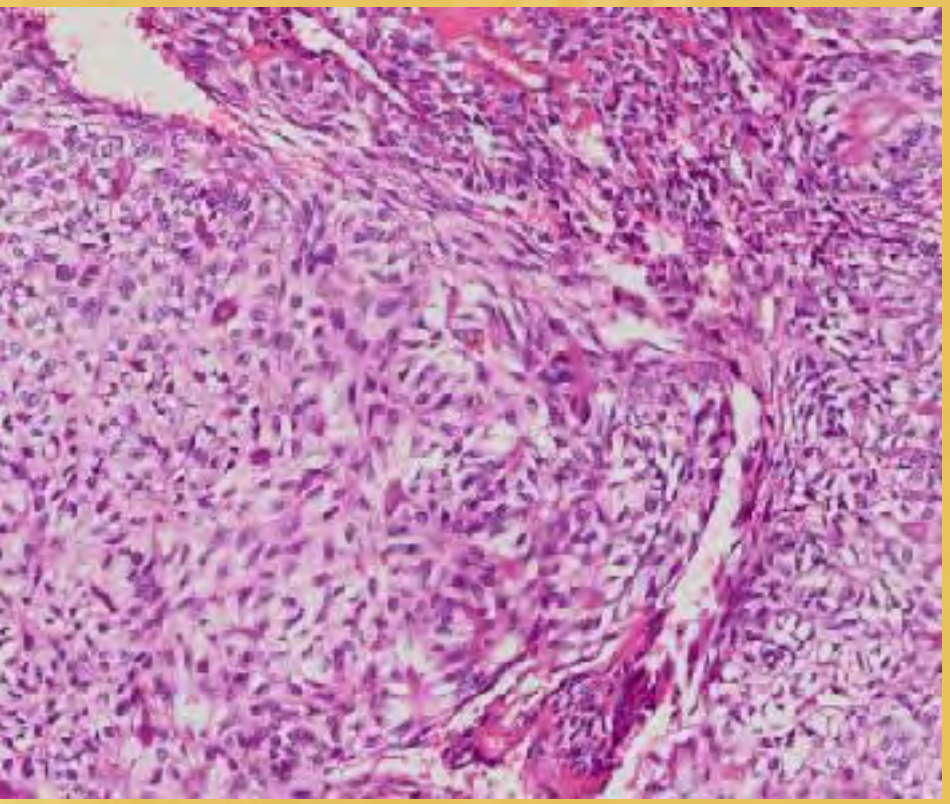

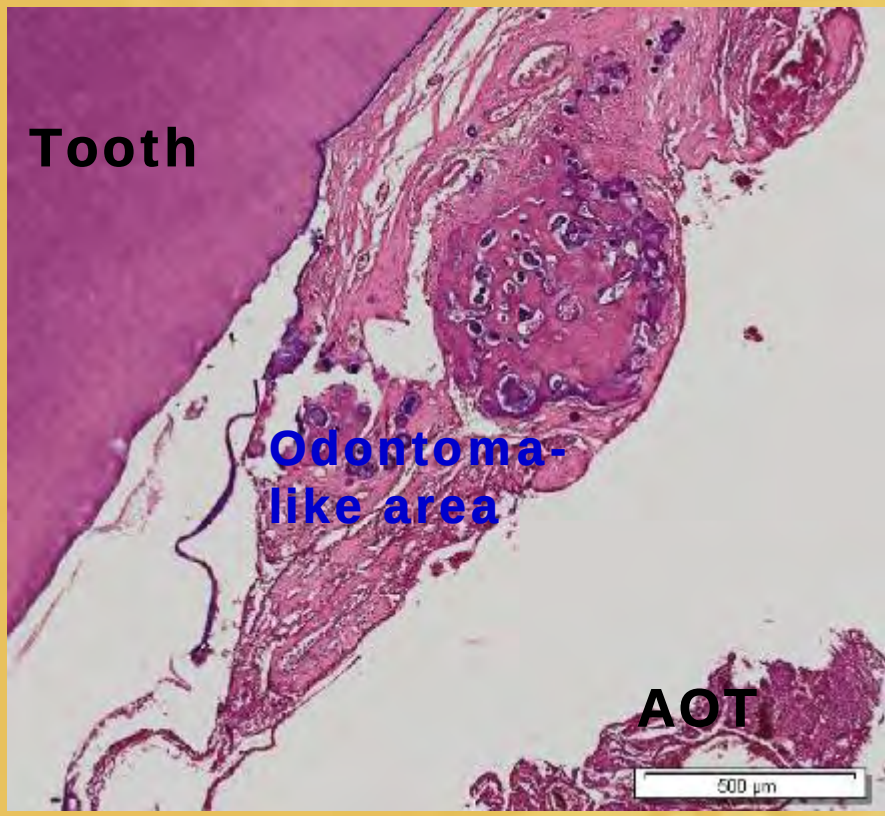

Final Diagnosis

- **Adenomatoid odontogenic tumor ex dentigerous cyst**

  Bone, Maxilla, Impacted 23, Enucleation

Discussion

- **Lesions arising from dentigerous cyst**

  1. Non-aggressive odontogenic benign tumor – AOT

  2. Aggressive odontogenic benign tumor – Ameloblastoma

  3. Malignant tumor – SCC, mucoepidermoid ca.
- **Lesions associated with AOT**

  1. COC

  2. CEOT
- **AOT ex DC in English language literatures – total 6 cases**
- **Incisional biopsy 的結果會受到切片位置的影響**
- **X-ray image:當包圍牙冠的R/L lesion 向牙根方向推進超過CEJ時, Tumor的可能性較高**

Case 8

- **Name : 高 X X**
- **Gender : Female**
- **Age : 42**
- **First visit : 95.06.08**

- **Chief complaint**

  Referred from LDC due to a radiolucent lesion over left mandible

Present Illness

- **This 42 y/o female suffered from toothache over upper left posterior area for 1 day and she came to LDC for treatment. After x-ray examination, an abnormal image over left mandible was found, and then she was referred to OS OPD. According to patients's statement, she felt pain over left mandible when palpation. The symptom lasted for a period of time.**

Past History

- **Past medical history**
  1. **Systemic disease: Denied**
  2. **Hospitalization: Nil**
  3. **Drug allergy: Denied**
- **Past dental history : NP**
- **Oral habits: A(+), B(-), C(-)**
- **Family history: NP**

Intra-oral Findings

- **Mild buccal & lingual bony expansion over tooth 37 and retromolar area**
  1. **Dimension: 3x2 cm**
  2. **Color: pink**
  3. **Covering mucosa: intact**
  4. **Pain(-)**
  5. **Tenderness(+)**
  6. **Induration(-)**
  7. **Vitality of 37(+)**
  8. **Numbness of left lower lip(-)**

X-ray Findings --Panorex

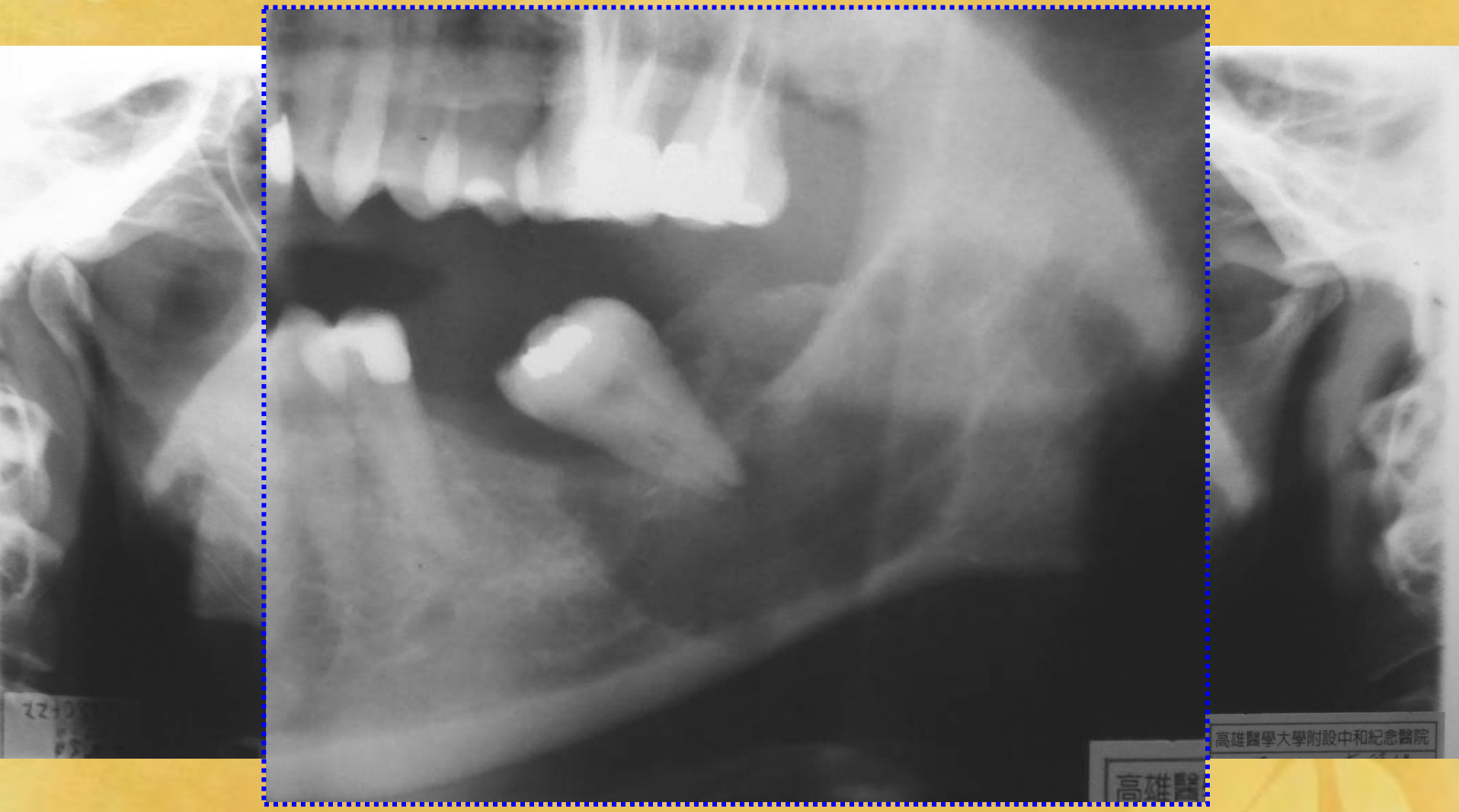

Treatment Course

- **95.06.08**

  Clinical impression– ameloblastoma, left mandible

  Incisional biopsy, sent for histopathological exam.

- **95.08.04**

  Hospitalization and OP

Microscopic Examination -- 1

Odontogenic epithelial islands

Amyloid-like deposition

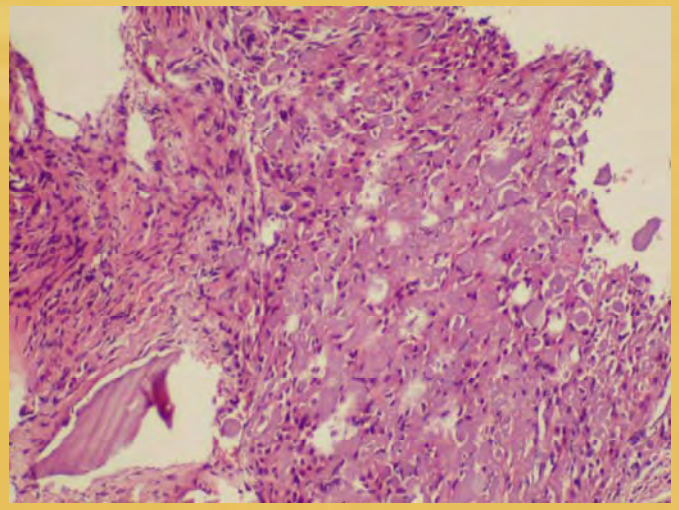

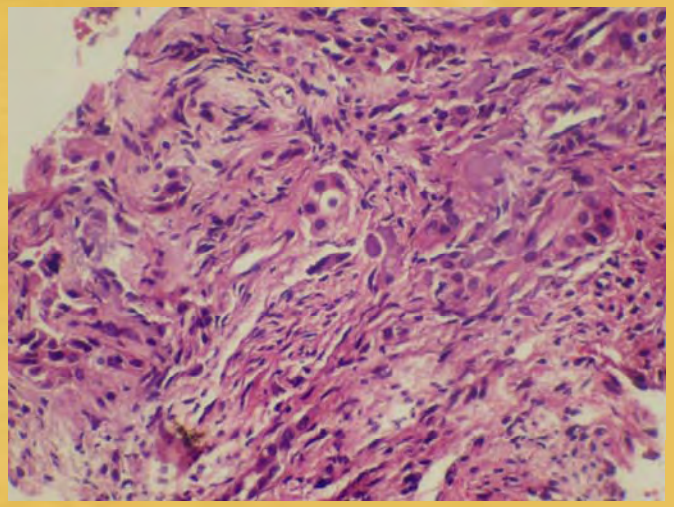

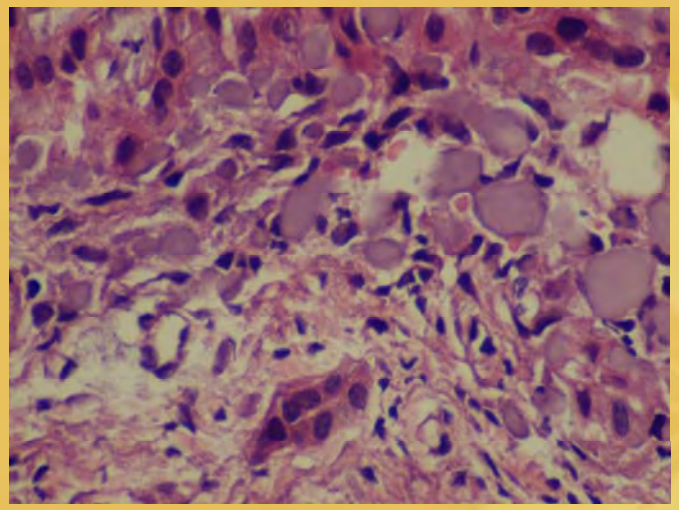

Immunohistochemical Stain

Cytokeratin(+)

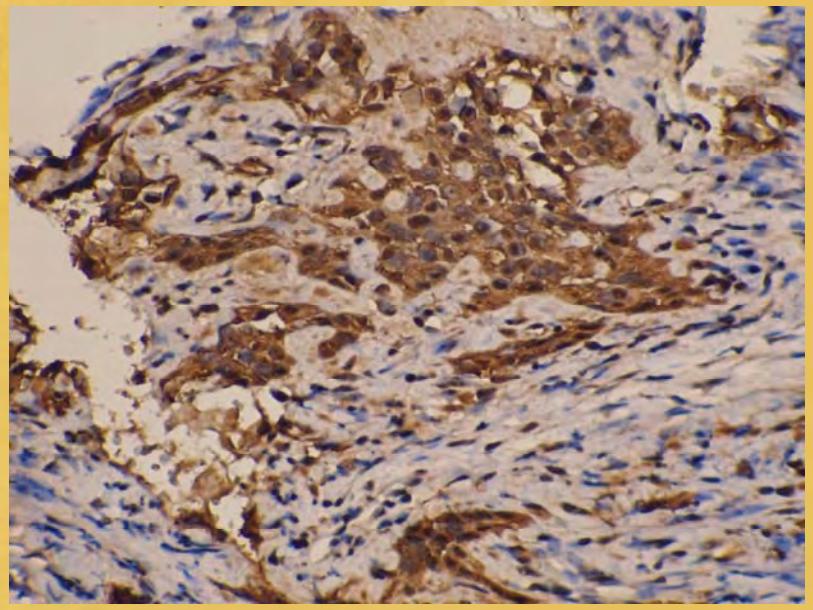

Congo red (+), amyloid indicated

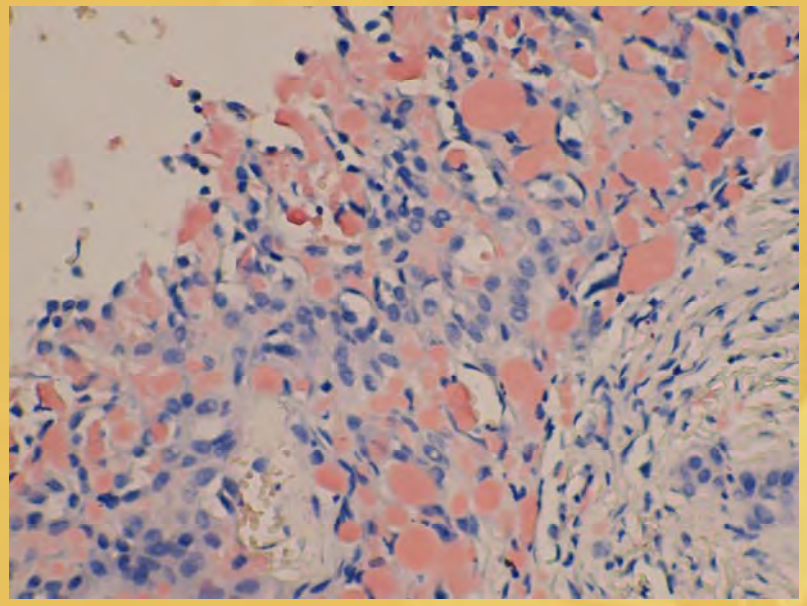

HP Report – Incisional

- **Odontogenic tumor, suggestive of calcifying epithelial odontogenic tumor**

  Bone, Mandible, Left, Incision

Final Diagnosis

- **Calcifying epithelial odontogenic tumor**

  Bone, Mandible, Left, Excision

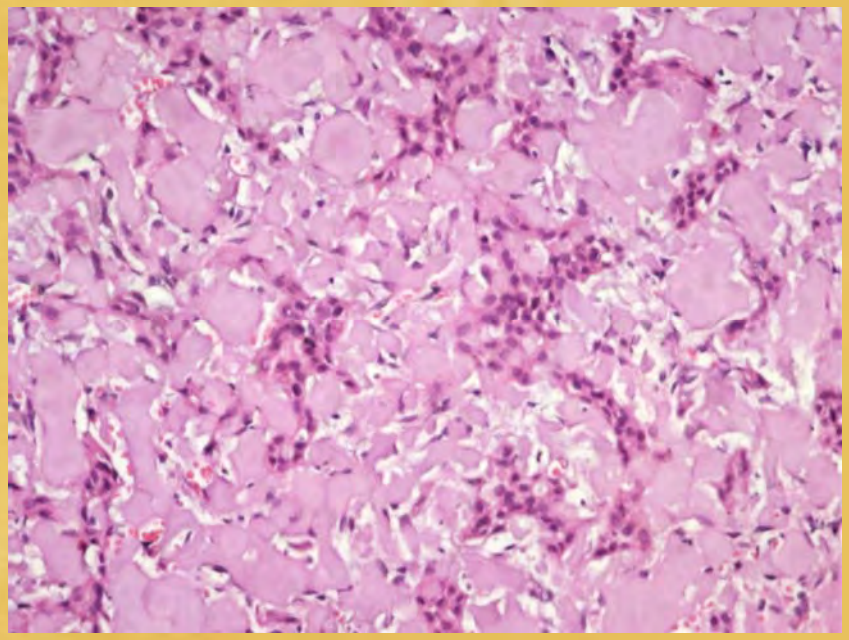

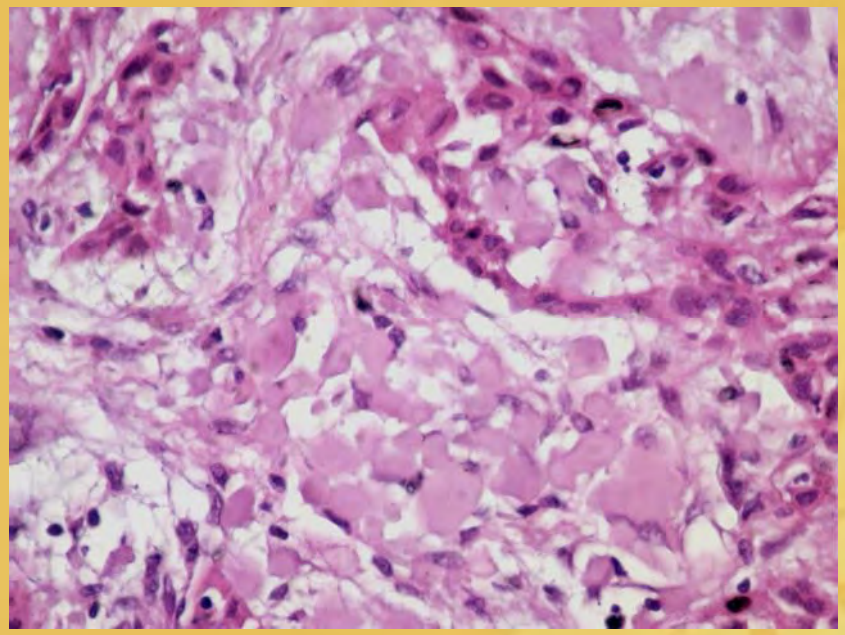

Case 9

- Name : 胡 X X
- Gender : Female
- Age : 30
- First visit : 95. 12.30

- Chief complaint

  A huge mass over lower right edentulous area for 4 months

Present Illness

- **This 30 y/o female patient suffered from above episode for 4 months. She felt mild pain at first and found the lesion getting larger and larger gradually. Then she came to LDC for treatment and was referred to our OS OPD for further evaluation and management on 95.12.30.**

Past History

- **Past medical history**
  1. **Systemic disease: asthma, uterine myoma, HCV**
  2. **Hospitalization: uterine myoma**
  3. **Drug allergy:Denied**
- **Past dental history : NP**
- **Oral habits: A(+), B(-), C(-)**

Intra-oral Findings

- An exophytic firm mass over 45 to 47 edentulous ridge
- Tooth 45 was shift to lingual side by the mass
- Indentation could be seen over lingual side of the

1. Dimension: 4 X 4 cm
2. Color: Red＆white
3. Surface : Ulcerative
4. Mild pain
5. Tenderness(-)
6. Induration(+)

X-Ray Findings -- Panorex

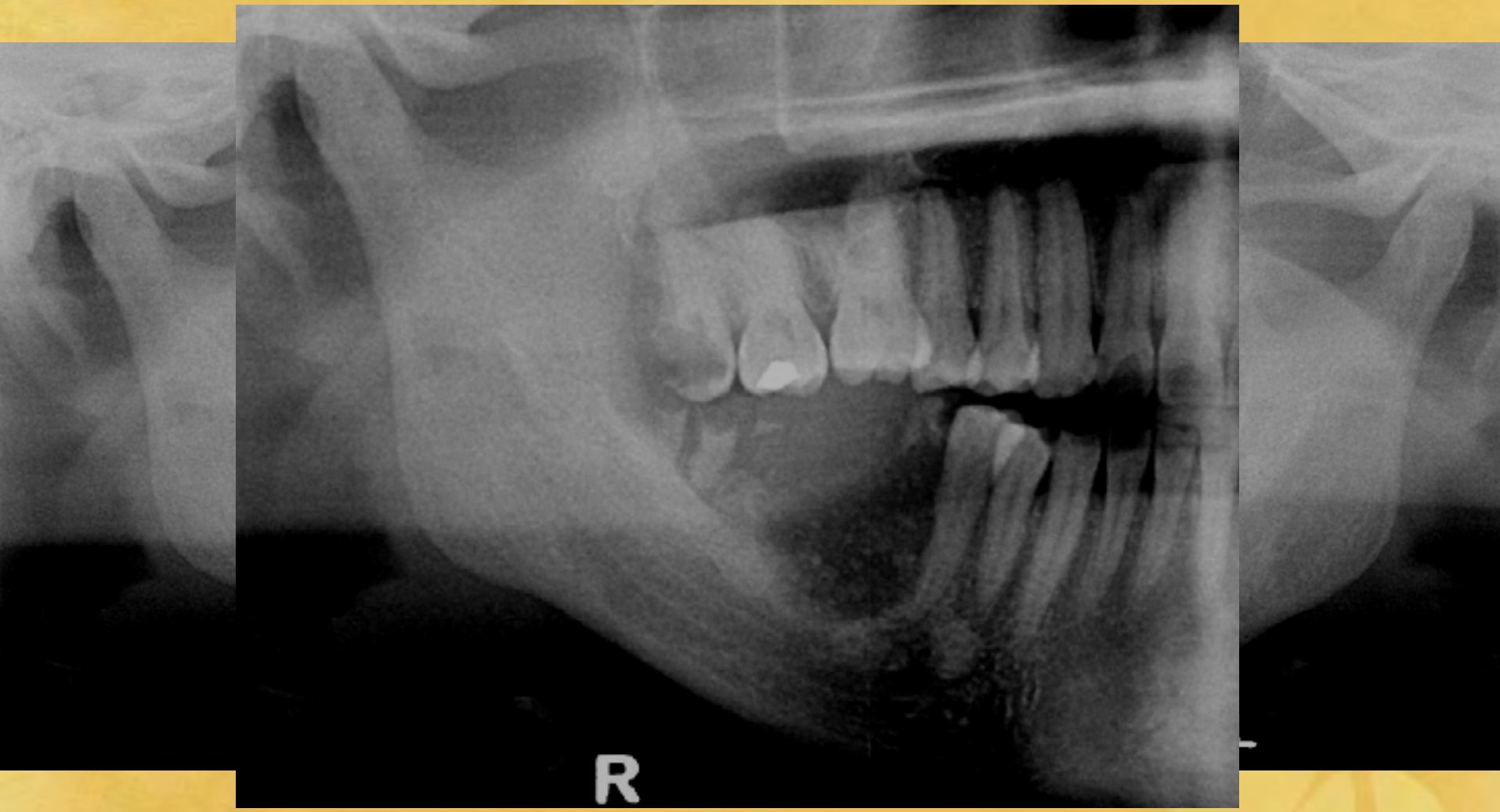

CT Findings

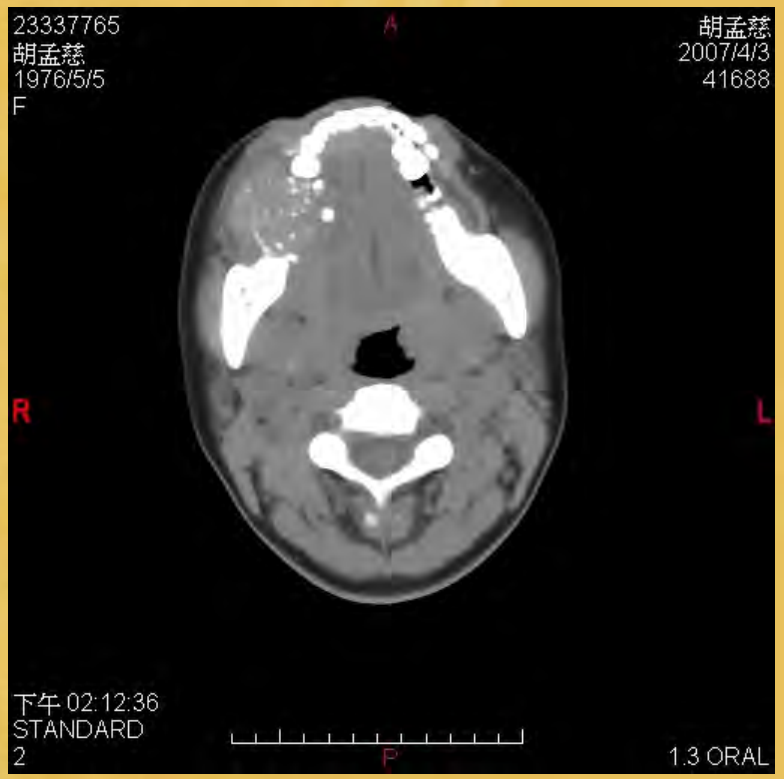
23337765
胡孟慈
1976/5/5
F
A
胡孟慈
2007/4/3
41688
R
L
下午 02:12:36
STANDARD
2
P
1.3 ORAL

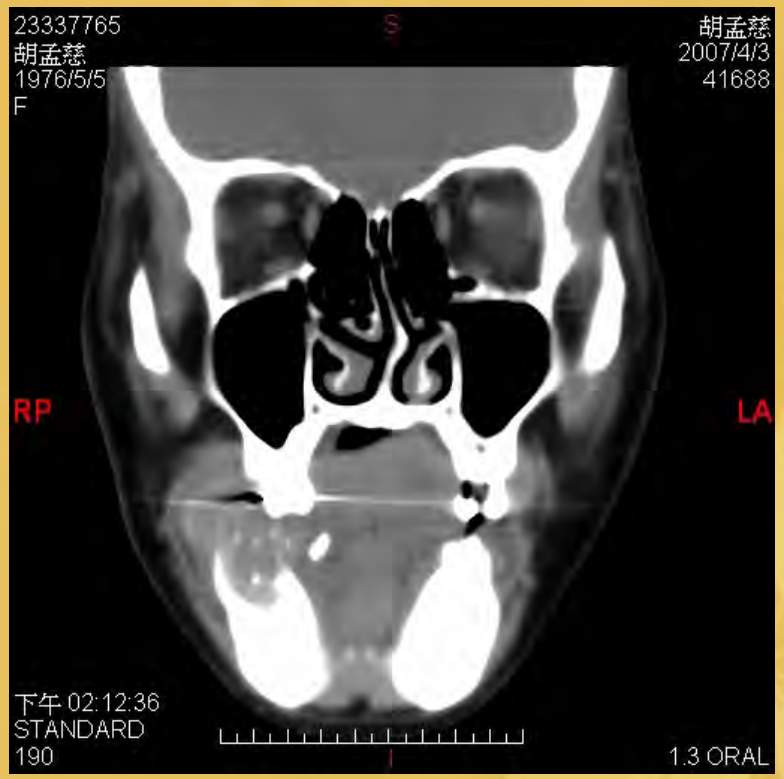
23337765
胡孟慈
1976/5/5
F
S
胡孟慈
2007/4/3
41688
RP
LA
下午 02:12:36
STANDARD
190
I
1.3 ORAL

Treatment Course

- **95.12.30**

  Clinical impression: Odontogenic tumor over lower right edentulous ridge

  Incisional biopsy, sent for histopathological exam.

- **96.01.09**

  Arrange operation on 96.01.18, delay due to high GOT, GPT, referred to 肝膽內科.

- **96.04.10**

  Hospitalization and operation

Microscopic Examination -- 1

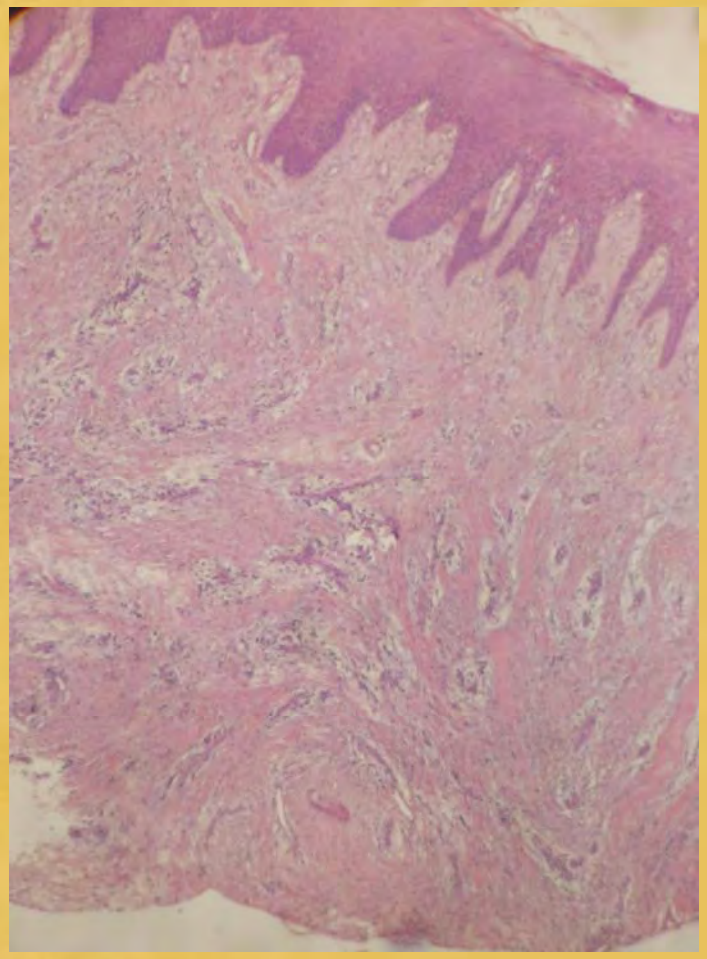

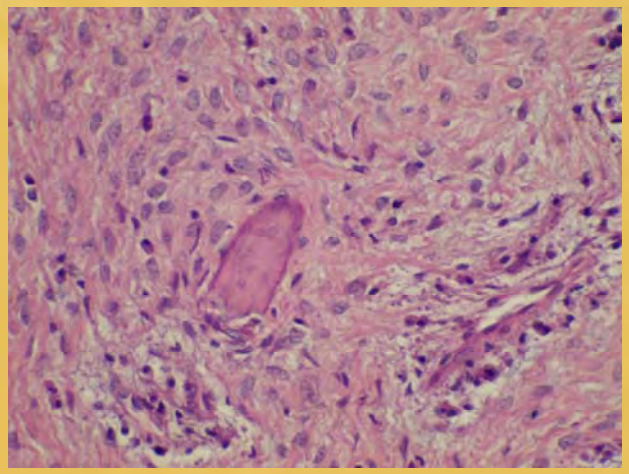

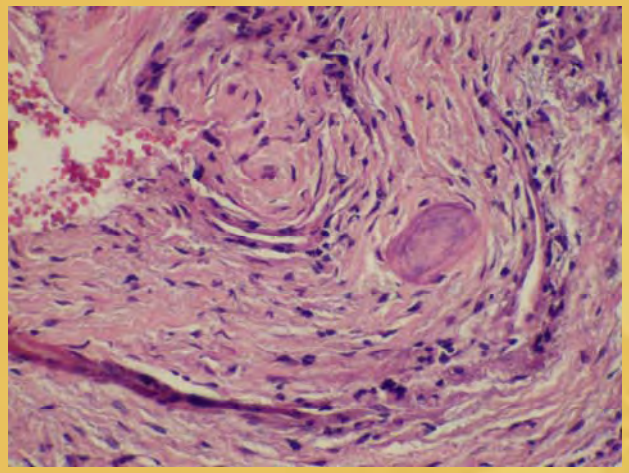

HP Report -- Incisional

- **Odontogenic fibroma**

  Oral cavity, Edentulous ridge, Lower right, Incision

Microscopic Examination -- 2

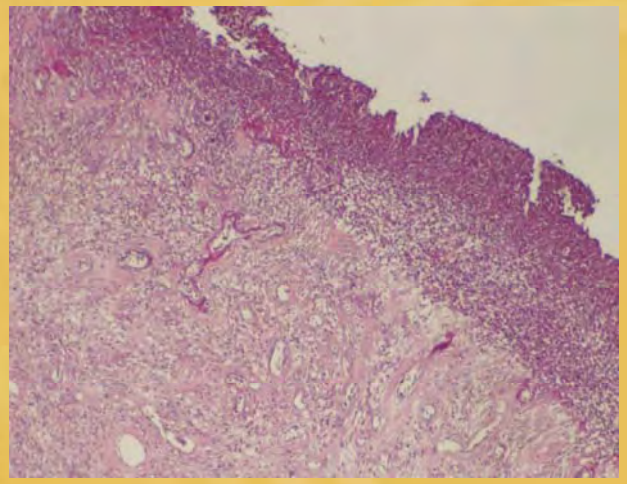

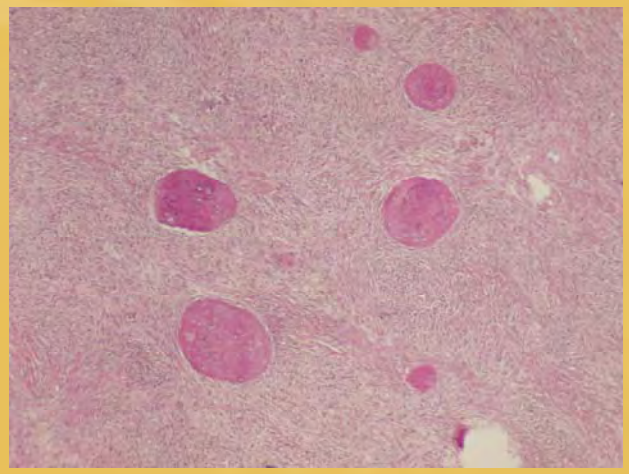

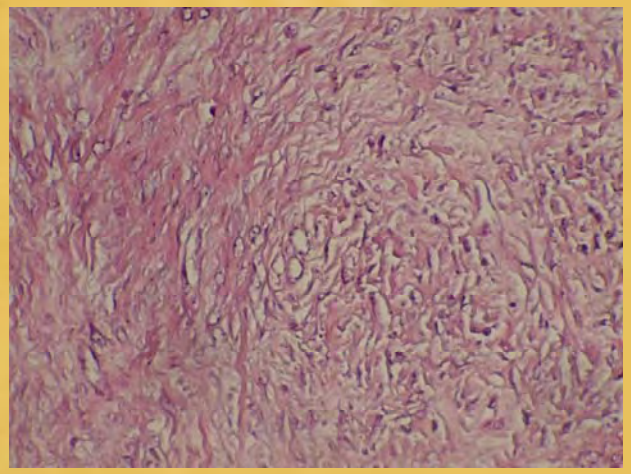

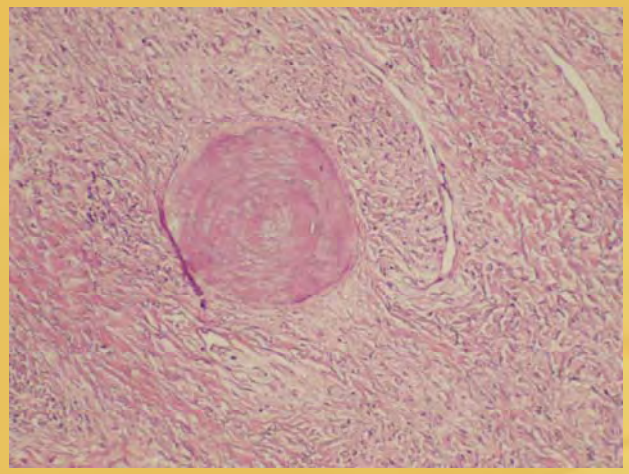

Immunohistochemical Stains

Ki67 (+)

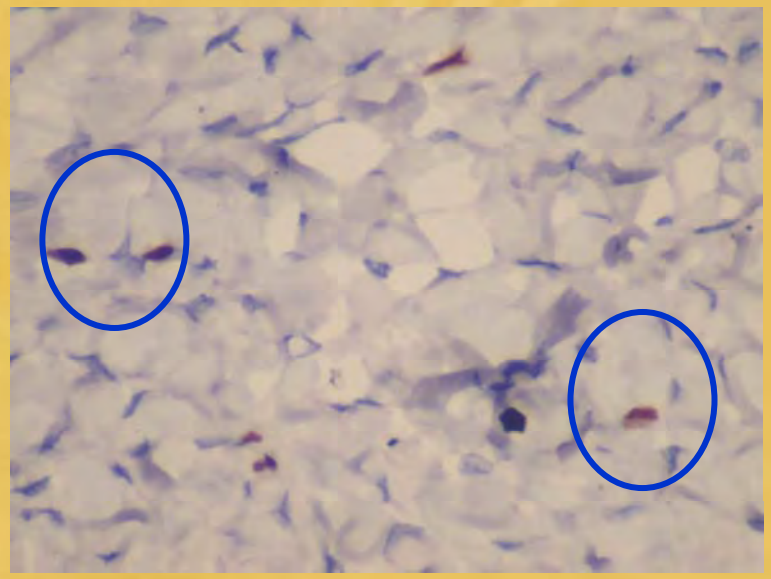

Cytokeratin(+)

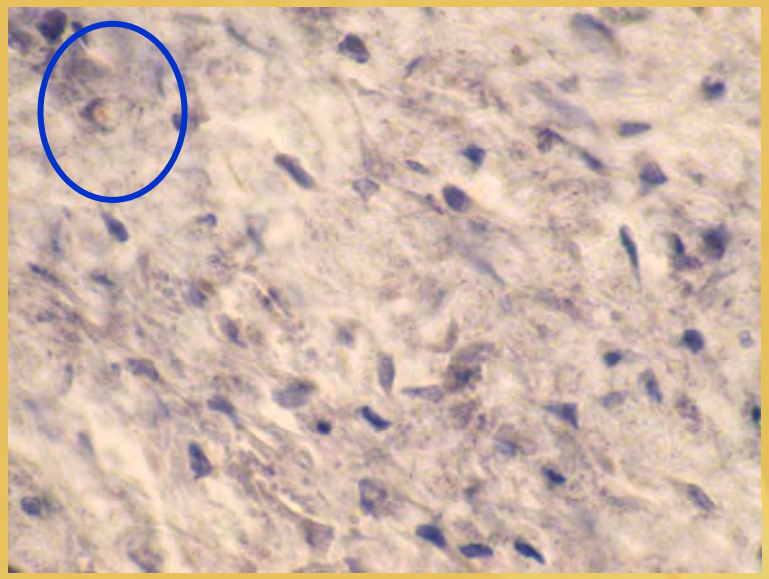

Final Diagnosis

- **Odontogenic fibroma, peripheral**

Oral cavity, Edentulous ridge, Lower right, Excision

Case 10

- **Name : 王 X X**
- **Gender : Male**
- **Age : 68**
- **First visit : 95. 09.04**

- **Chief complaint**

  Swelling over left buccal mucosa for 1 week

Present Illness

- **This 68 y/o male patient suffered from above episode for 1 week. He felt pain and swelling over left buccal mucosa. So, he came to OM OPD for further treatment.**
- **According to her daughter, two weeks ago, he went to 大同hospital due to osteophyte and fever. He also had dry cough during this period.**

Past History

- **Past medical history**
  1. **Systemic disease:Denied**
  2. **Hospitalization: Nil**
  3. **Drug allergy:Denied**
- **Past dental history : NP**
- **Oral habits: A(+), B(+), C(+)**

Intra-oral Findings

- **A swelling mass extending from left mouth angle to molar region.**

  1. Dimension: 4x3.5 cm

  2. Color: red and white

  3. Surface: rough

  4. Consistency: firm

  5. Pain(+)

  6. Tenderness(+)

  7. Induration(+)

  8. Lymphadenopathy(+)

Treatment course

- **95.09.04**

  Clinical impression: oral cancer, left buccal

  Referred to OS -- incisional biopsy, sent for histopathological exam

Microscopic Examination

Granulomatous inflammation (tubercle)

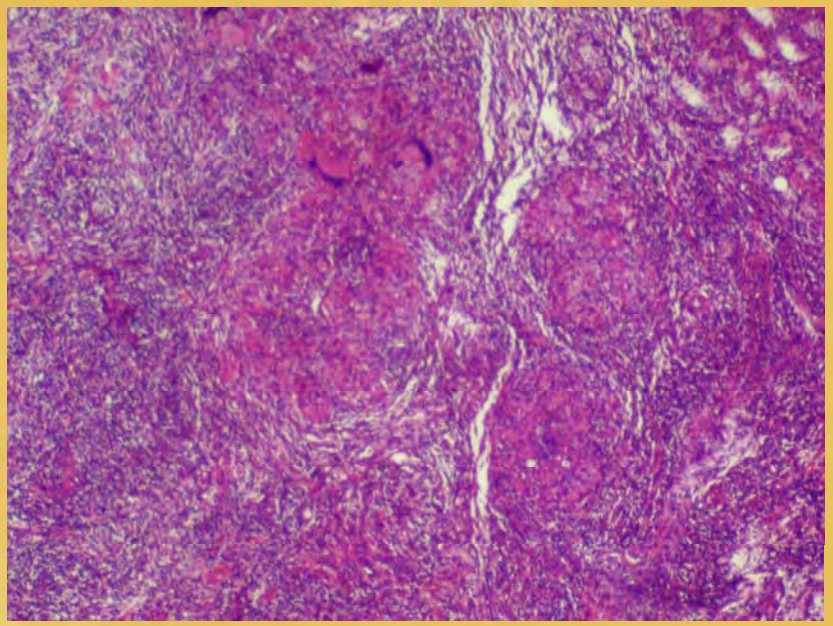

Multinucleated giant cells (Langhan cells) , caseous necrosis, epithelioid histiocytes

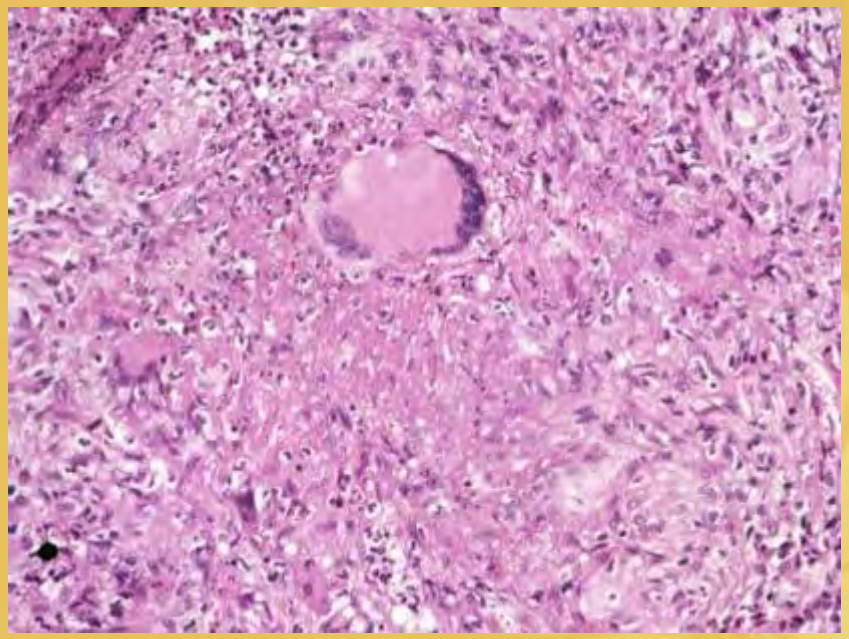

Histochemical Stain

Acid fast stain(+)

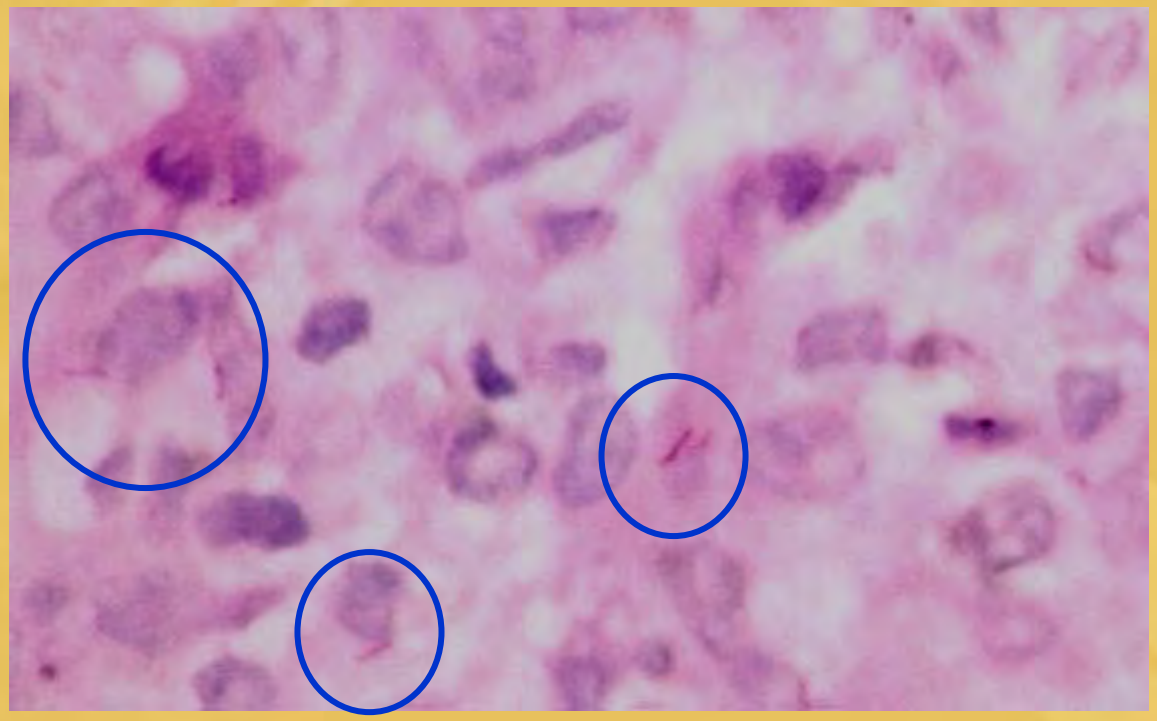

Final Diagnosis

- **Tuberculosis, secondary**

  Oral cavity, Buccal, Left, Incision

- **Referred to 胸腔內科**

  95.09.11 -- 抗酸菌直接鏡檢 (sputum): (++++)

  建議病患住院或在家隔離

  Improved after medications

  96.05.14 -- 抗酸菌直接鏡檢 (sputum): (-)

Chest X-Ray

- **95.09.1: inflammatory or metastatic disease**

- **96.05.14: post-inflammatory pulmonary emphysema, fibrosis and bronchiectasis**

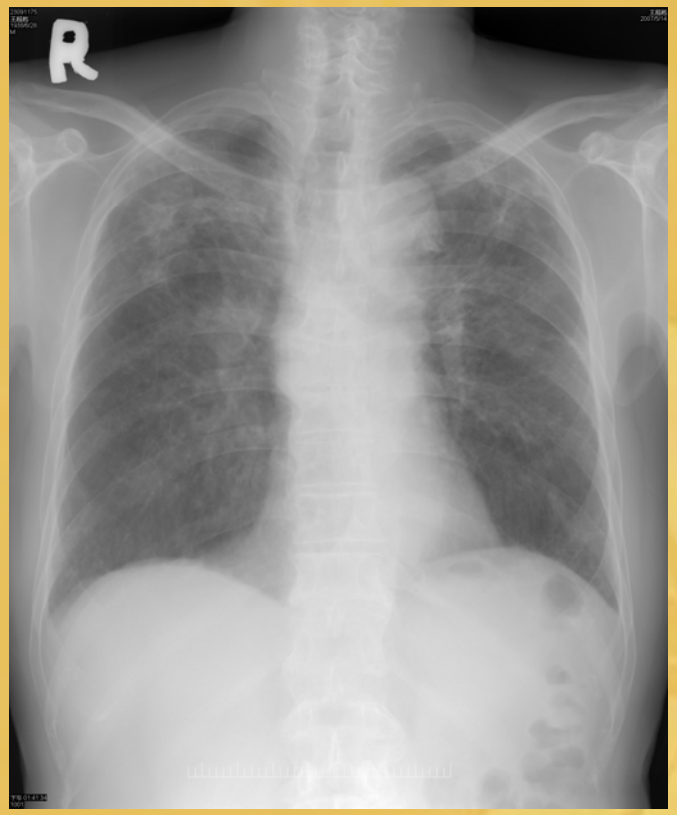

Discussion

- **Oral TB lesions:**

  Secondary TB: 0.5-1.5% (primary: lung)

  Primary: rare

Thank you for your attention !