

NO. 055 Castleman disease, hyaline vascular variant

<ul style="list-style-type: none">➤ 低倍下可見 lymphoid follicle 較大，且 germinal centers 有退化、消失的現象。(regressed or involuted germinal center)。➤ Mantle zone lymphocytes 形成同心圓狀或洋蔥狀的排列(Concentric rings of mantle zone lymphocytes)➤ 可見大量有不成熟內皮細胞的小血管增生。➤ 可見淋巴結內有 fibrosis area 。	<p>重點標記：</p> <ol style="list-style-type: none">1. Regressed germinal centers (Fig. 1,2 red ↑)2. Concentric rings of mantle zone lymphocytes (Fig. 2 yellow lines)3. Increased vascular proliferation (Fig. 3 blue ↑)4. Fibrosis area (Fig. 3 green ↑)
--	--

Fig. 1

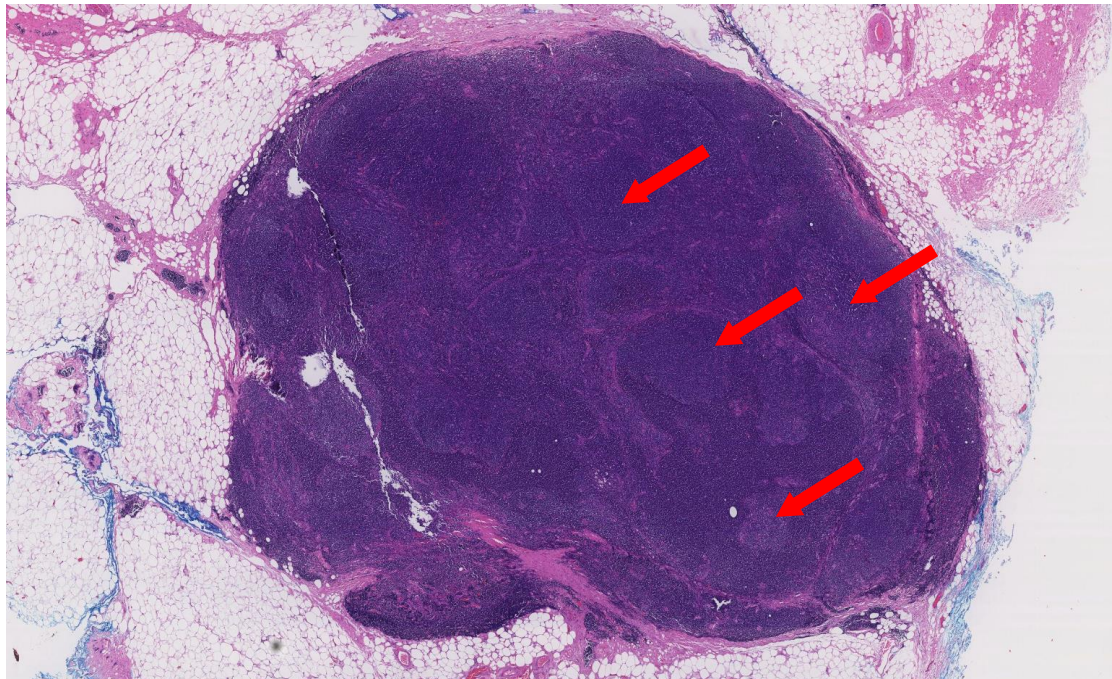


Fig. 2

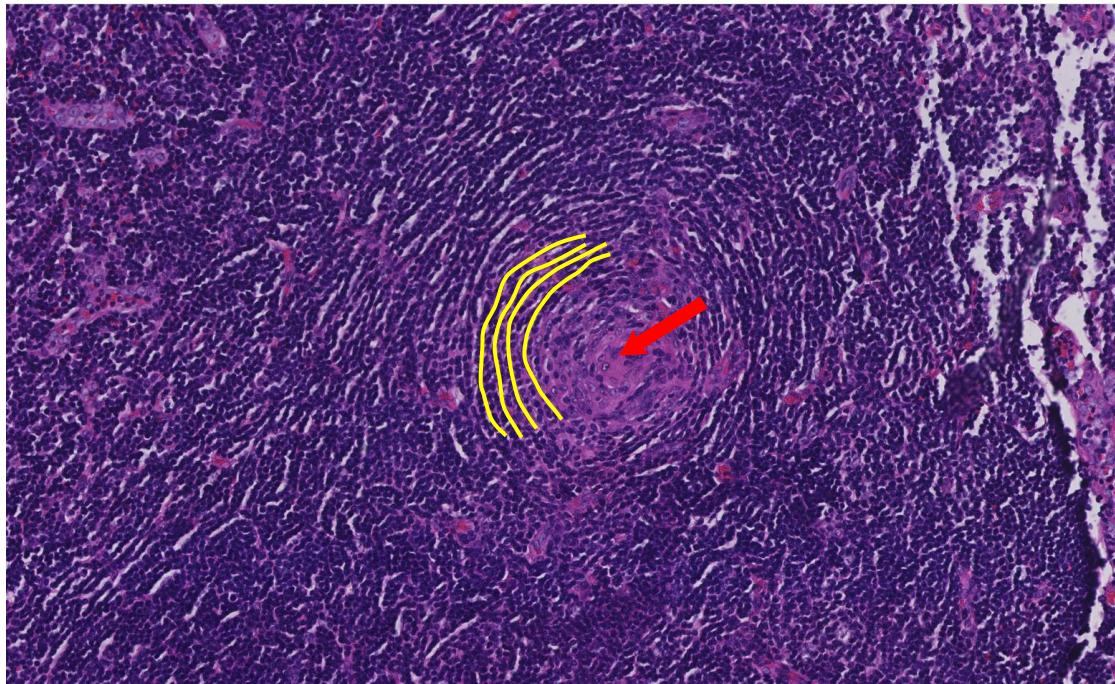


Fig. 3

