

NO. 054 Histoplasmosis

<ul style="list-style-type: none">➤ 此疾病為一種侵襲性黴菌感染。➤ 低倍下可見有著大量發炎細胞的 granulation tissue (Fig. 1 red ↑)及殘餘的 minor salivary gland (Fig. 1 blue ↑)。➤ Granulation tissue 部分於高倍下可見大量 histiocytes 與 chronic inflammatory cells。➤ 此外，可見大量穿插在發炎細胞中的 organisms of <i>Histoplasma capsulatum</i>。	<p>標記重點：</p> <ol style="list-style-type: none">1. Organisms of <i>Histoplasma capsulatum</i> (Fig. 2,3 red ↑)2. Histiocyte (Fig. 2 yellow ↑)3. Lymphocyte (Fig. 2 green ↑)
--	--

Fig. 1

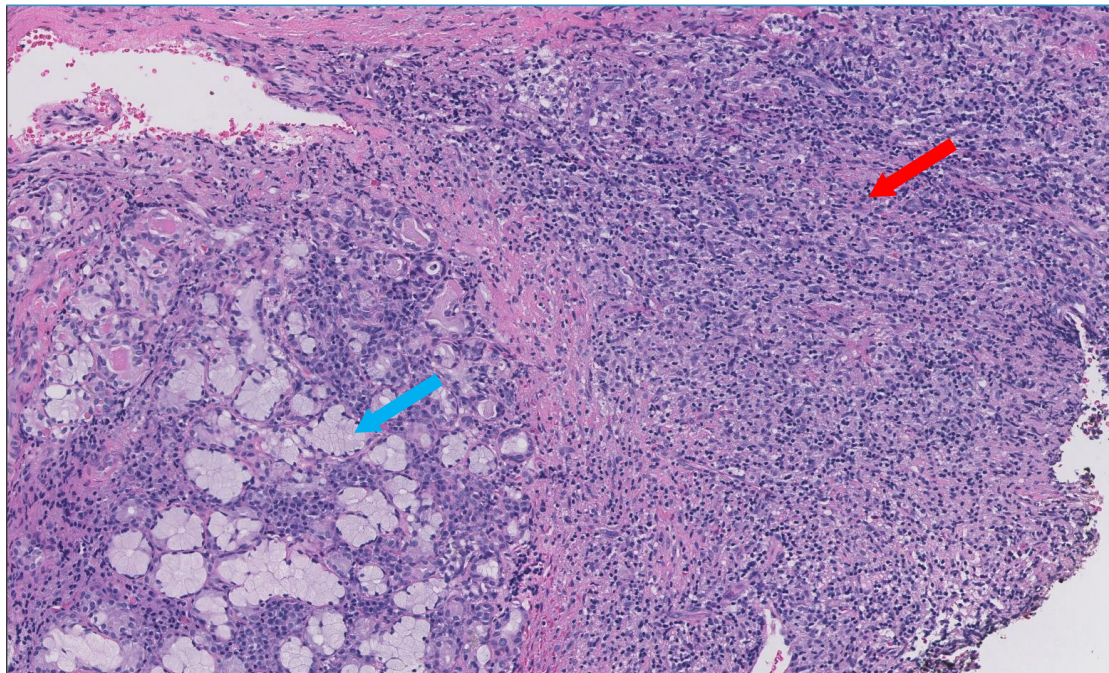


Fig. 2

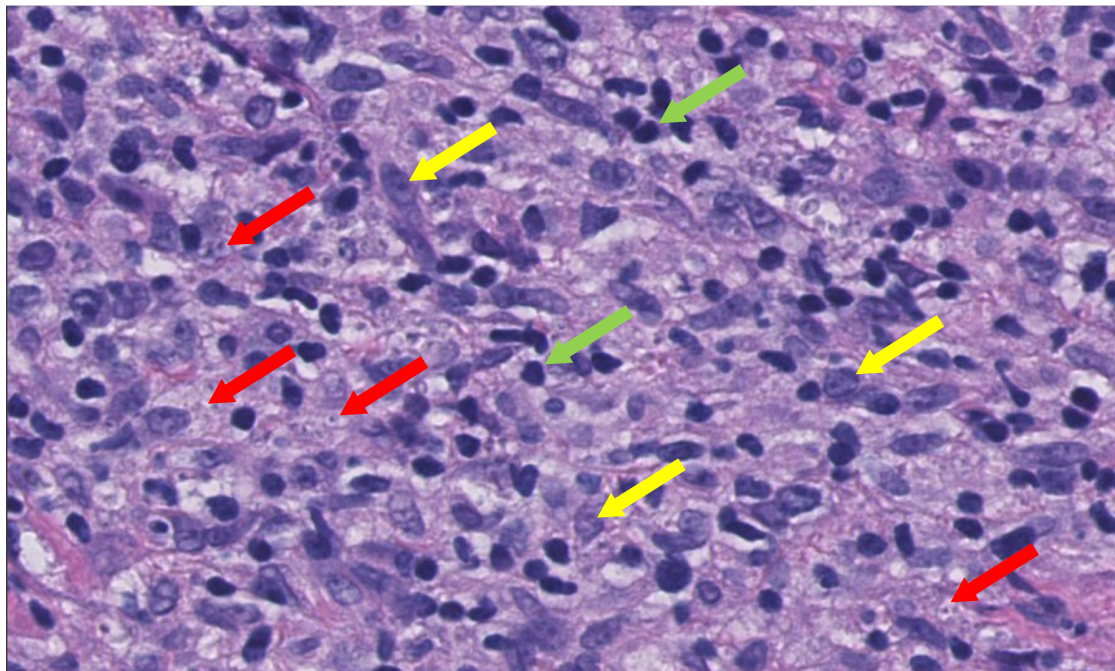


Fig. 3

