

## NO. 028 Plasmacytoma/Multiple myeloma

<ul style="list-style-type: none"><li>➤ 似 lymphoma，病灶區都是一片黑藍色 (diffuse pattern) (Fig. 1 red ★)，是 bone marrow disorder 造成，但組成的細胞型態不一樣。</li><li>➤ 高倍下可見，plasma cell 呈現多角形，核偏向一邊，cytoplasm 像影子一般，此片的 plasma cell 型態大小不一 (pleomorphism)，是不正常的表現 (Fig. 2&amp;3 yellow ↑)。</li></ul>	<p>標記重點：</p> <ol style="list-style-type: none"><li>1. Proliferation of plasma cells (Fig. 1 red ★)</li><li>2. Plasma cells 之核不規則，偏向一側且呈 pleomorphism (Fig. 2&amp;3 yellow ↑)</li></ol>
--	--

Fig. 1

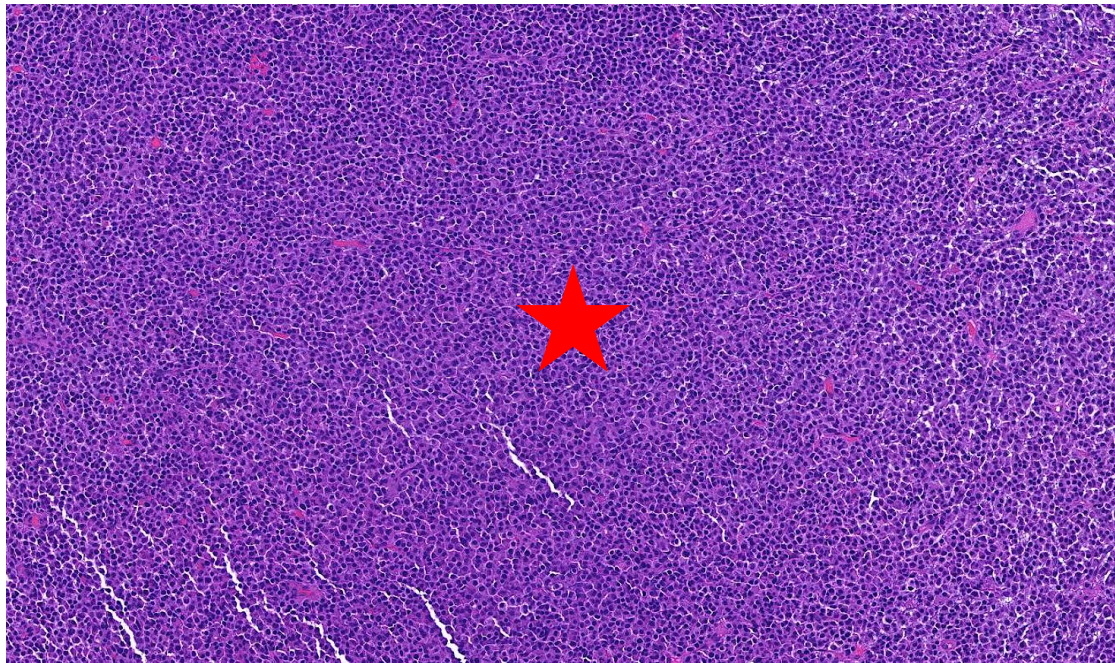


Fig. 2

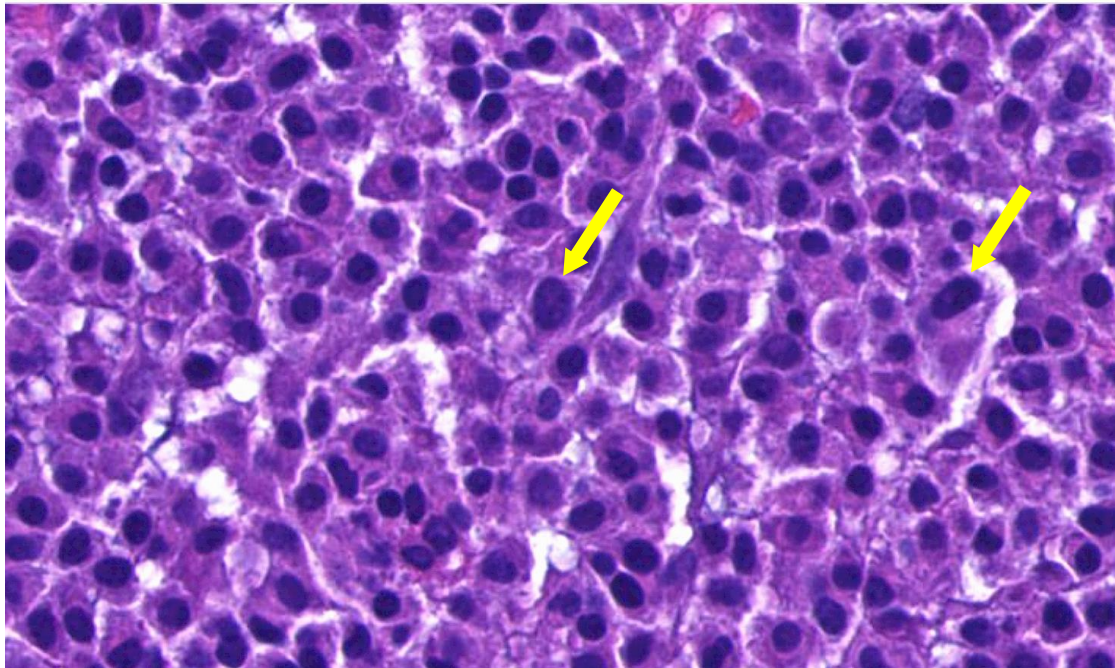


Fig. 3

