

NO. 025 Nevus · Intra-mucosal

<ul style="list-style-type: none">➤ 表皮是 stratified squamous epithelium 。➤ 表皮下有很多 nest of nevus cell · nevus cell 為 small 、uniform nuclei 且有少量的 eosinophilic cytoplasm 。（Fig. 1&2 blue ↑）➤ Nevus cell 所分泌的 pigment （ melanin ）· 呈現黑棕色 。（Fig. 2 yellow ↑）	<p>標記重點：</p> <ol style="list-style-type: none">1. Stratified squamous epithelium (Fig. 1 red ↑)2. Nevus cells (Fig. 1&2 blue ↑)3. Pigments (Fig. 2 yellow ↑)
---	--

Fig. 1

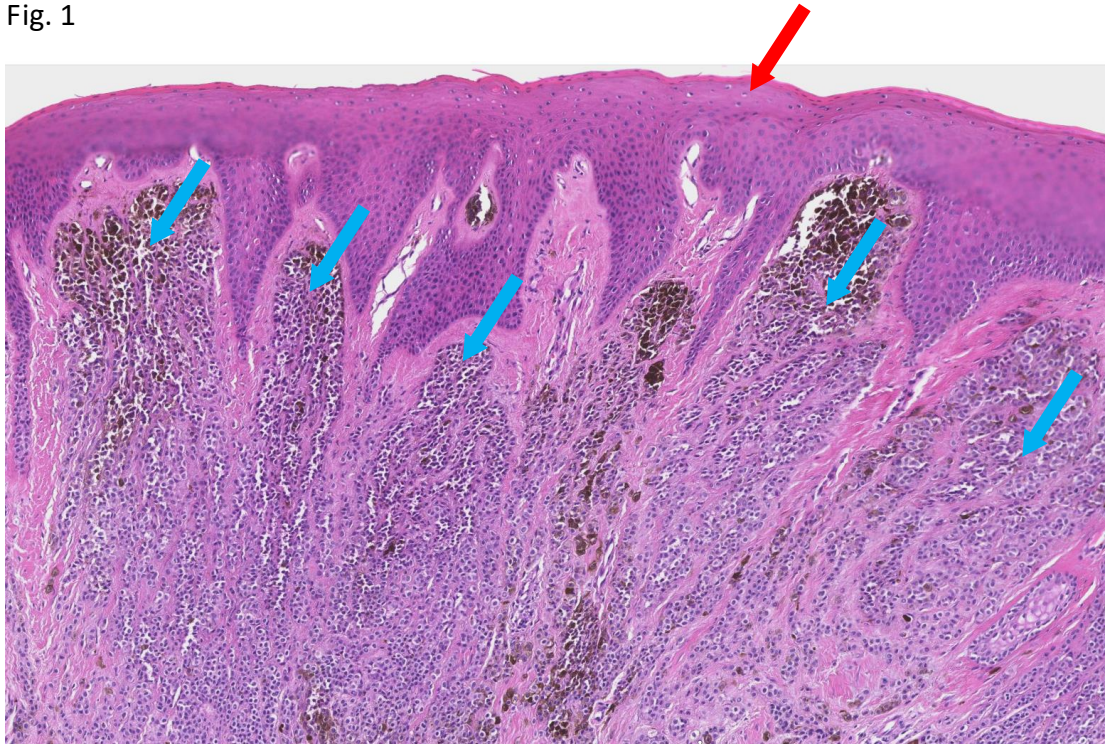


Fig. 2

