

NO. 023 Neurofibroma

<ul style="list-style-type: none">➤ 表皮為 stratified squamous epithelium · 往下有 well circumscribed, unencapsulated 粉紅色區域。裡頭由 spindle cells 混亂排列(haphazard arrangement) · 不似 Schwannoma 平行排列。 (Fig. 1 red ★)➤ Spindle cells 具有小、濃染之波浪狀核 (wavy nuclei) (Fig. 2 yellow ↑) 並伴隨著纖細的 collagen bundles (Fig. 2 red ↑)。➤ 腫瘤內部夾雜小神經束(Fig. 3 green ↑)。	<p>標記重點：</p> <ol style="list-style-type: none">1. Spindle-shaped cell with wavy nuclei (Fig. 2 yellow ↑)2. Nerve bundles (Fig. 3 green ↑)
-----------------------------------------------------------------------------------------------------------------------------------------------------------------------------------------------------------------------------------------------------------------------------------------------------------------------------------------------------------------------------	------------------------------------------------------------------------------------------------------------------------------------------------------------------

Fig. 1

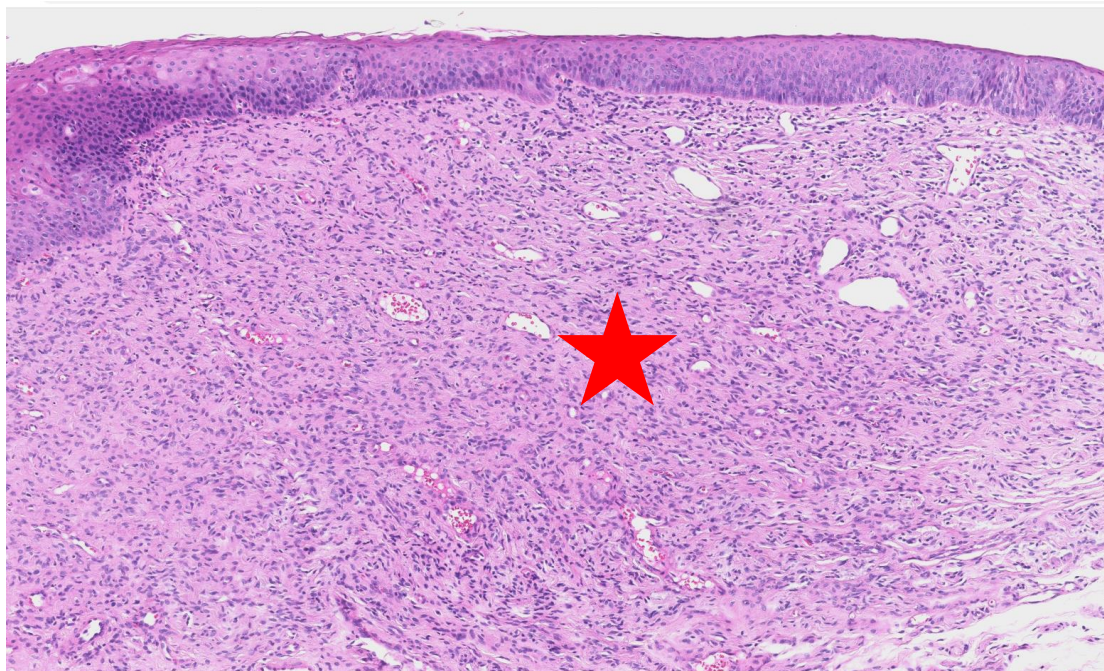


Fig. 2

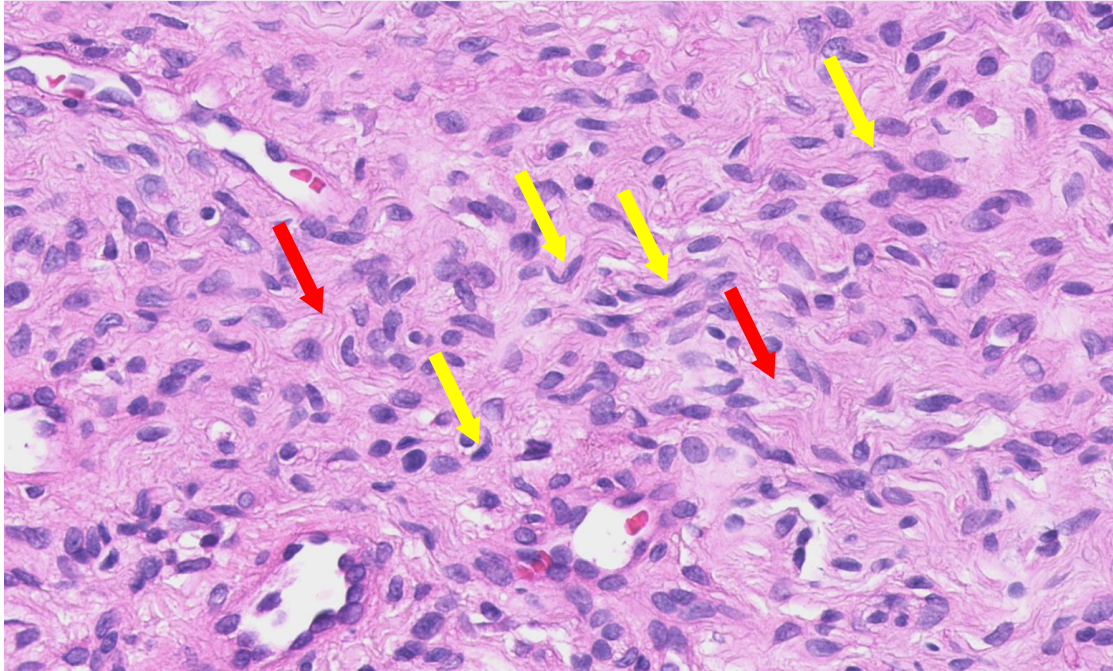


Fig. 3

