

## NO. 019 Congenital epulis

<ul style="list-style-type: none"><li>➤ Epulis 泛指口腔的腫塊跟突起。</li><li>➤ 下方的結締組織為重點，其間充滿 granular cell，在高倍下，cytoplasm 內有很多 granule，且 cell nucleus 偏向一側。(Fig. 2 red ↑)</li><li>➤ 雖然都是由 granular cells 構成的病灶，但 granular cell tumor 上方的上皮呈現 pseudo-epitheliomatous hyperplasia；而 congenital epulis 表皮很薄且有 atrophy of rete peg 的現象。(Fig. 1 yellow line)</li></ul>	<p>標記重點：</p> <ol style="list-style-type: none"><li>1. Large, round cells with abundant granular, eosinophilic cytoplasm and round to oval, lightly basophilic nuclei (Fig. 2 red ↑)</li><li>2. Atrophy of the rete ridge (Fig. 1 yellow line)</li></ol>
-----------------------------------------------------------------------------------------------------------------------------------------------------------------------------------------------------------------------------------------------------------------------------------------------------------------------------------------------------------	---------------------------------------------------------------------------------------------------------------------------------------------------------------------------------------------------------------------------------------------------------

Fig. 1

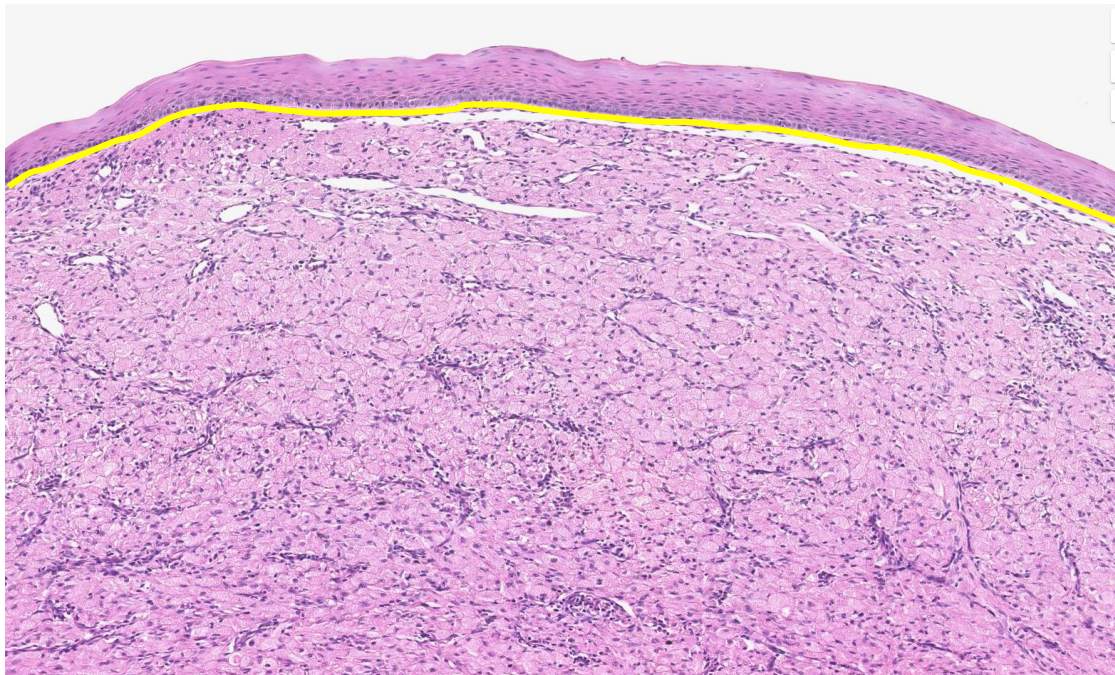


Fig. 2

