

NO. 086 Oncocytoma

<ul style="list-style-type: none">➤ 為 well encapsulated，可見與周邊的 parotid gland 有平順的邊緣，周邊有 fibrous capsule。➤ Tumor 都是由 oncocyte 構成。➤ Oncocyte 的 cytoplasm 均勻，有顆粒狀（內含豐富粒線體），有兩種型態：淡染且較大或深染較小➤ Tumor 內的 stroma 很少	<p>標記重點：</p> <ol style="list-style-type: none">1. Fibrous capsule (Fig. 1 blue ↑)2. Parotid gland (Fig. 1 yellow ↑)3. Oncocyte：<ul style="list-style-type: none">- dark cell (較小)：eosinophilic cytoplasm，pyknotic nucleus (Fig. 2 blue ↑)- light cell (較大)：oncocytic cytoplasm，oval vesicular nucleus (Fig. 2 green ↑)
---	---

Fig. 1

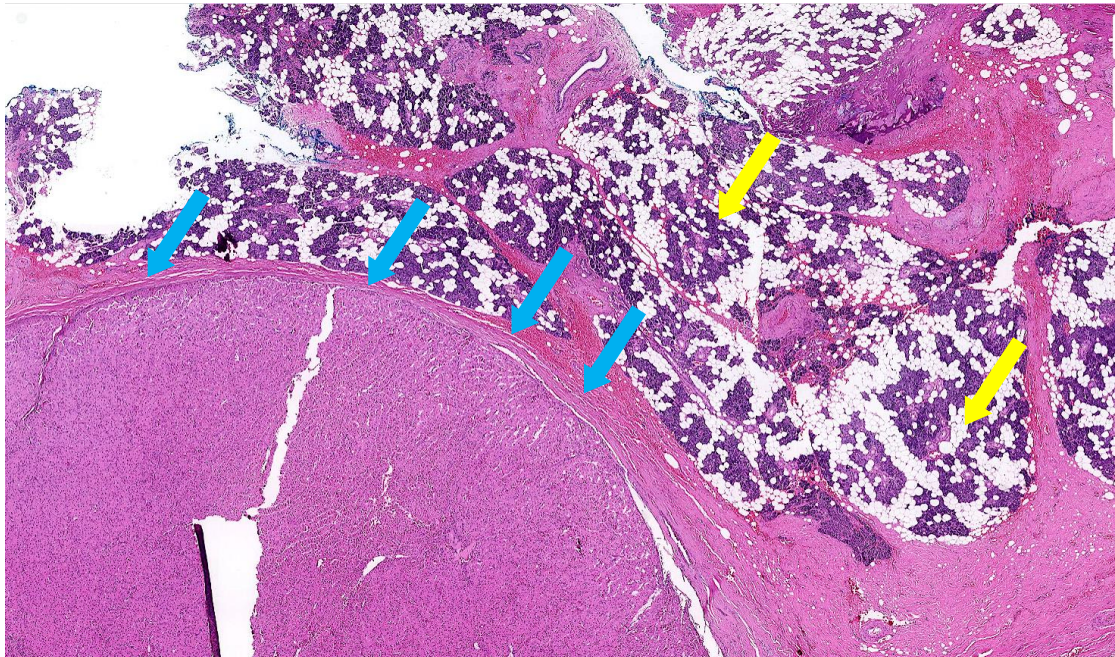


Fig. 2

